

Open Lab Bone Review

D.HAMMOUDI, MD

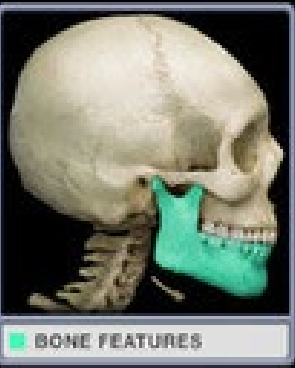Prince George community college

Tutoring Center Lago

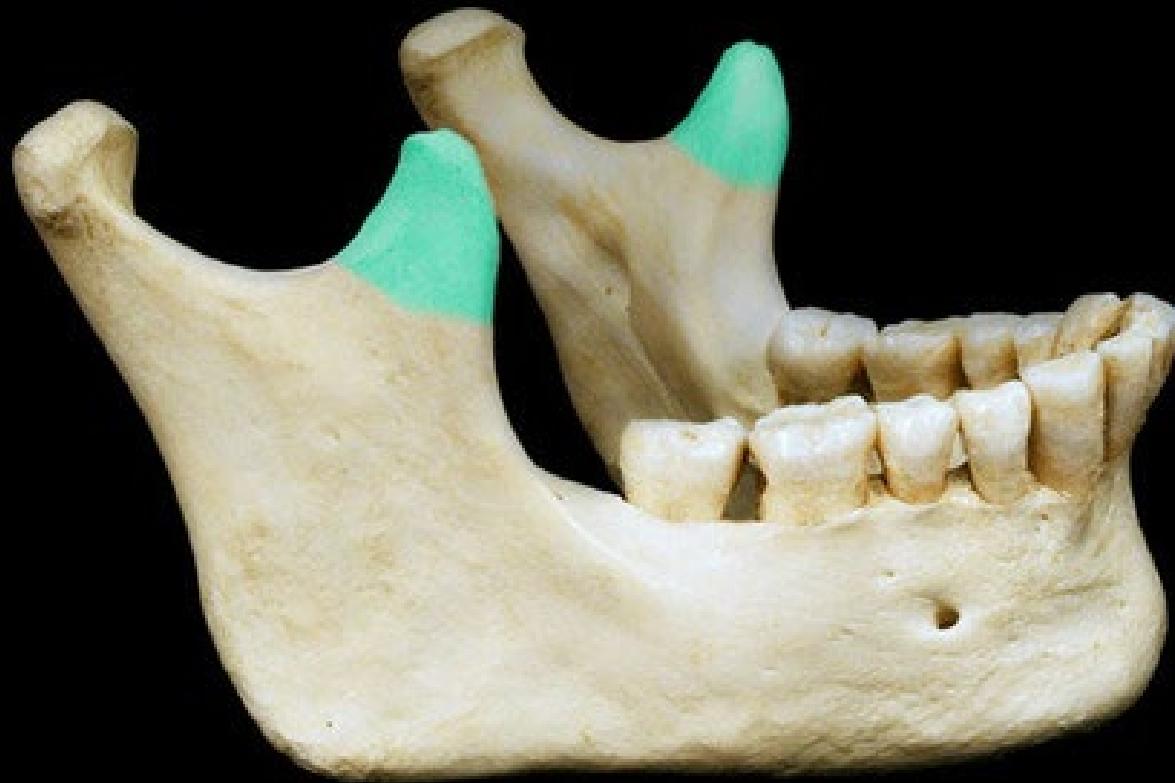

PRINCE GEORGE'S
COMMUNITY COLLEGE

Mandible

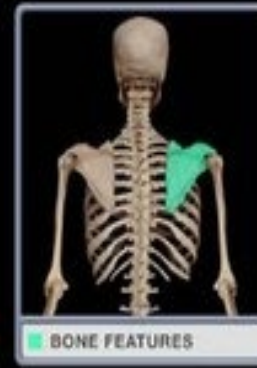

Coronoid process

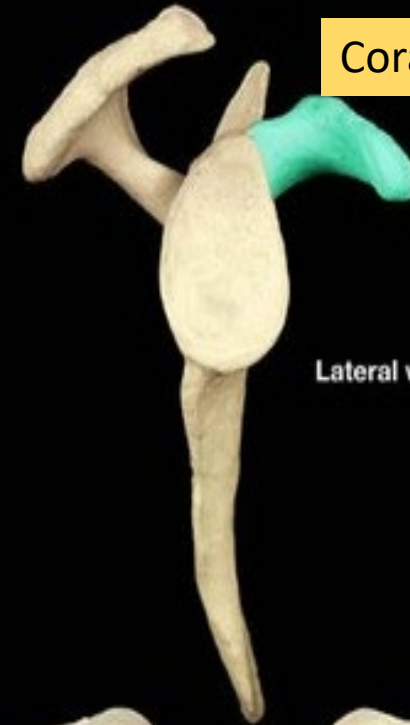

Lateral view

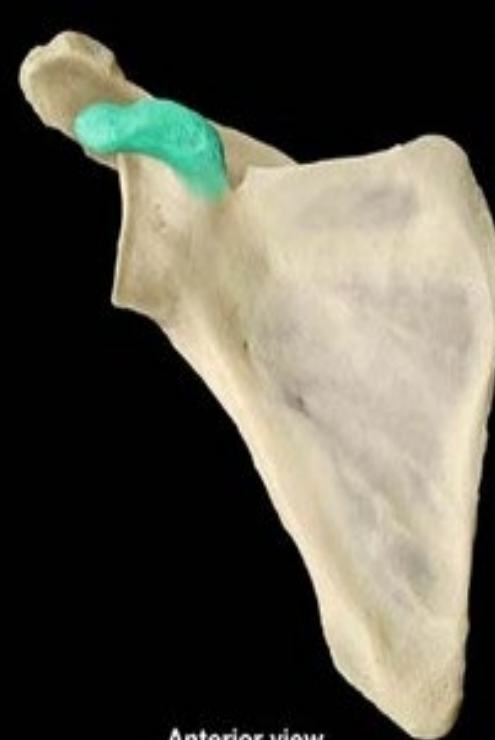Scapula



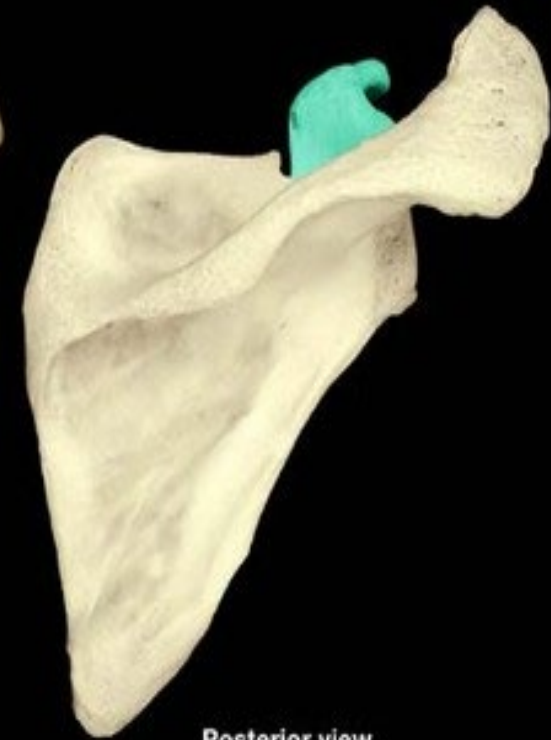Coracoid process



Lateral view

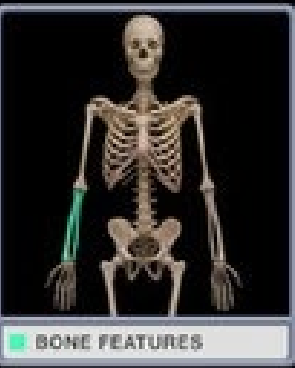

Anterior view



Posterior view

Radius and ulna

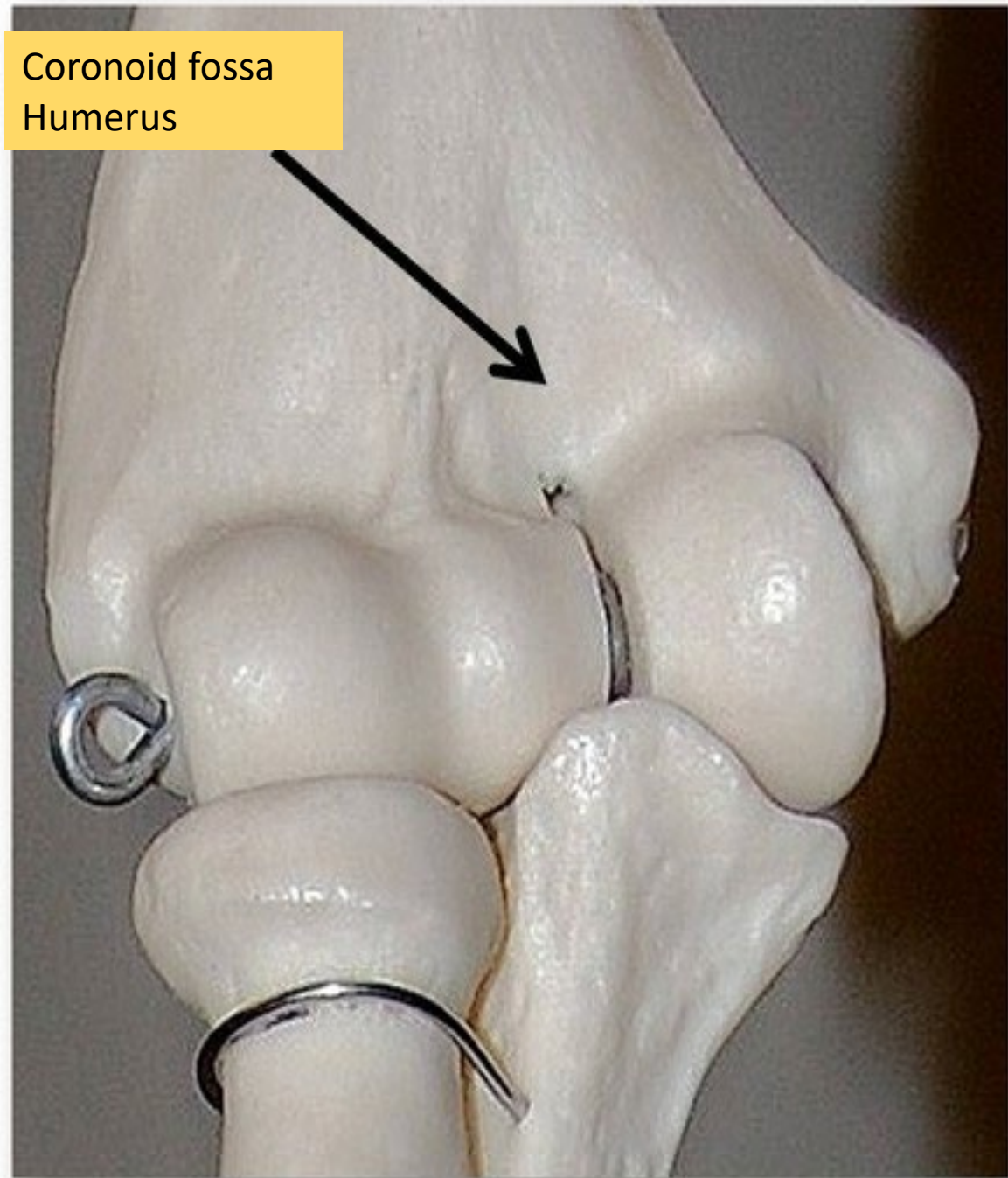
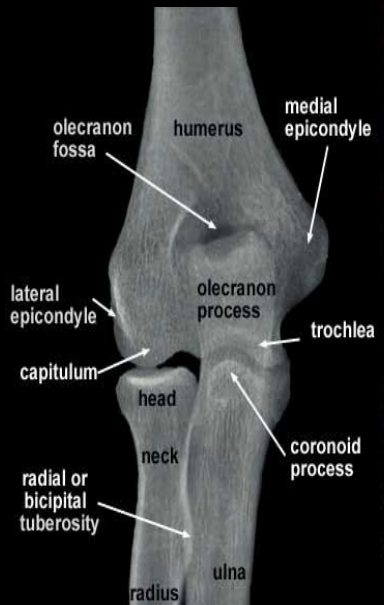


Coronoid process
Ulna



Anterior view

Posterior view



Noid - coid - noid

Coracoid lies between the two Noids

Coronoid-jaw-mandible

Coracoid-shoulder-scapula

Coronoid-elbow-distal humerus-proximal ulna



Conoid tubercle
Clavicle

GENERAL REVIEW

Bone Basic functions ?

- A. support
- B. protection
- C. movement – assistance in
- D. RBC formation-hemopoiesis
- E. mineral homeostasis +importance of calcium
- F. energy supply -yellow marrow
- G. detoxification

four cell types of bone?

1. osteogenic
2. osteoblasts
3. osteocytes
4. osteoclasts

- THE SKULL
- ? BONES
- ALL FUSED EXCEPT ONE.:?
- JOINTS = ?
- CRANIAL CAVITY ? BONES=CRANIAL BONES
- ? LEFT = FACIAL BONES
- ? MORE IN THE EARS

- THE SKULL
- = 22 BONES
- ALL FUSED EXCEPT ONE.:HYOID BONE
- JOINTS = SUTURES
- CRANIAL CAVITY 8 BONES=CRANIAL BONES
- 14 LEFT = FACIAL BONES
- 3 MORE IN THE EARS

Paired Cranial Bones?

Unpaired Cranial Bones?

Paired Cranial Bones:

- Parietals
- Temporals

Unpaired Cranial Bones:

- Frontal
- Occipital
- Sphenoid
- Ethmoid

Paired Facial Bones:?

-

Paired Facial Bones:

- Lacrimals
- Nasals
- Zygomatics
- Maxillae
- Palatines
- Inferior Nasal Conchae

Unpaired Facial Bones:

Unpaired Facial Bones:

- Vomer
- Mandible
- Hyoid

- *In the middle ears bones(6)?*

middle ears

- *In the (6):*
 - **malleus (2)**
 - **incus (2)**
 - **stapes (2)**

- What **bone** articulates with:

Ulna?

Radius?

- What **bone** articulates with:

ulna (articulates with trochlea)

radius (articulates with capitulum)

- **function of a lacunae?**

- **function of a lacunae?**

It houses osteocytes

- hip bone is composed of:

- which fuse at the?

The hip bone is composed of three elements:

- the ilium
- ischium
- and pubis

which fuse at the acetabulum (the socket of the hip joint).

1. sagittal suture—?
coronal suture—?
lambdoidal suture—?
squamous suture—?

1. sagittal suture—left and right parietal bones

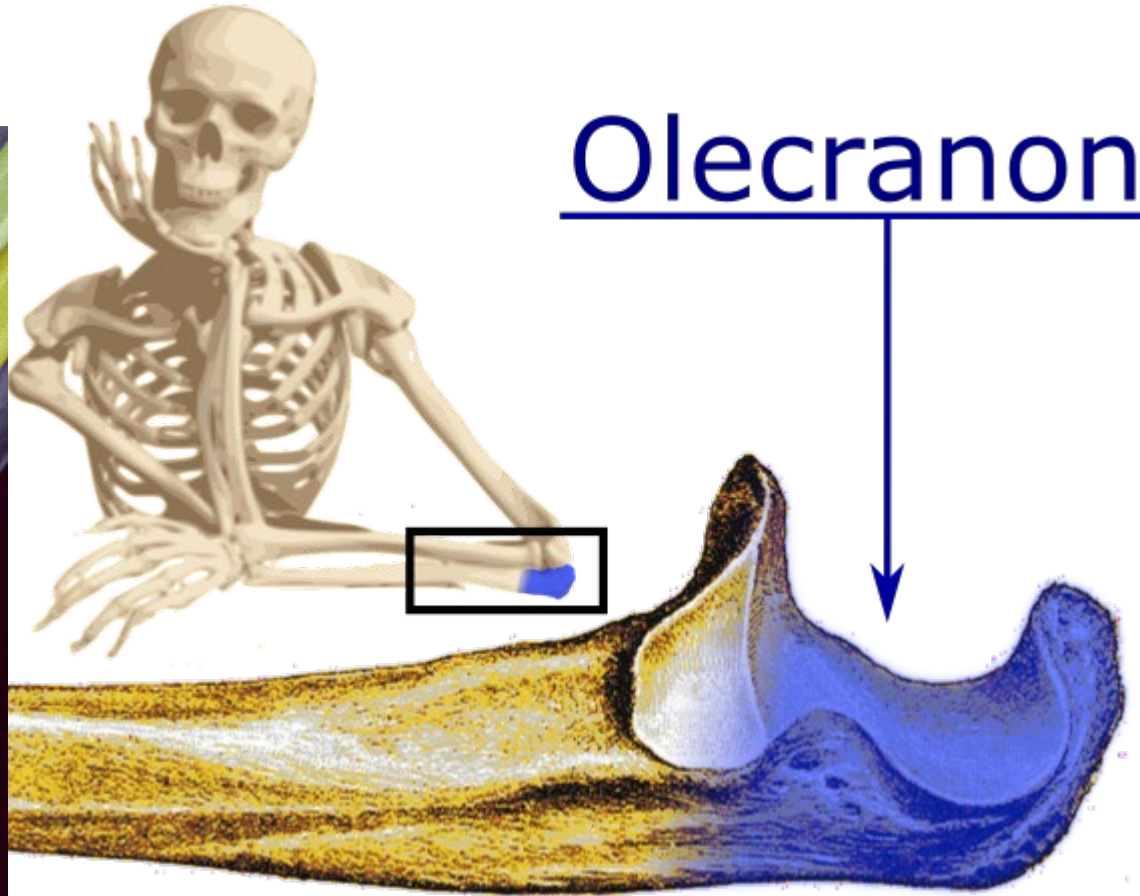
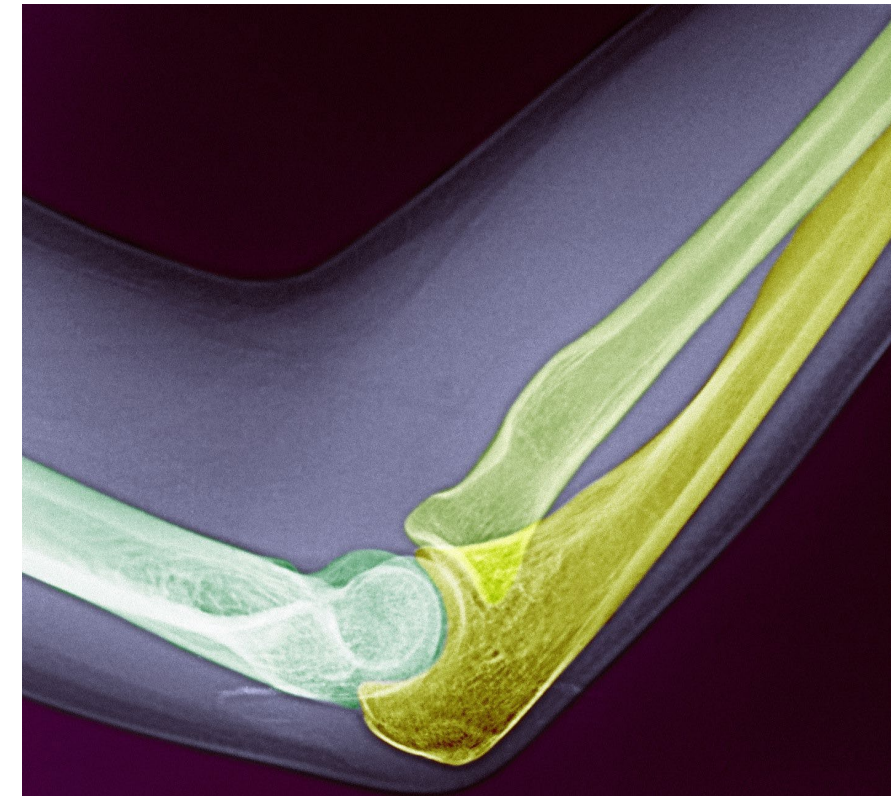
coronal suture—frontal bone and both parietal bones

lambdoidal suture—occipital bone and both parietal bones

squamous suture—temporal bone and parietal bone

Olecranon process ?

Prominent bump elbow



Bone Markings: Depressions and Openings

Meatus – ?

Sinus – ?

Fossa – ?

Groove – ?

Fissure – ?

Foramen – ?

Bone Markings: Depressions and Openings

Meatus – canal-like passageway

Sinus – cavity within a bone

Fossa – shallow, basin-like depression

Groove – furrow

Fissure – narrow, slit-like opening

Foramen – round or oval opening through a bone

- A. Symphysis**
- B. suture**
- C. syndesmosis**
- D. pivot**
- E. hinge.**

1 Intervertebral joints

3. Knee joint.

3. Joint between the atlas and axis

4. Joints between the cranial bones.

5. Joint between the distal ends of the tibia and fibula.

6. Joint between the right and left pubic bones (or pubes).

- A. Symphysis
- B. suture
- C. syndesmosis
- D. pivot
- E. hinge.

23. Intervertebral joints

A

24. Knee joint.

E

25. Joint between the atlas and axis

D

26. Joints between the cranial bones.

B

28. Joint between the distal ends of the tibia and fibula.

C

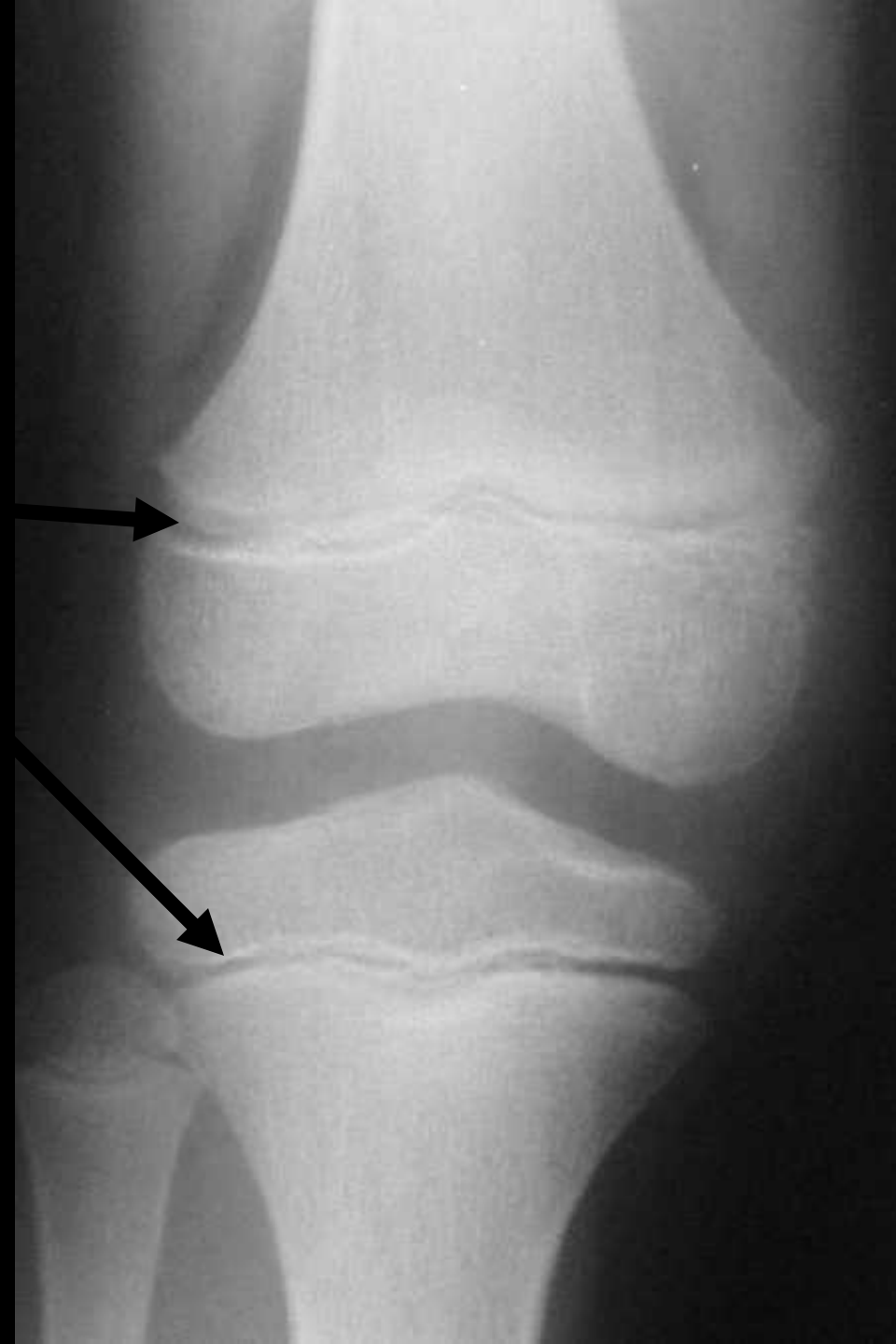29. Joint between the right and left pubic bones (or pubes).

A

Name the axial bones?

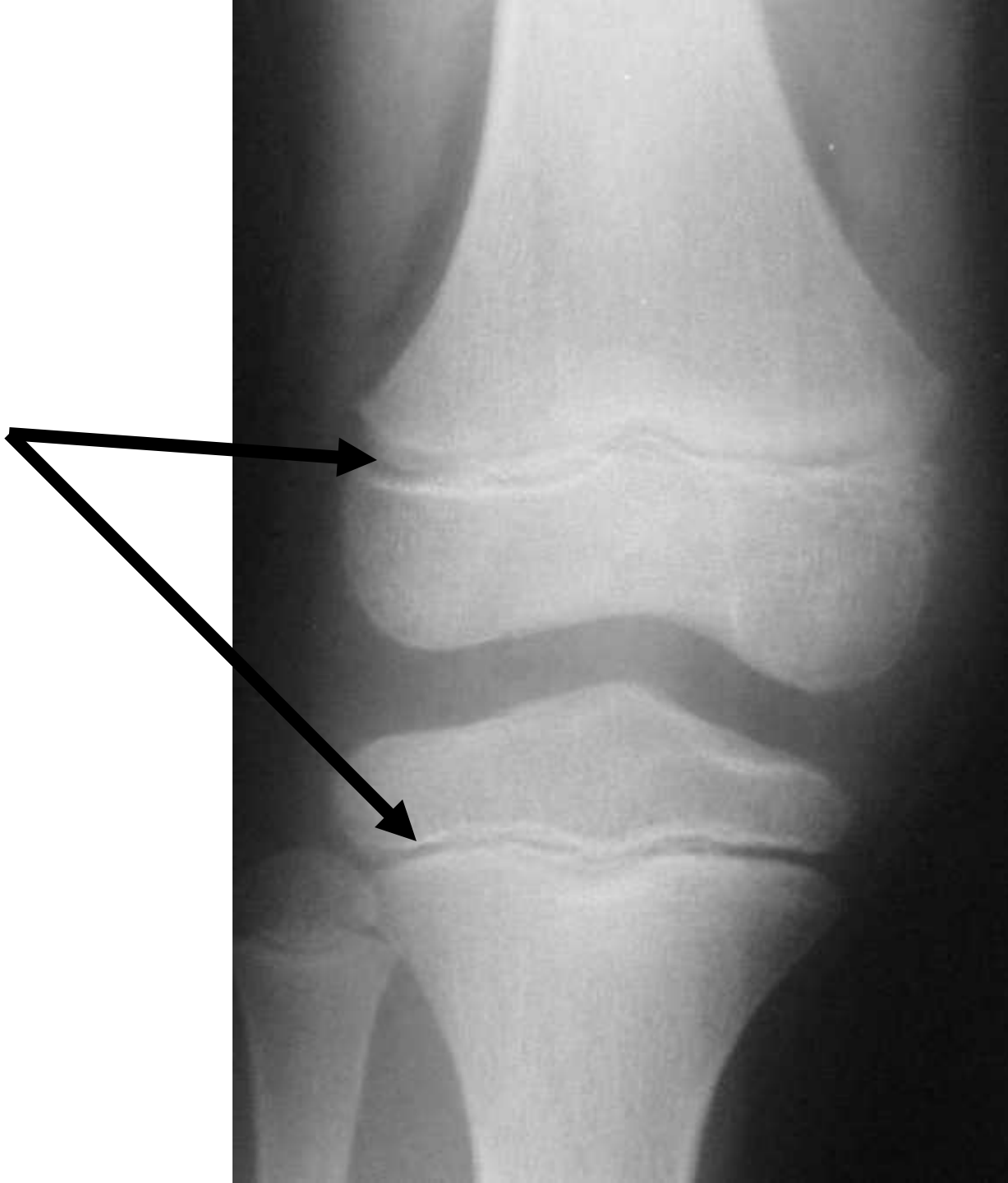1/ . Name the axial bones? write on the same line

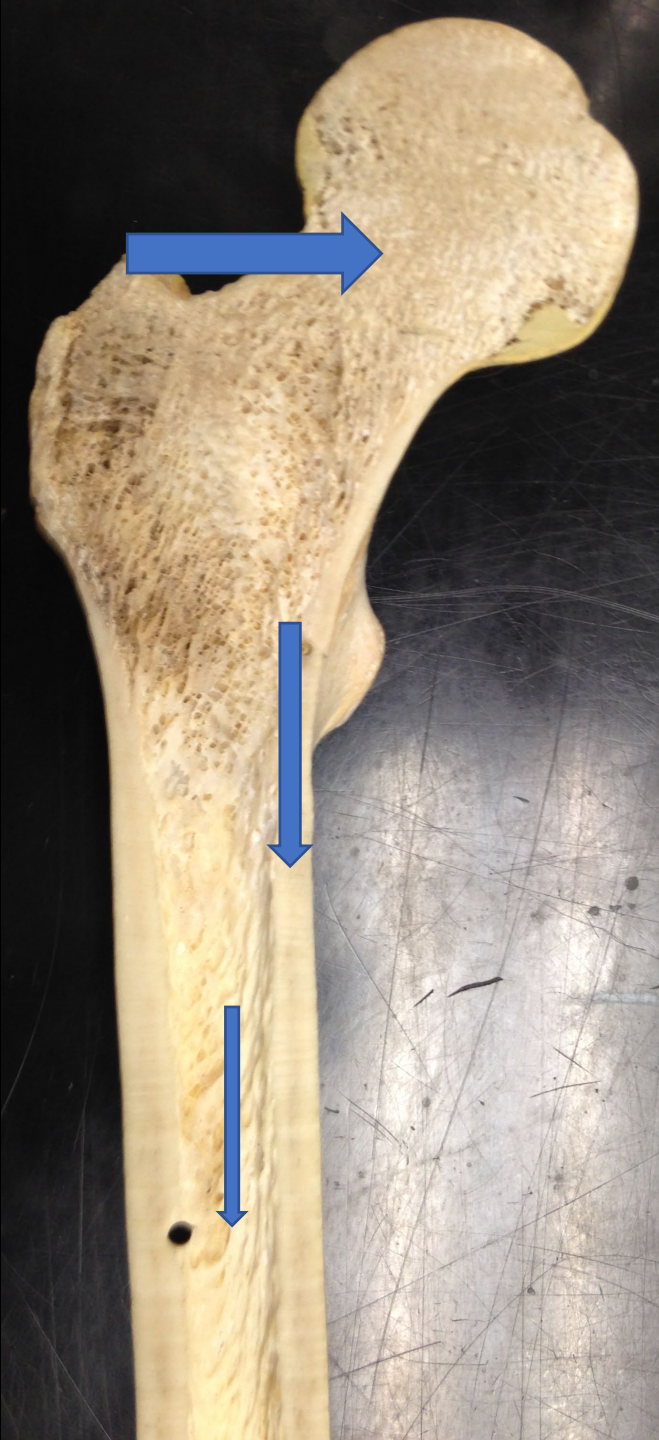- a. skull bones
- b. auditory ossicles
- c. hyoid bone
- d. vertebral column
- e. sternum
- f. ribs

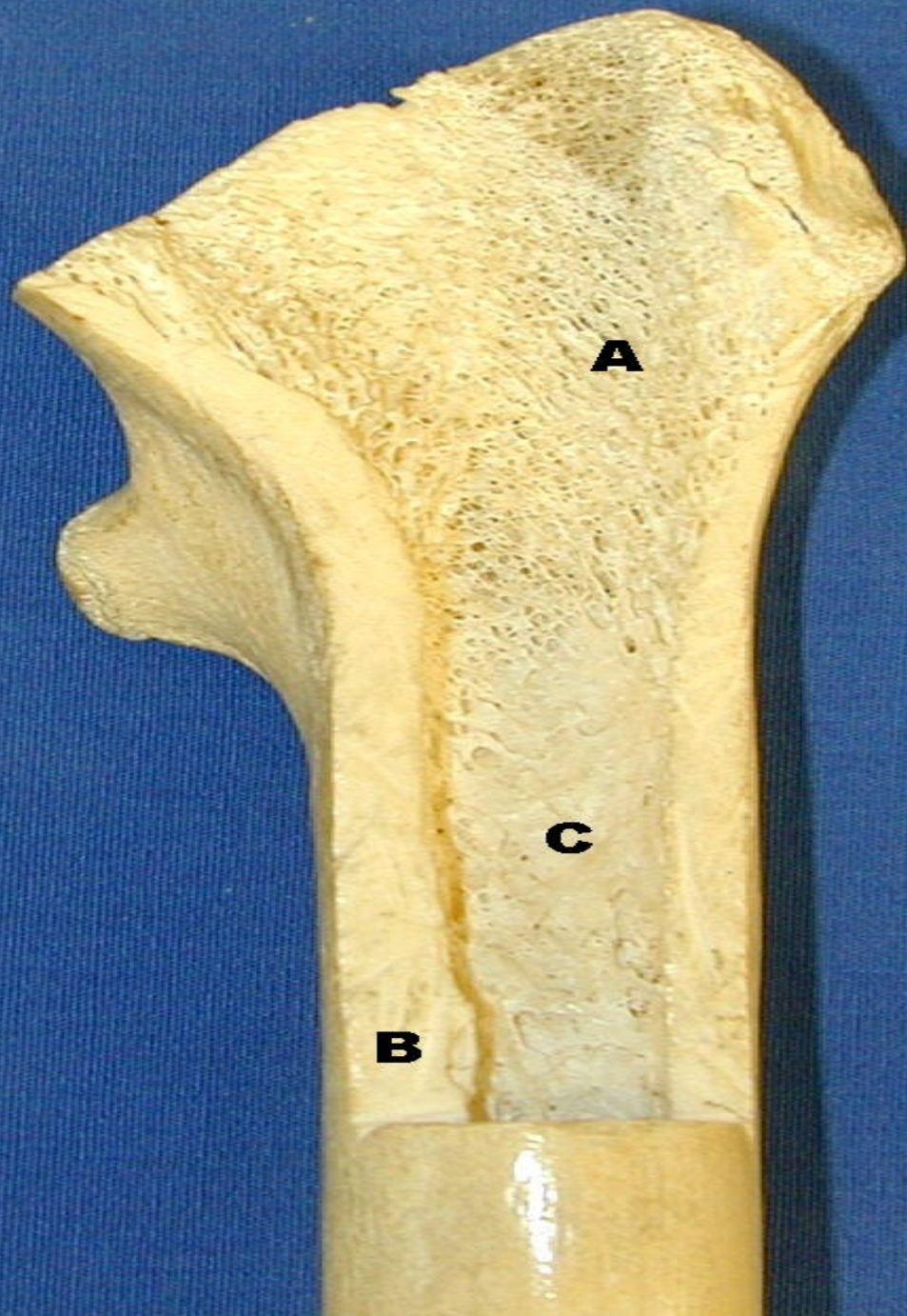


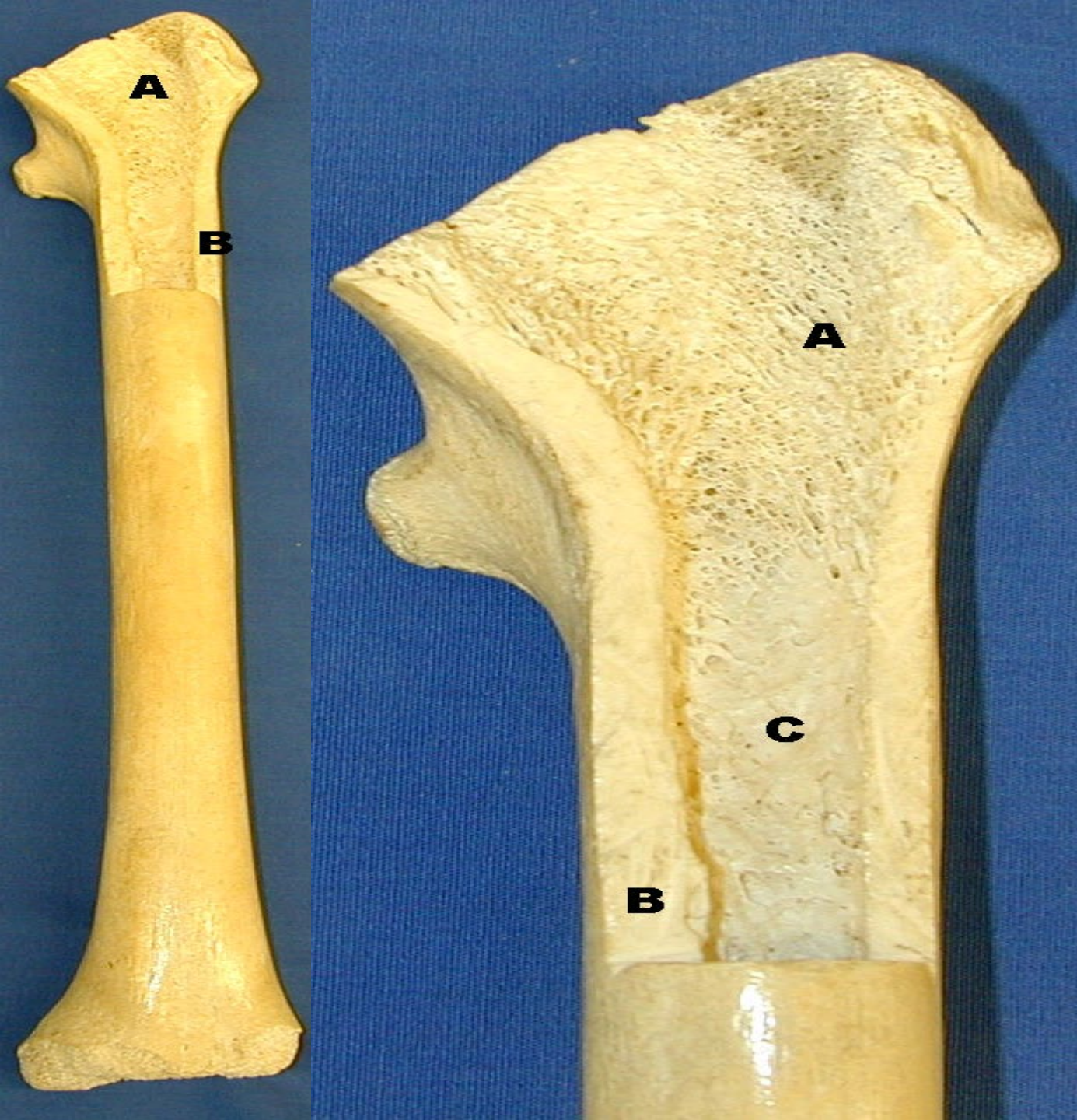
18/ What these 2 arrows point to?

Growth plate= EPIPHYSEAL PLATE









A:SPONGY BONE CONTAIN
RED BONE MARROW

B:COMPACT BONE

C:MEDULLARY CAVITY
CONTAINING YELLOW
MARROW

How many bones the human hands?

How many bones the human hands?

27 bones:

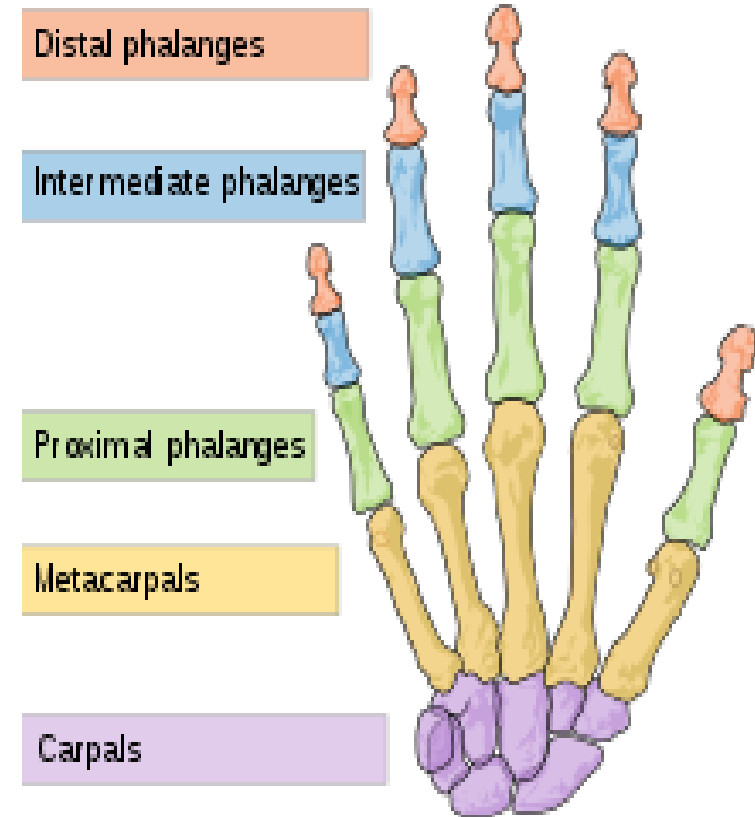
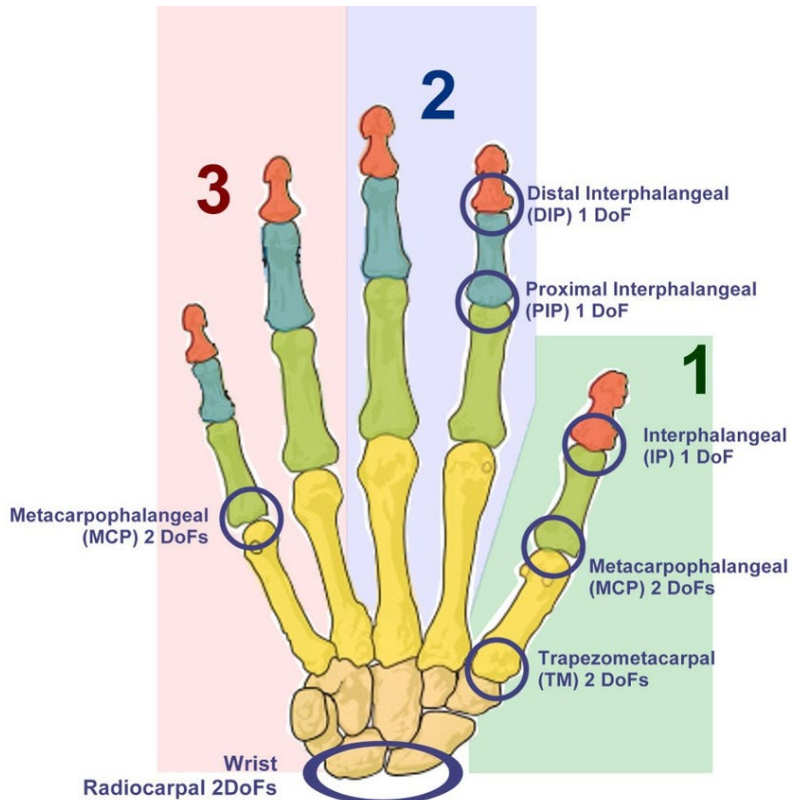
the carpals or wrist accounts for 8;

the metacarpals or palm contains 5;

the remaining fourteen are digital bones; fingers and thumb.

The palm has 5 bones known as metacarpal bones, one to each of the 5 digits.

These metacarpals have a head, a shaft, and a base.

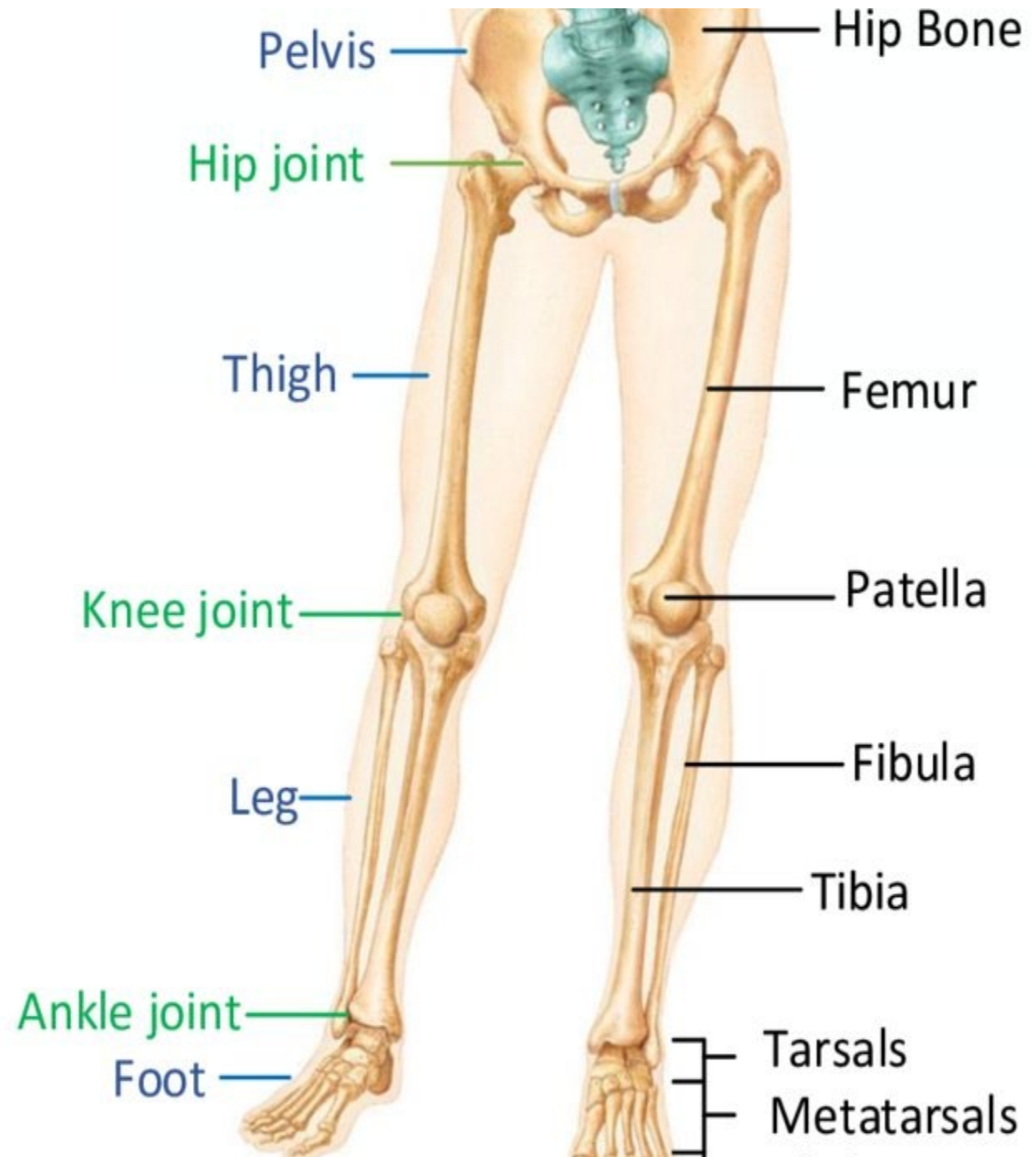


Bones NUMBER of the leg?

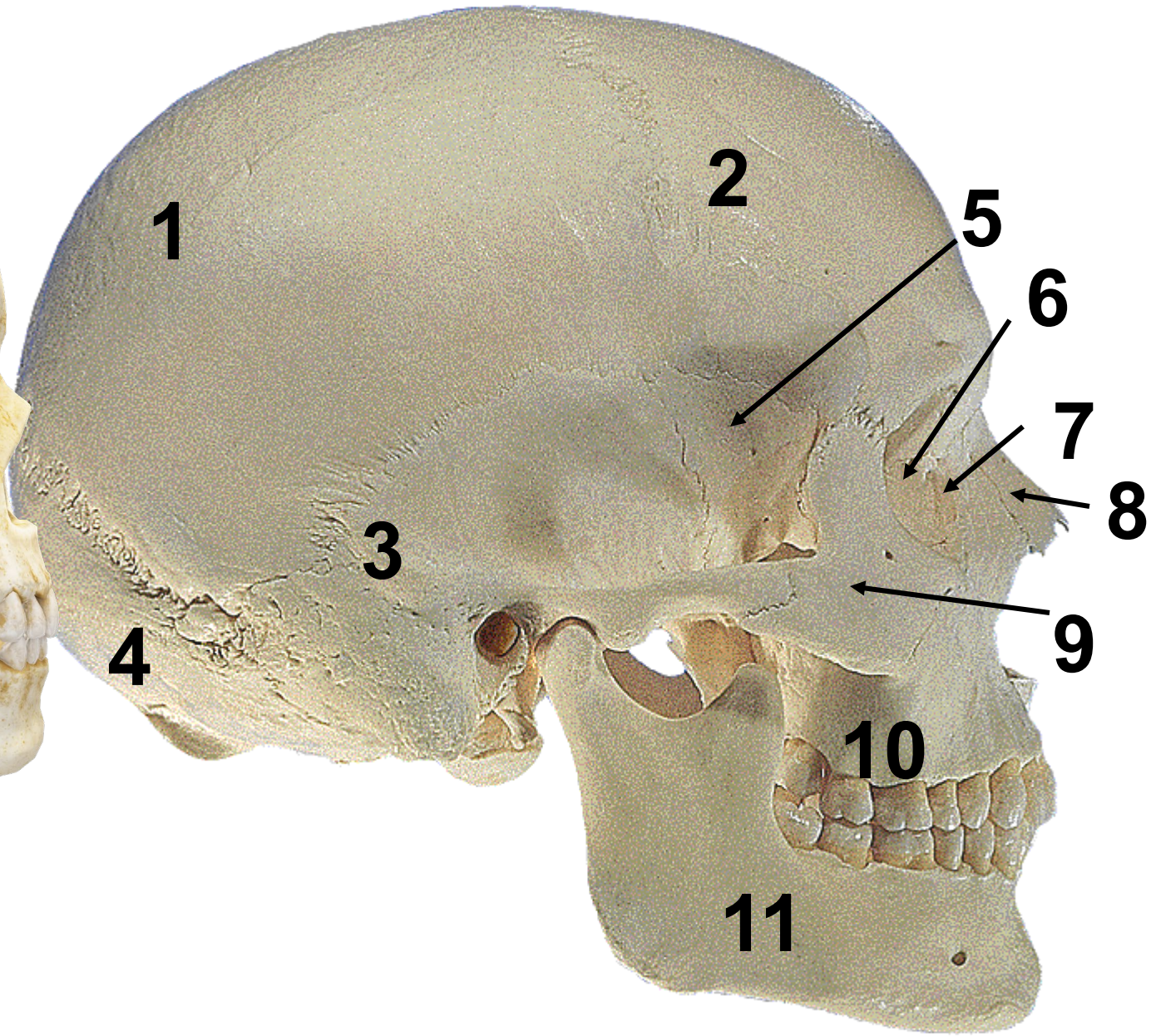
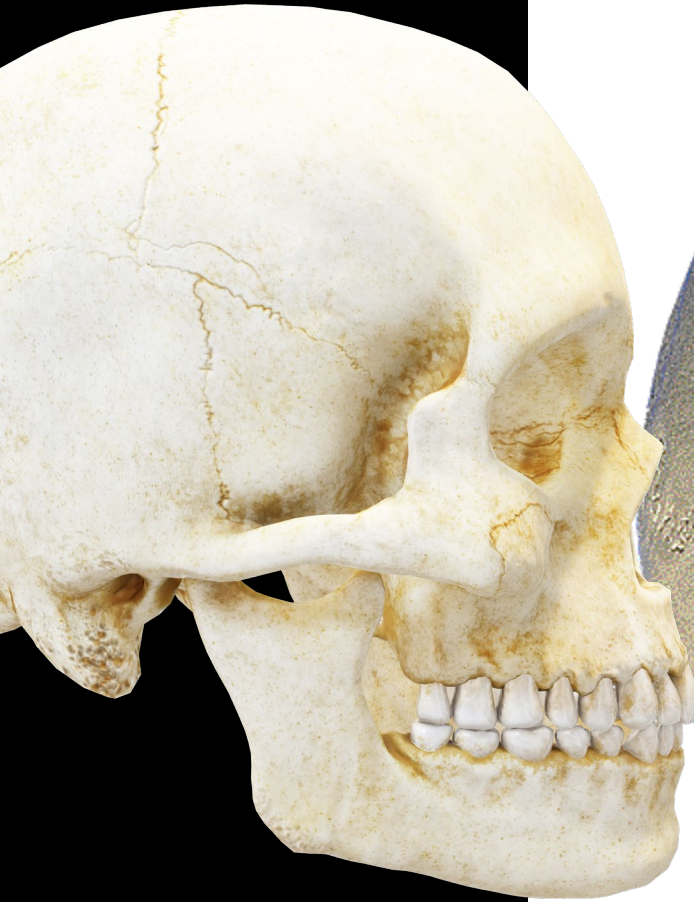There are **62 lower extremity bones**.

They consist of 10 hip and leg, 14 ankle and 38 foot bones.

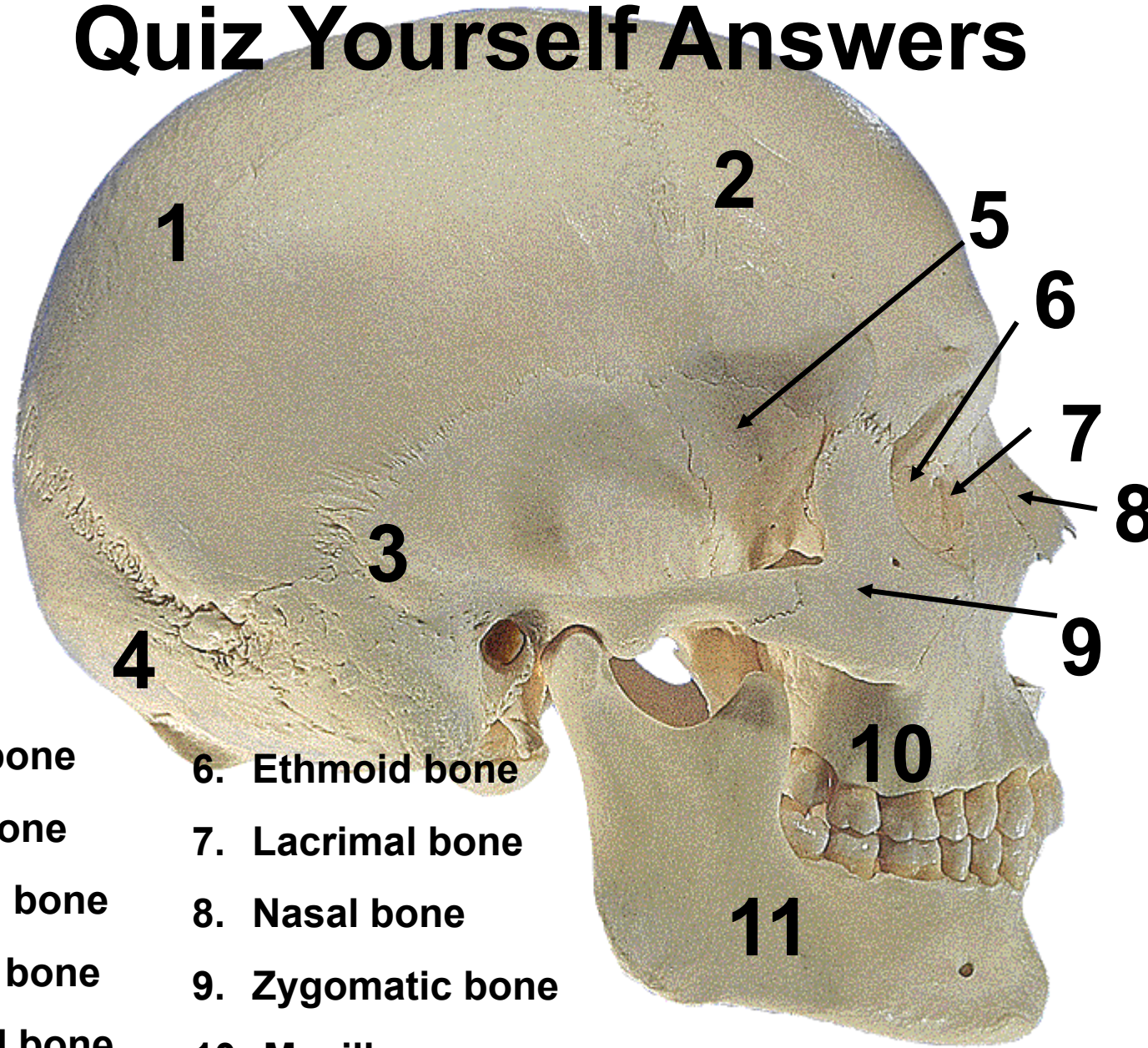
The 10 hip and leg bones are the innominate or hip bone (fusion of the ilium, ischium, and pubis), femur, tibia, fibula, and patella (kneecap) on each side.



The skull



Quiz Yourself Answers



tal bone

tal bone

poral bone

ipital bone

noid bone

6. Ethmoid bone

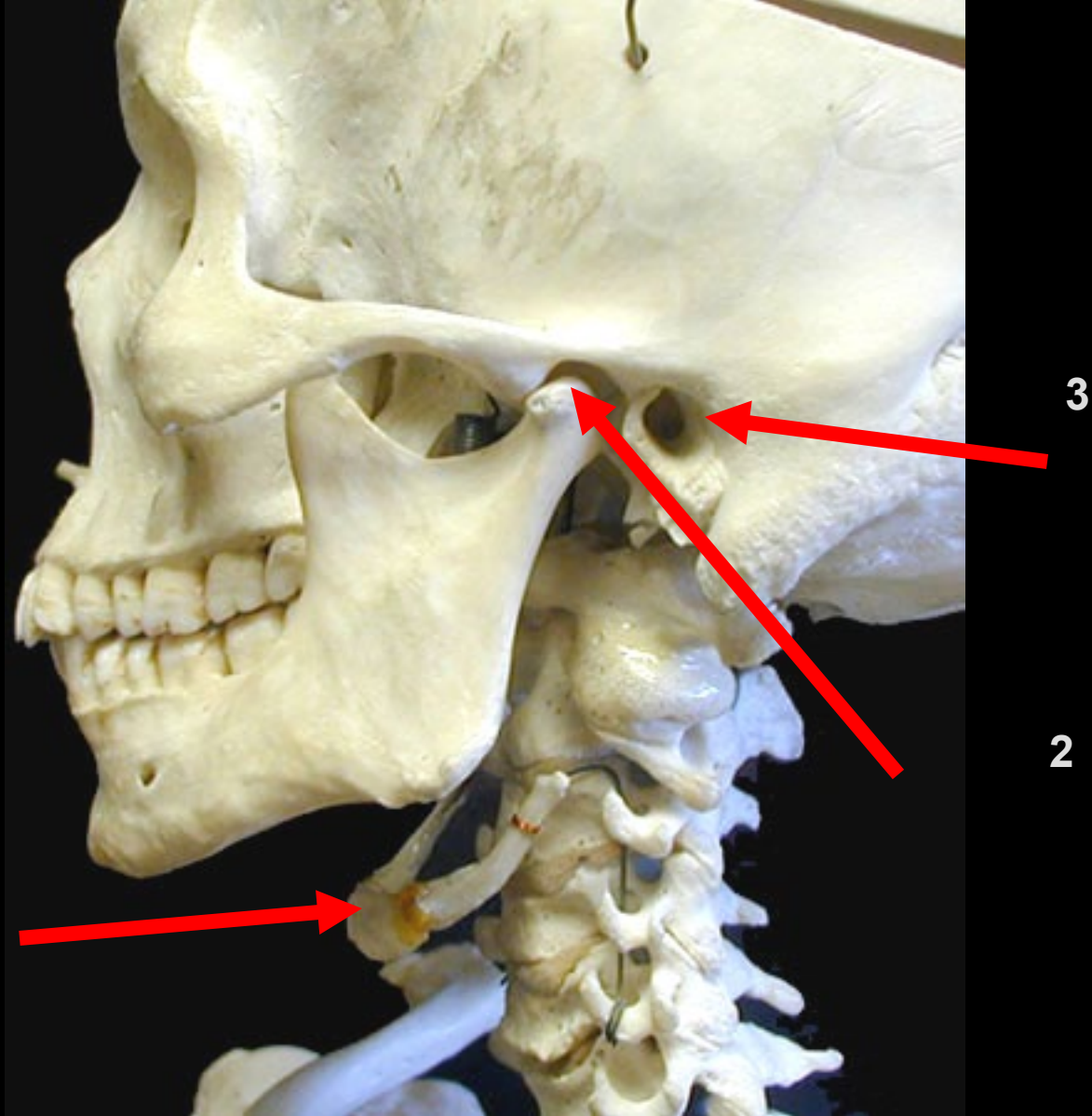
7. Lacrimal bone

8. Nasal bone

9. Zygomatic bone

10. Maxilla

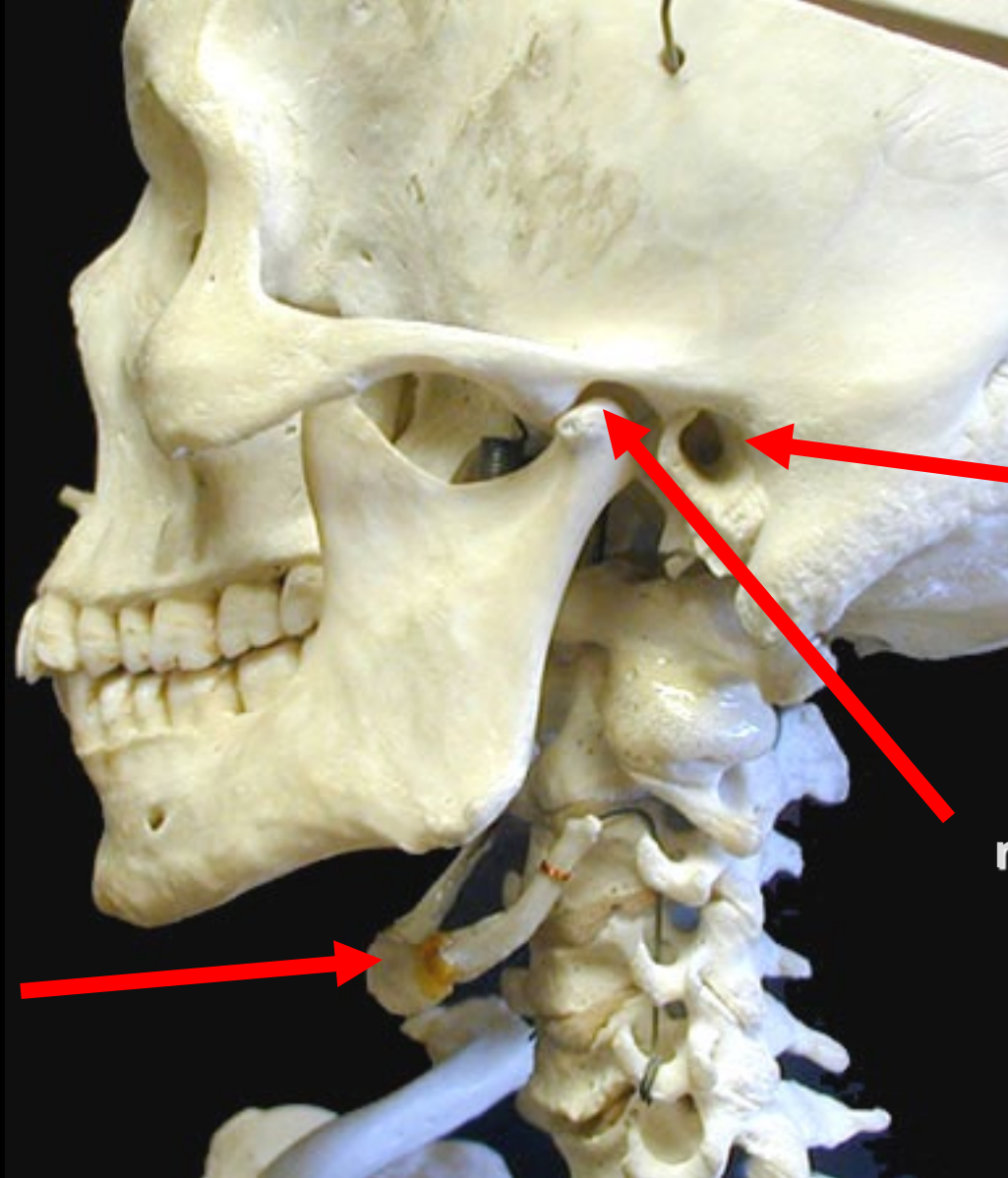
11. Mandible



1

3

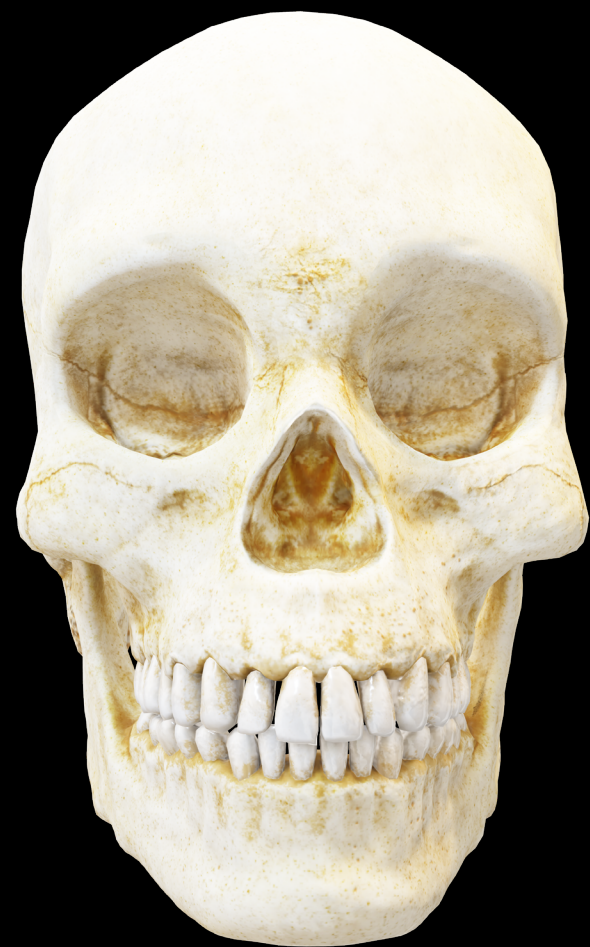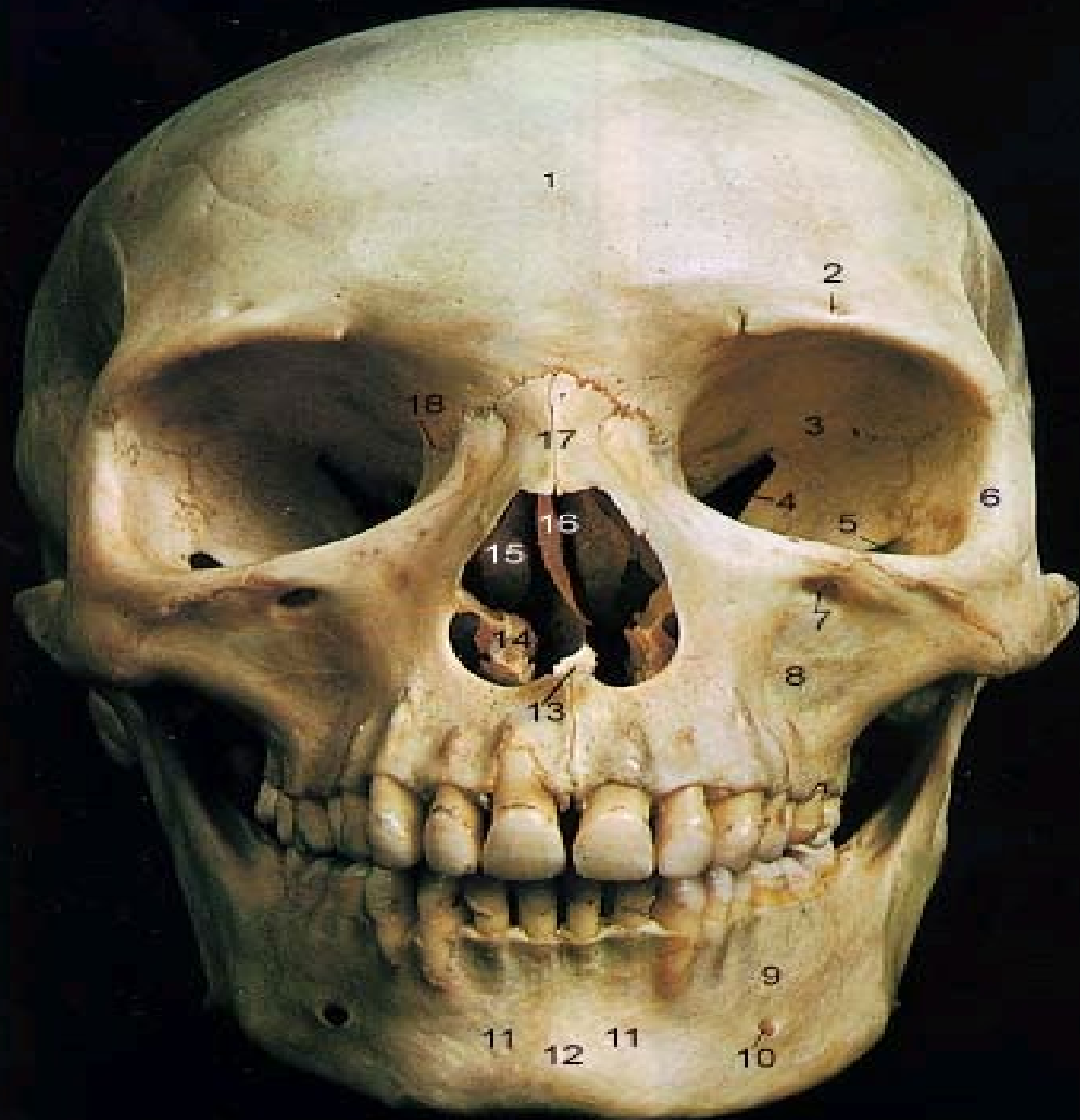2



**external
acoustic
meatus**

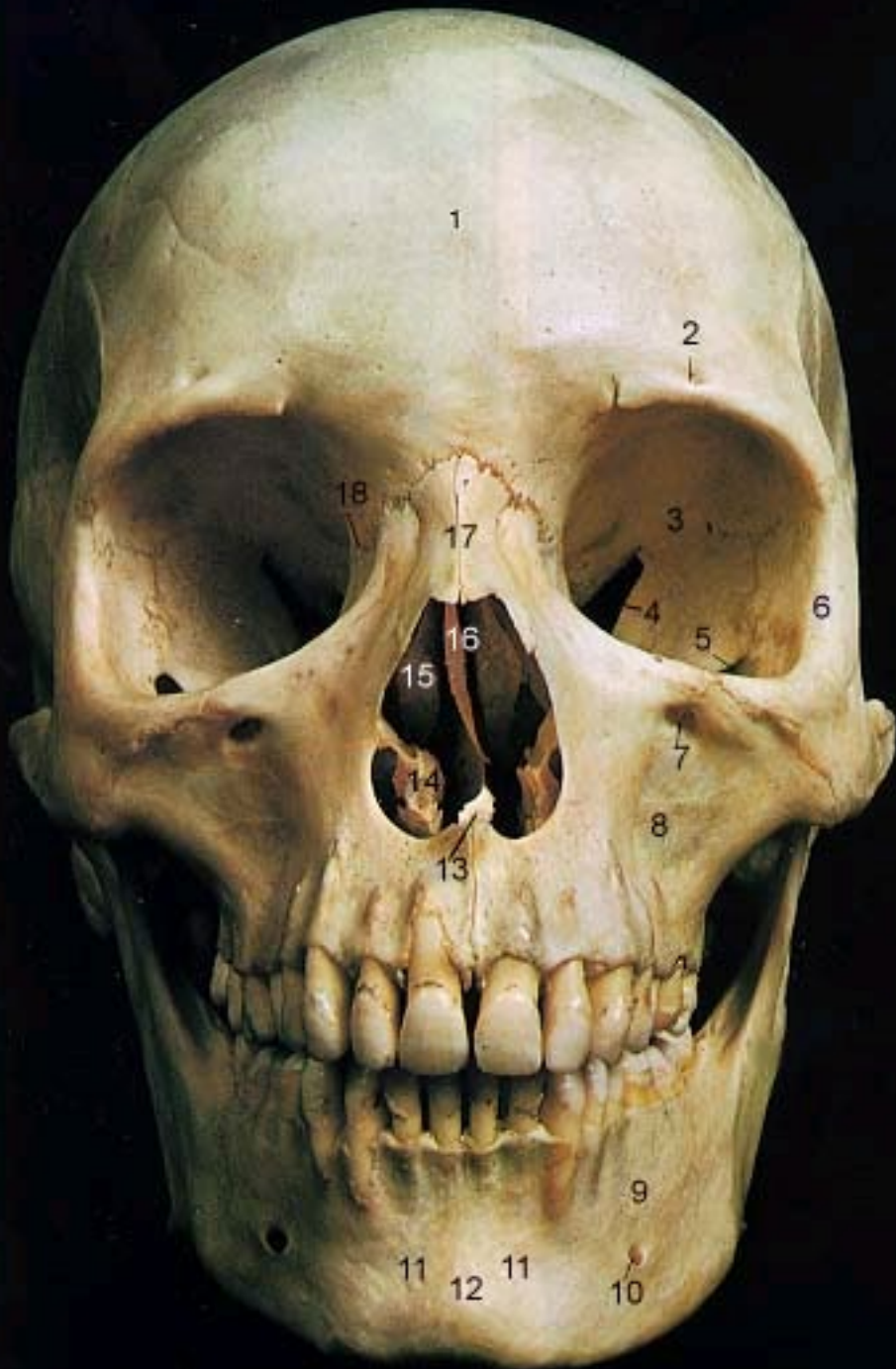**temporal
mandibular
joint**

Hyoid bone

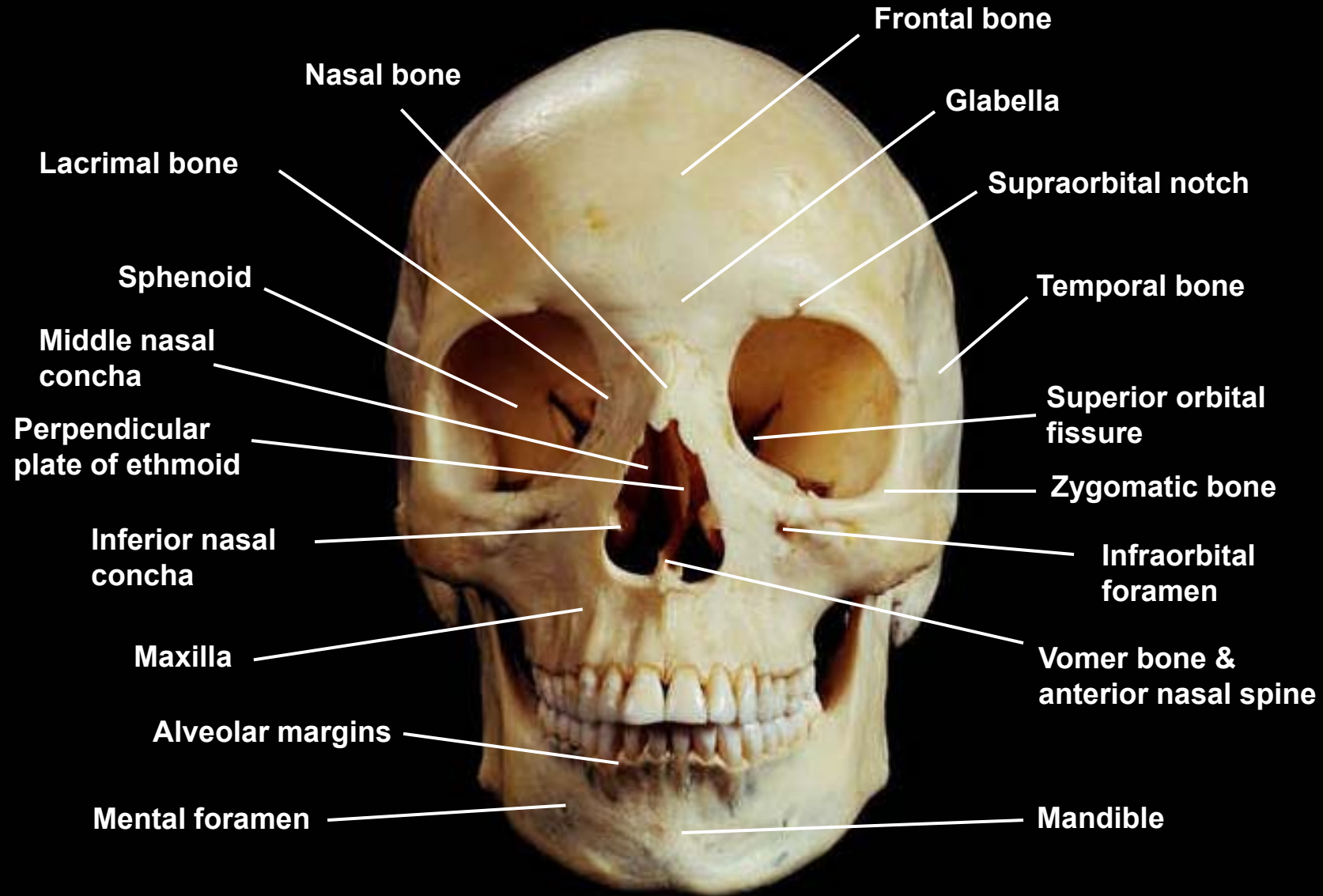


1 Frontal Bone

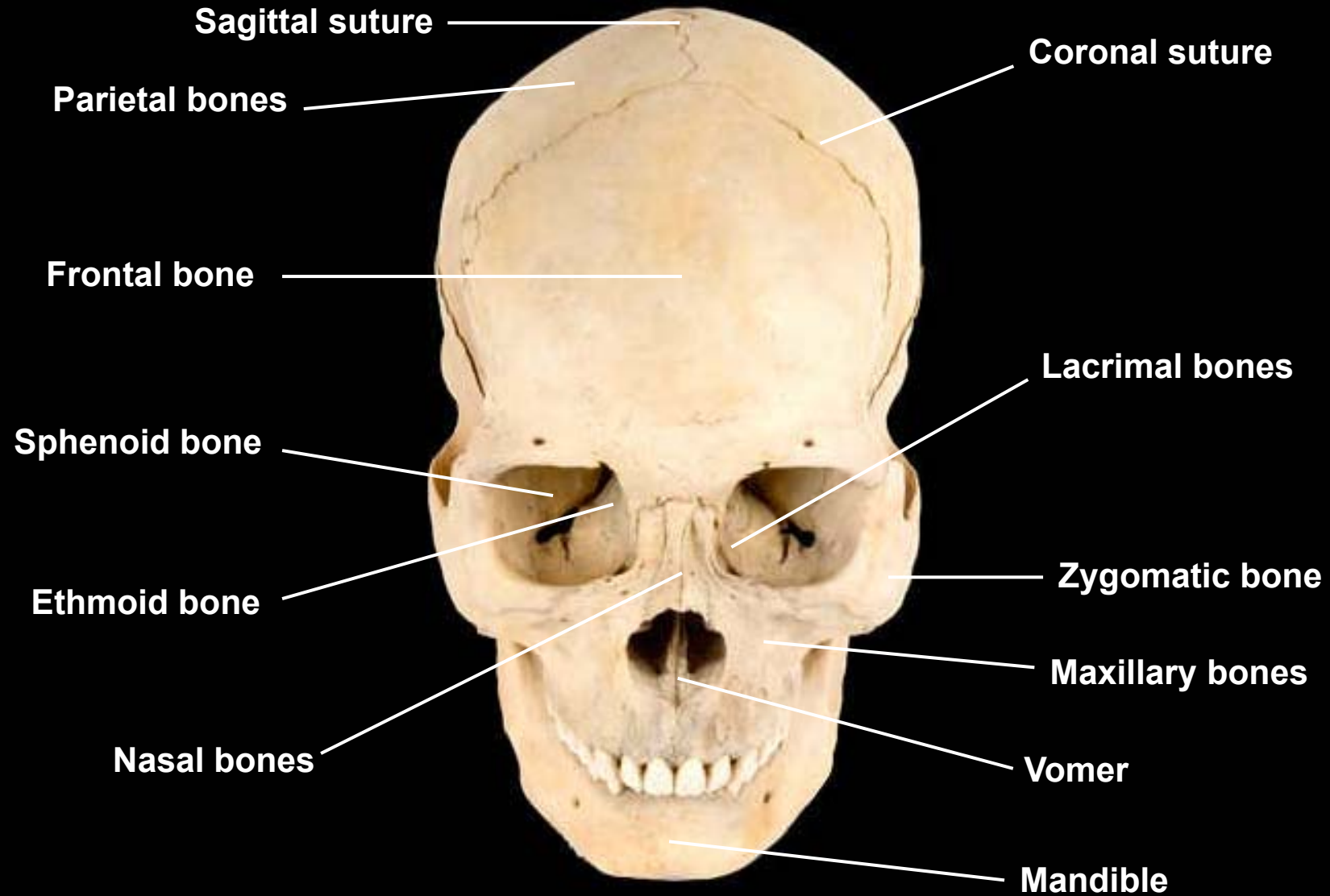
2. Supra-Orbital Foramen
3. Orbit (Orbital Cavity)
4. Superior Orbital Fissure
5. Inferior Orbital Fissure
6. Zygomatic Bone
7. Infra-Orbital Foramen
8. Maxilla
9. Mandible
10. Mental Foramen
11. Incisive Fossa
12. Symphysis
13. Vomer
14. Inferior Nasal Concha
15. Middle Nasal Concha
16. Perpendicular Plate of Ethmoid
17. Nasal Bone
18. Lacrimal Bone



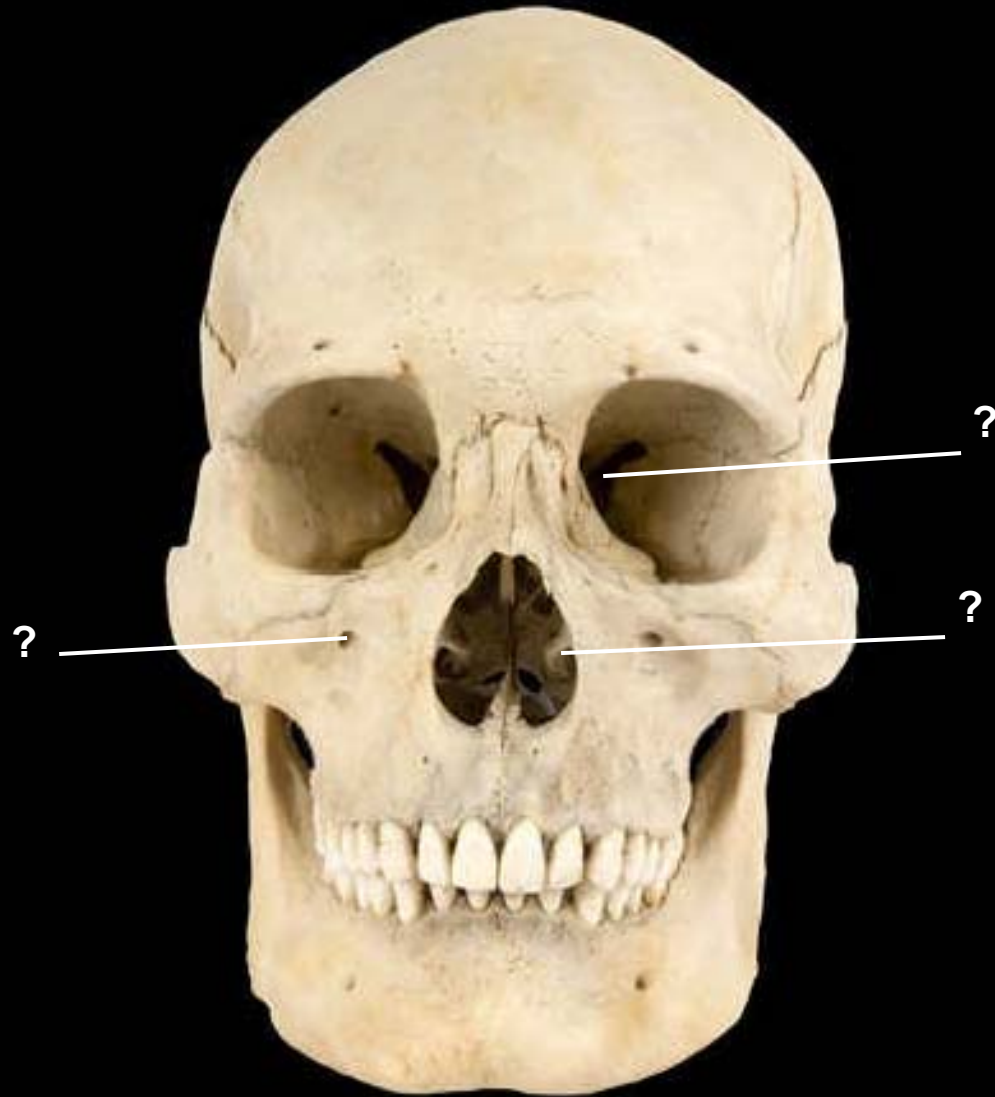
Skull, anterior view



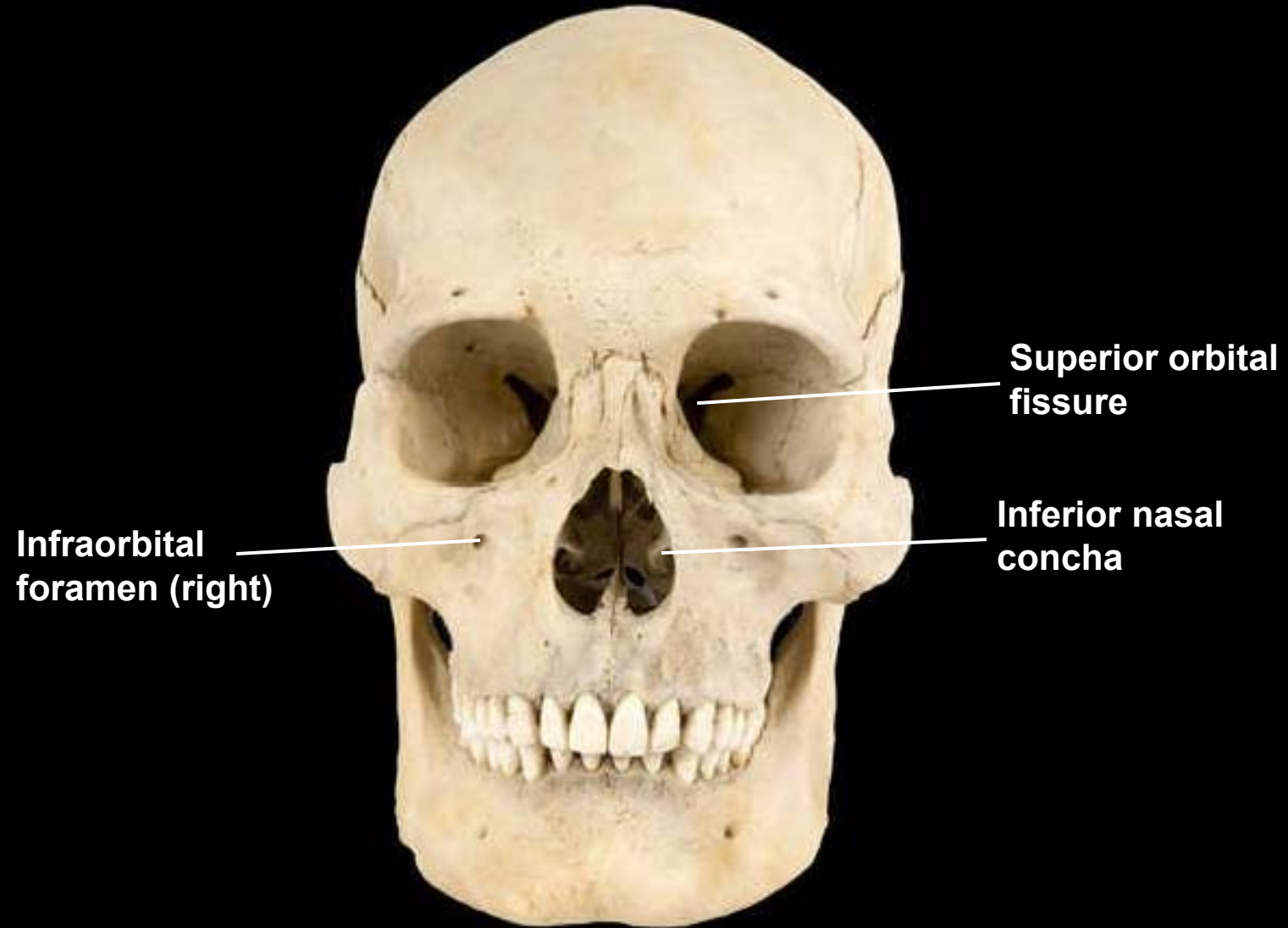
Skull, superioanterior view



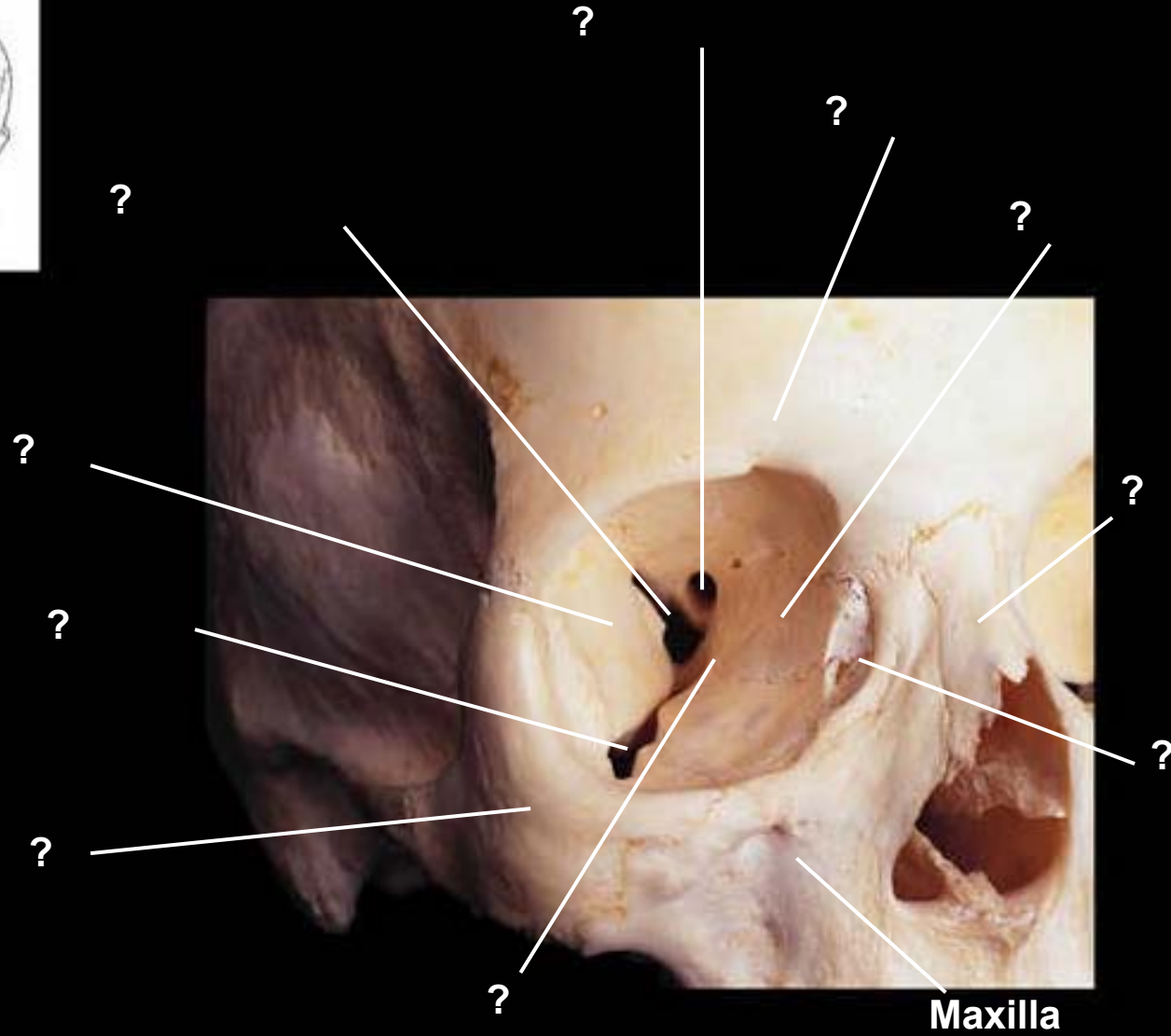
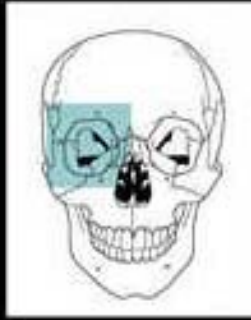
Skull, anterior view



Skull, anterior view

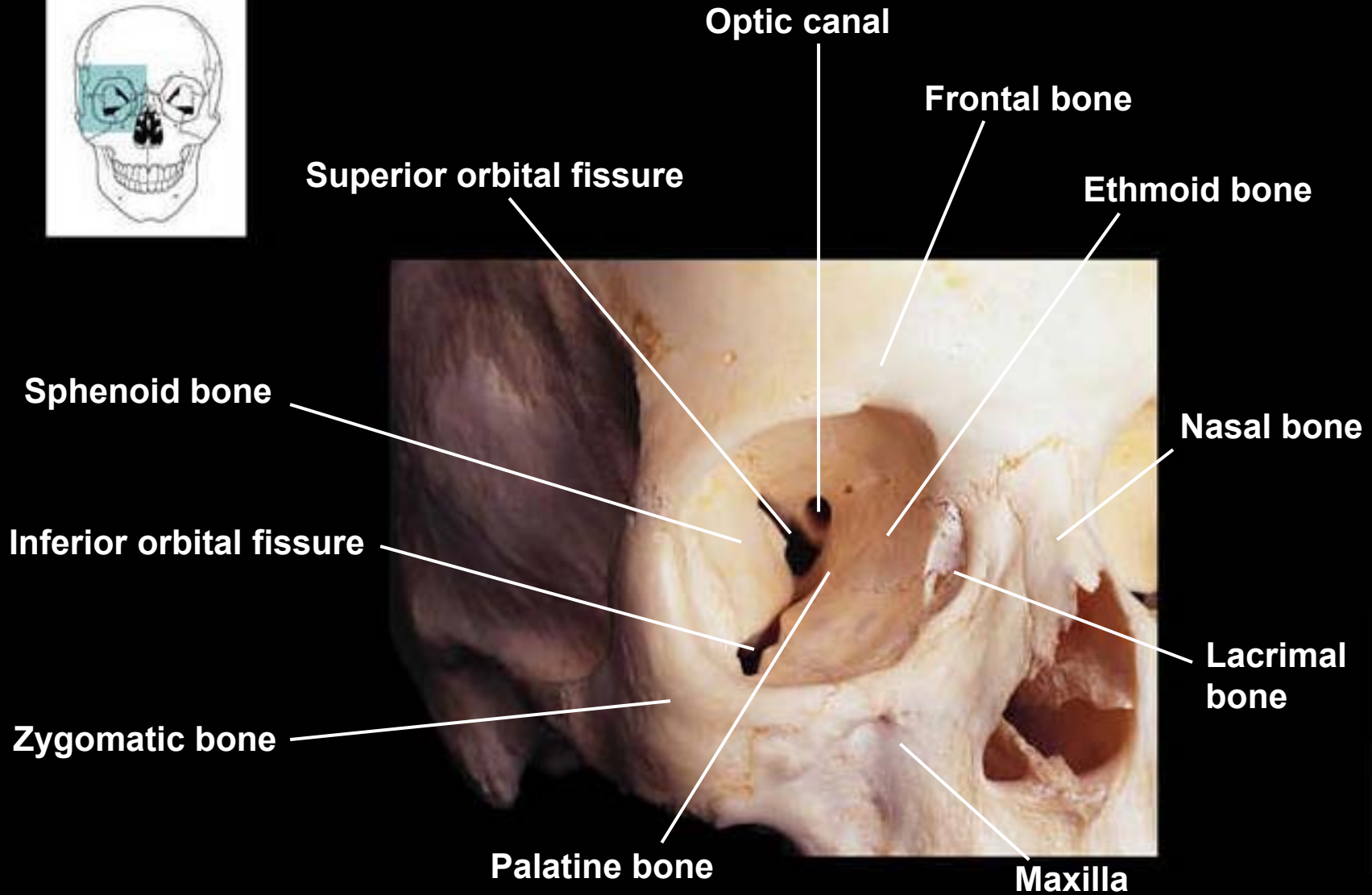
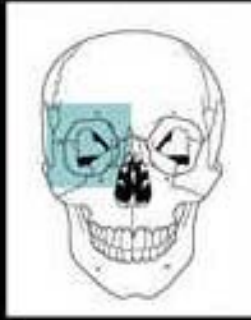


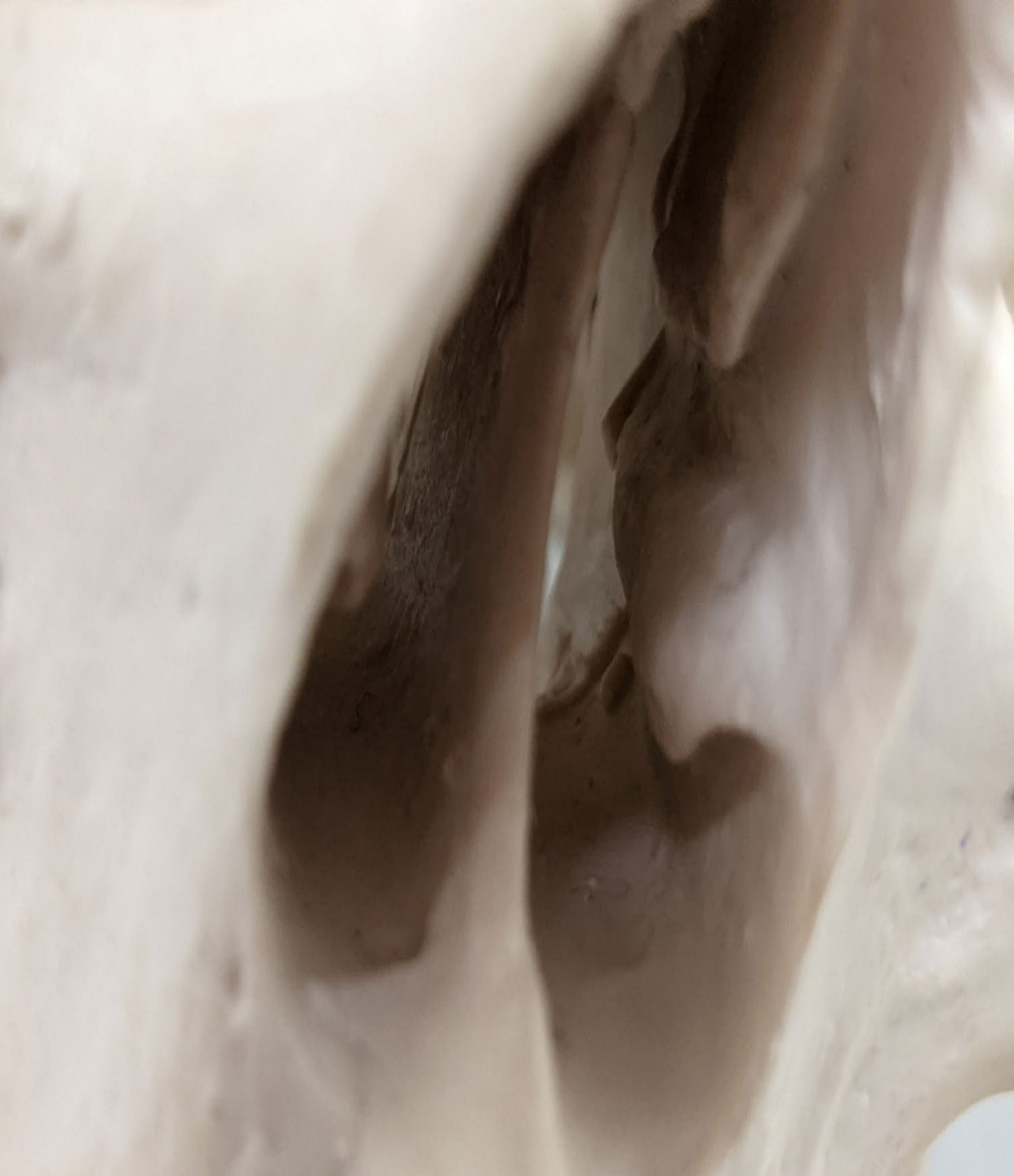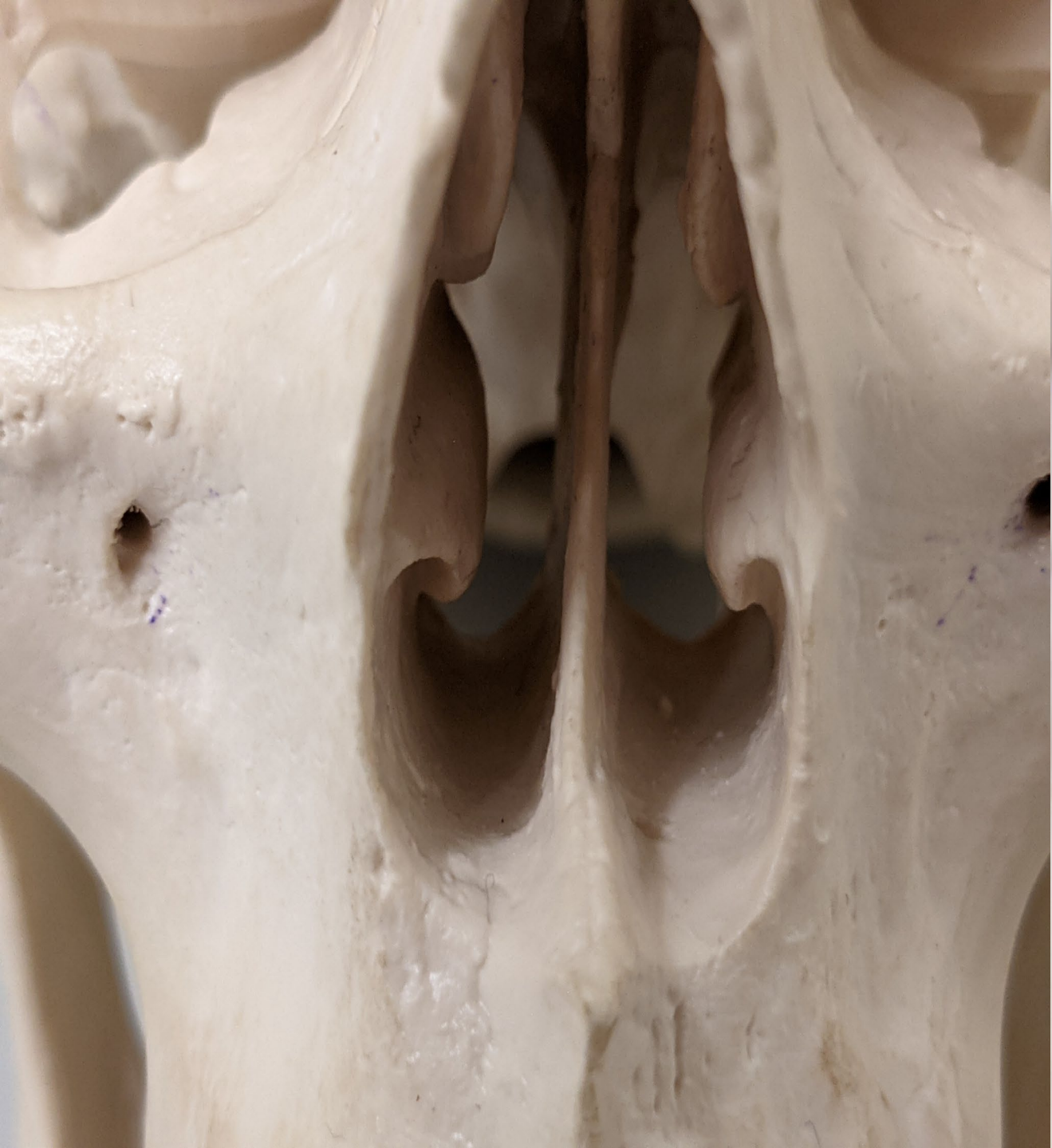Bones of the orbit

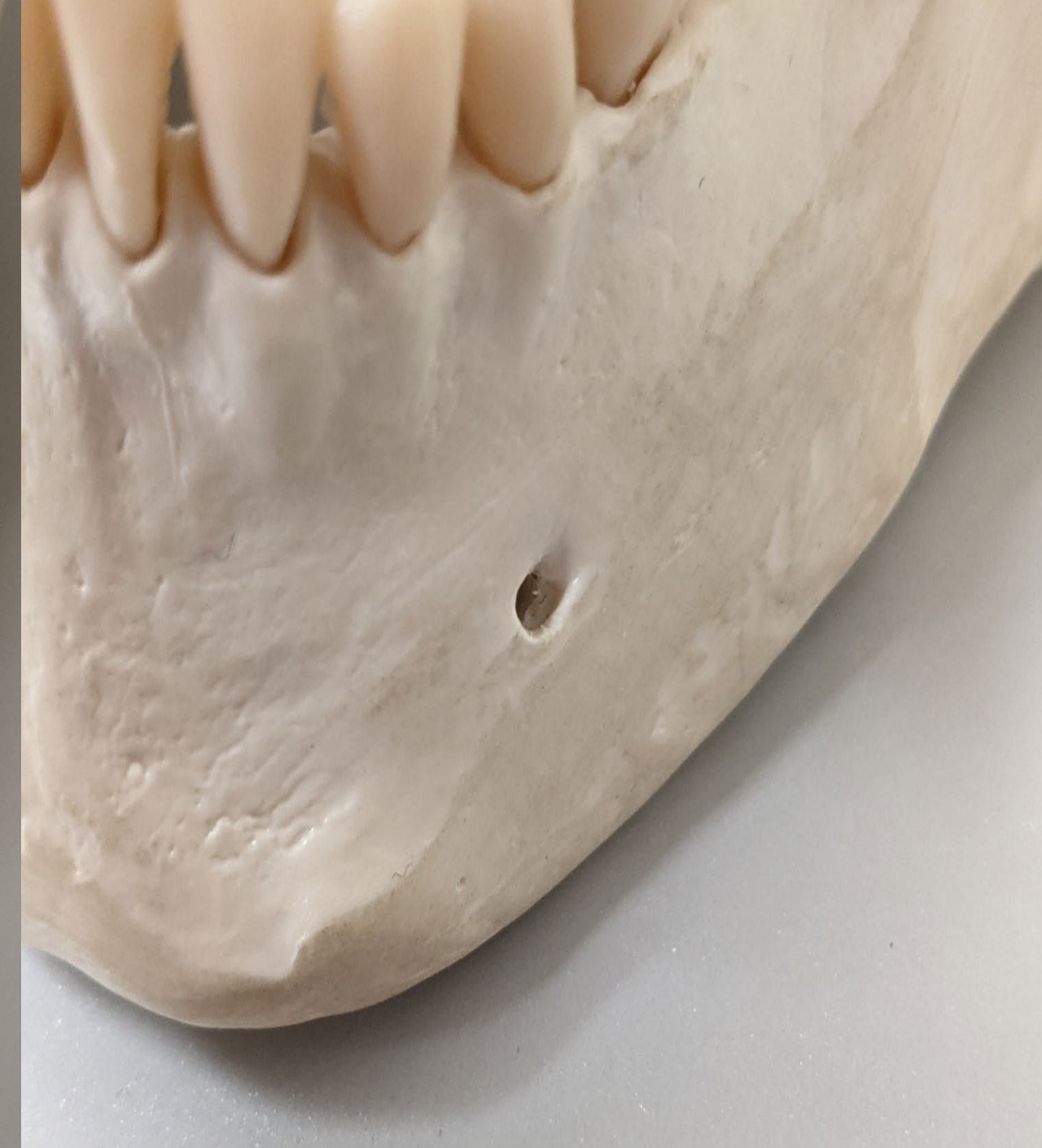
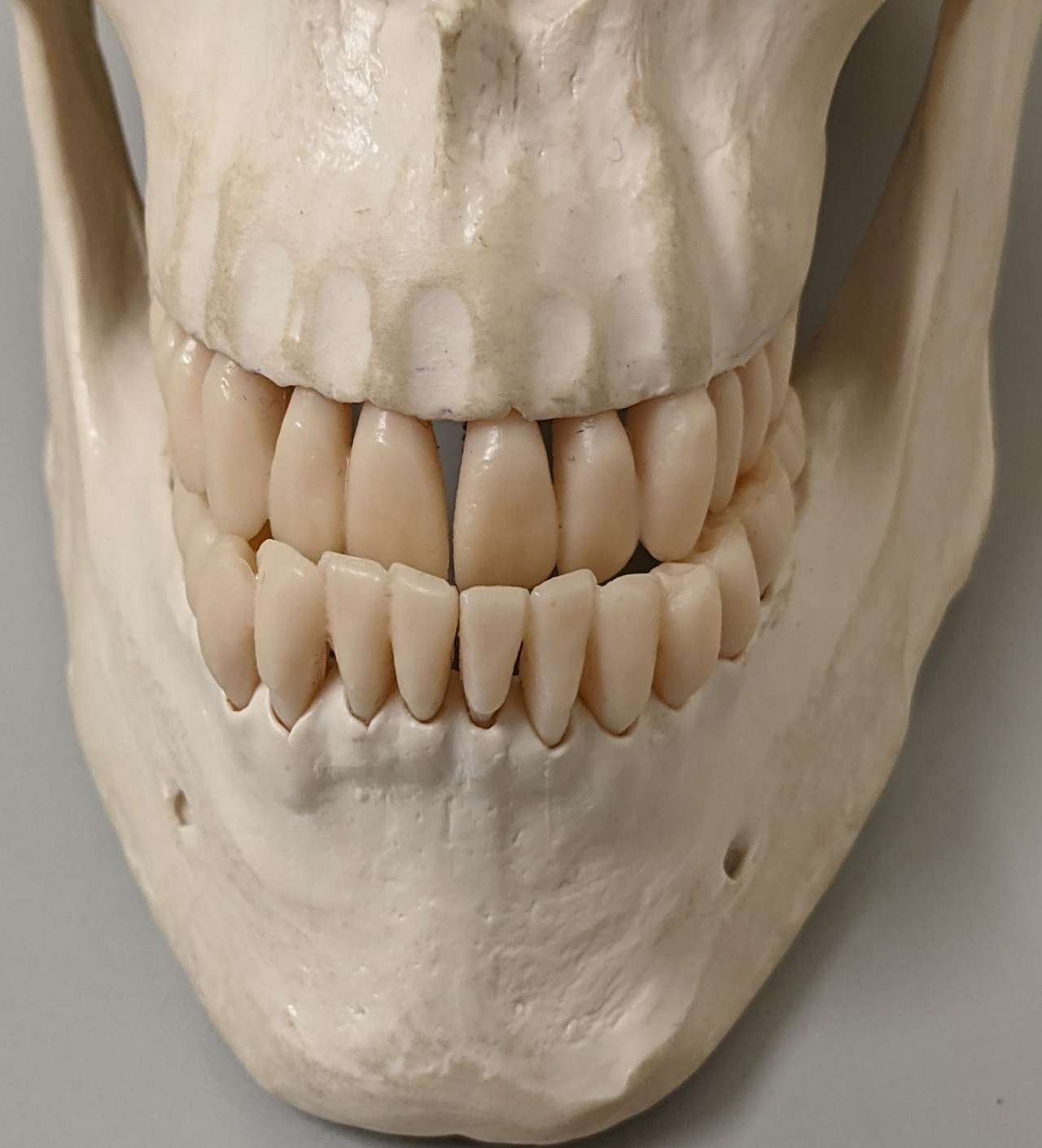
Maxilla

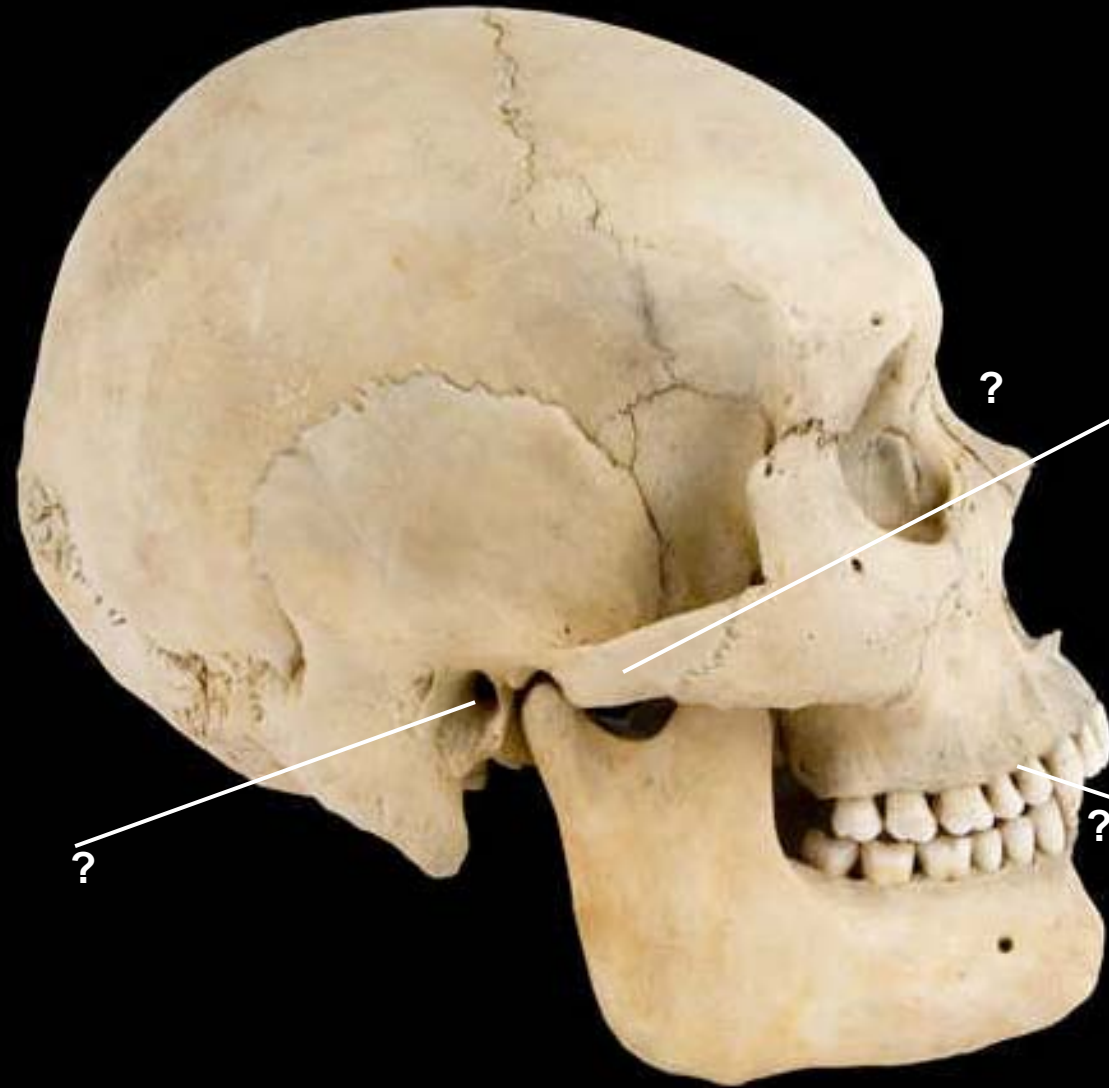
Bones of the orbit



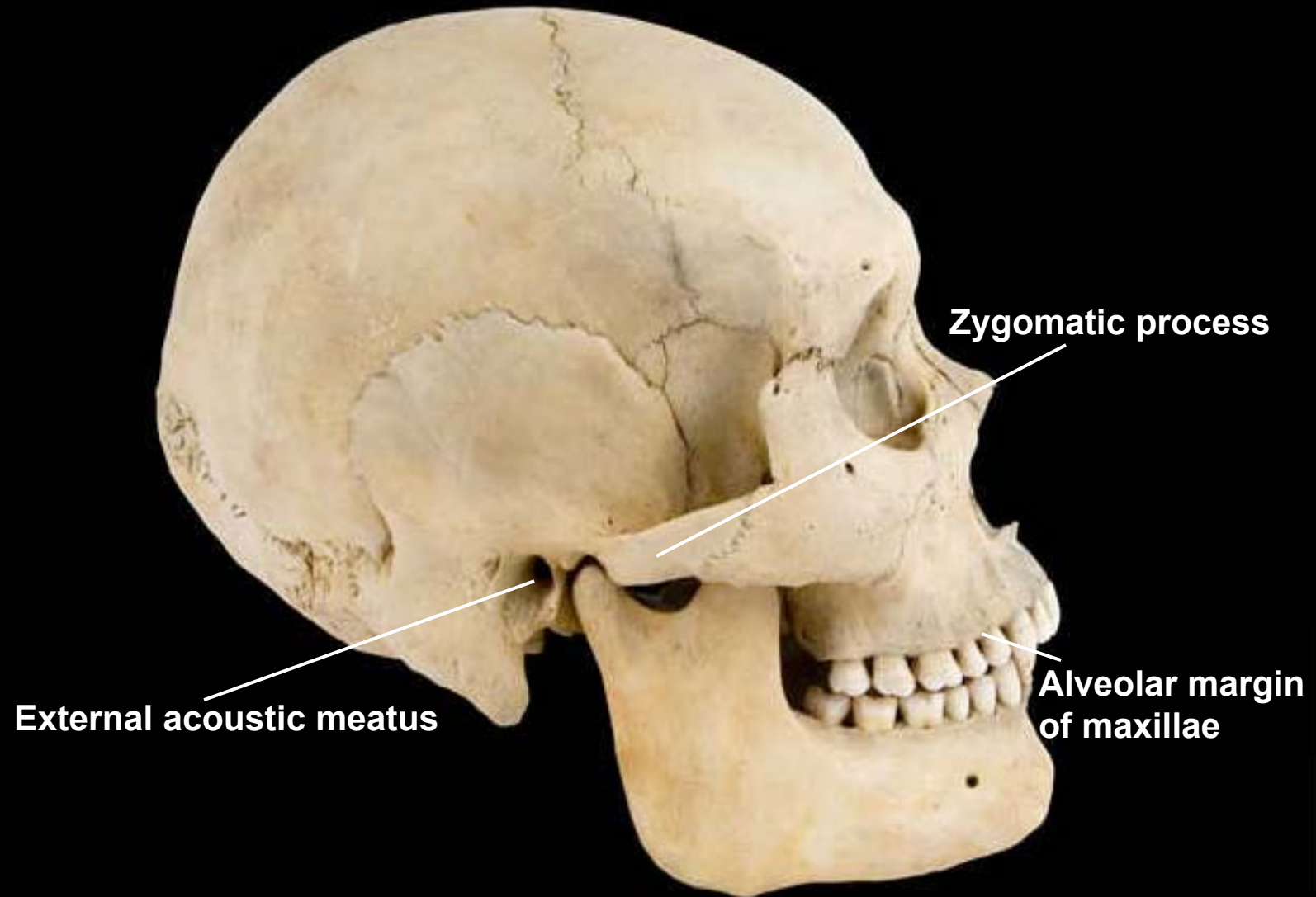




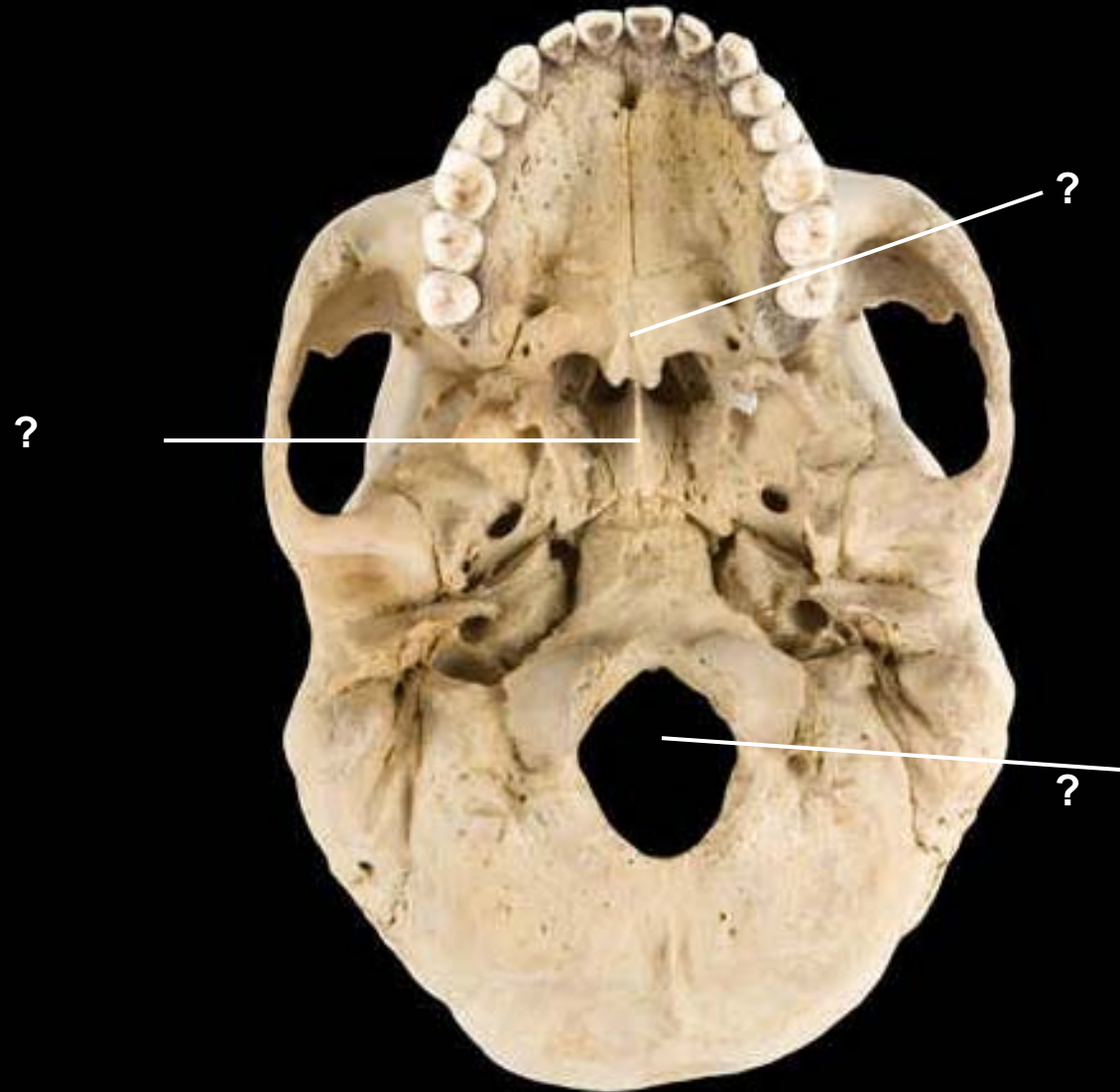
Skull, lateral view, right side



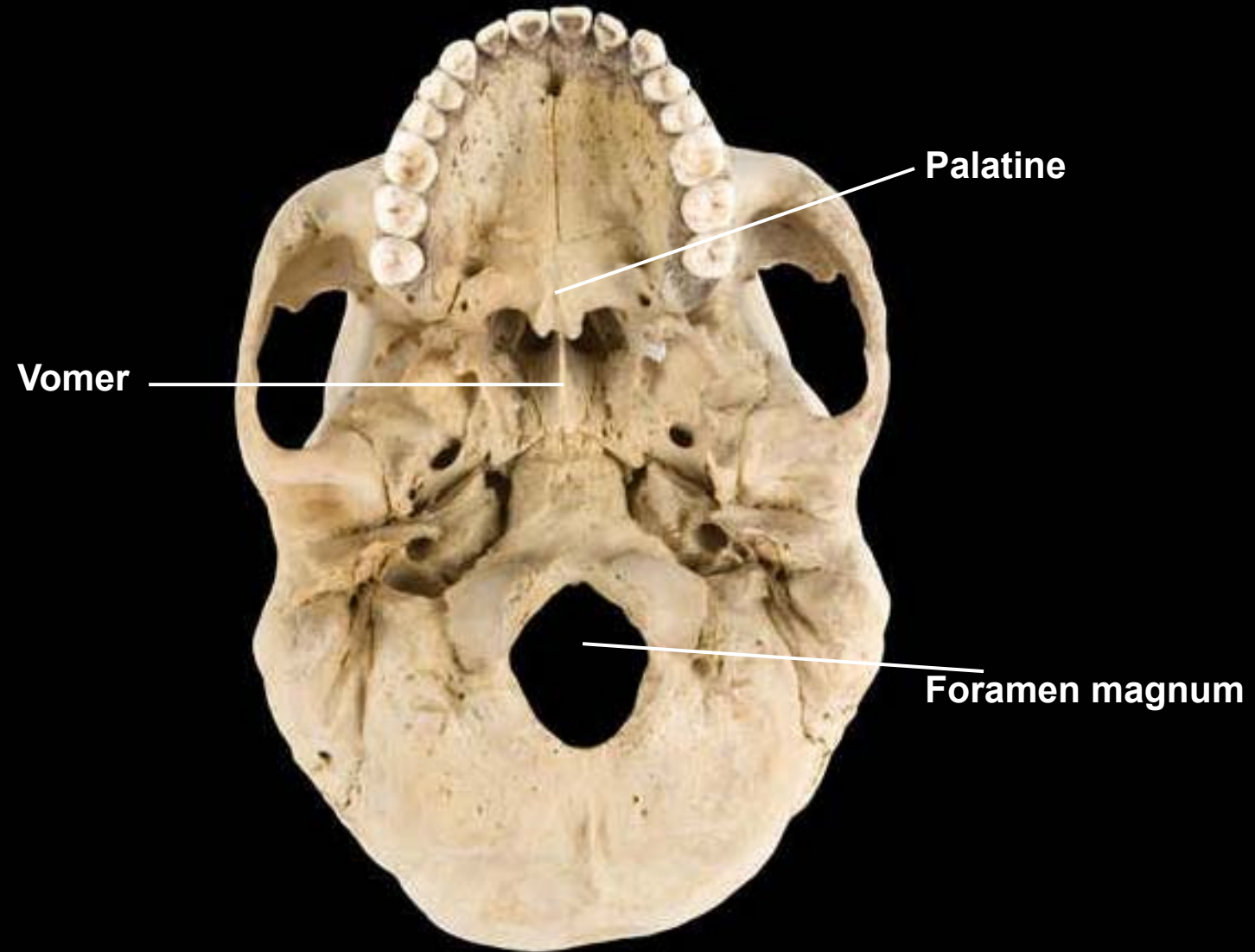
Skull, lateral view, right side

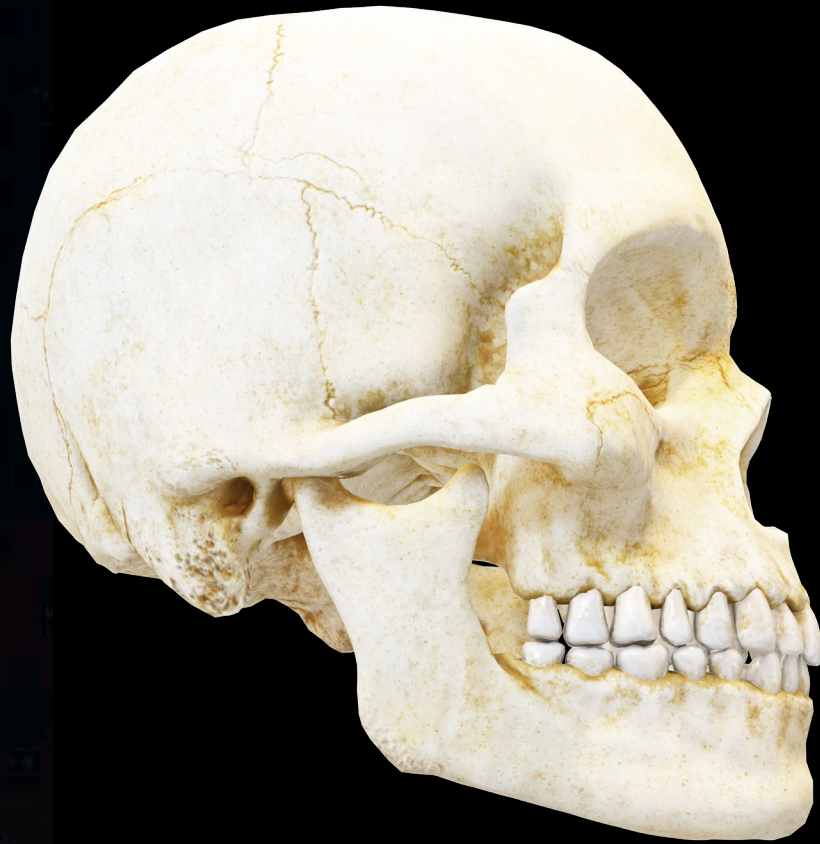
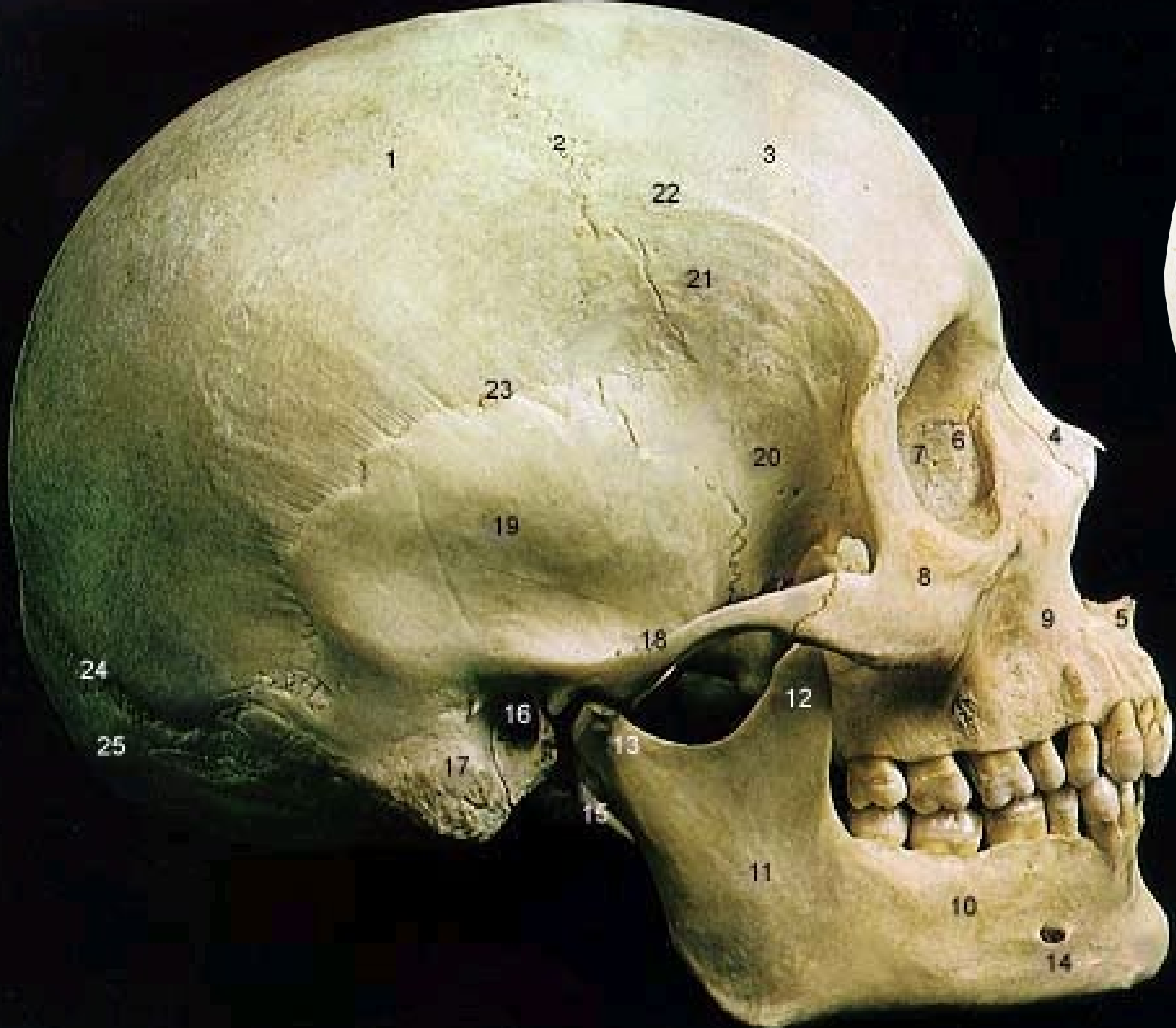
Skull, inferior view



Skull, inferior view





1 Parietal Bone

2. Coronal Suture

3. Frontal Bone

4. Nasal Bone

5. Vomer

6. Lacrimal Bone

7. Orbital Part of Ethmoid

8. Zygomatic Bone

9. Maxilla

10. Body of Mandible

11. Ramus of Mandible

12. Coronoid Process

13. Mandibular Condyle

14. Mental Foramen

15. Styloid Process

16. External Acoustic Meatus

17. Mastoid Process

18

Zygomatic Process

19

Temporal Bone

20

Greater Wing of Sphenoid

21

Inferior Temporal Line

22

Superior Temporal Line

23

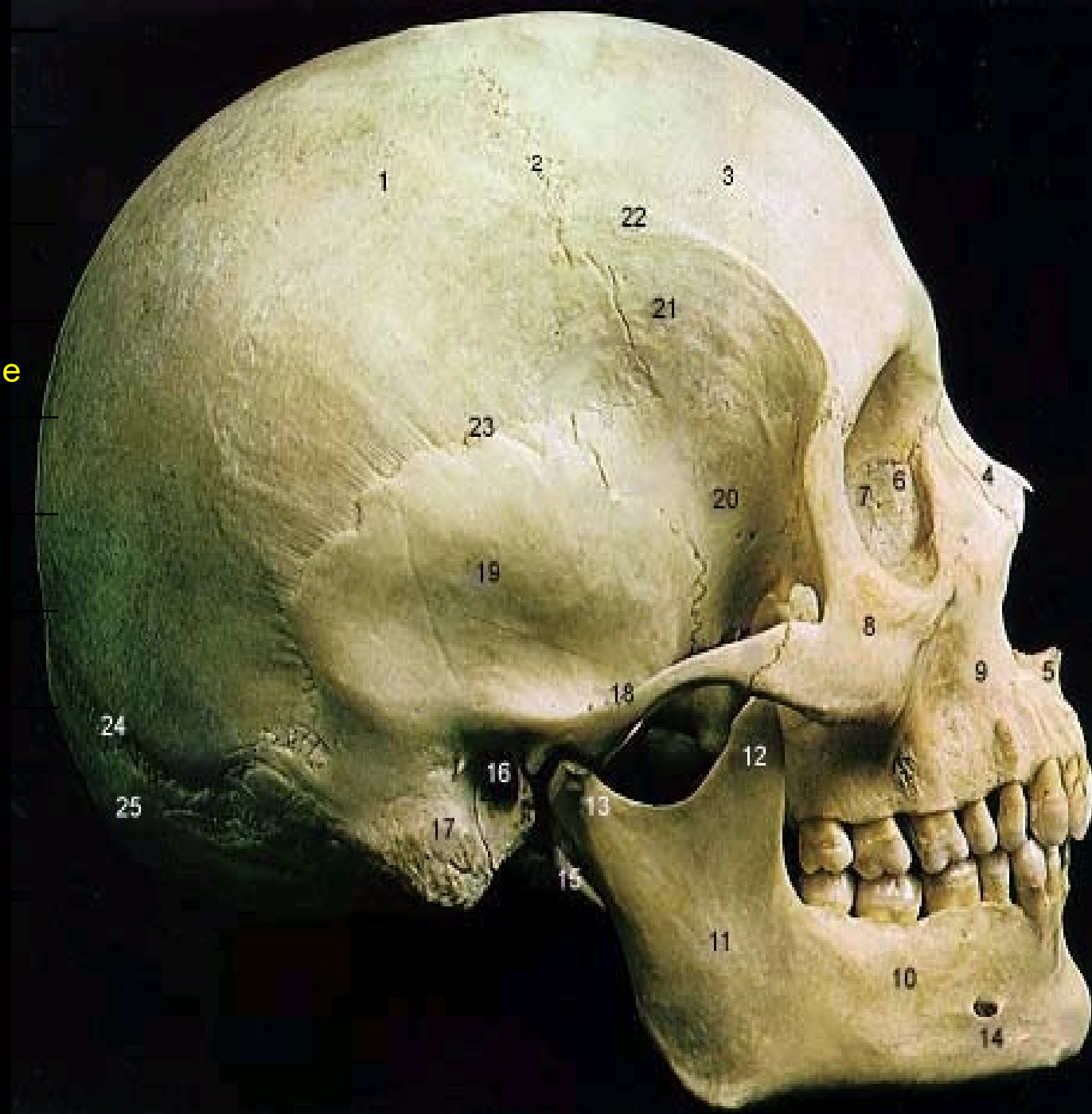Squamosal Suture

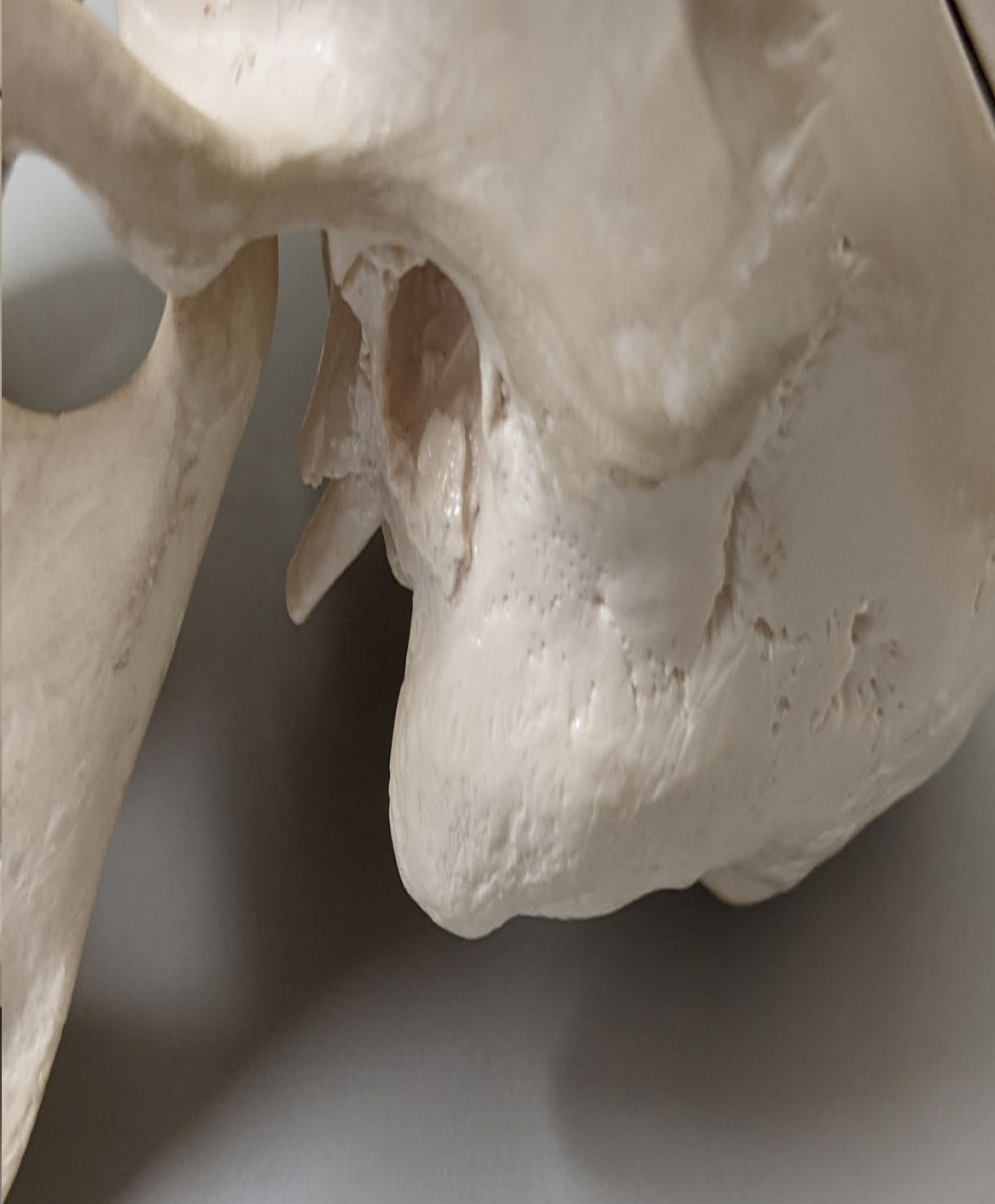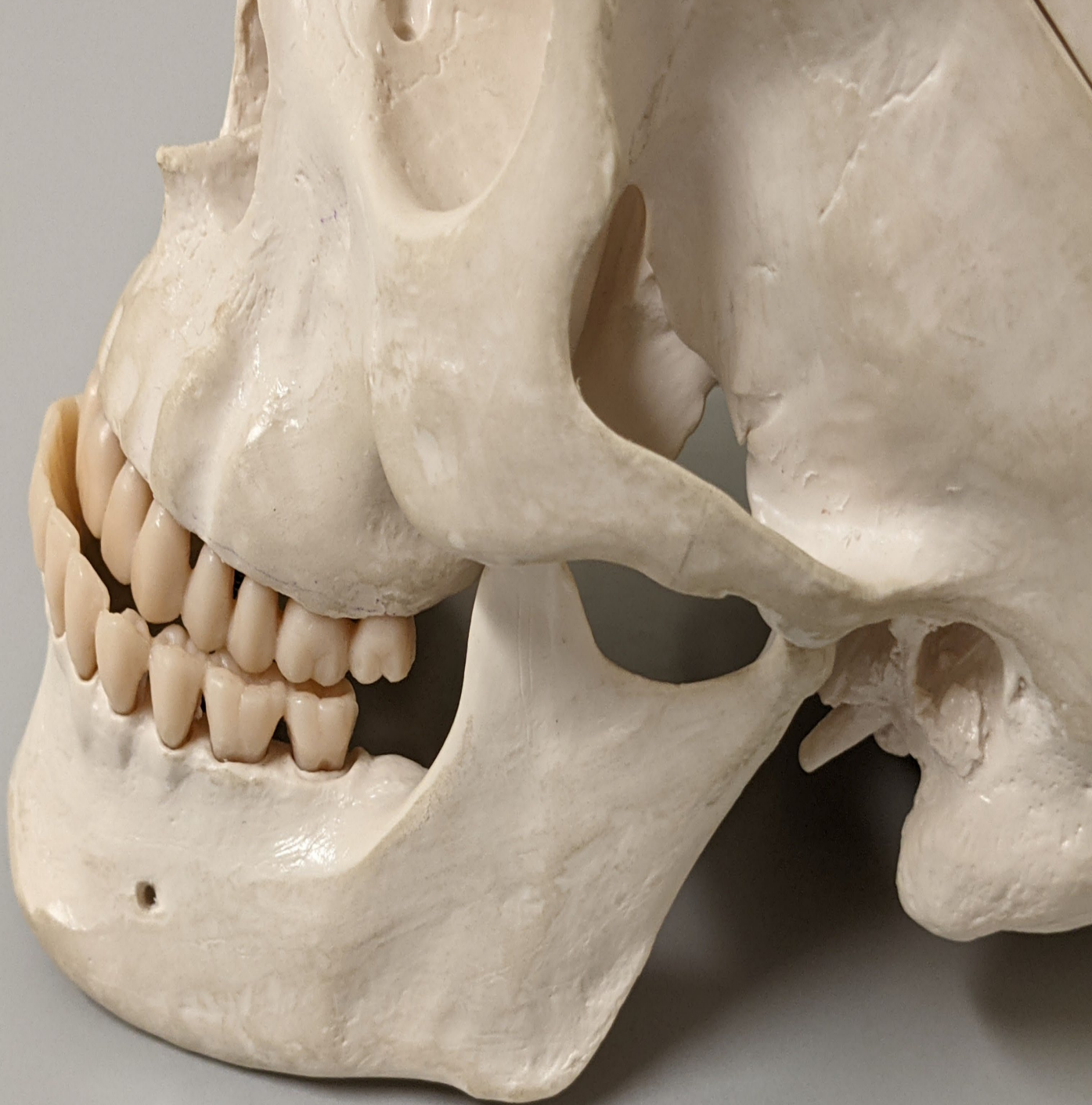24

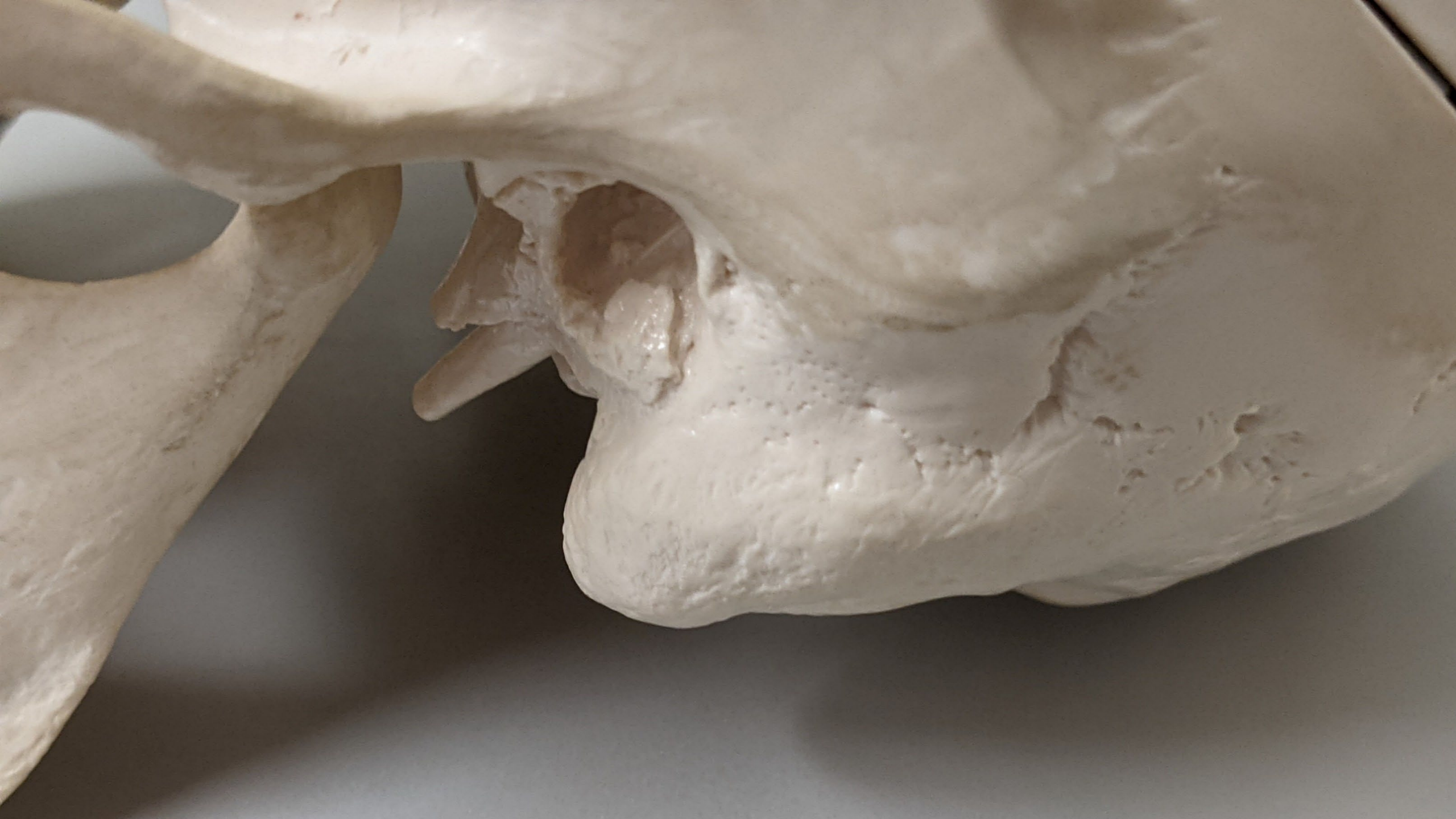Lambdoidal Suture

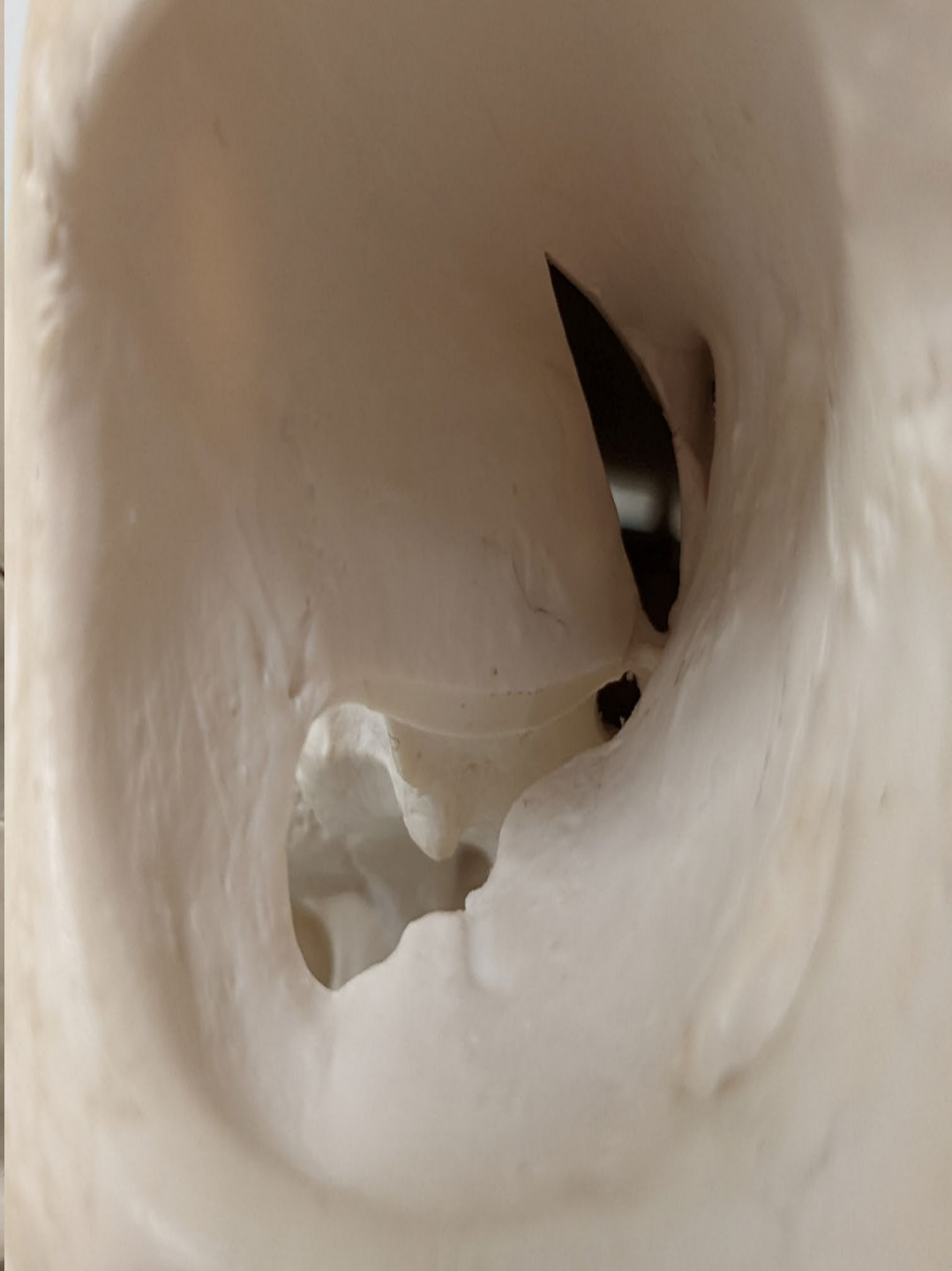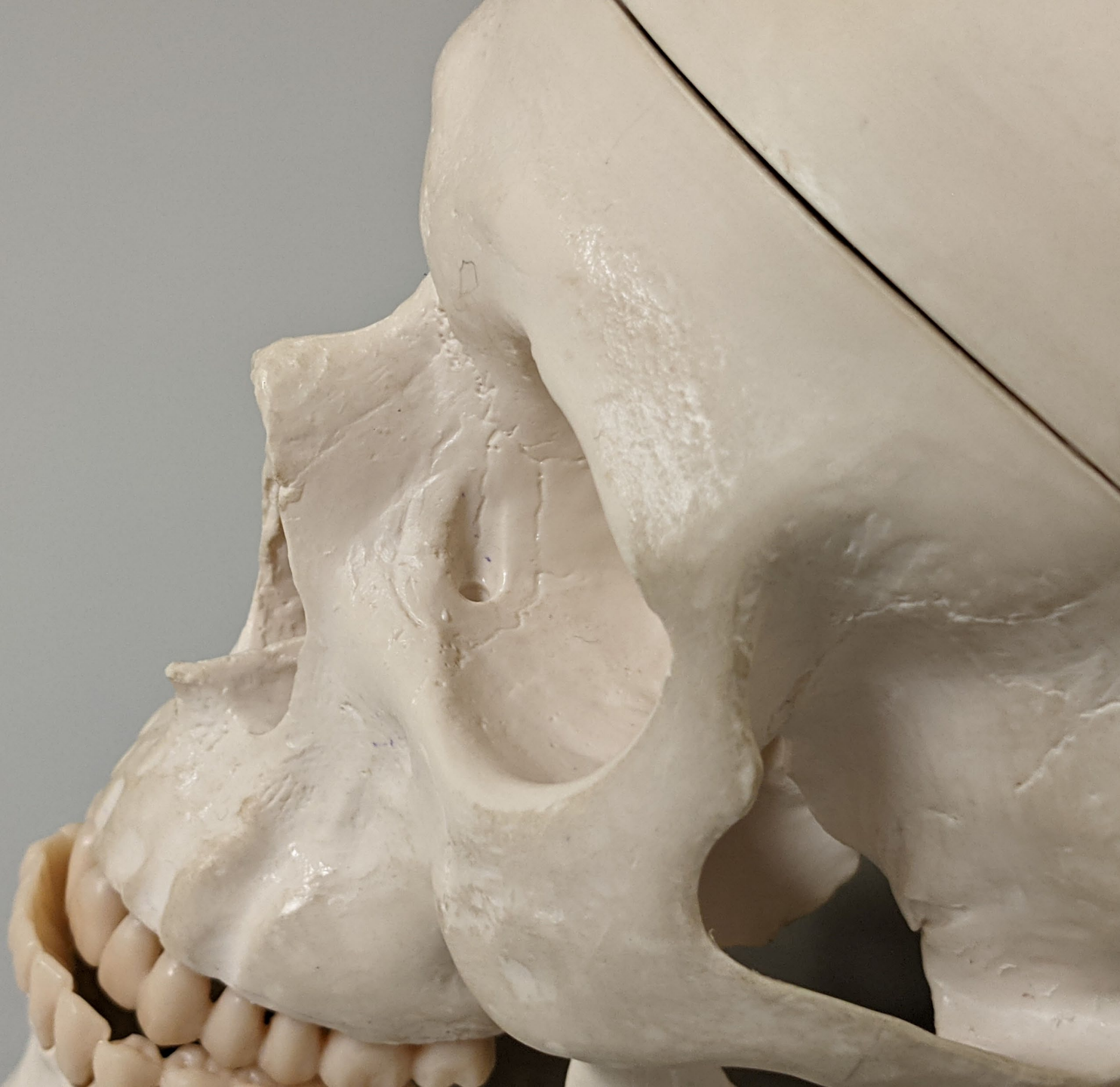25

Occipital Bone

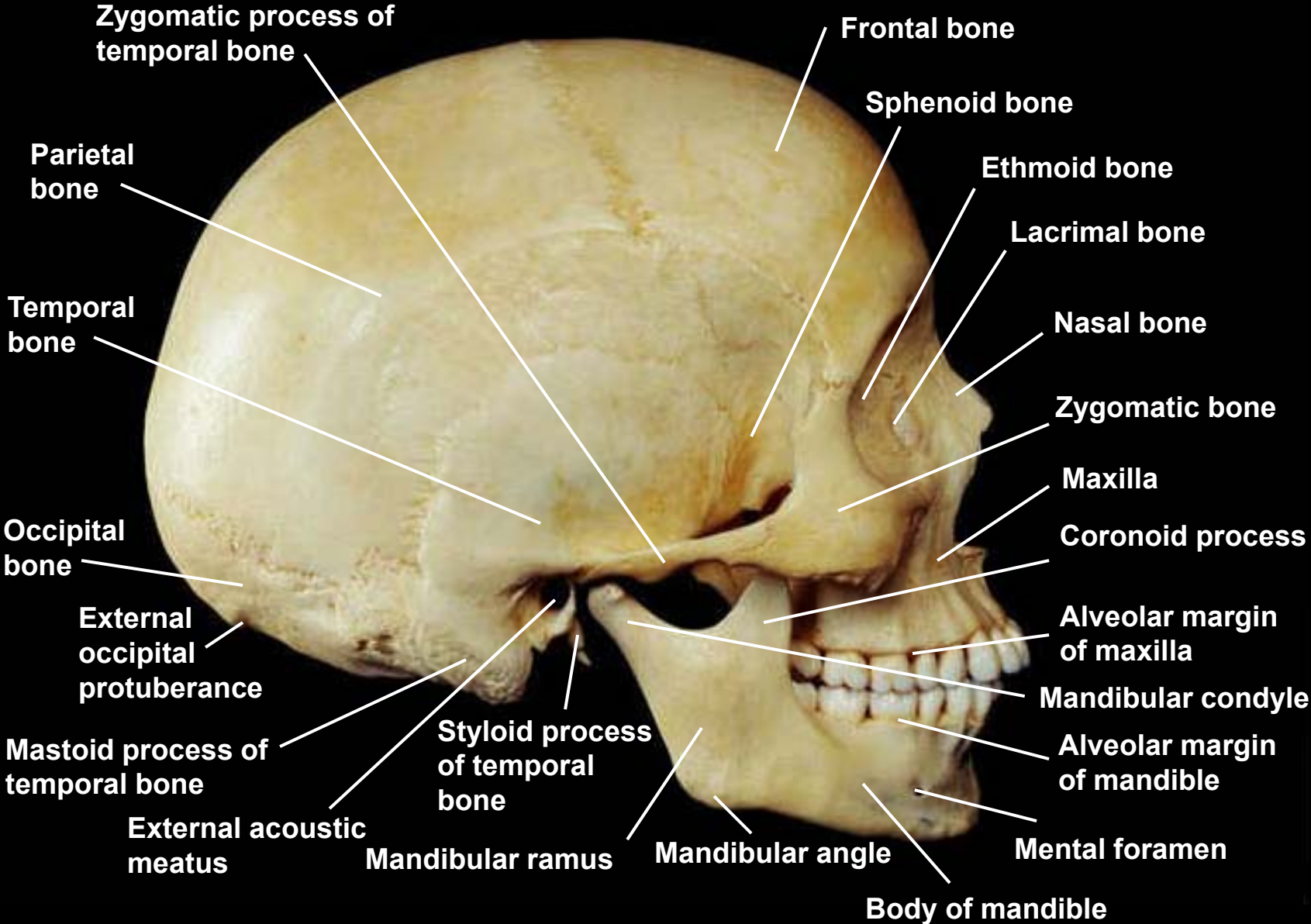


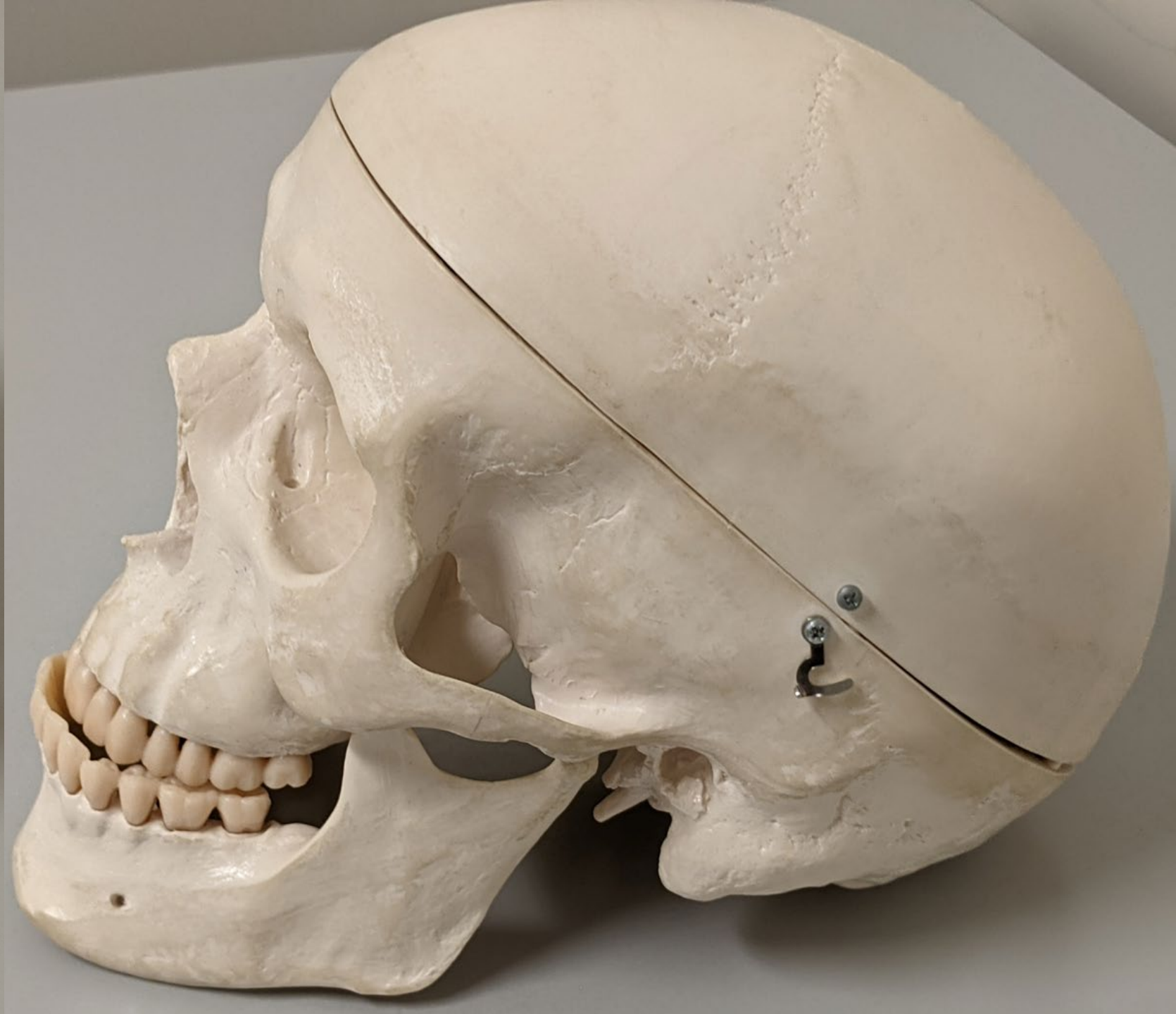
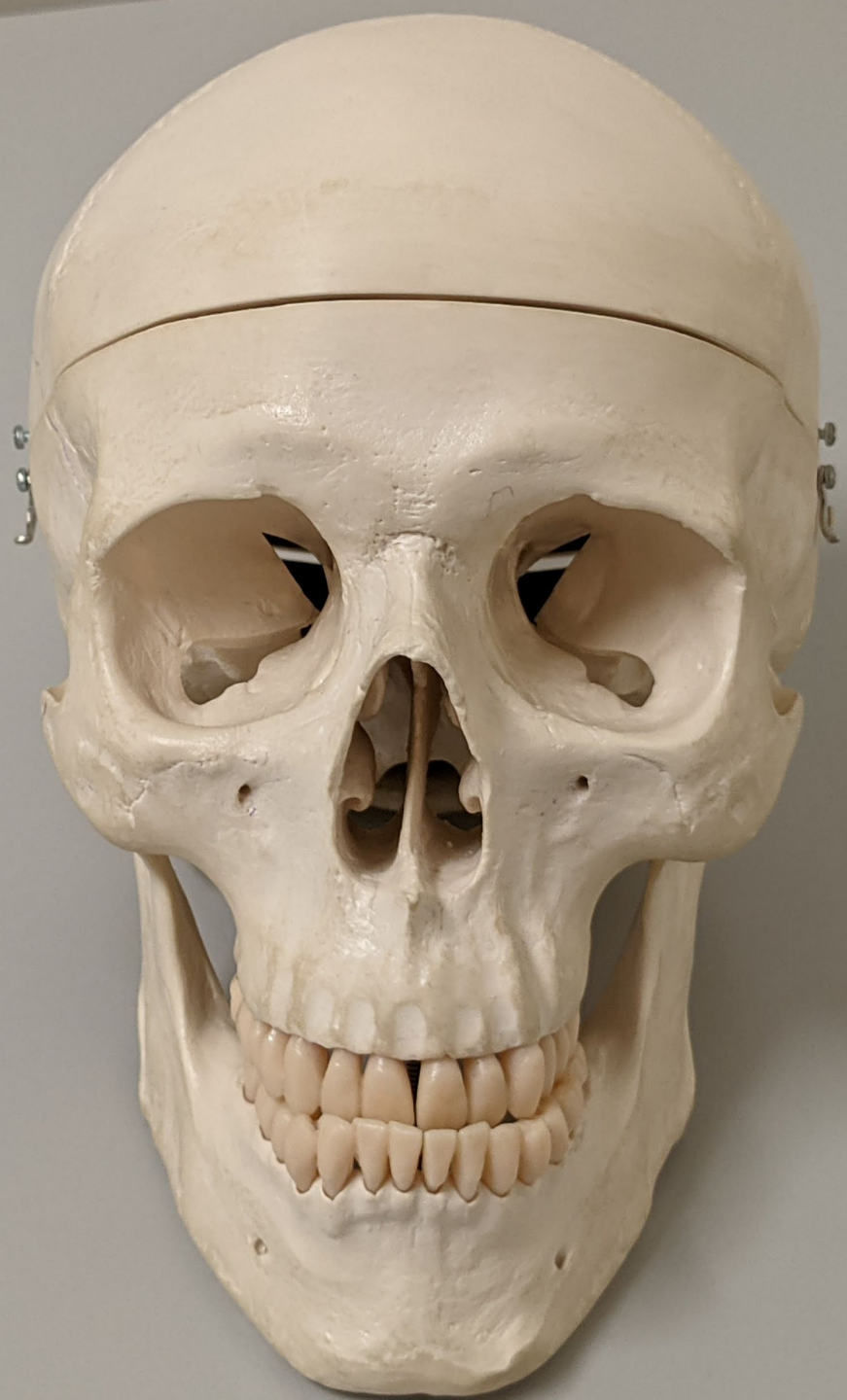


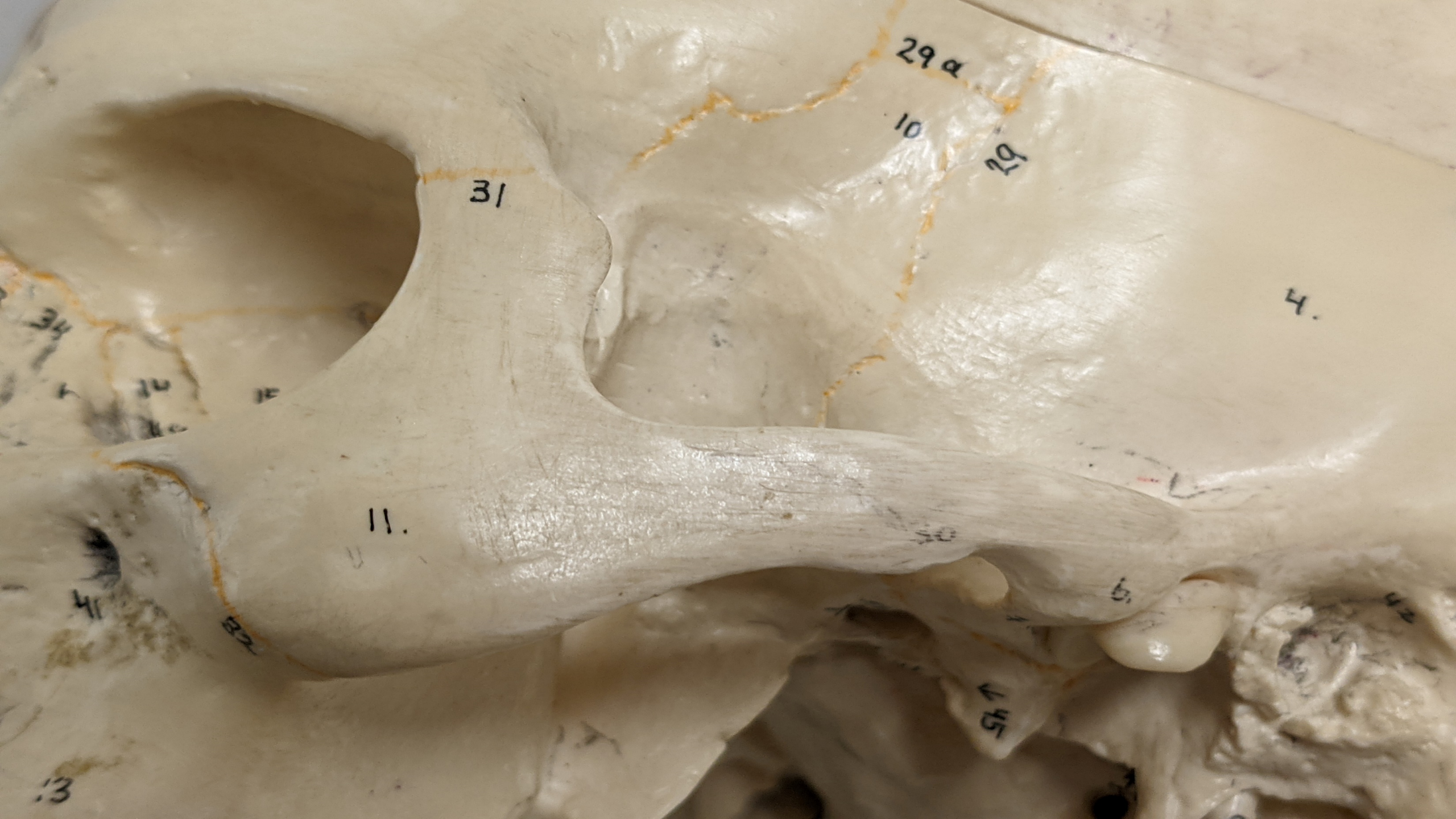



Skull, lateral view, right side







29 a

10

29

31

34

10

15

11.

41

43

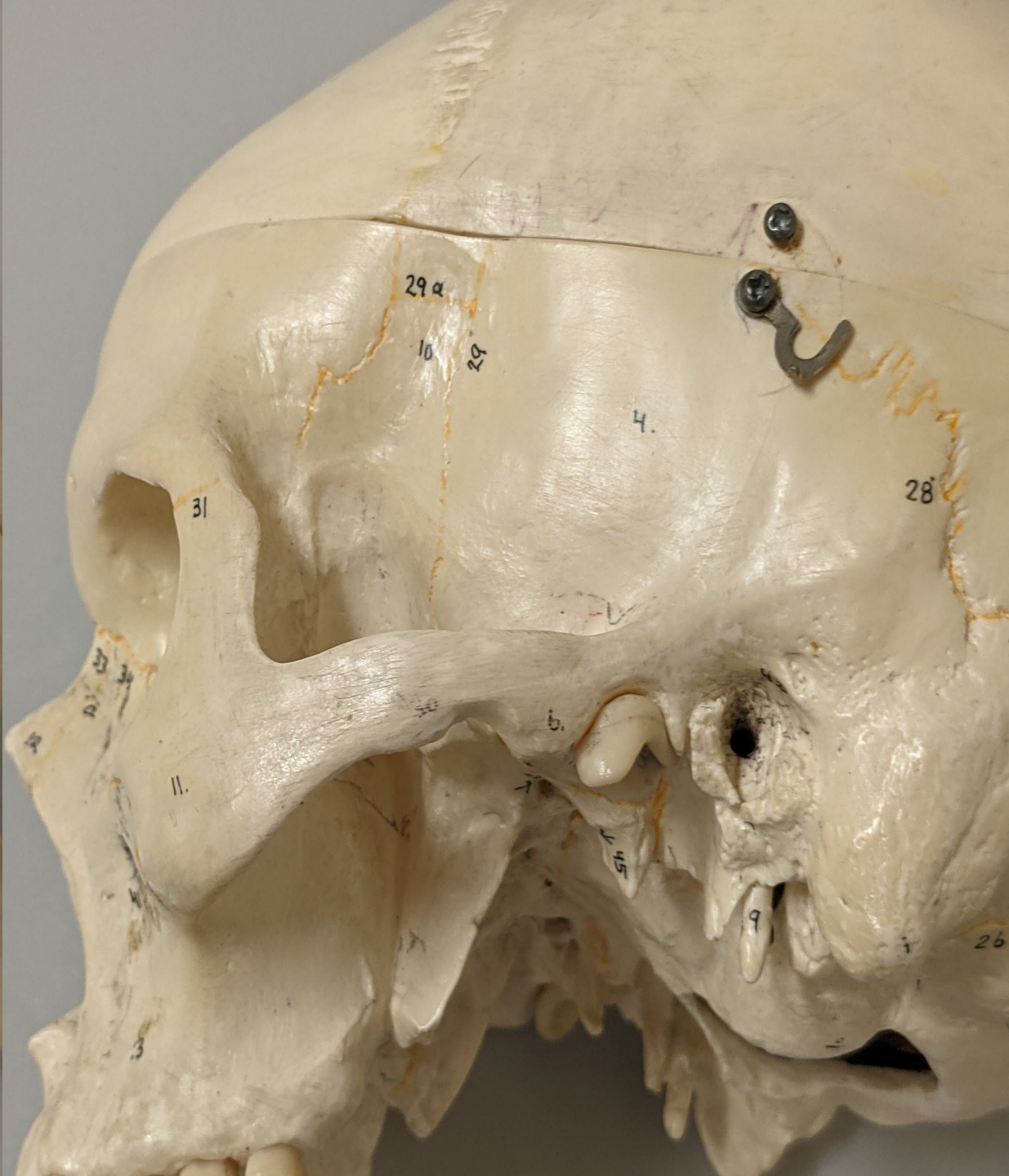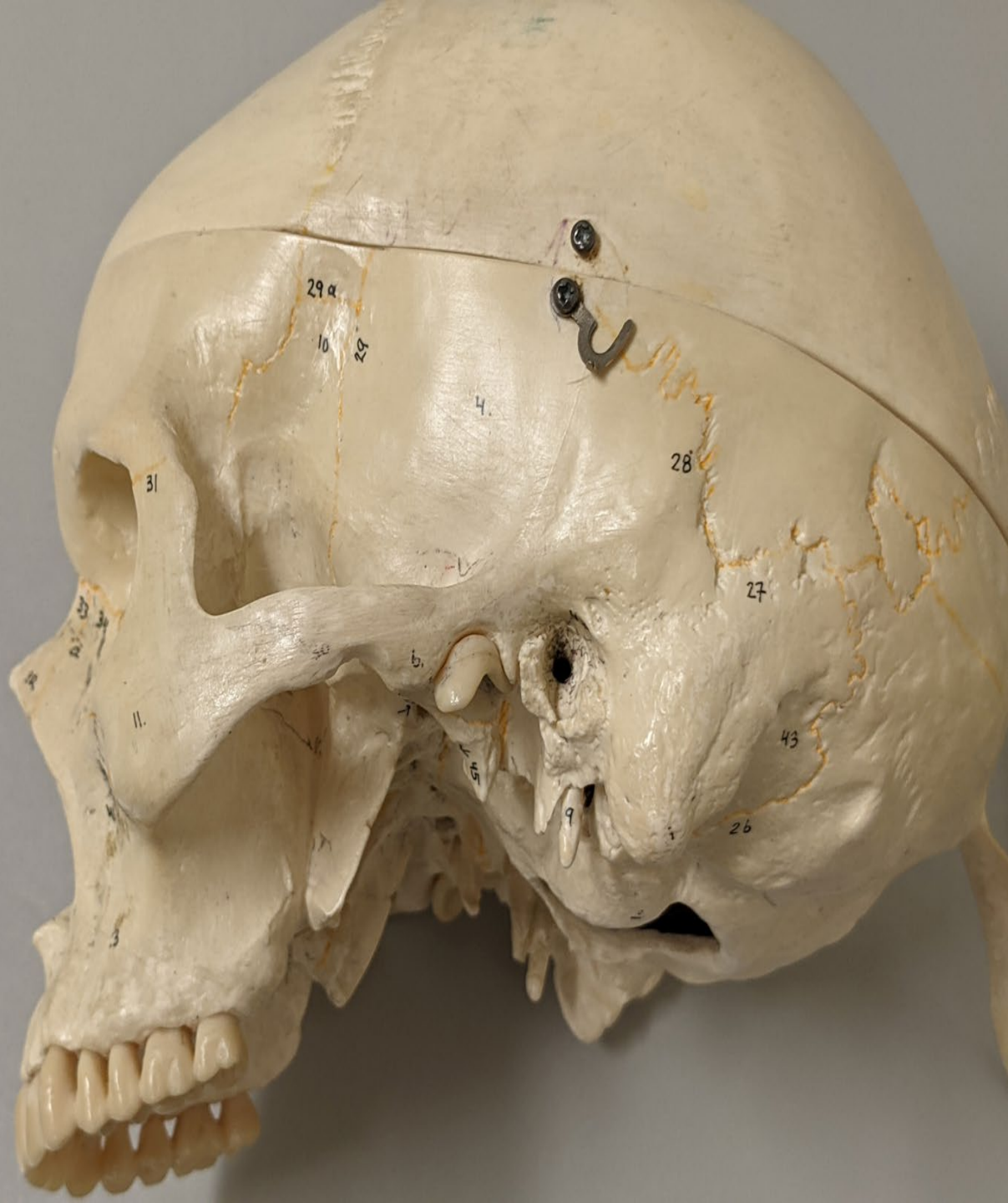42

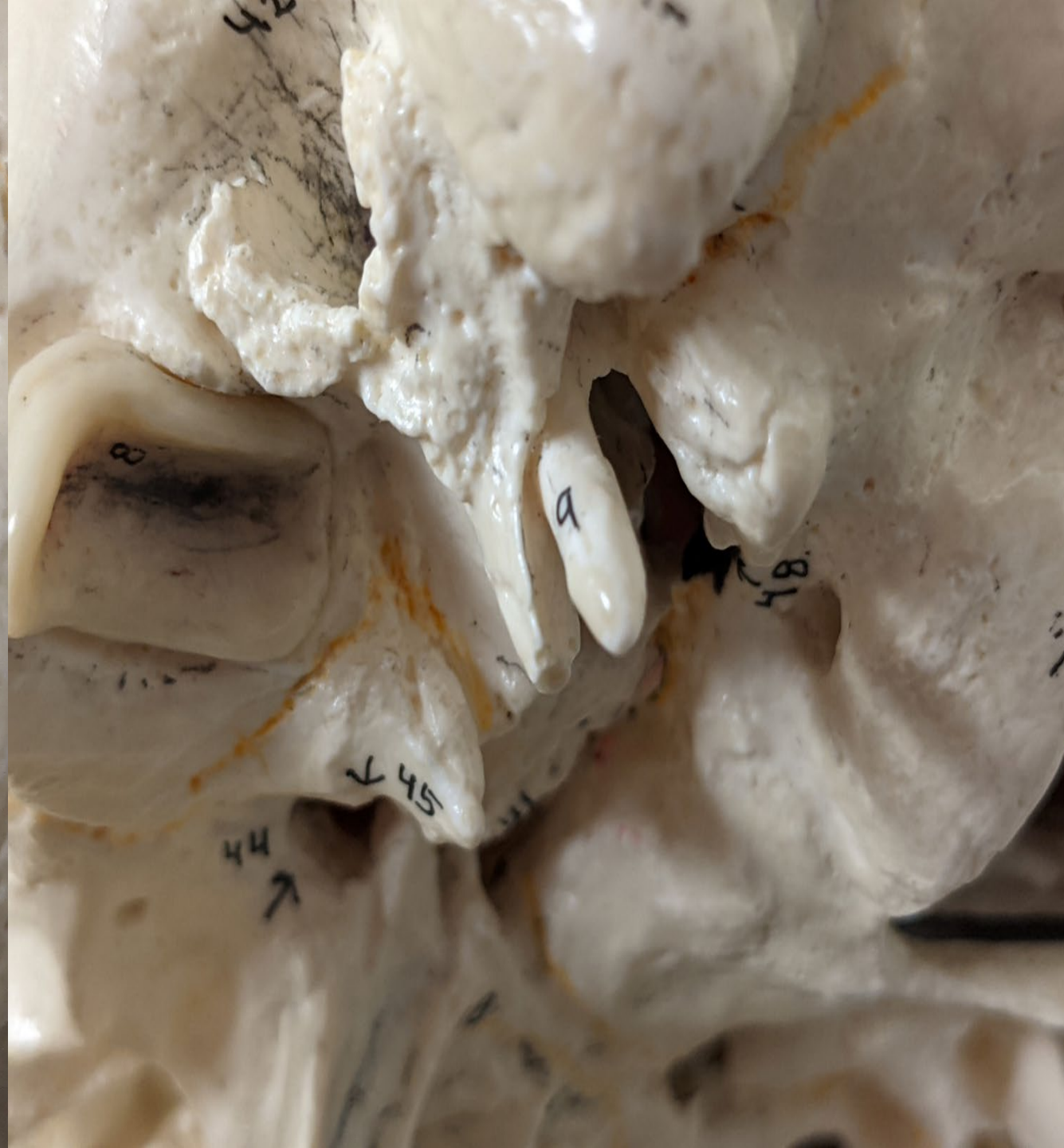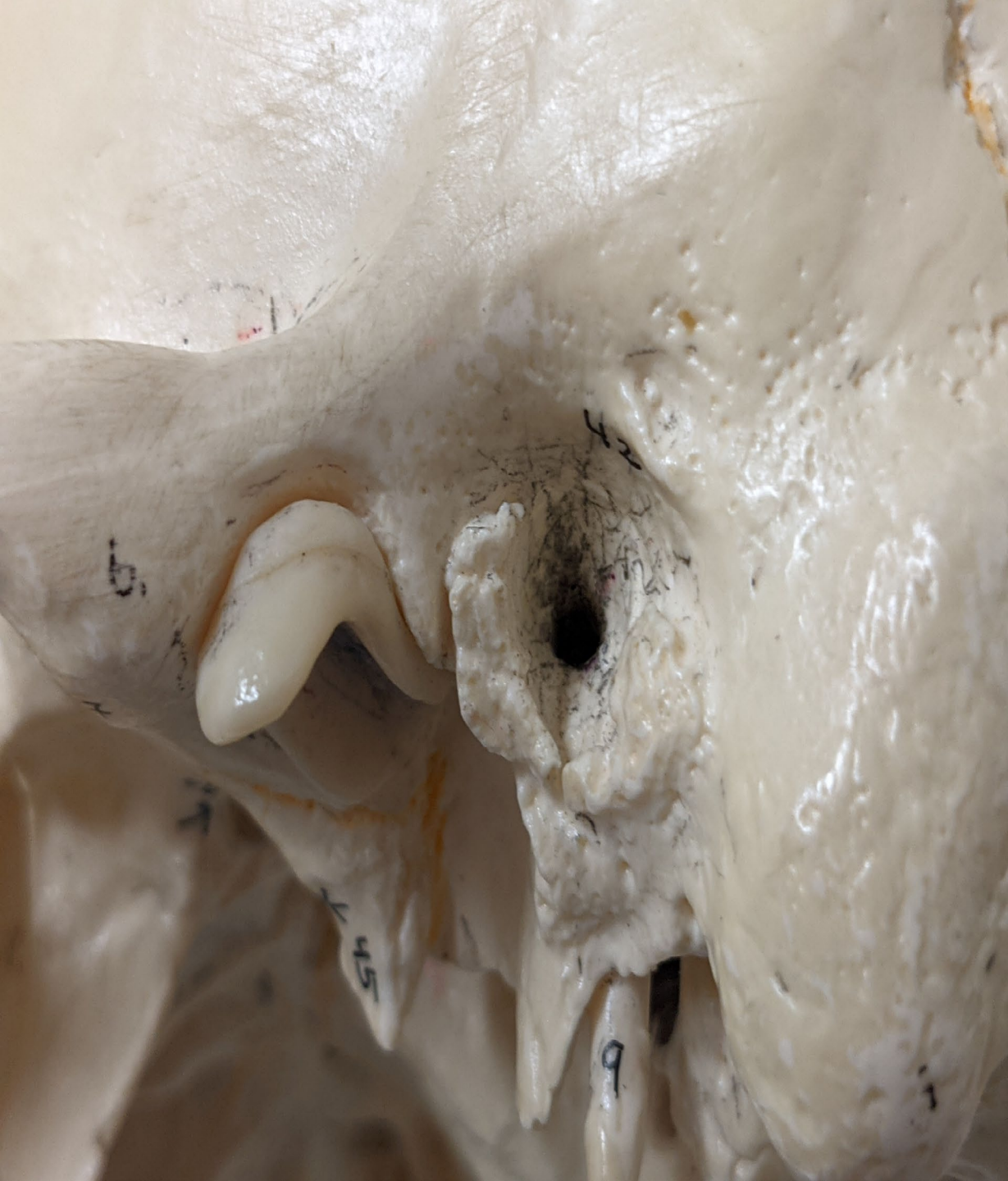45
↑

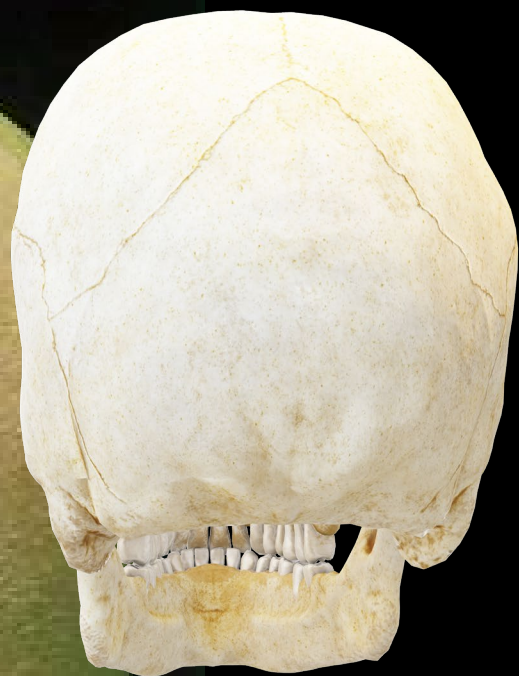b.

42

H.



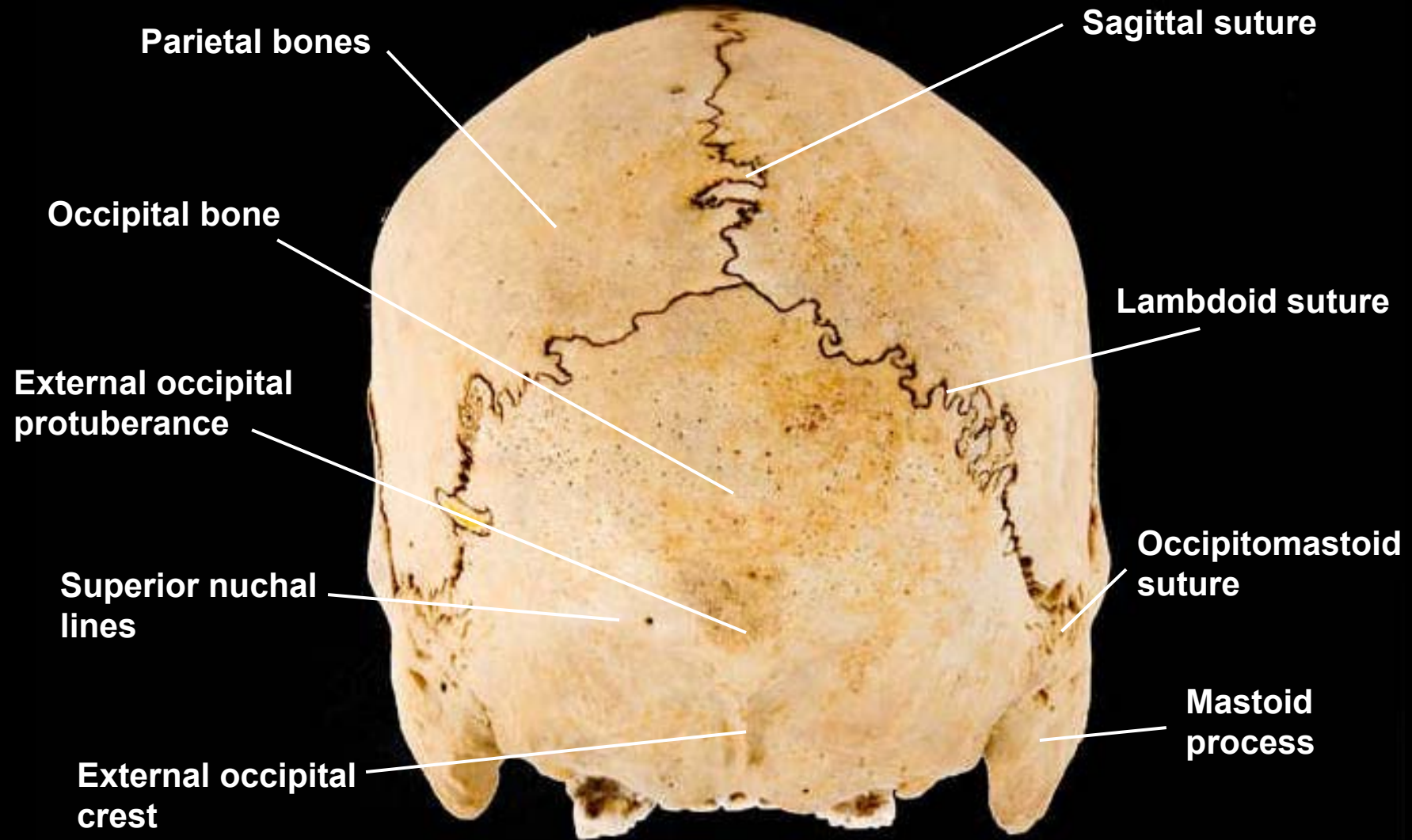




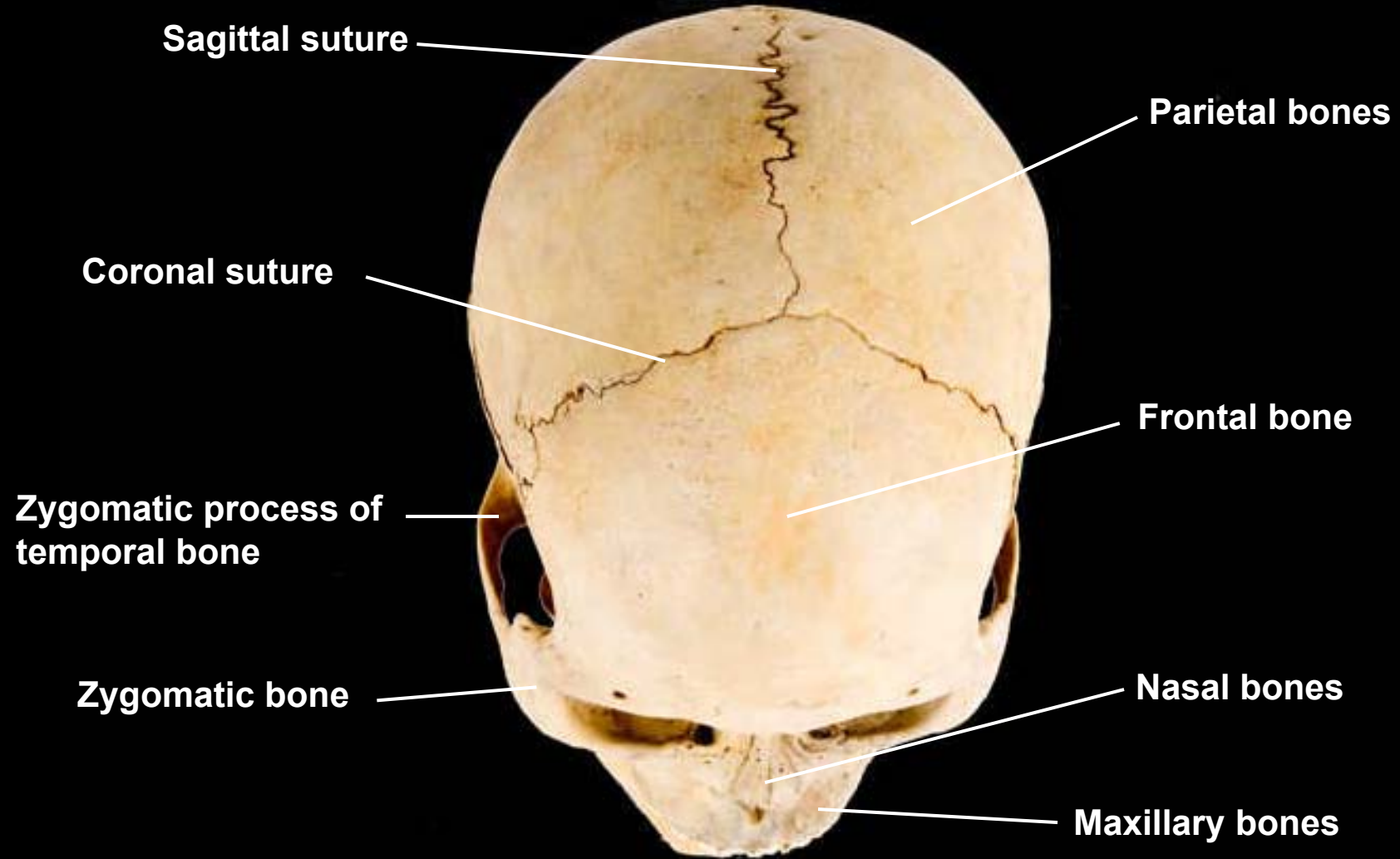


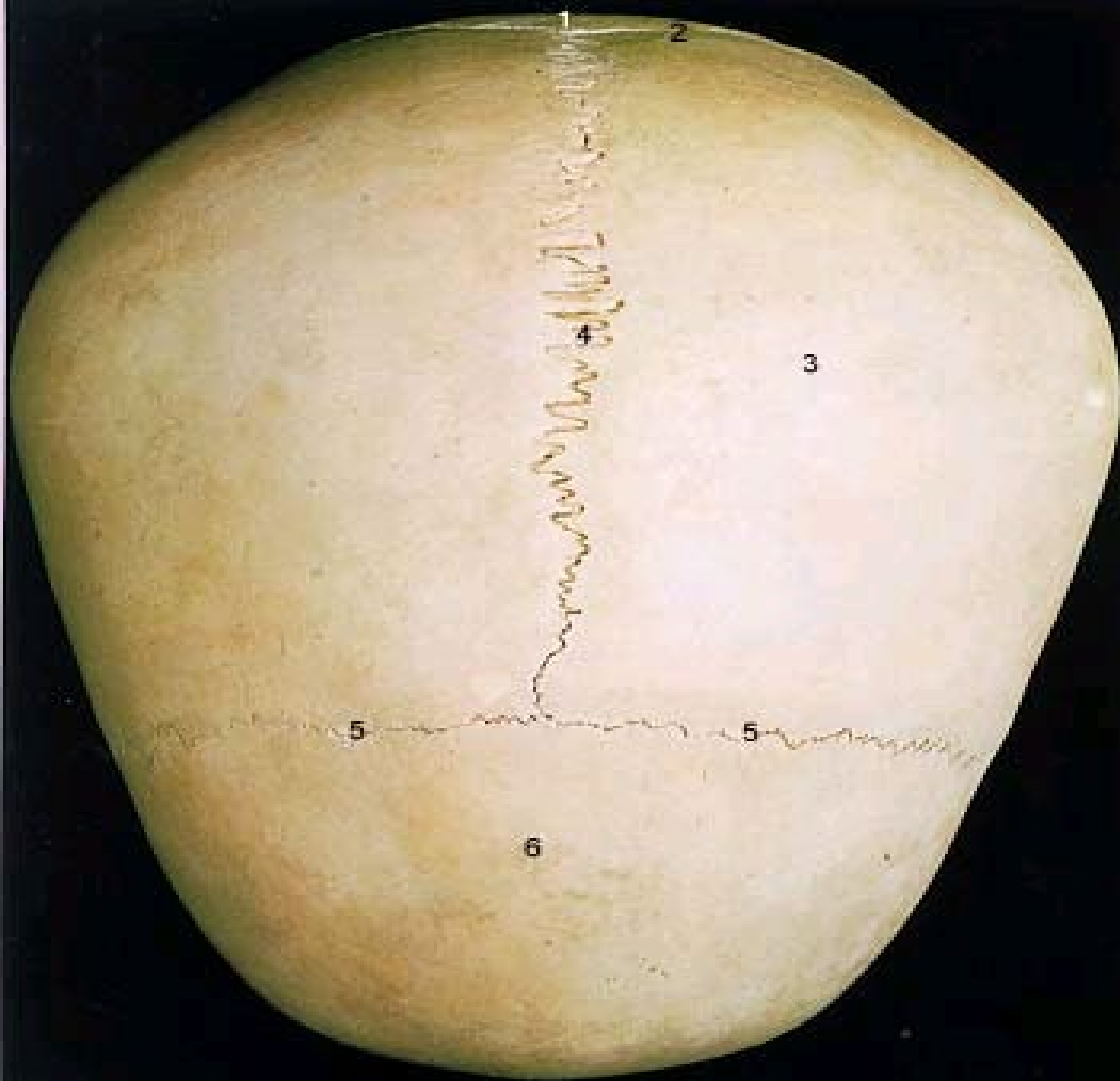
1. Parietal Bone
2. Sagittal Suture
3. Lambdoid Suture
4. Occipital Bone
5. External Occipital Protruberance
6. Superior Nuchal Line
7. Inferior Nuchal Line

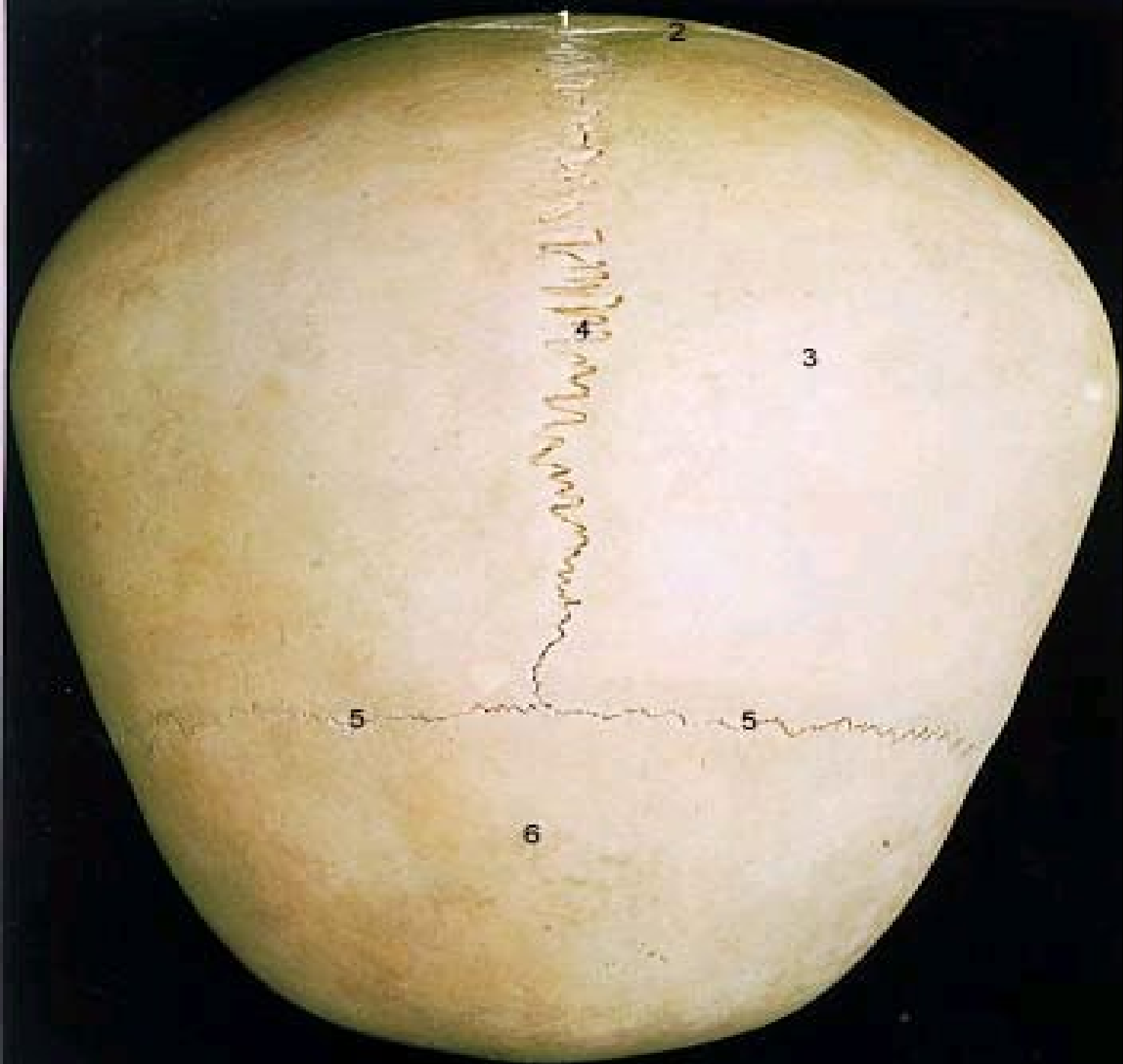
Skull, posterior view



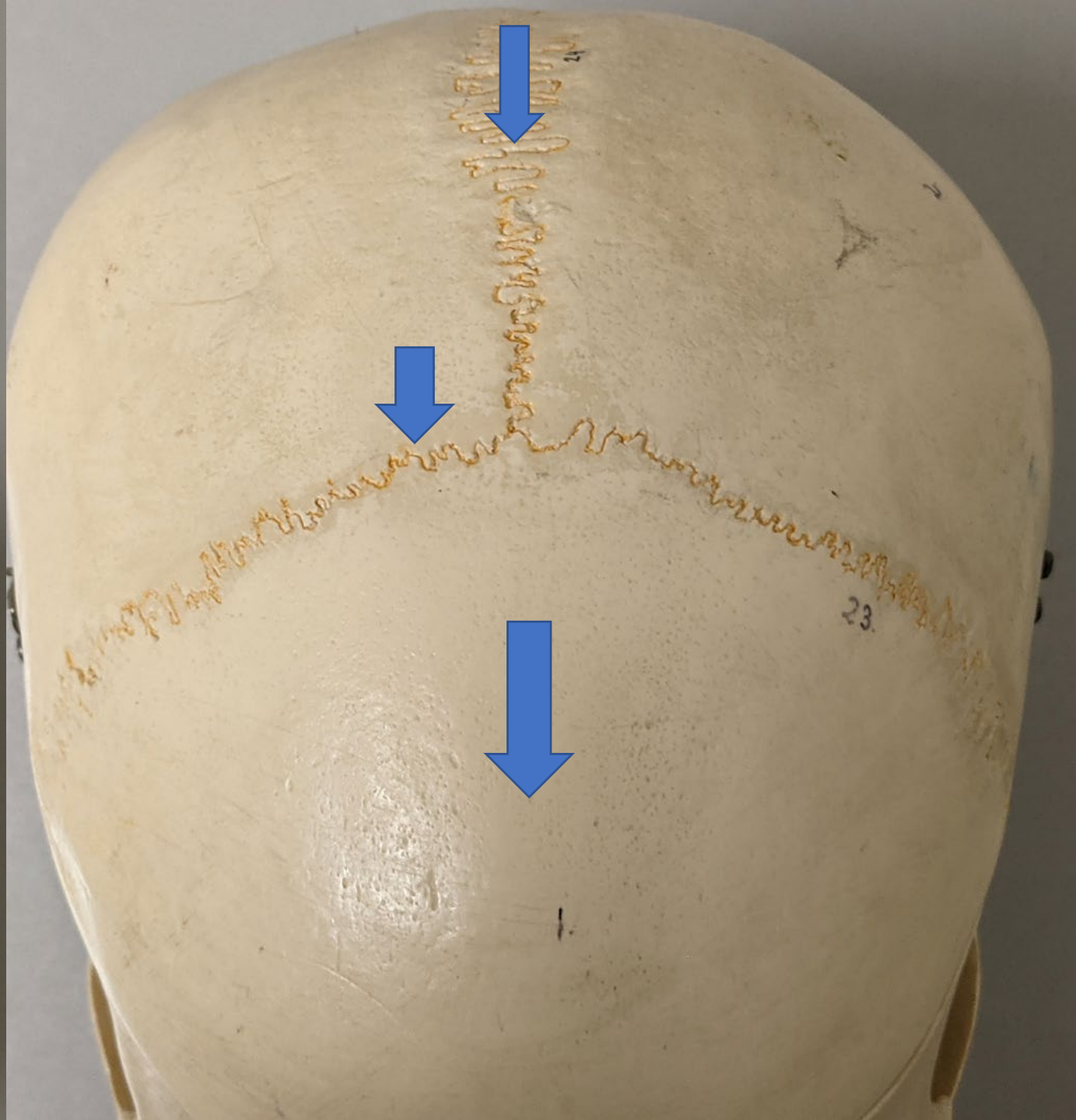

Skull, superior view

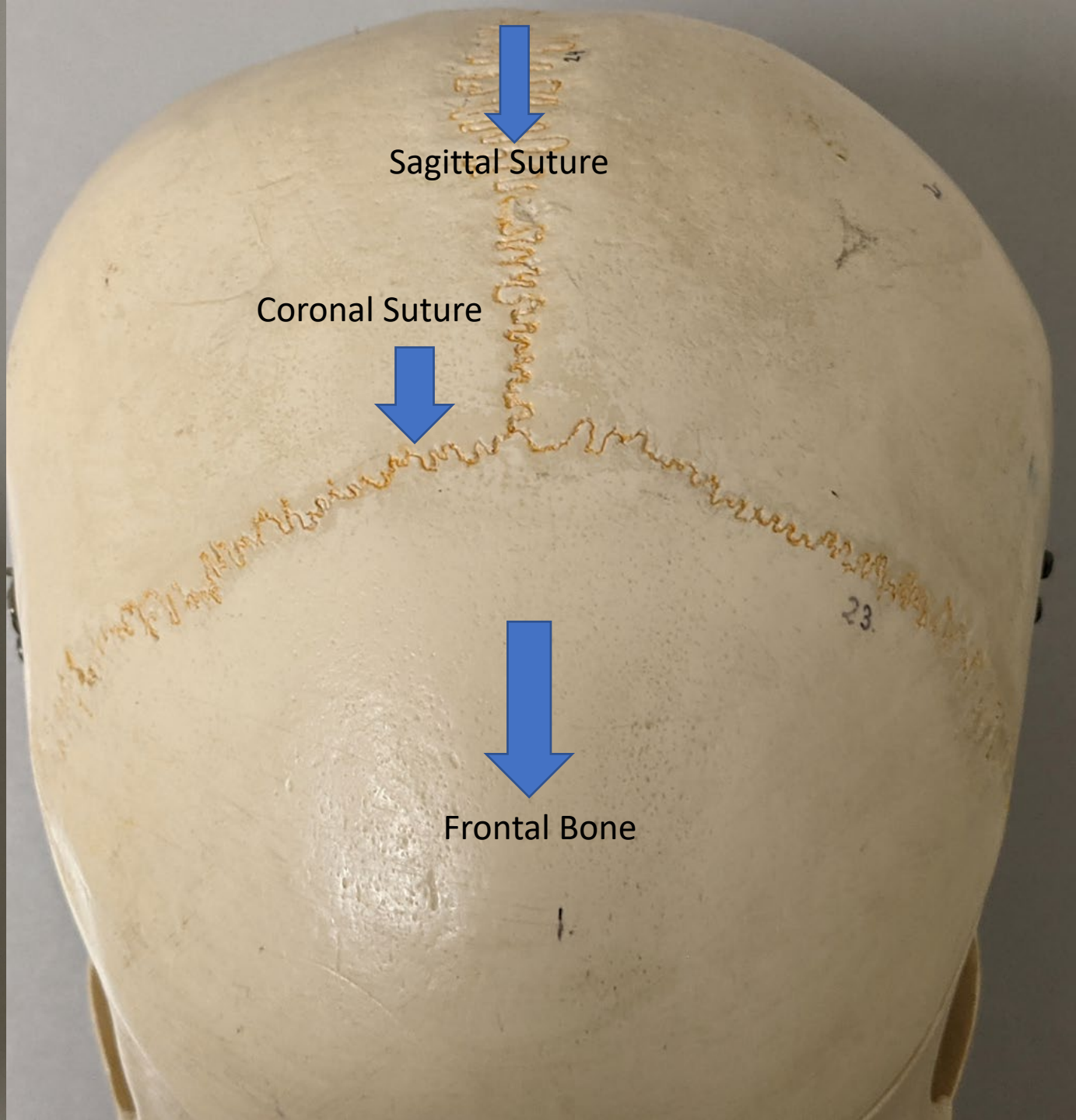
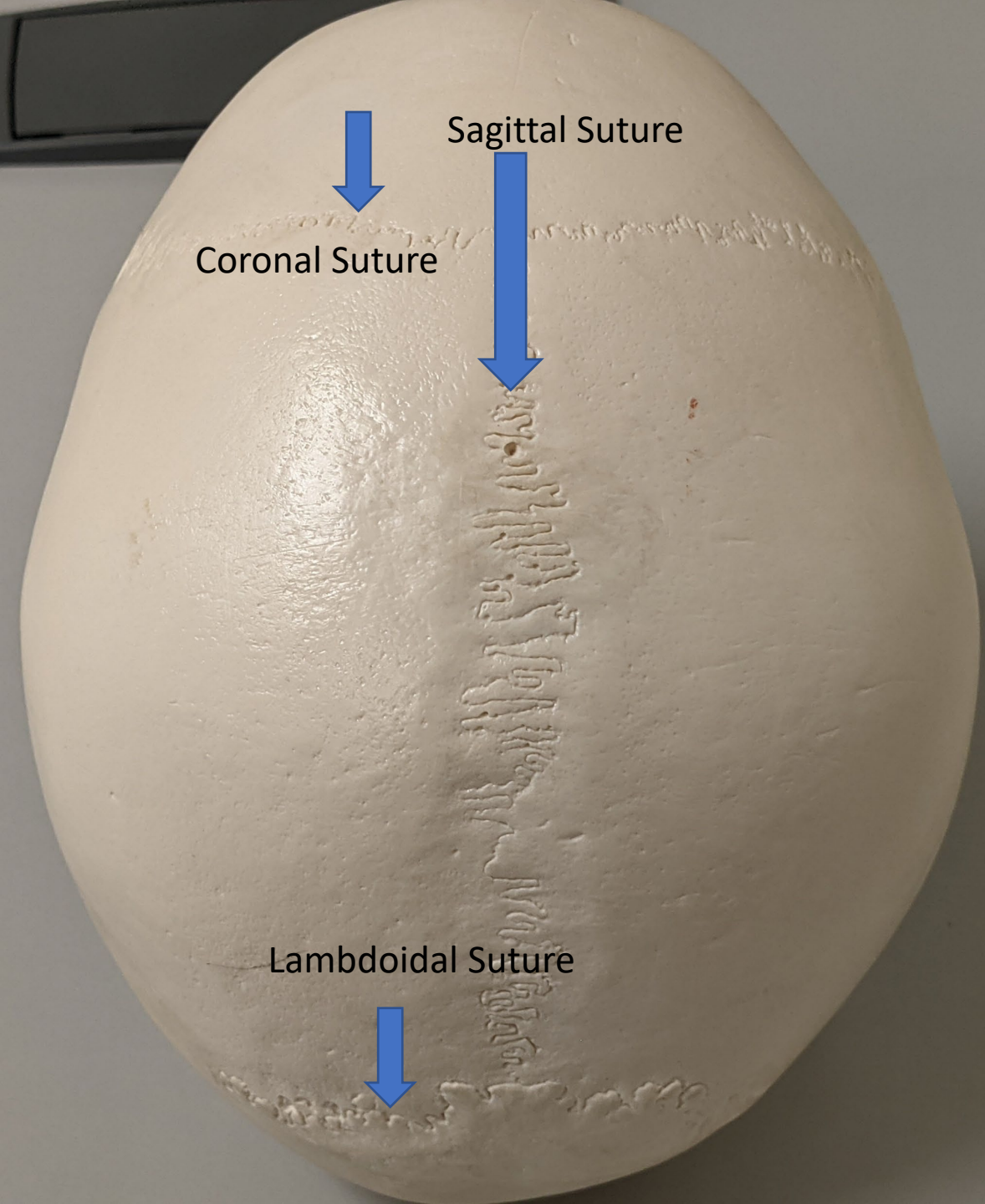


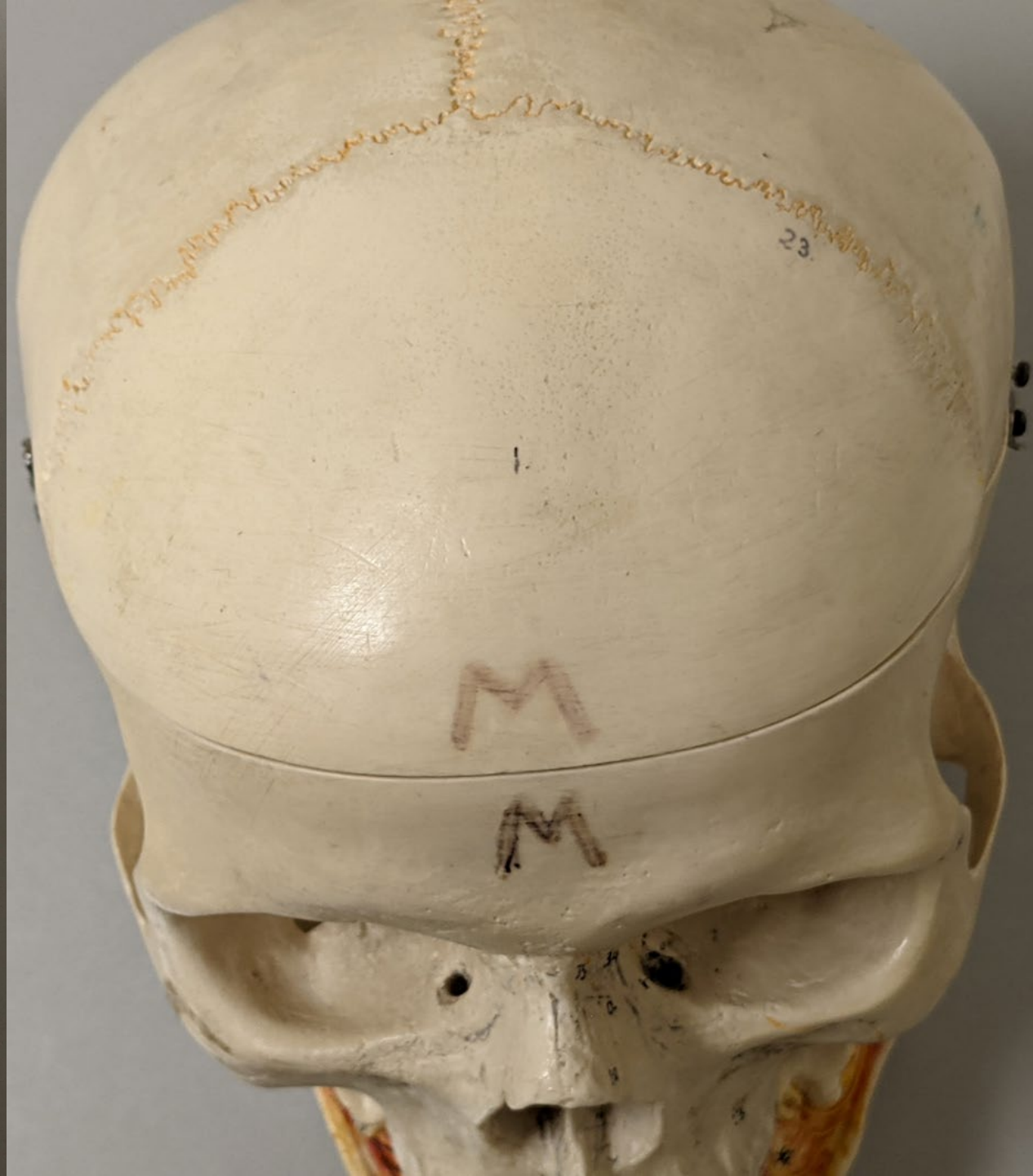


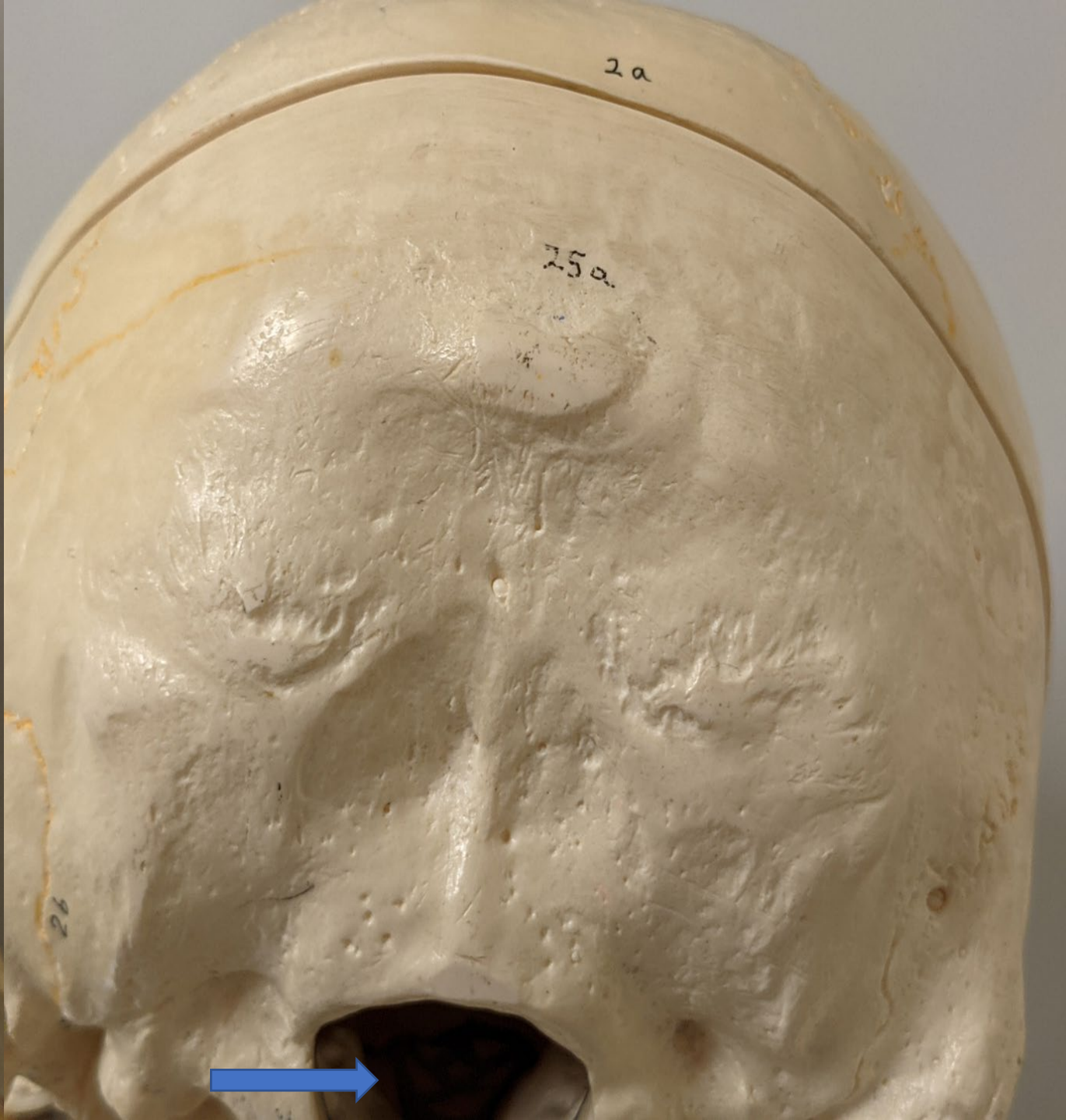
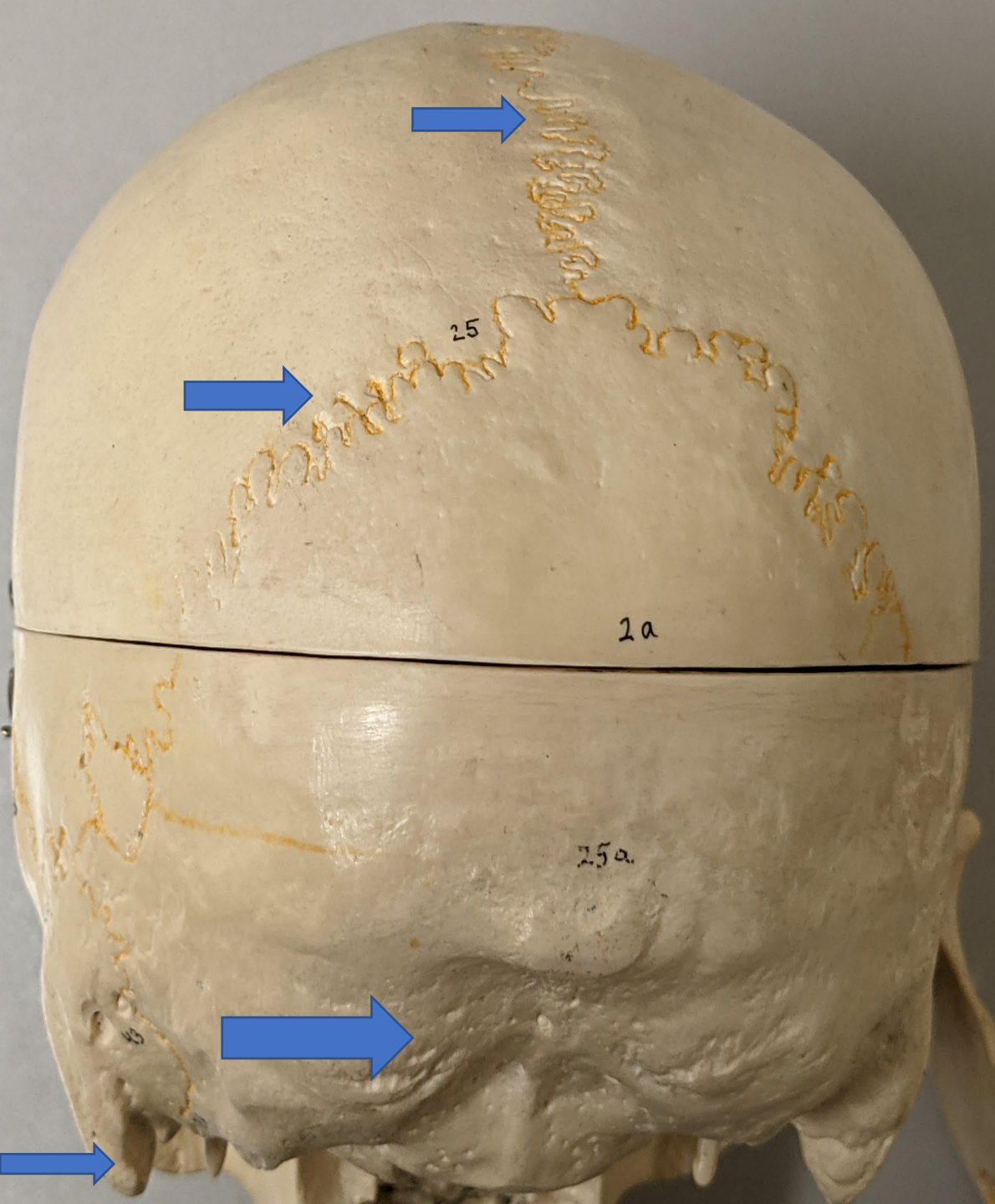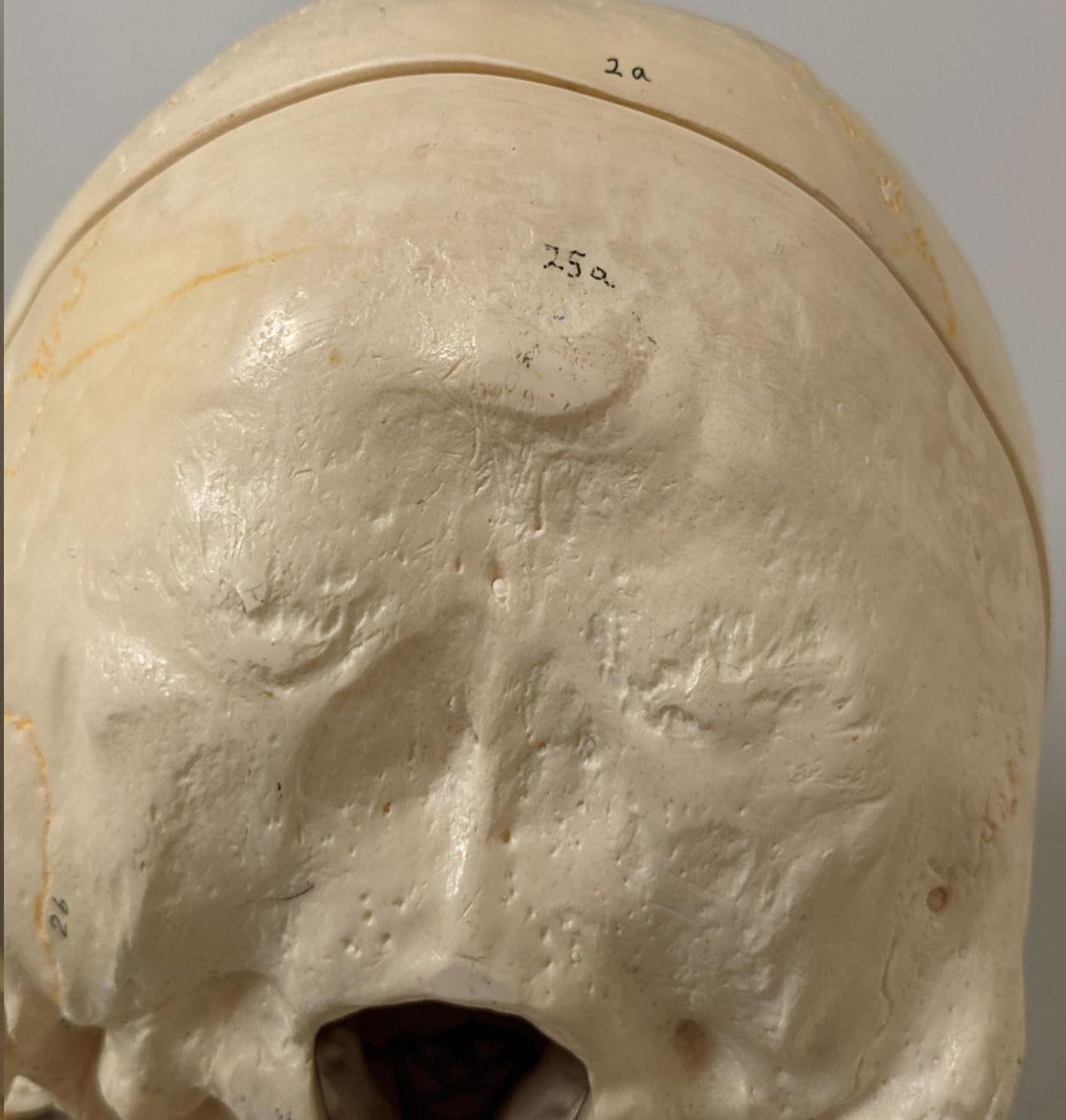
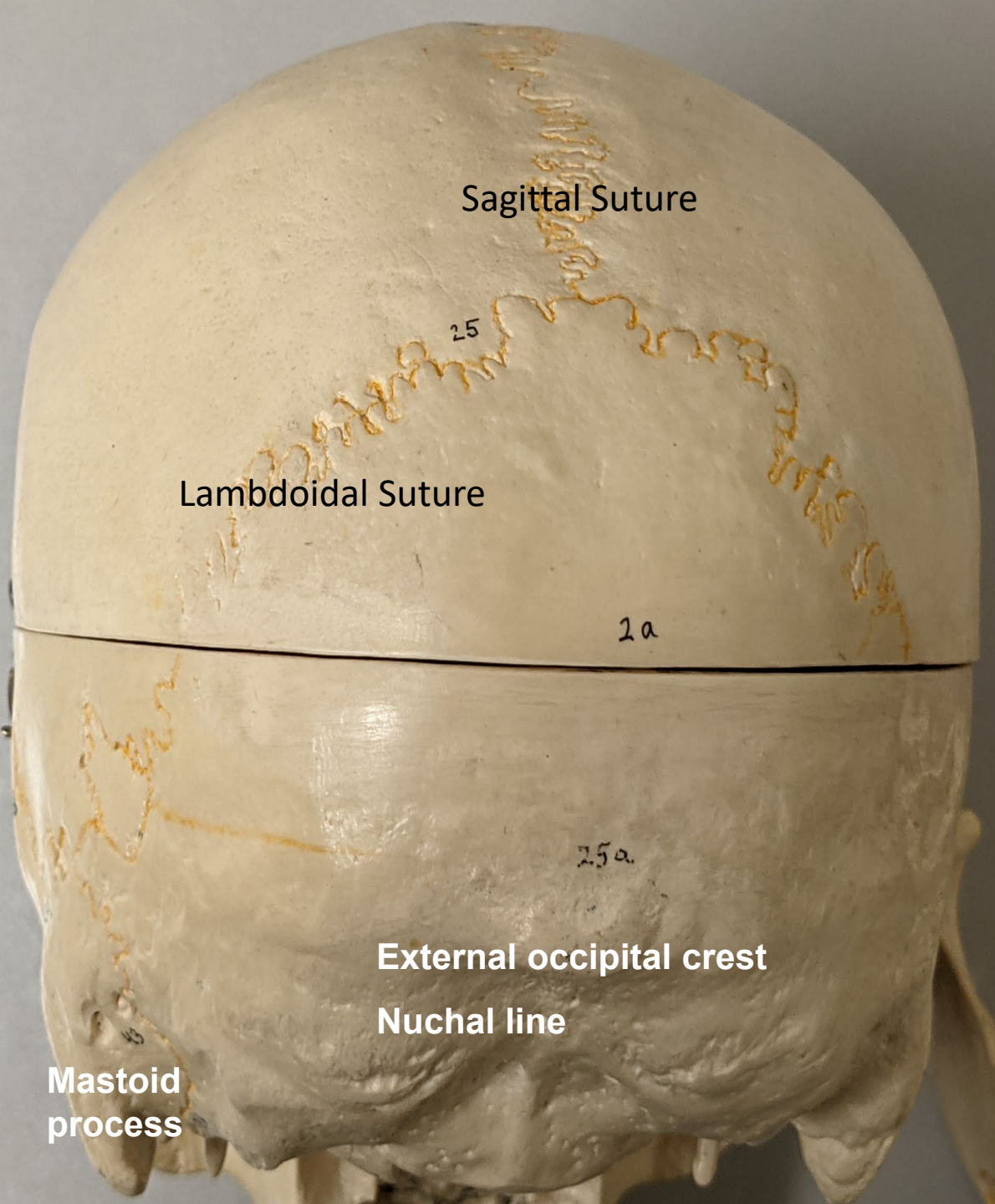
1. Occipital Bone
2. Lambdoidal Suture
3. Parietal Bone
4. Sagittal Suture
5. Coronal Suture
6. Frontal Bone









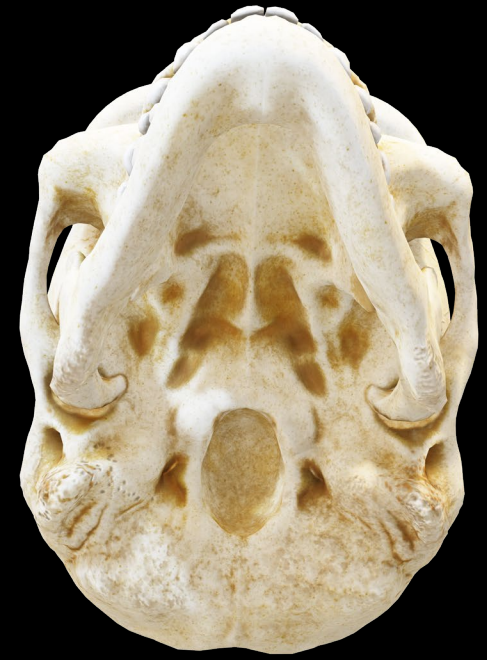
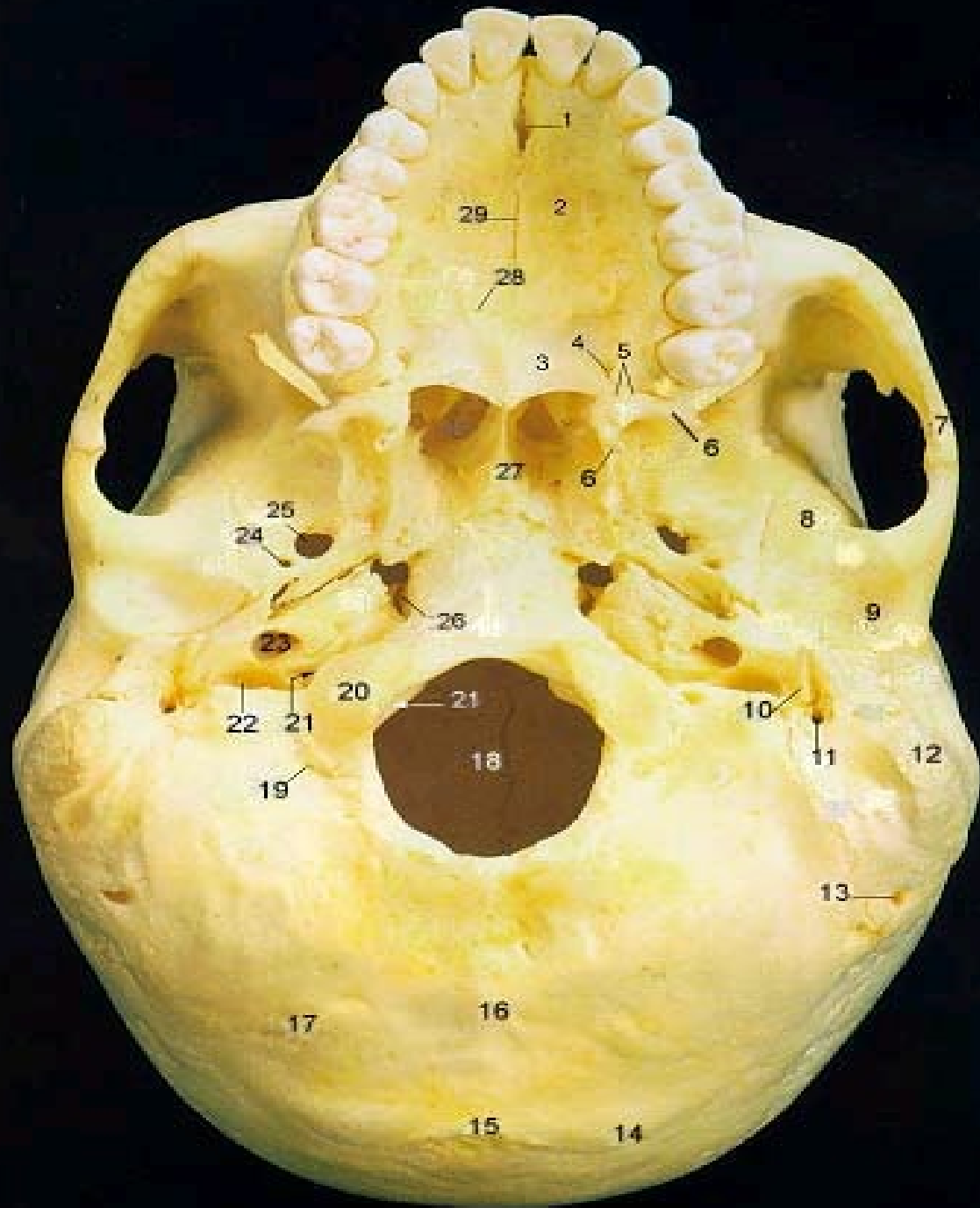


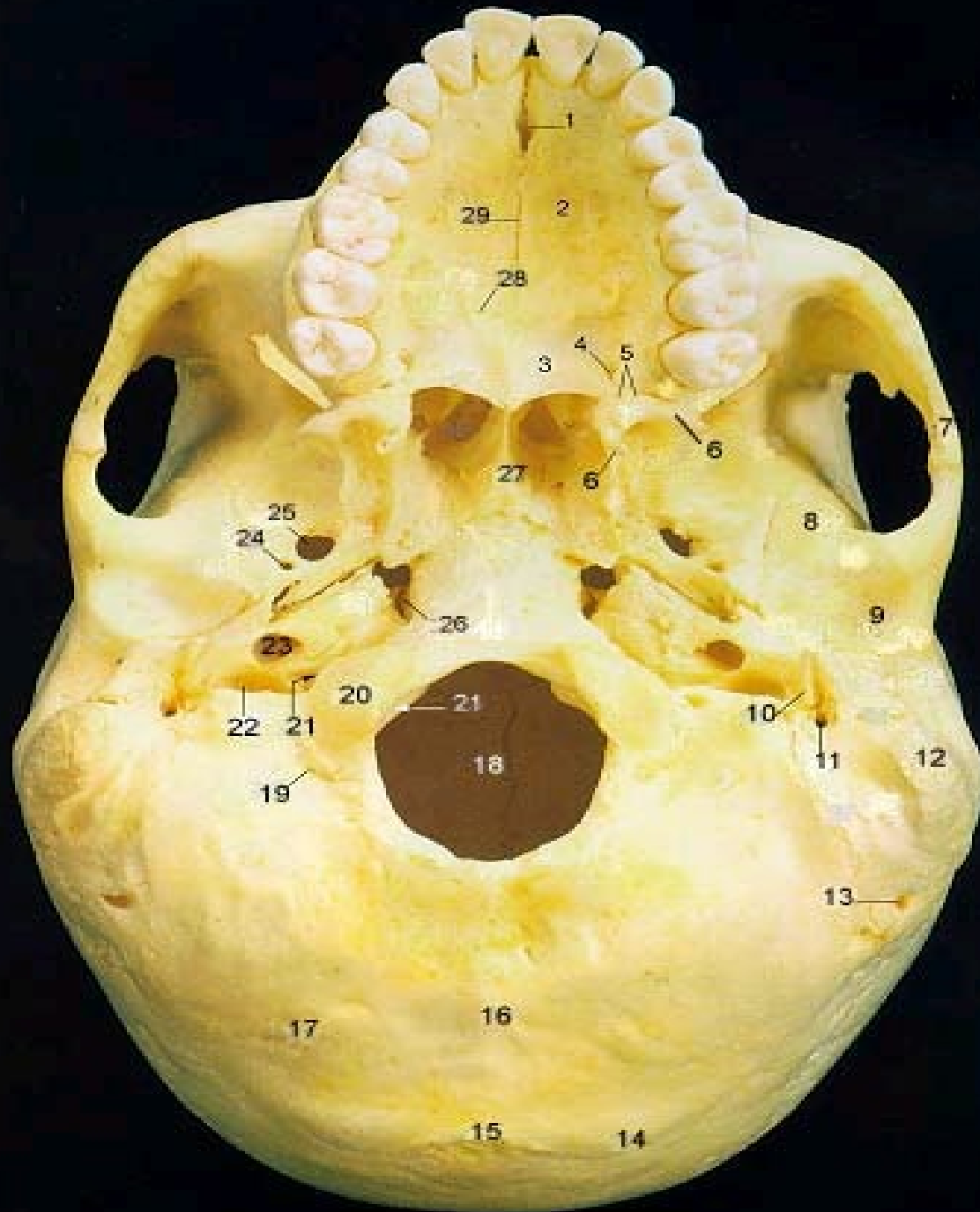


Sagittal Suture

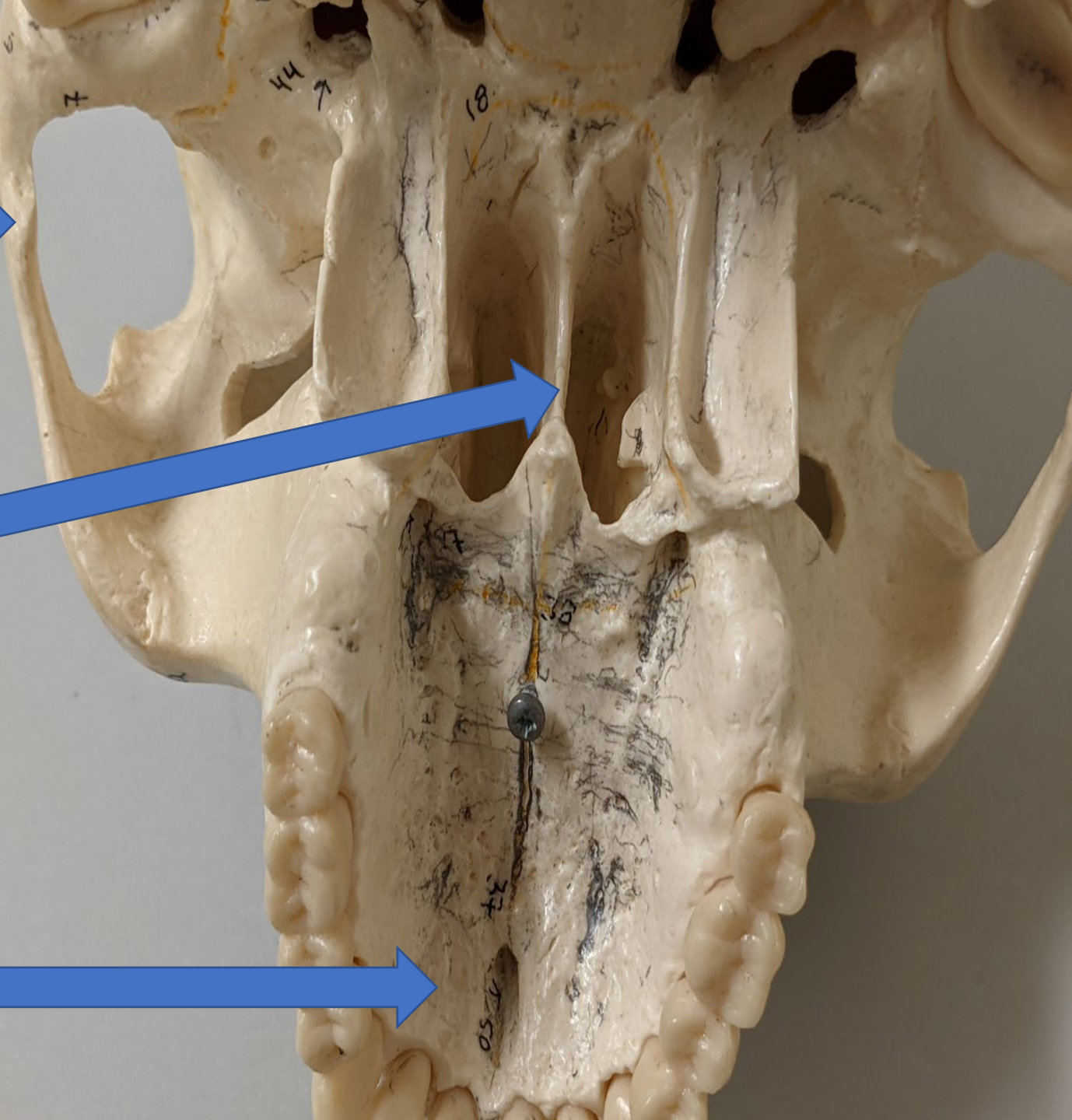
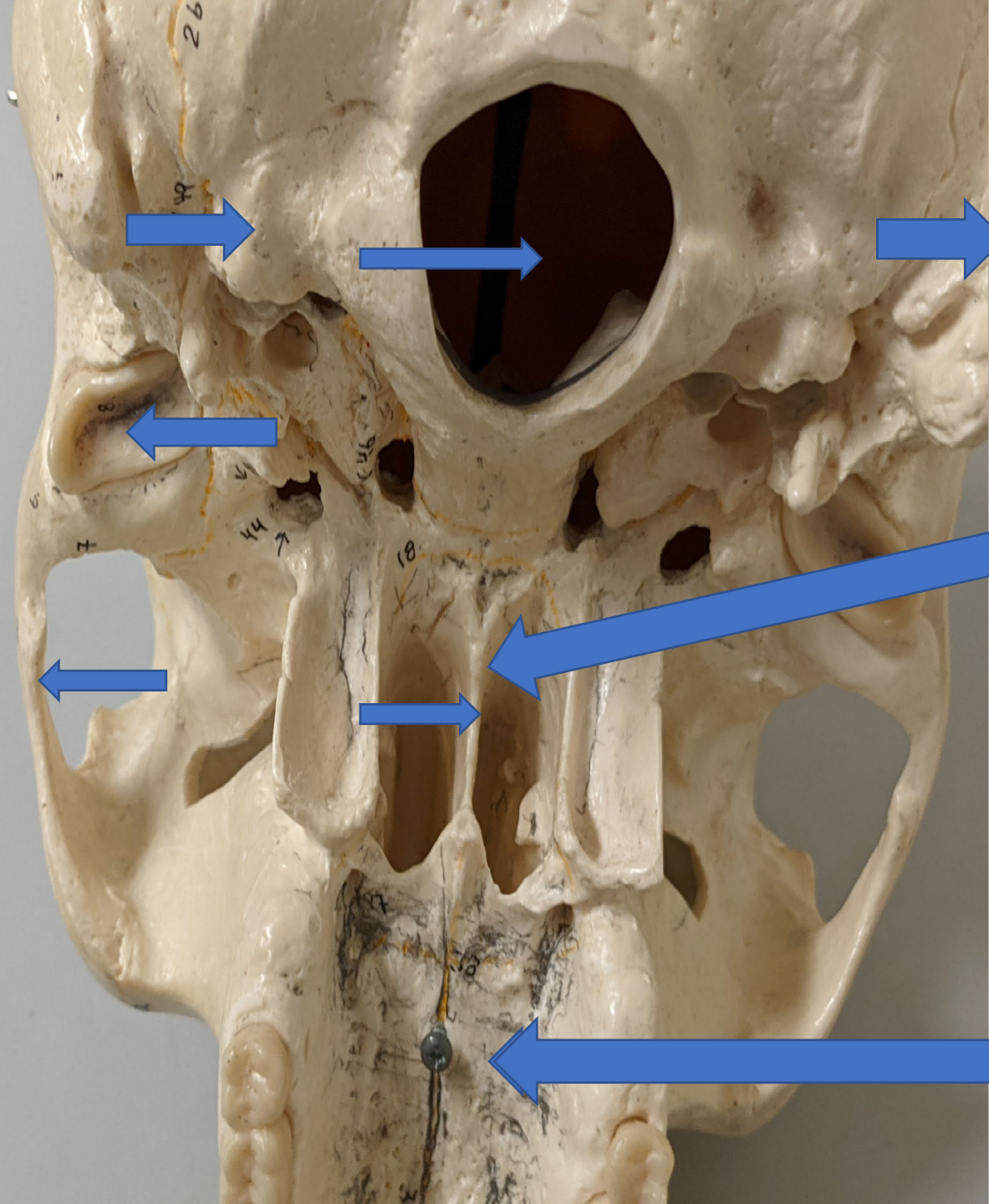
24

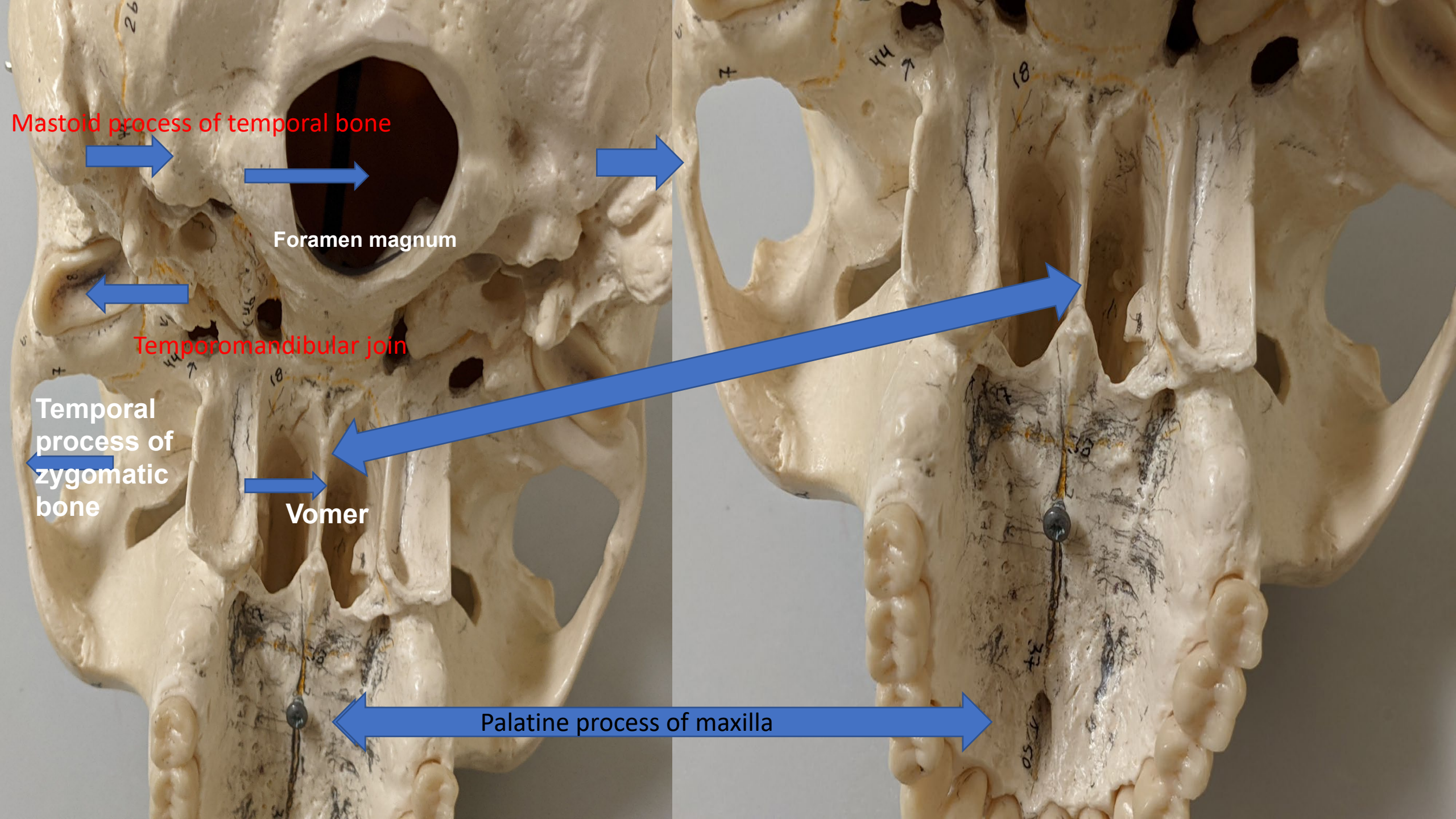
25





- 3. Palatine
- 6. Pterygoid Processes of Sphenoid
- 7. Zygomatic Process
- 8. Squamous Part of Temporal Bone
- 9. Mandibular Fossa
- 10. Styloid Process
- 12. Mastoid Process
- 14. Superior Nuchal Line
- 15. External Occipital Protruberance
- 17. Inferior Nuchal Line
- 18. Foramen Magnum
- 20. Occipital Condyle
- 22. Jugular Foramen
- 23.





Mastoid process of temporal bone

Foramen magnum

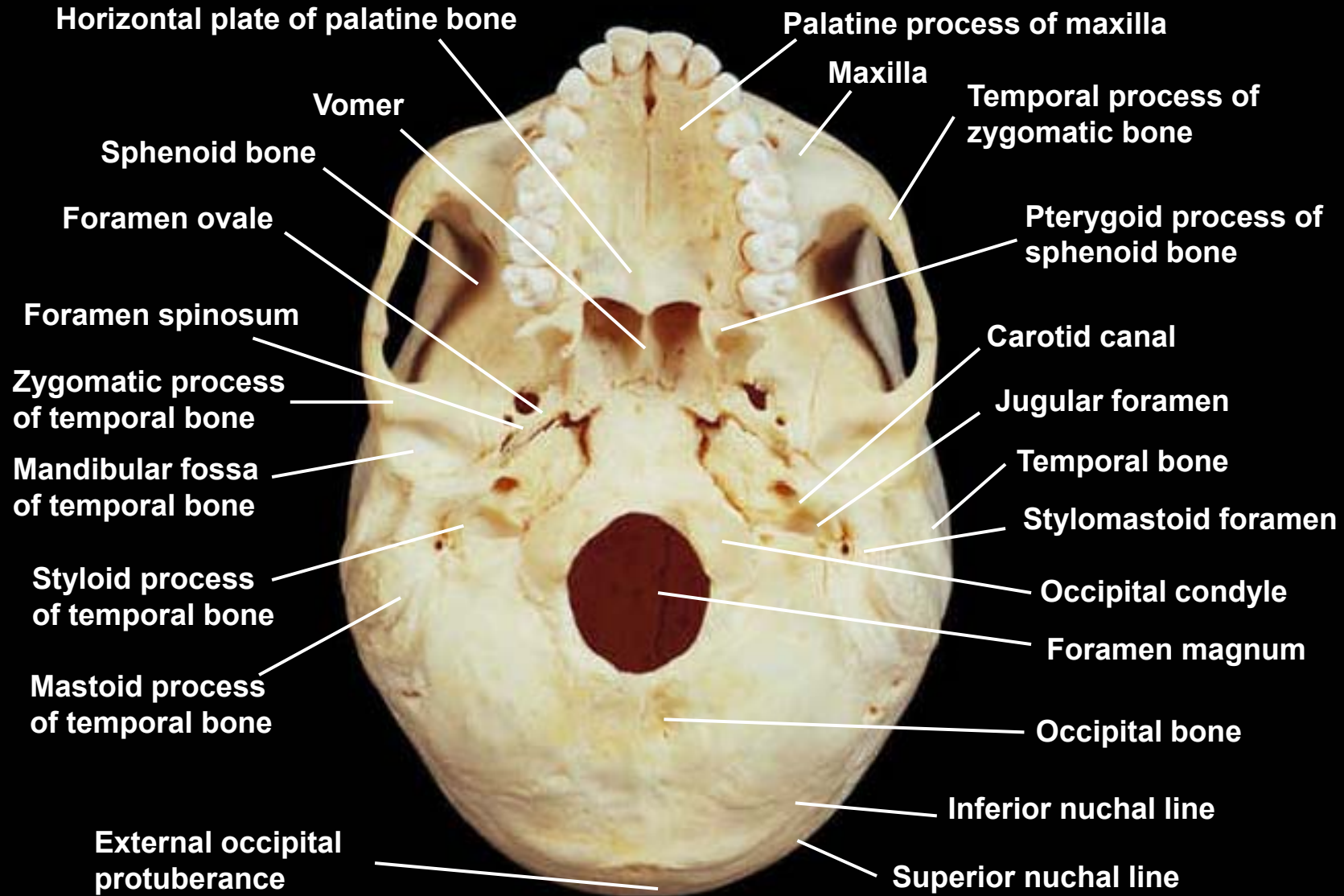
Temporomandibular joint

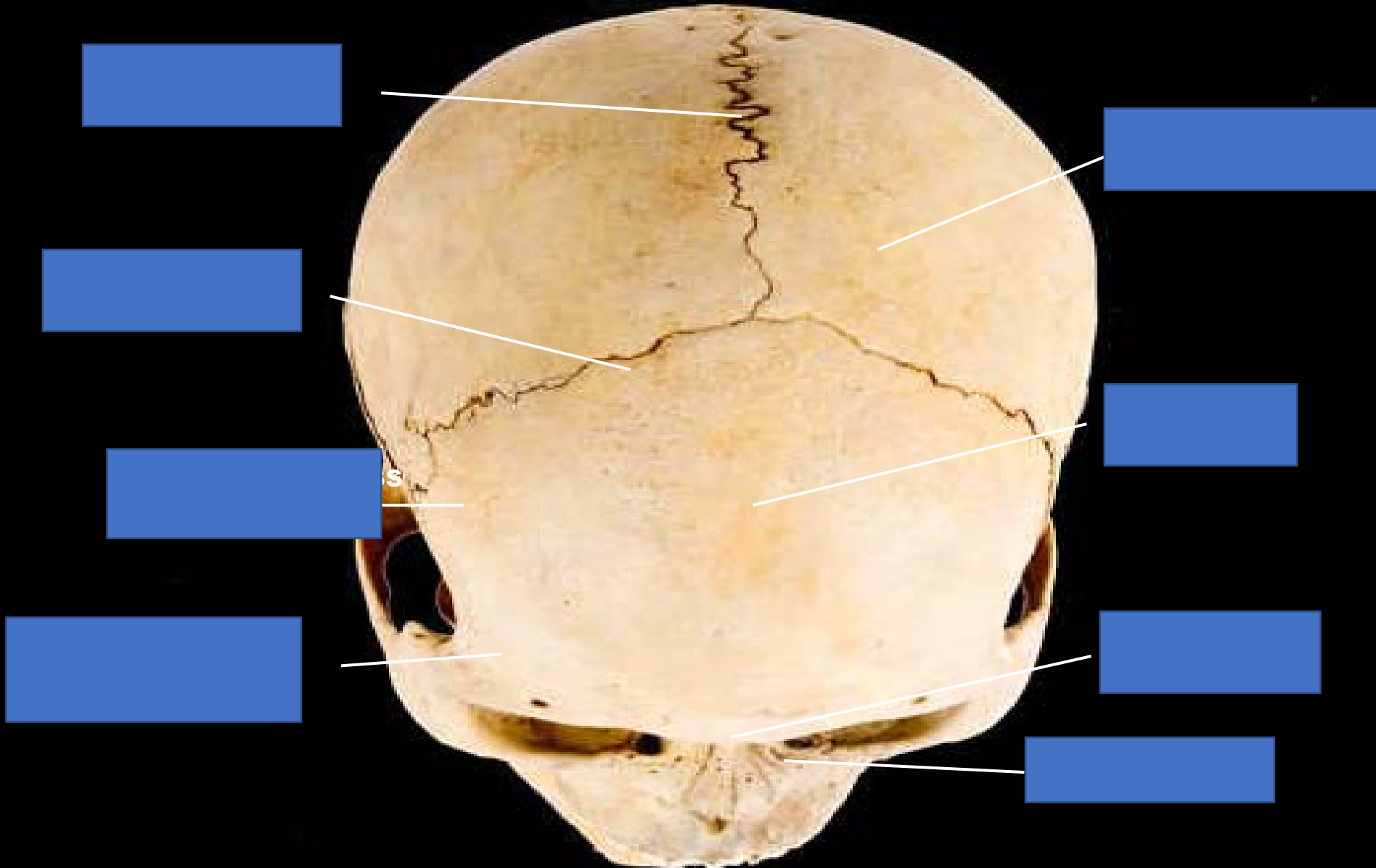
Temporal process of zygomatic bone

Vomer

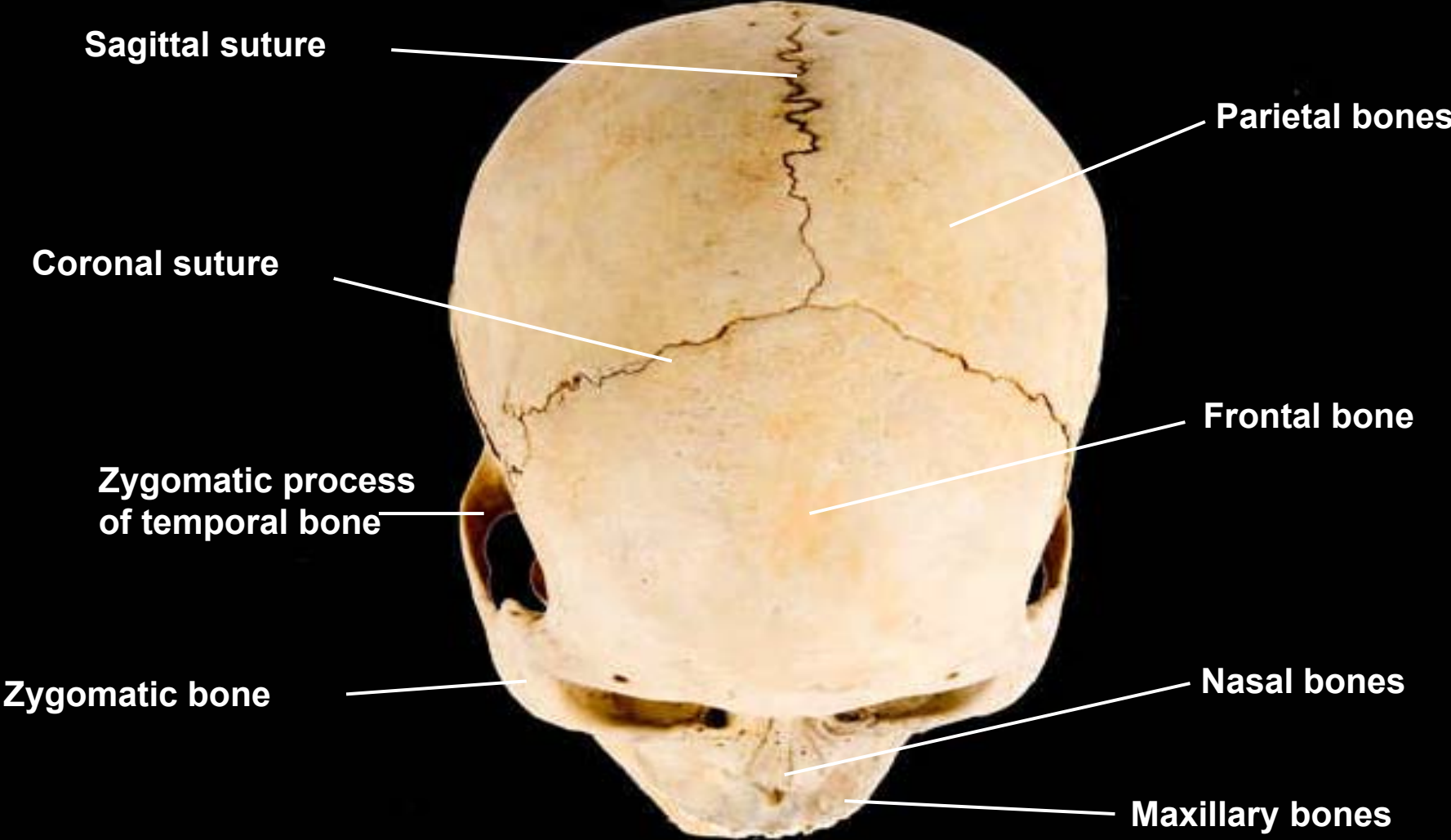
Palatine process of maxilla

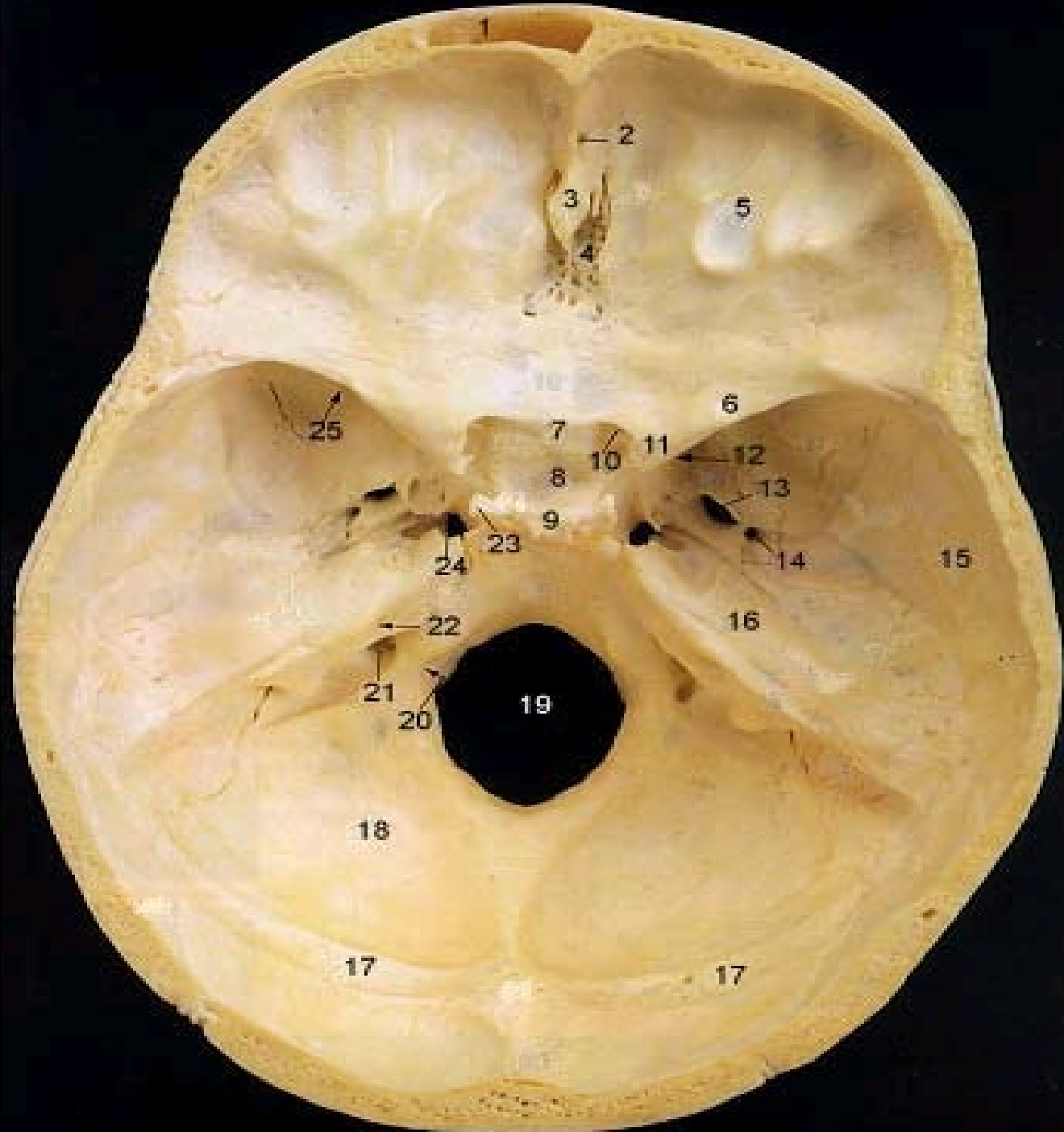
Skull, inferior view

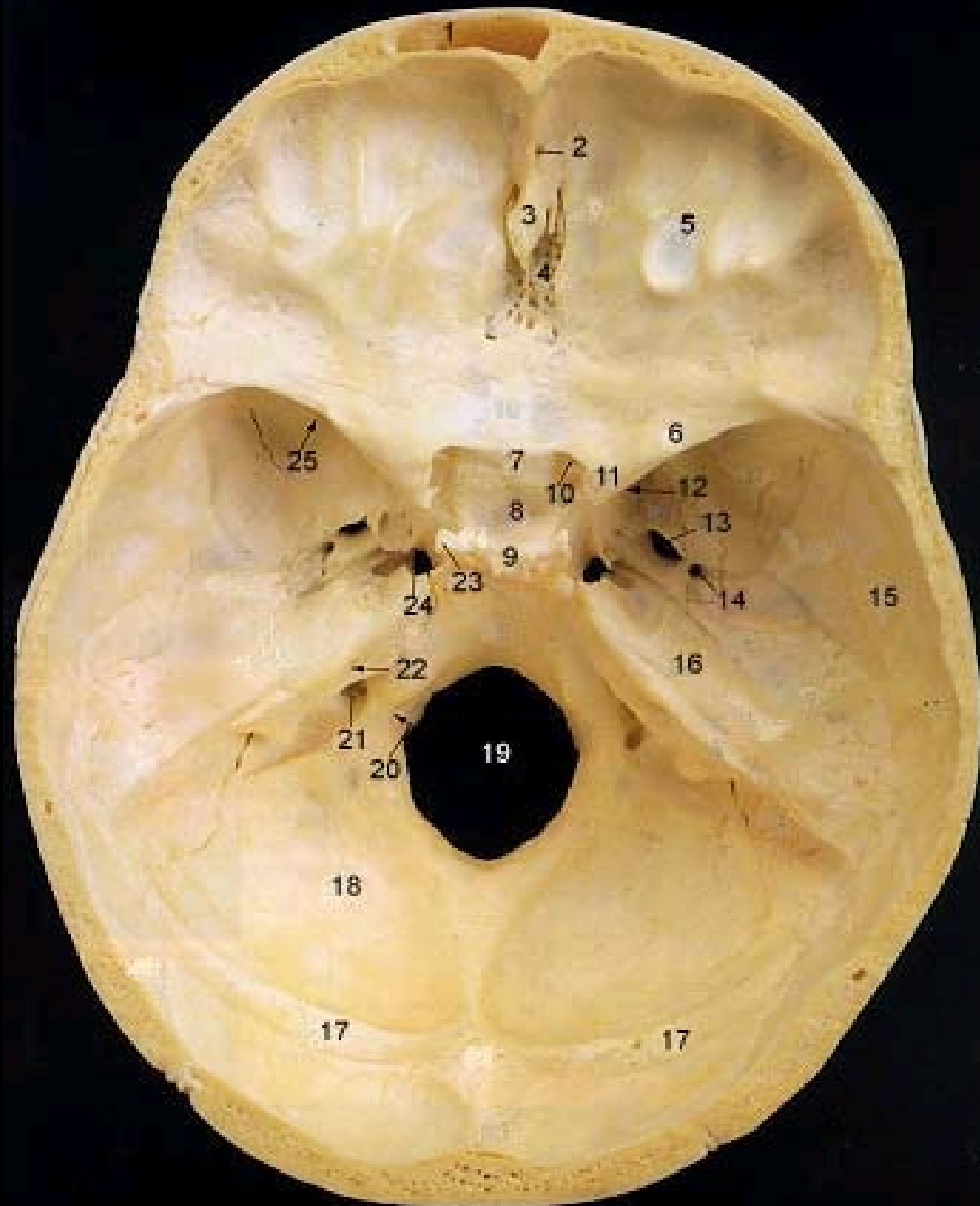




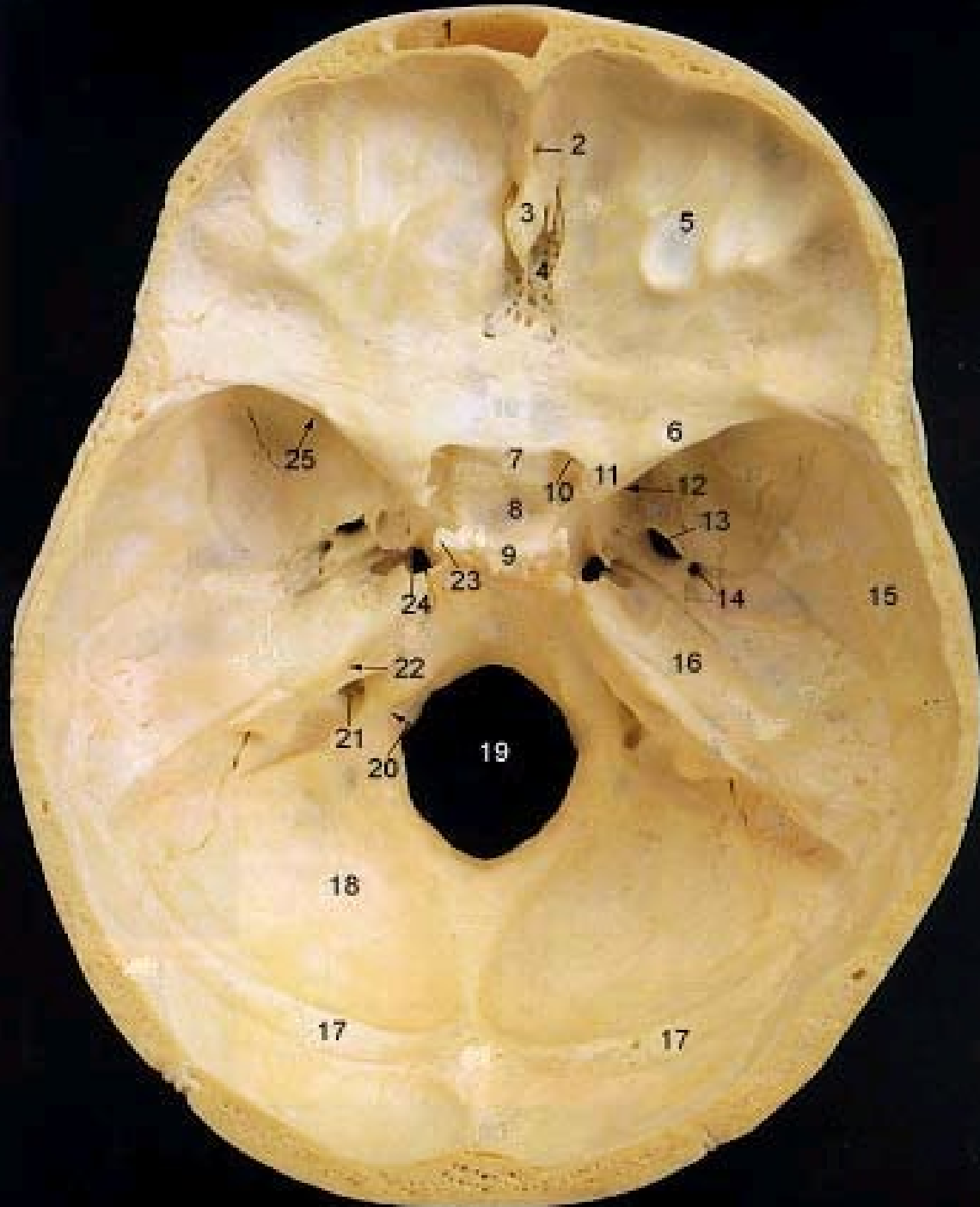
Skull, superior view





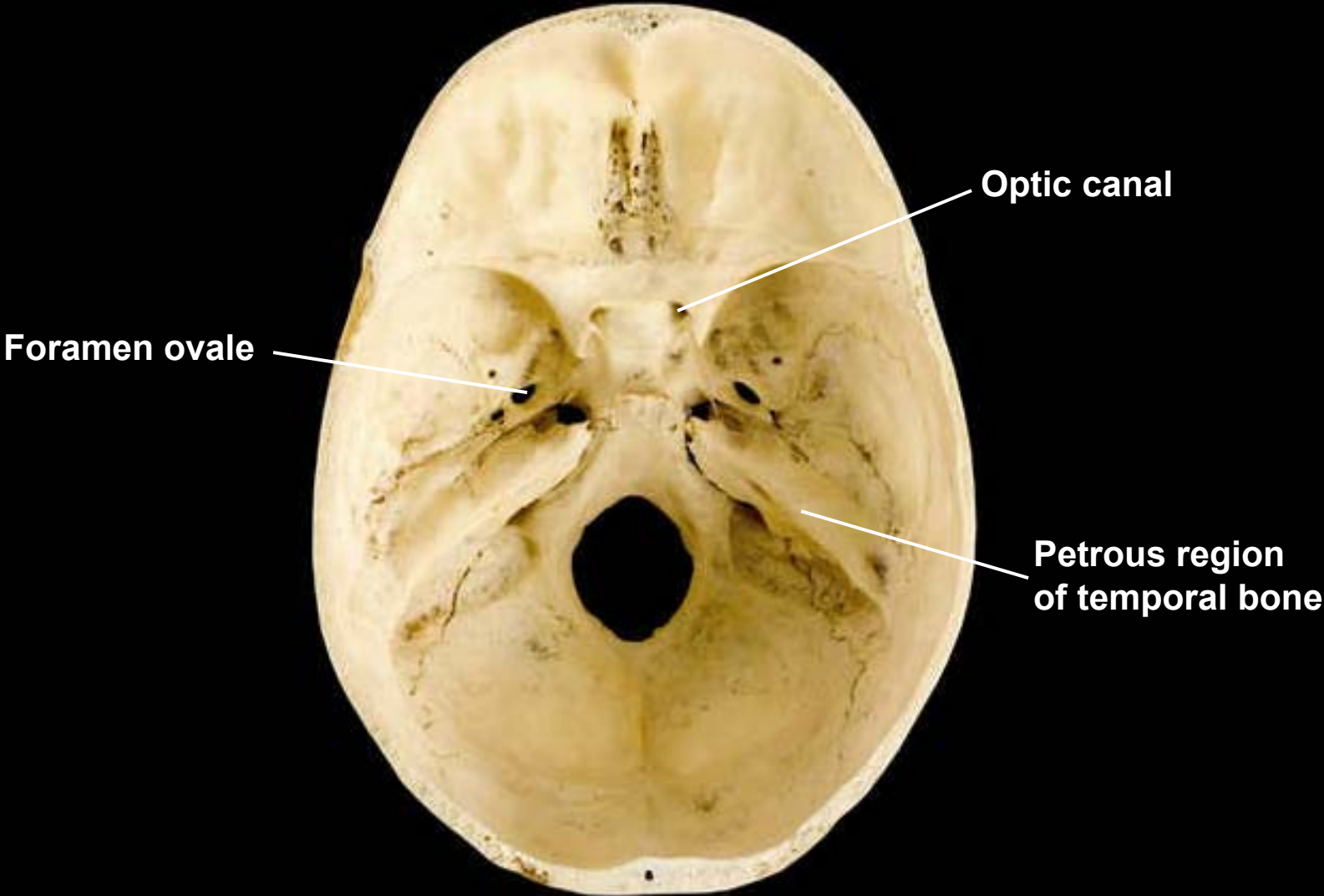


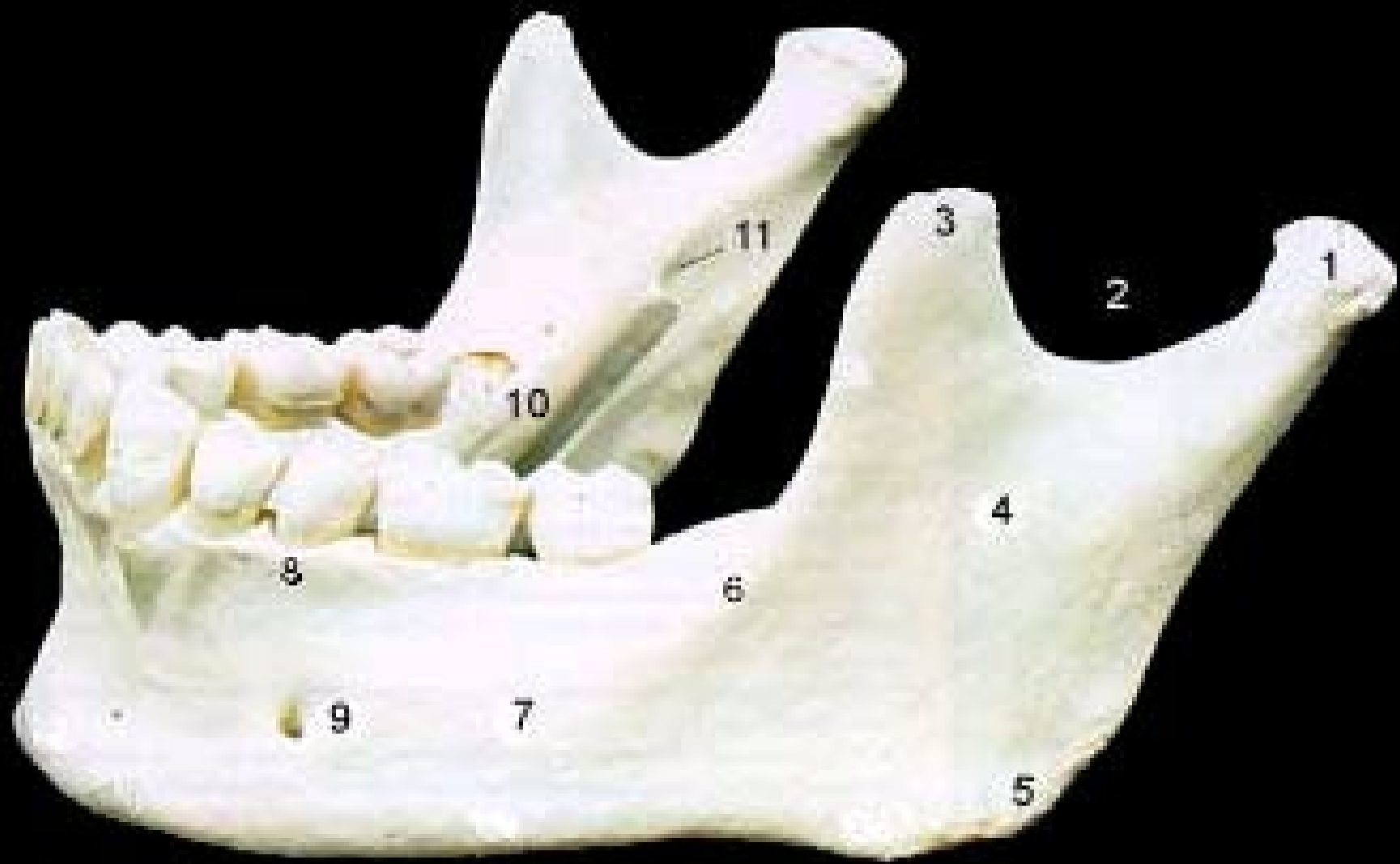1. Frontal Sinus
2. Foramen Cecum
3. Crista Galli
4. Cribriform Plate
5. Anterior Cranial Fossa
6. Lesser Wing of Sphenoid
7. Chiasmatic Groove
8. Hypophyseal Fossa
9. Dorsum Sella
10. Optic Canal
11. Anterior Clinoid Process
12. Foramen Rotundum
13. Foramen Ovale
14. Foramen Spinosum
15. Squamous Part of Temporal
16. Petrous Part of Temporal
17. Groove for Transverse Sinus
18. Posterior Cranial Fossa
19. Foramen Magnum
20. Hypoglossal Canal
21. Jugular Foramen
22. Internal Acoustic Meatus
23. Posterior Clinoid Process
24. Foramen Lacerum
25. Superior Orbital Fissure



- 20. Hypoglossal Canal
- 21. Jugular Foramen
- 22. Internal Acoustic Meatus
- 23. Posterior Clinoid Process
- 24. Foramen Lacerum
- 25. Superior Orbital Fissure

Skull, superior view of floor of cranial activity





1

2

3

4

5

6

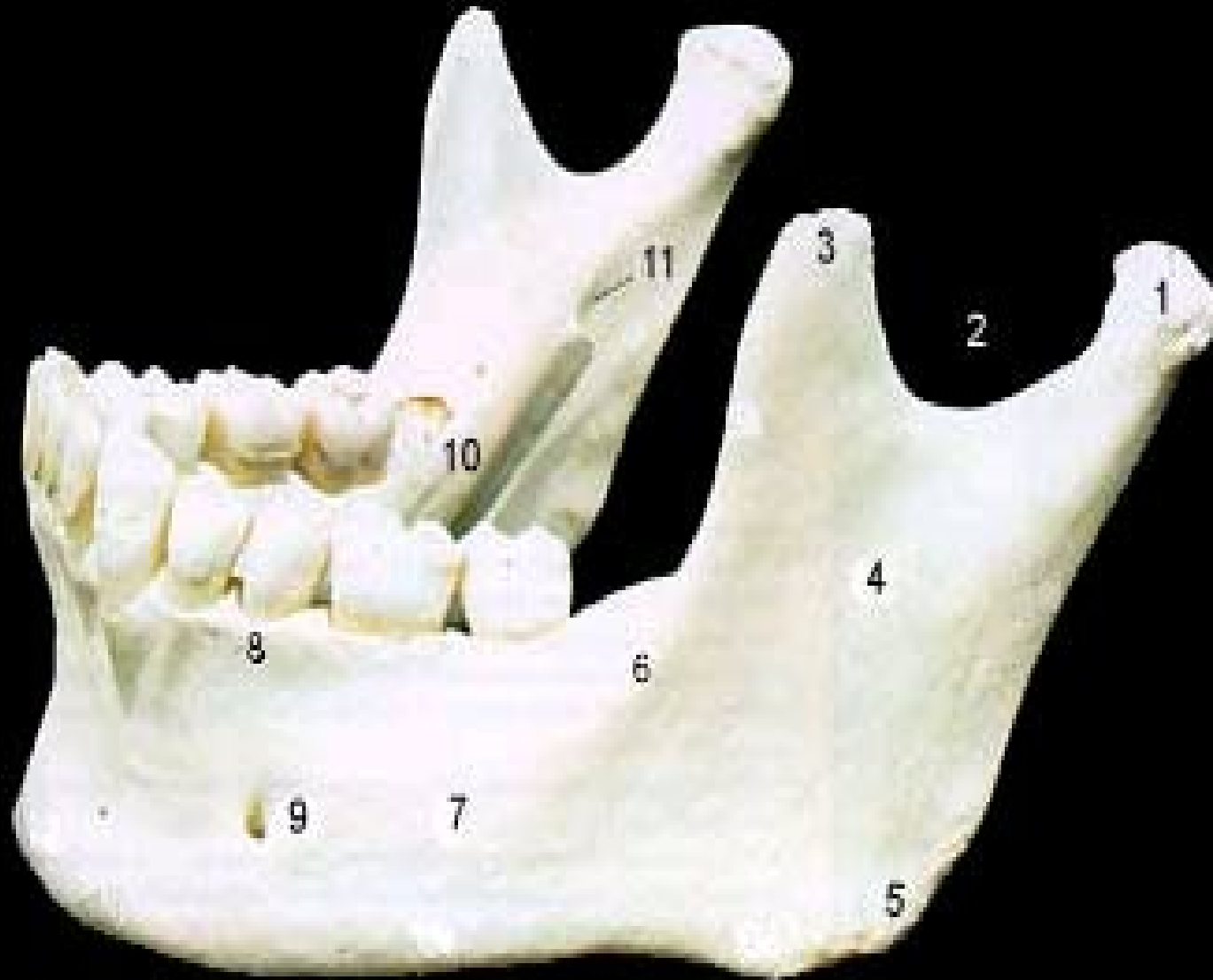7

8

9

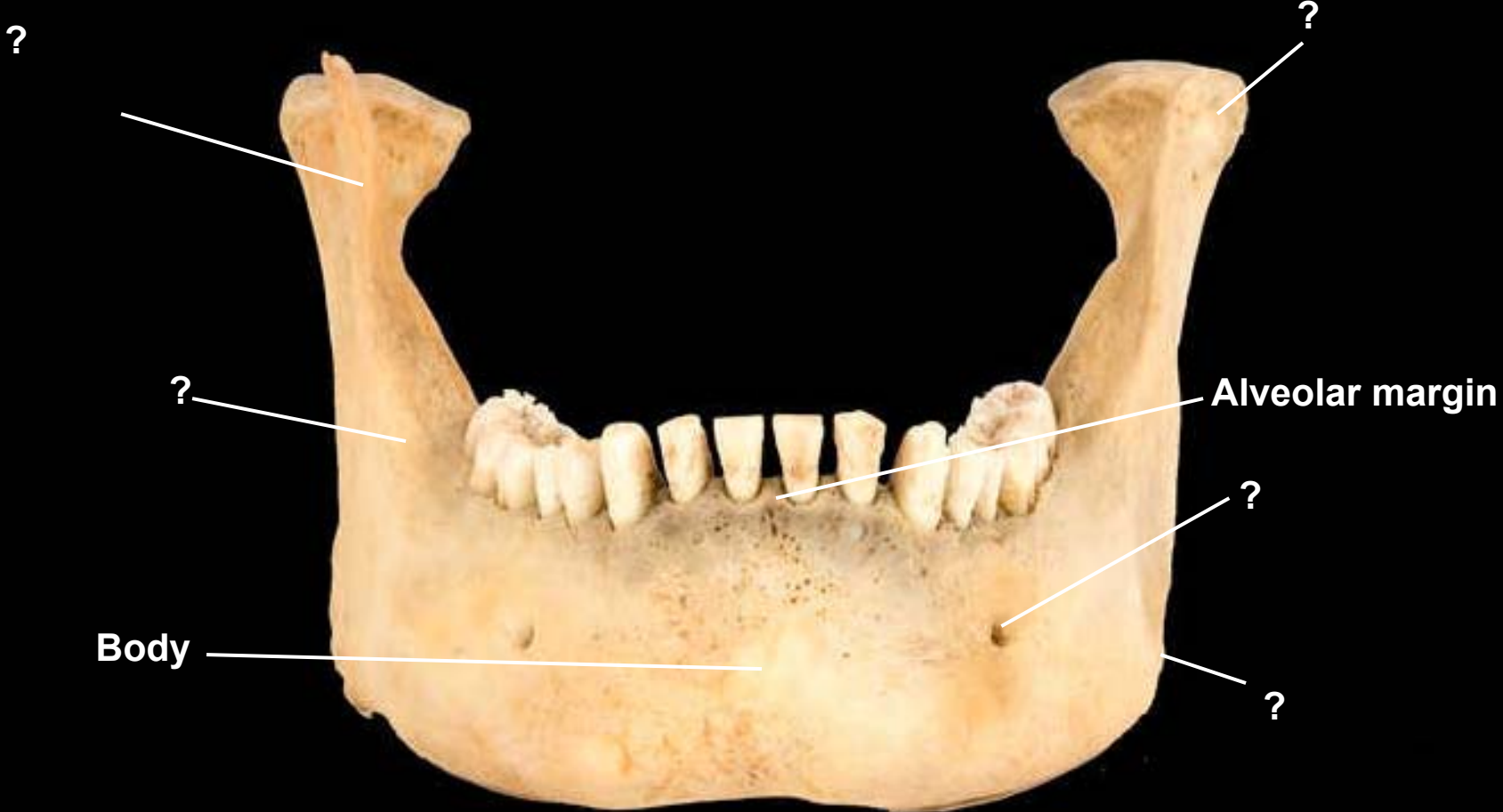10

11

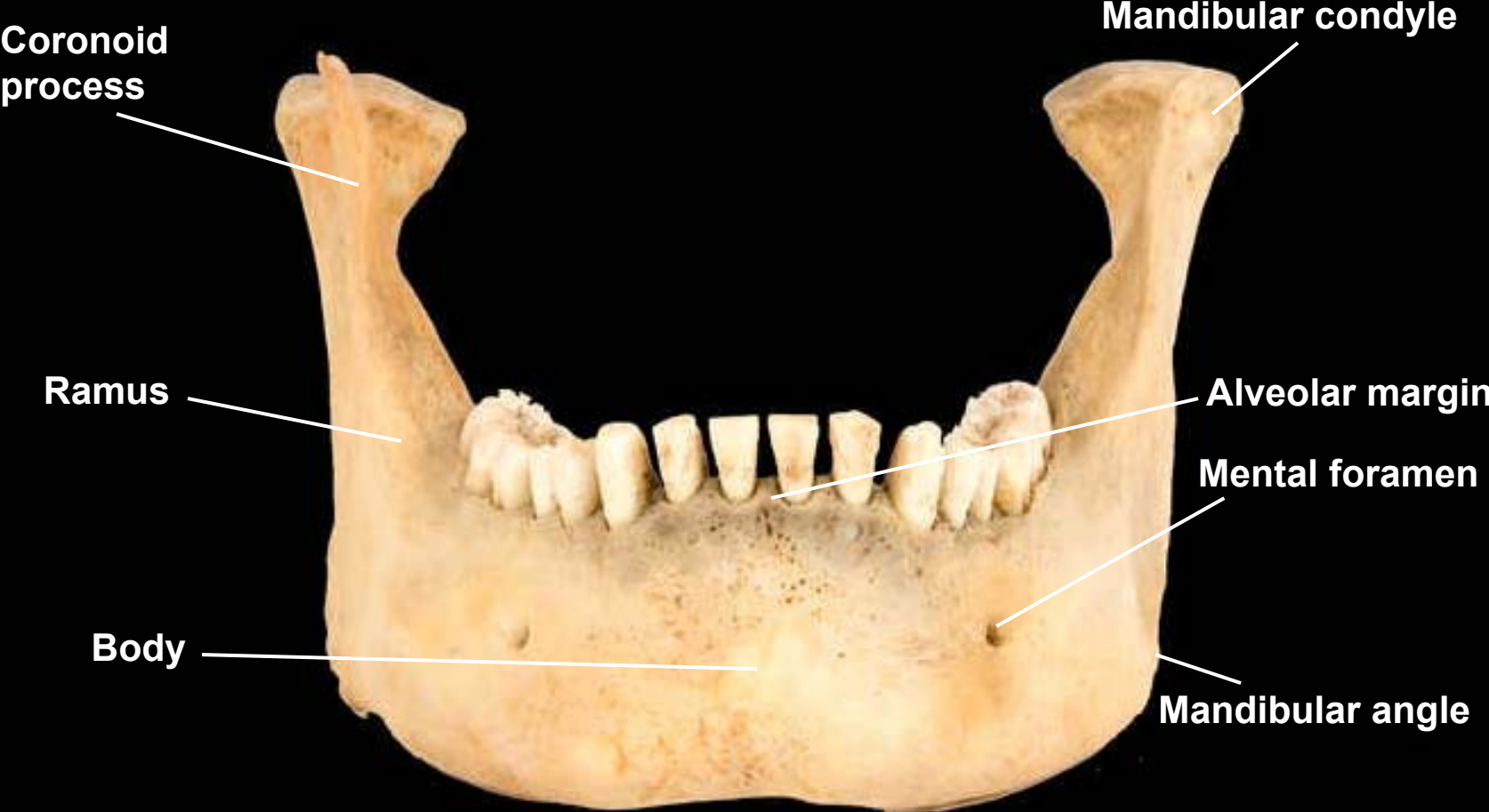

1. Mandibular Condyle
2. Mandibular Notch
3. Coronoid Process
4. Ramus
5. Angle
6. Oblique Line
7. Body
8. Alveolar Process
9. Mental Foramen
10. Mylohyoid Line
11. Mandibular Foramen

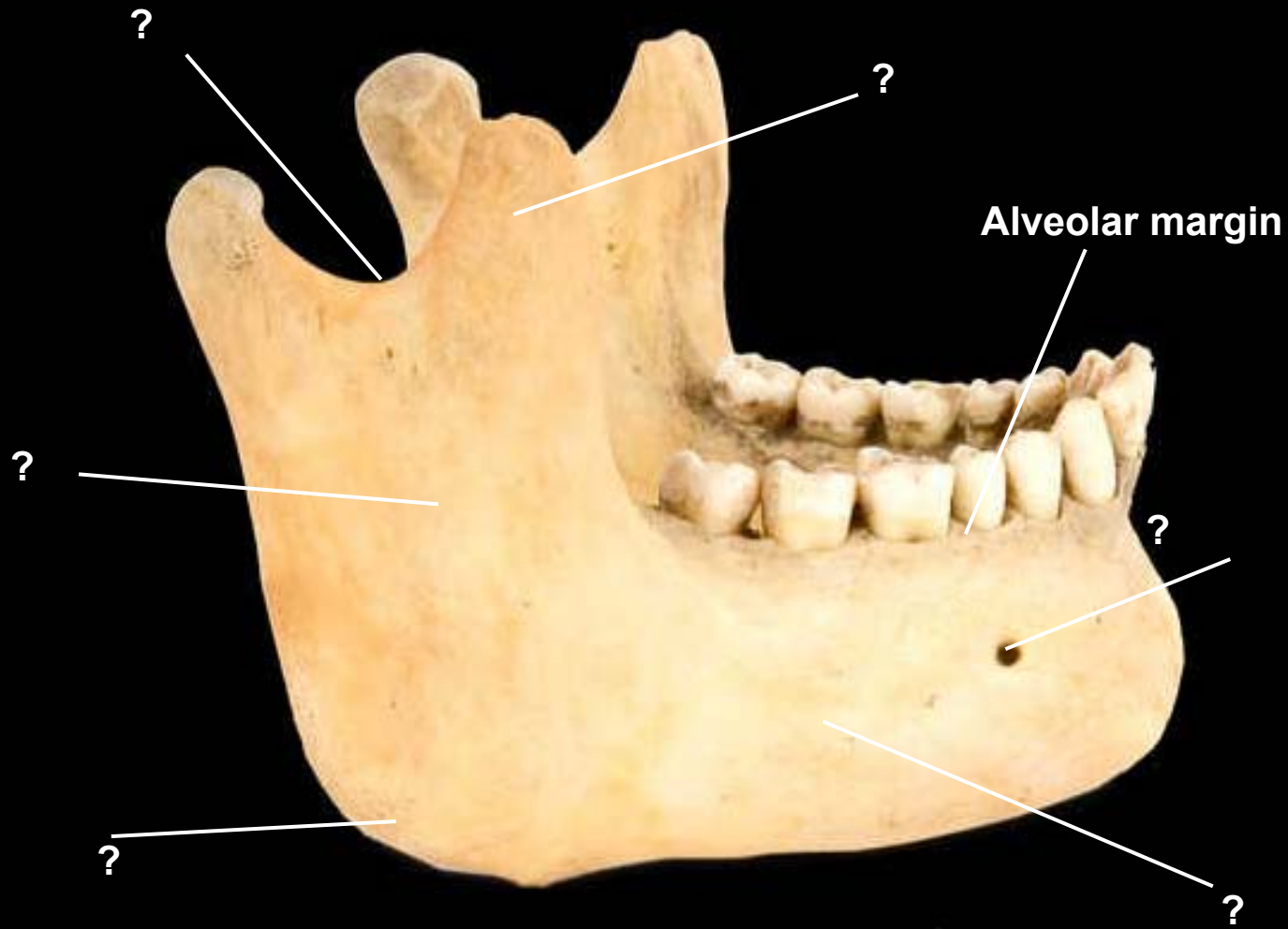
Mandible, anterior view



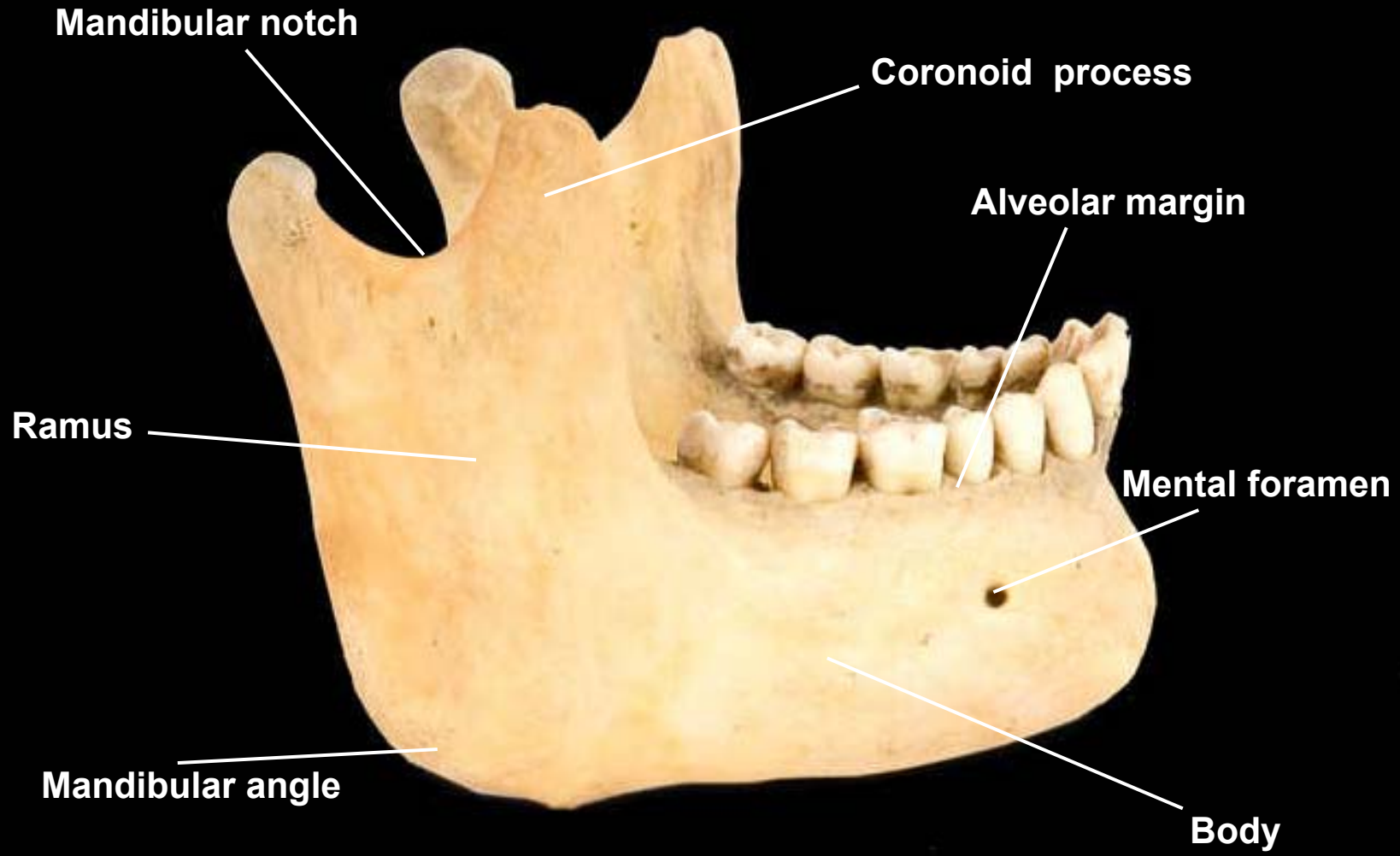
Mandible, anterior view



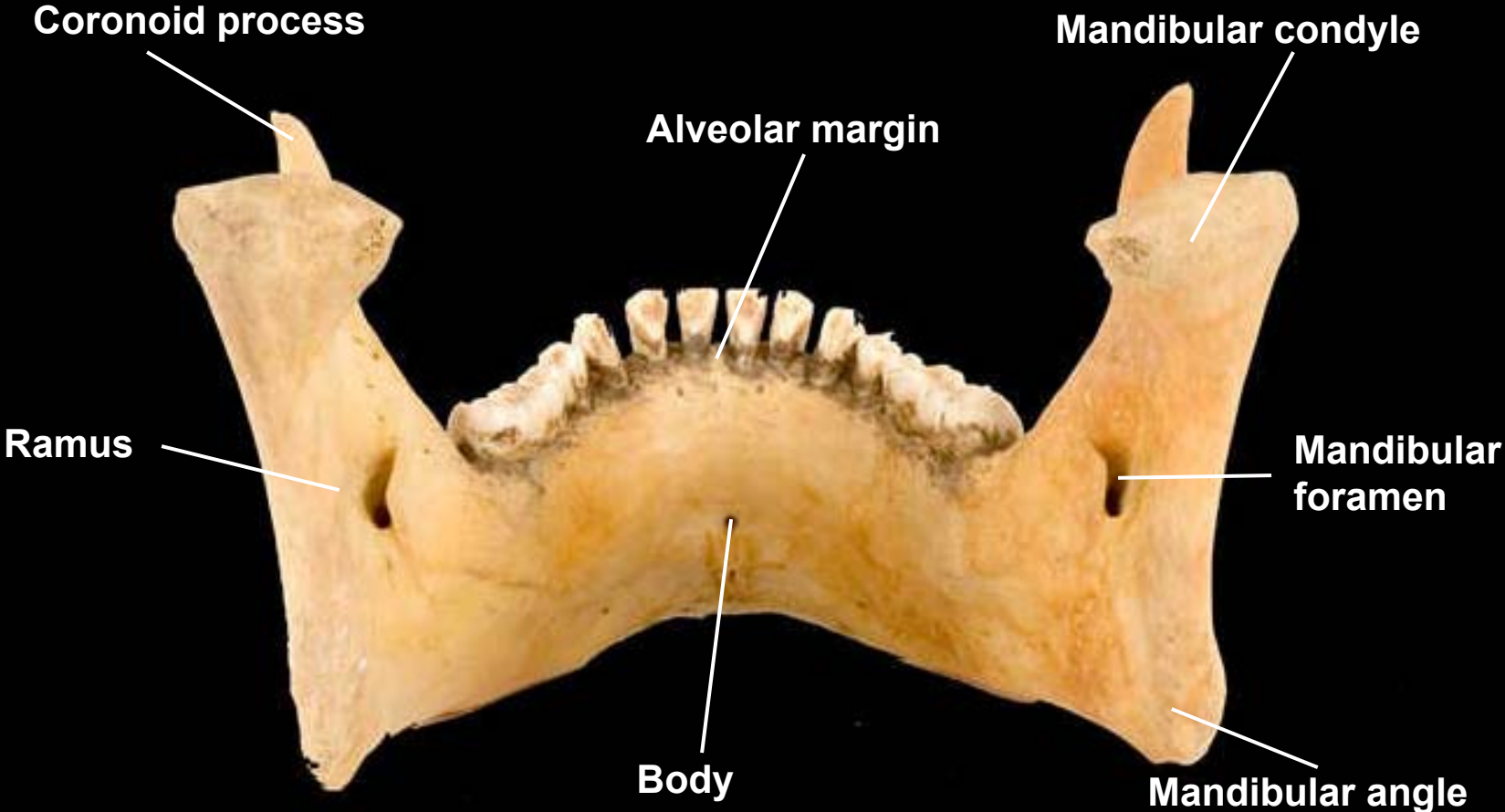
Mandible, lateral view, right side

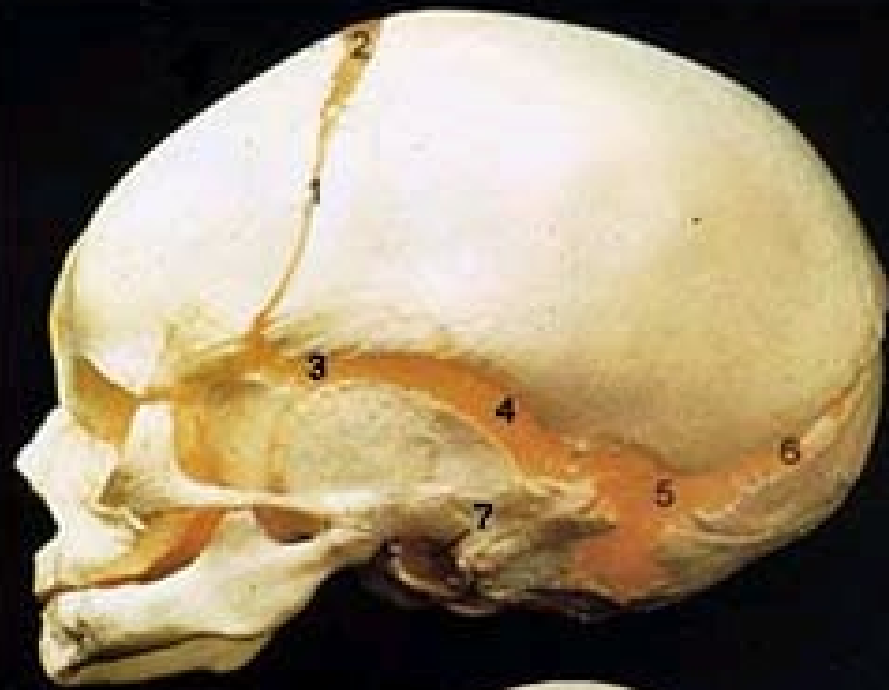

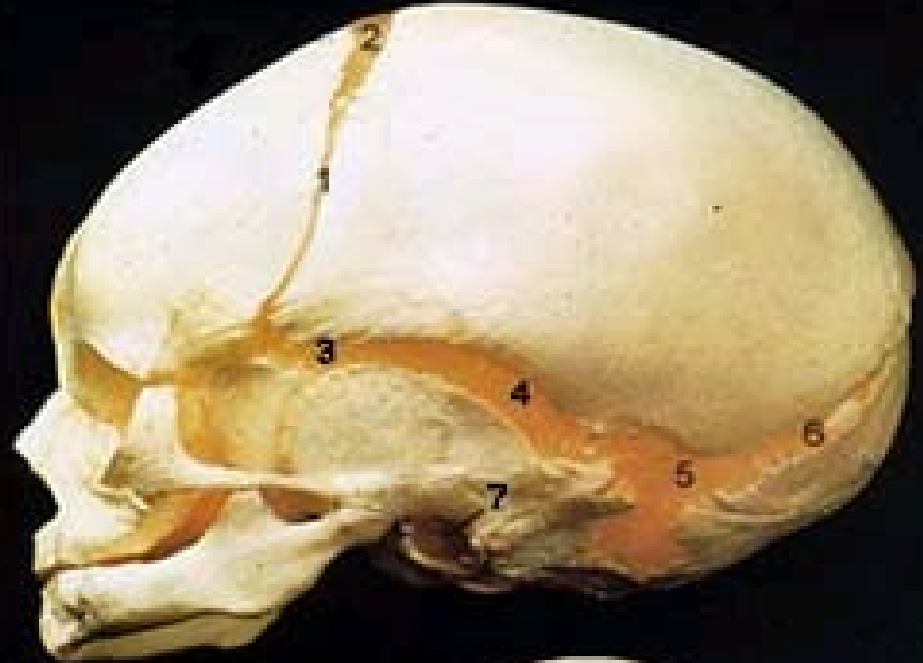Mandible, lateral view, right side




Mandible, posterior view

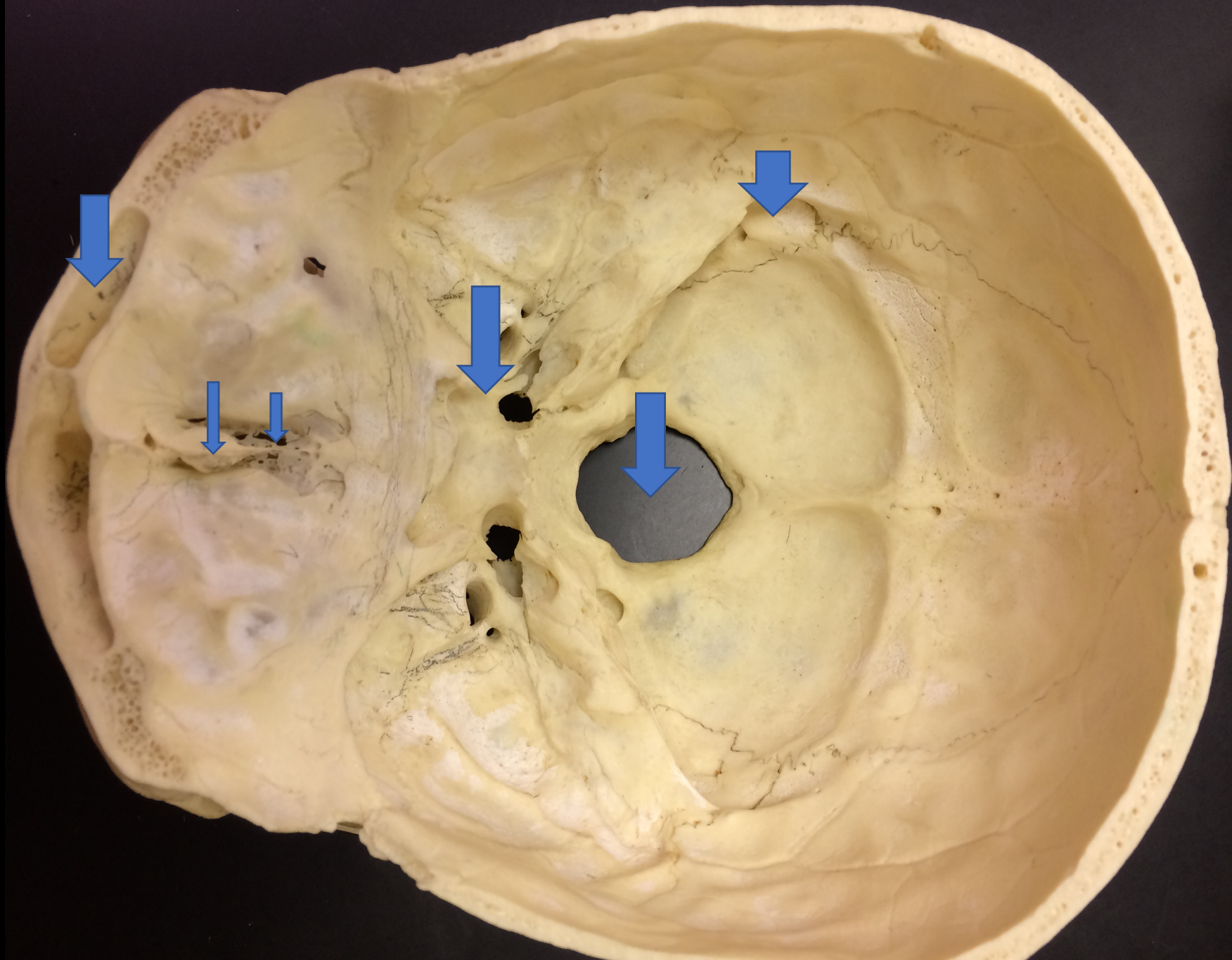


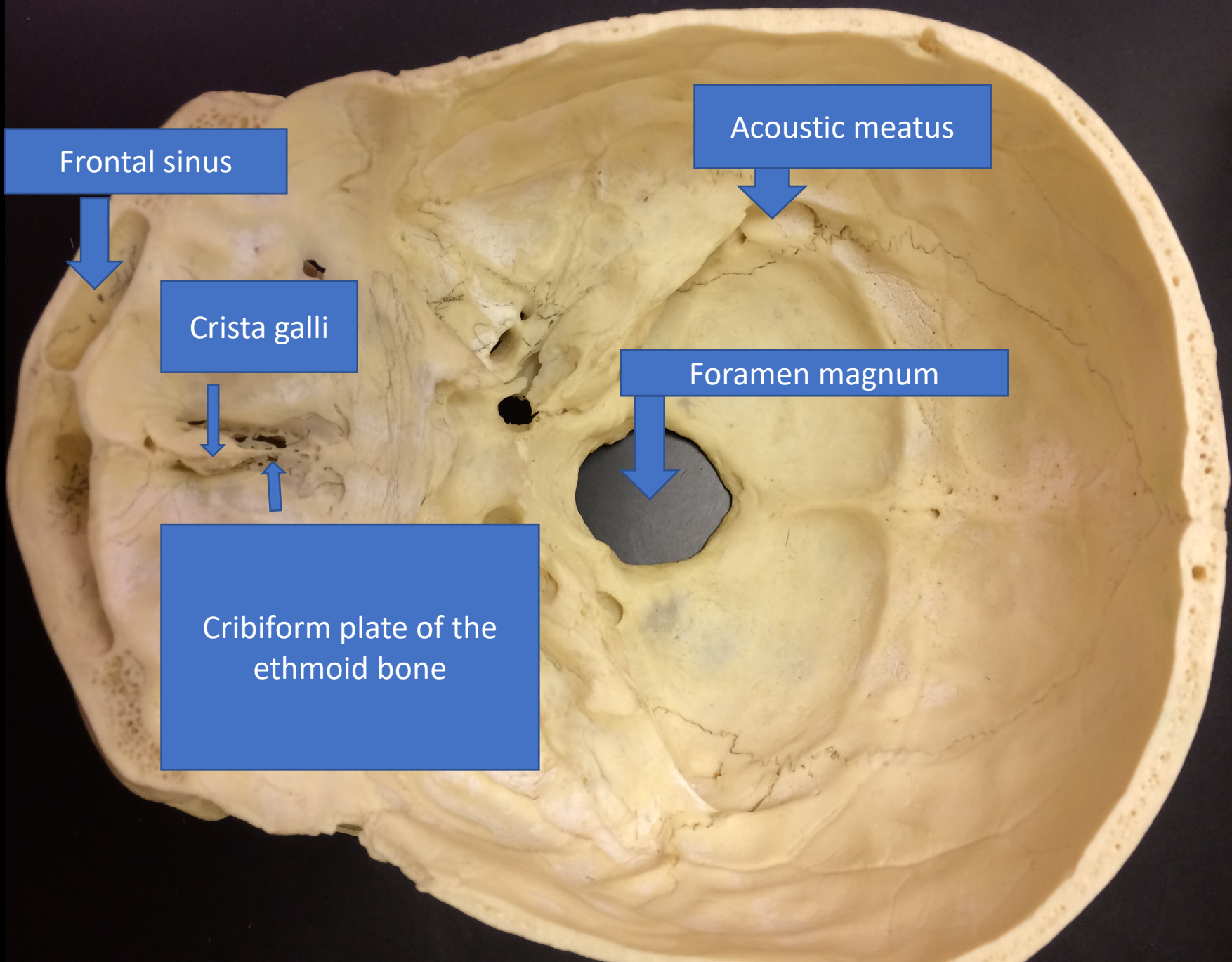




2. Anterior Fontanel







Frontal sinus



Crista galli



Cribiform plate of the ethmoid bone


Acoustic meatus

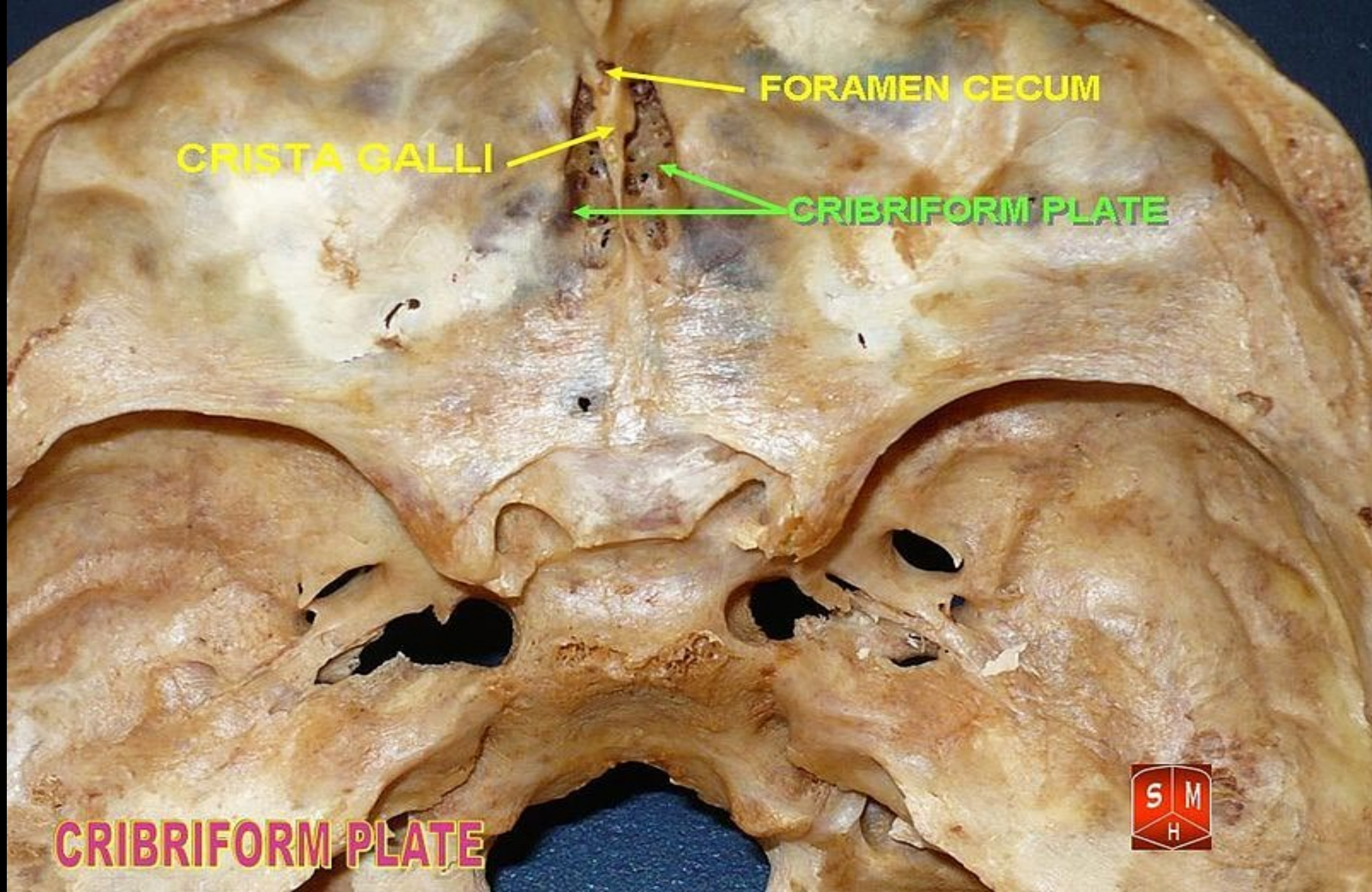


Foramen magnum



FORAMEN CECUM





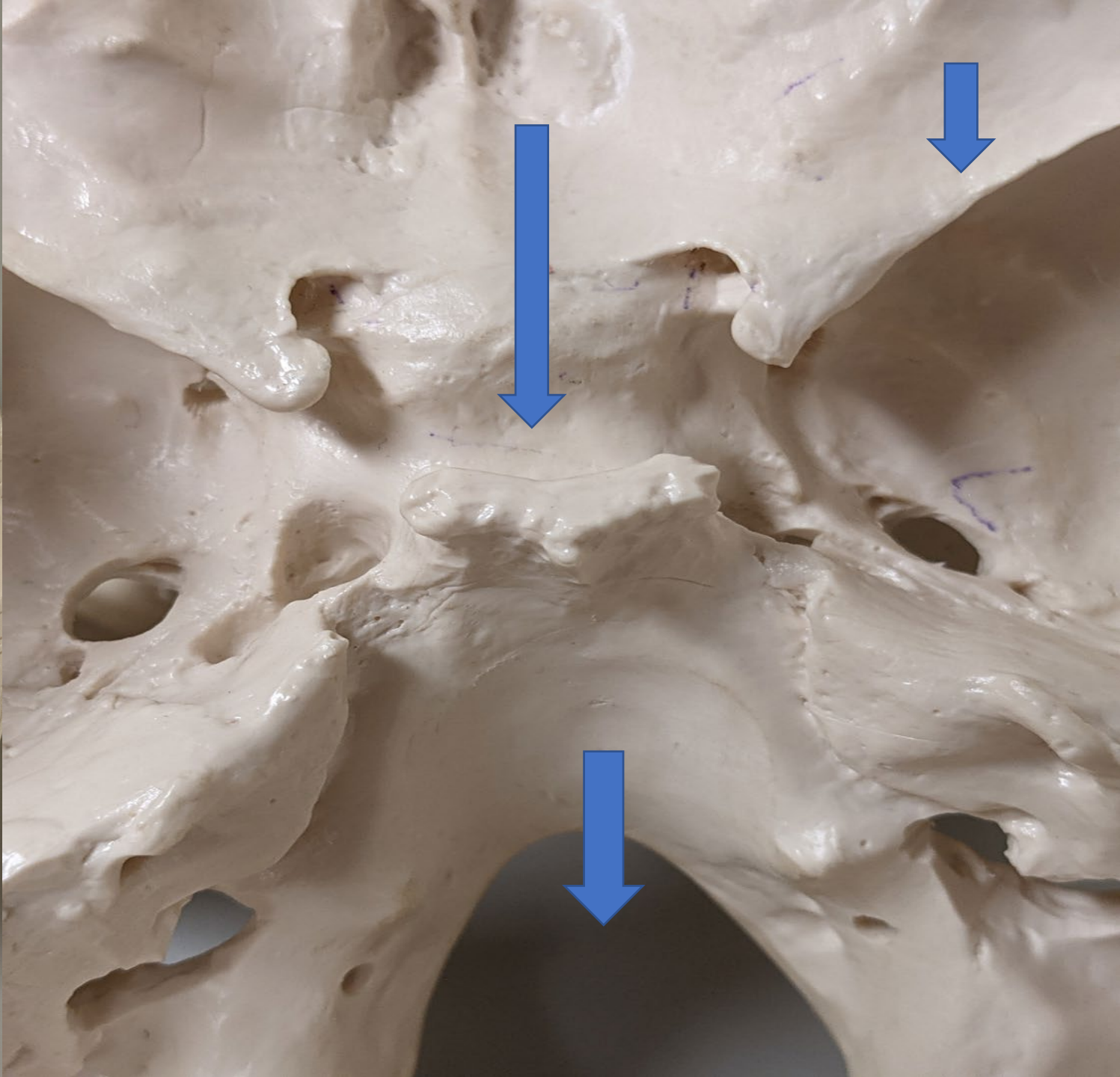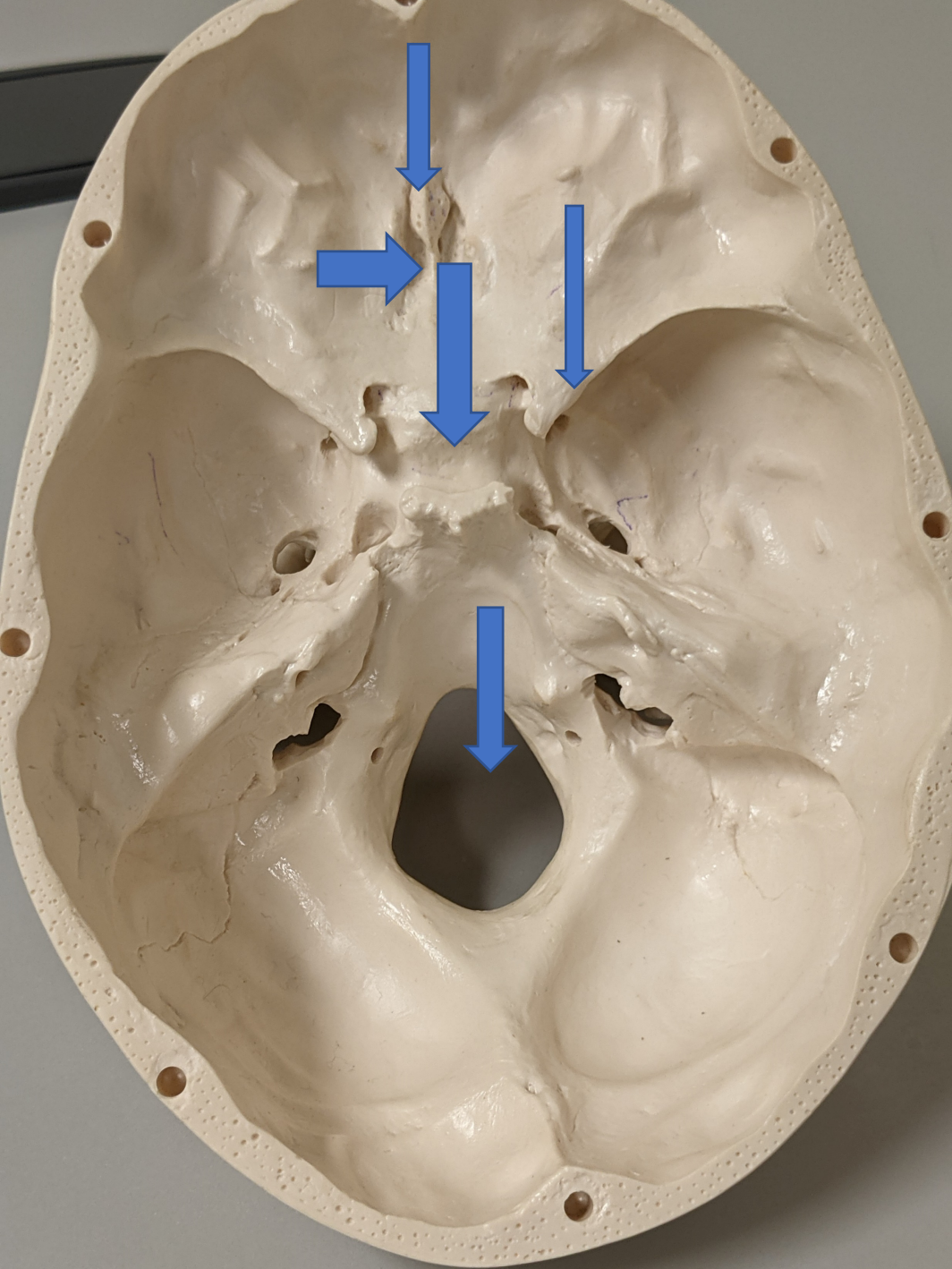
FORAMEN CECUM

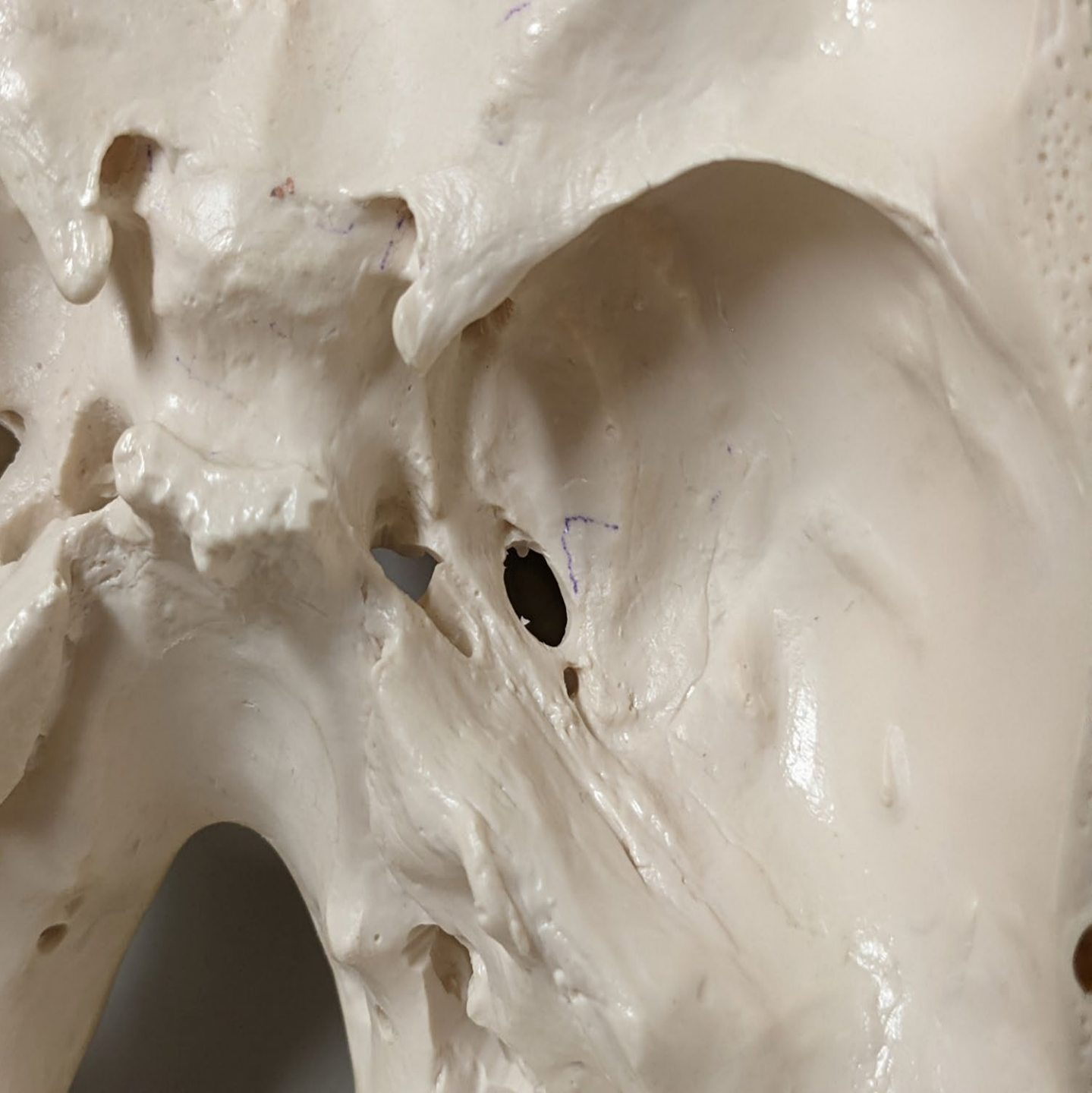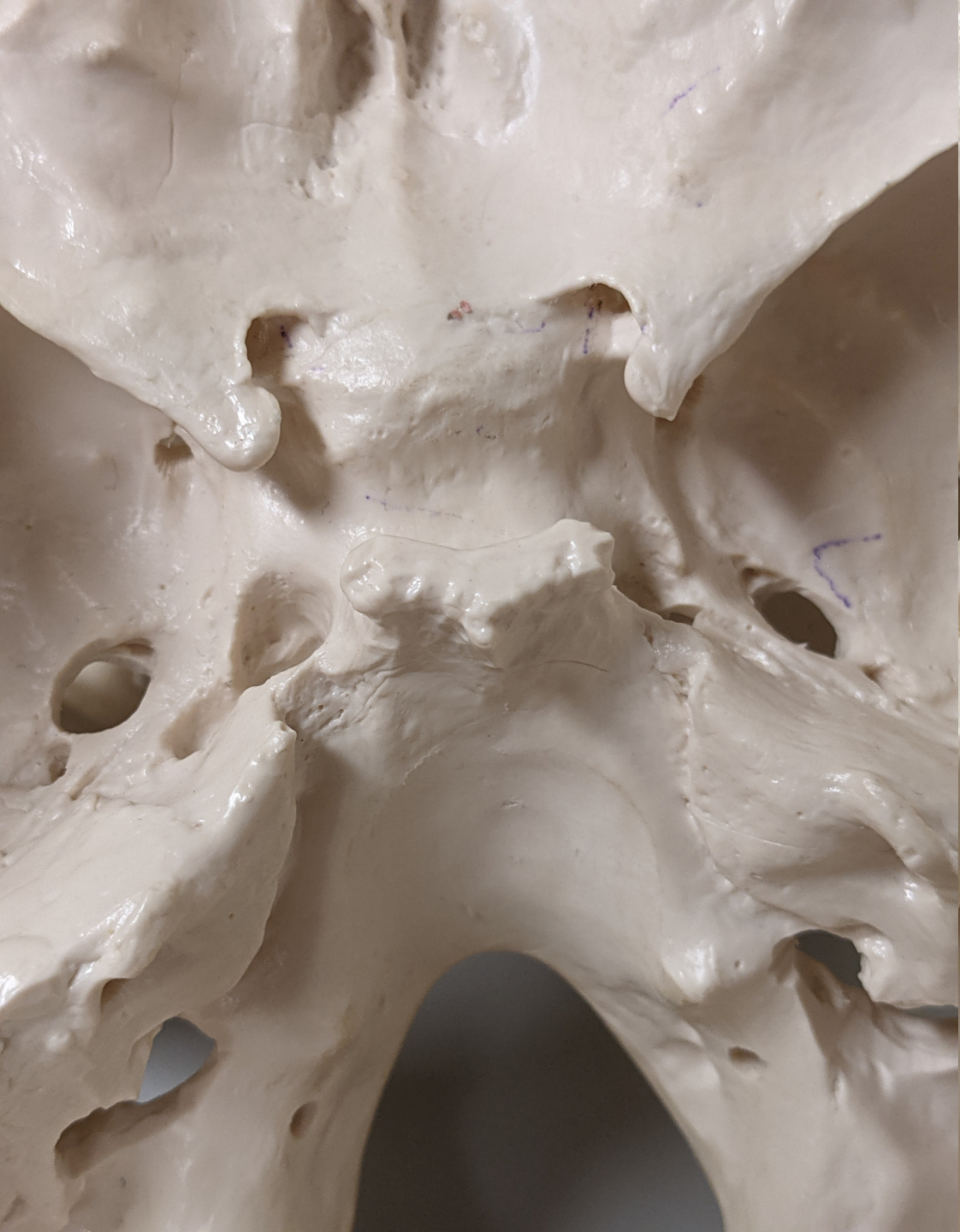CRISTA GALLI

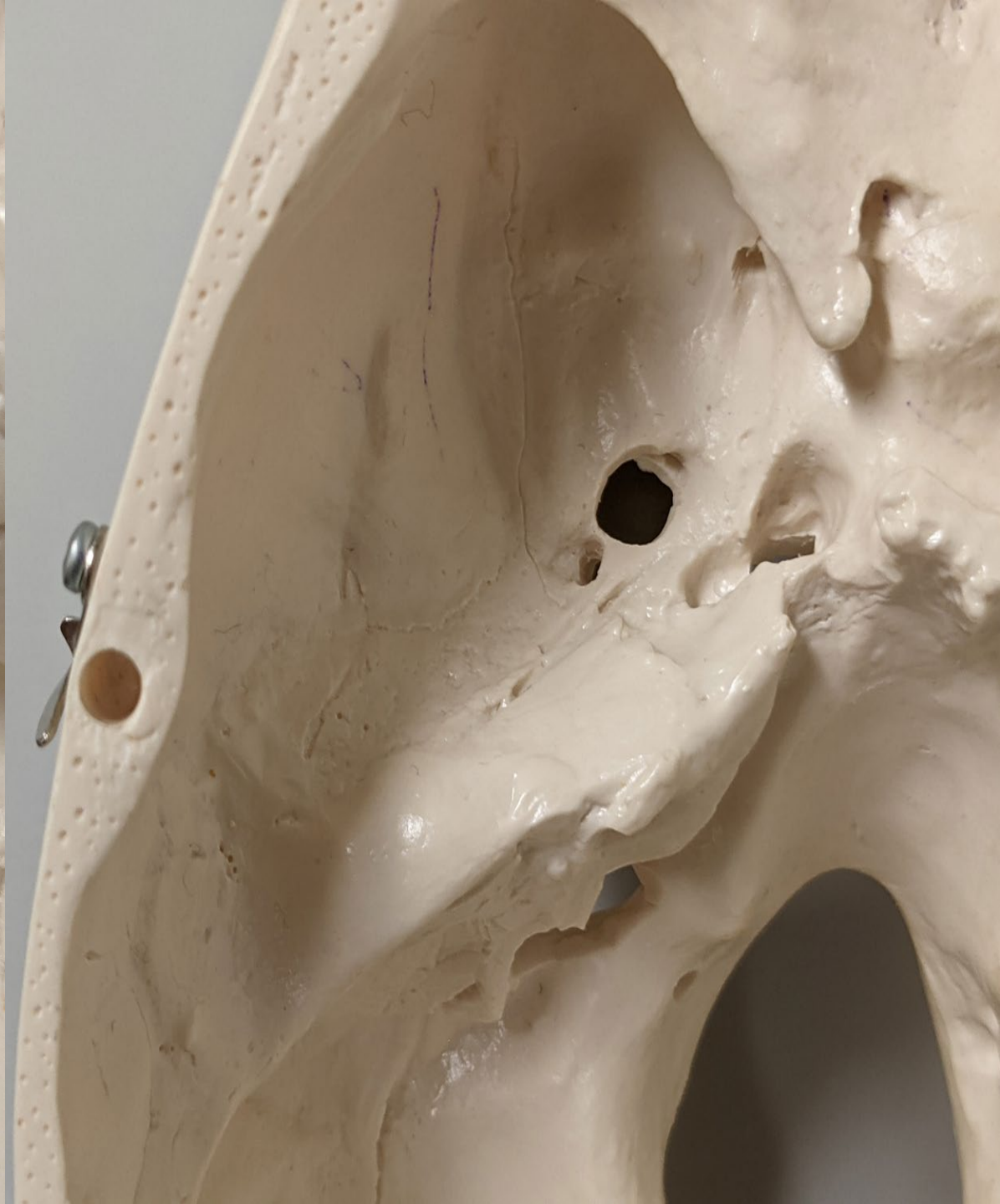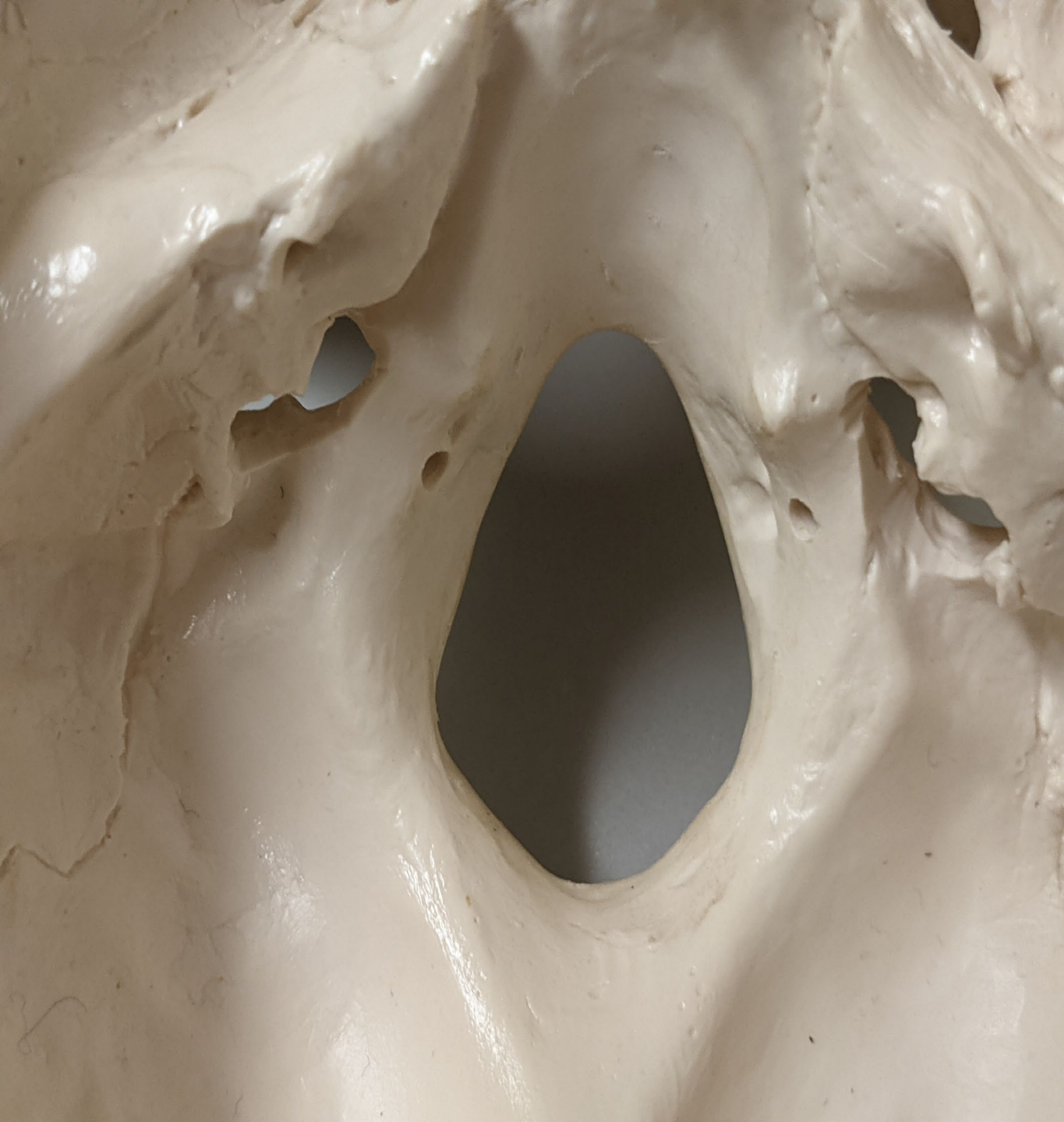CRIBRIFORM PLATE

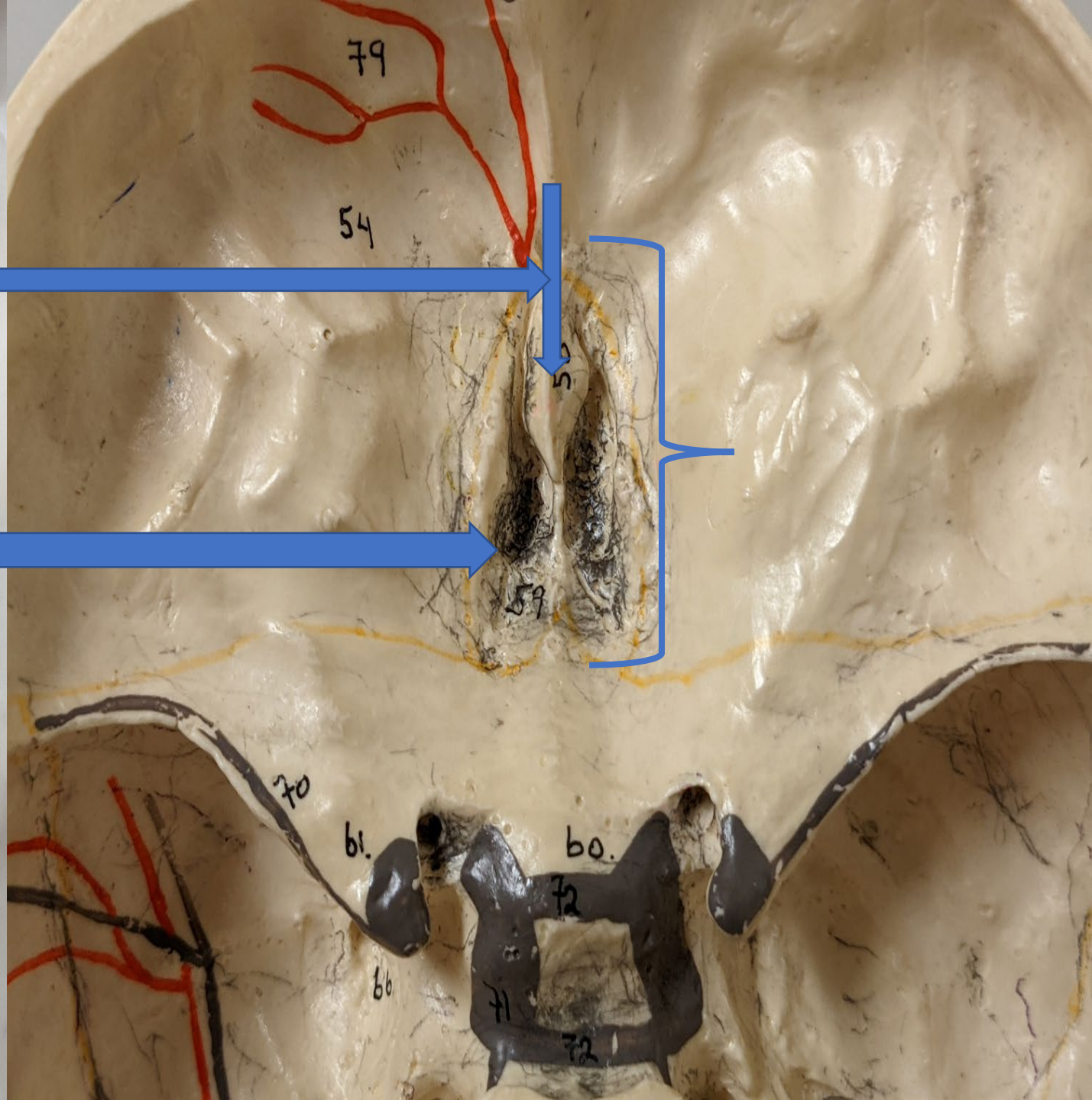
CRIBRIFORM PLATE



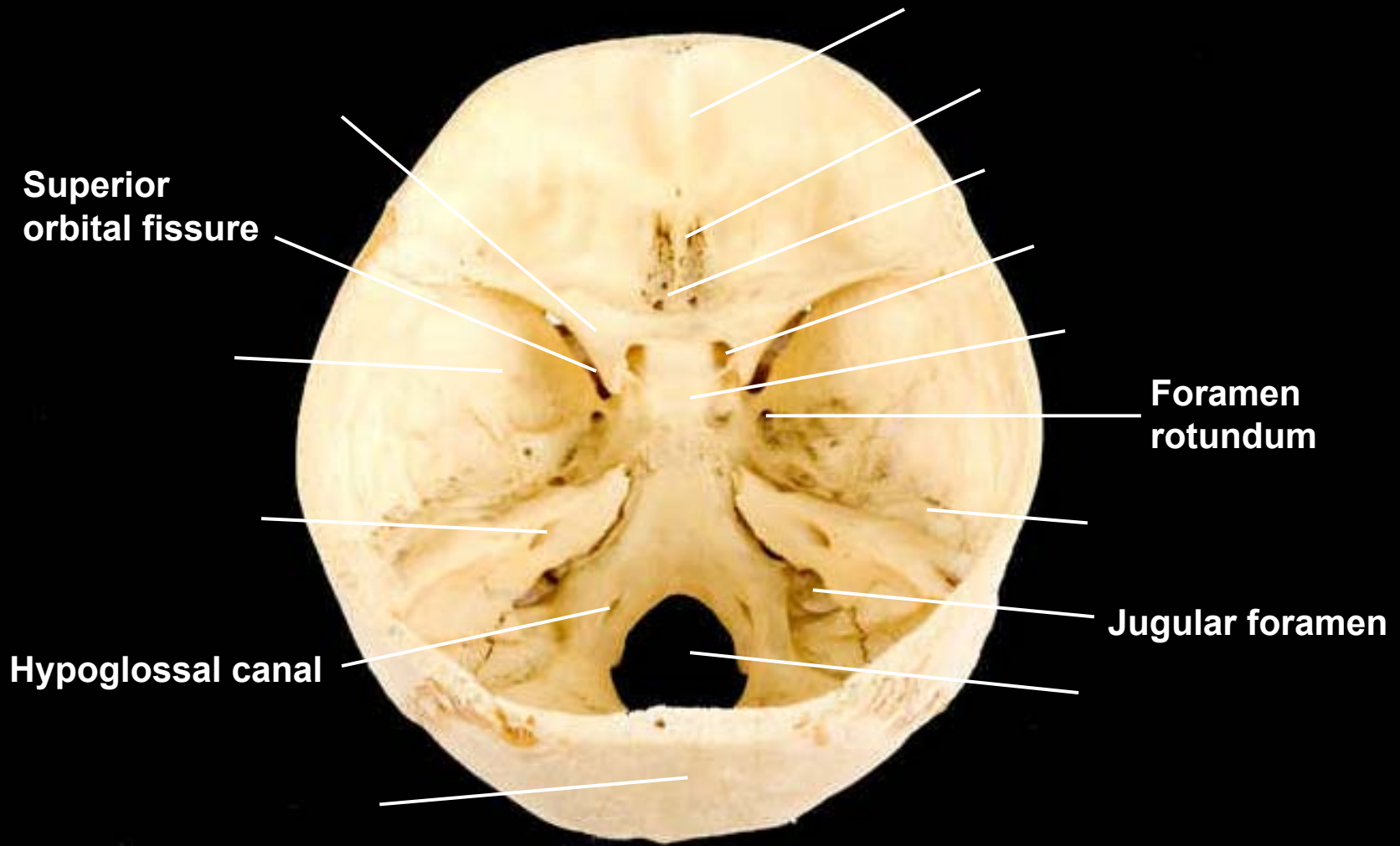




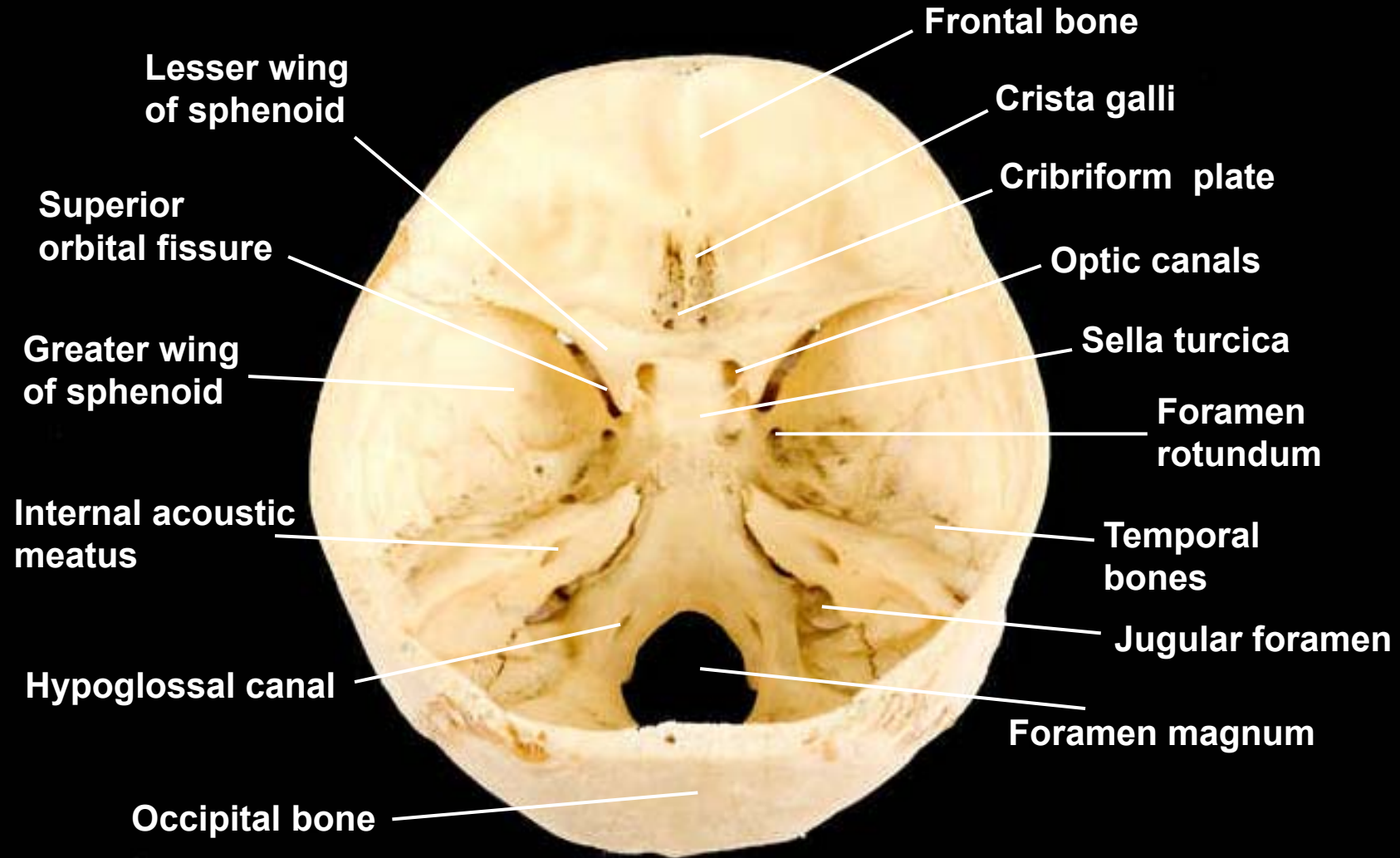




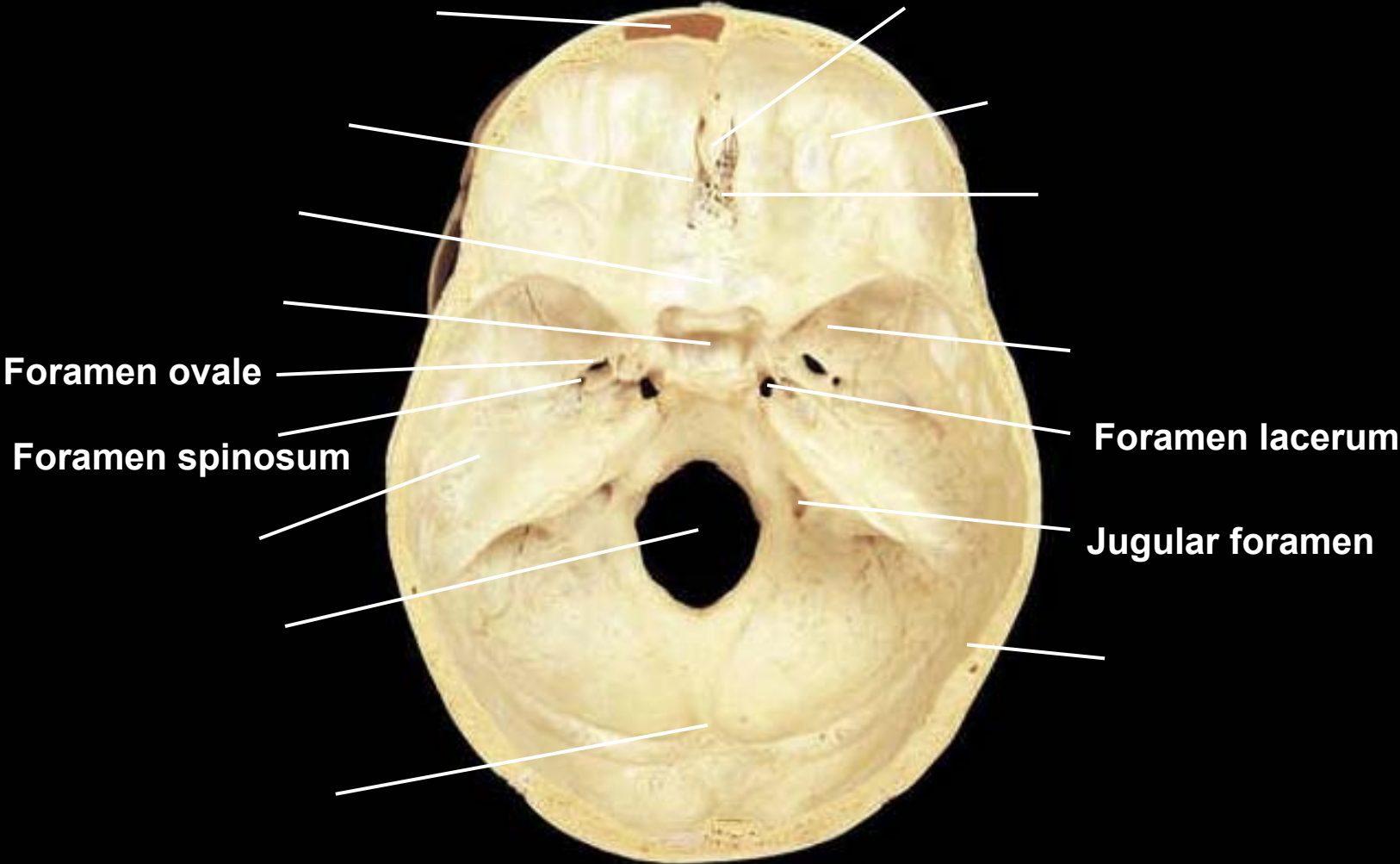
Skull, posterosuperior view of floor of cranial cavity



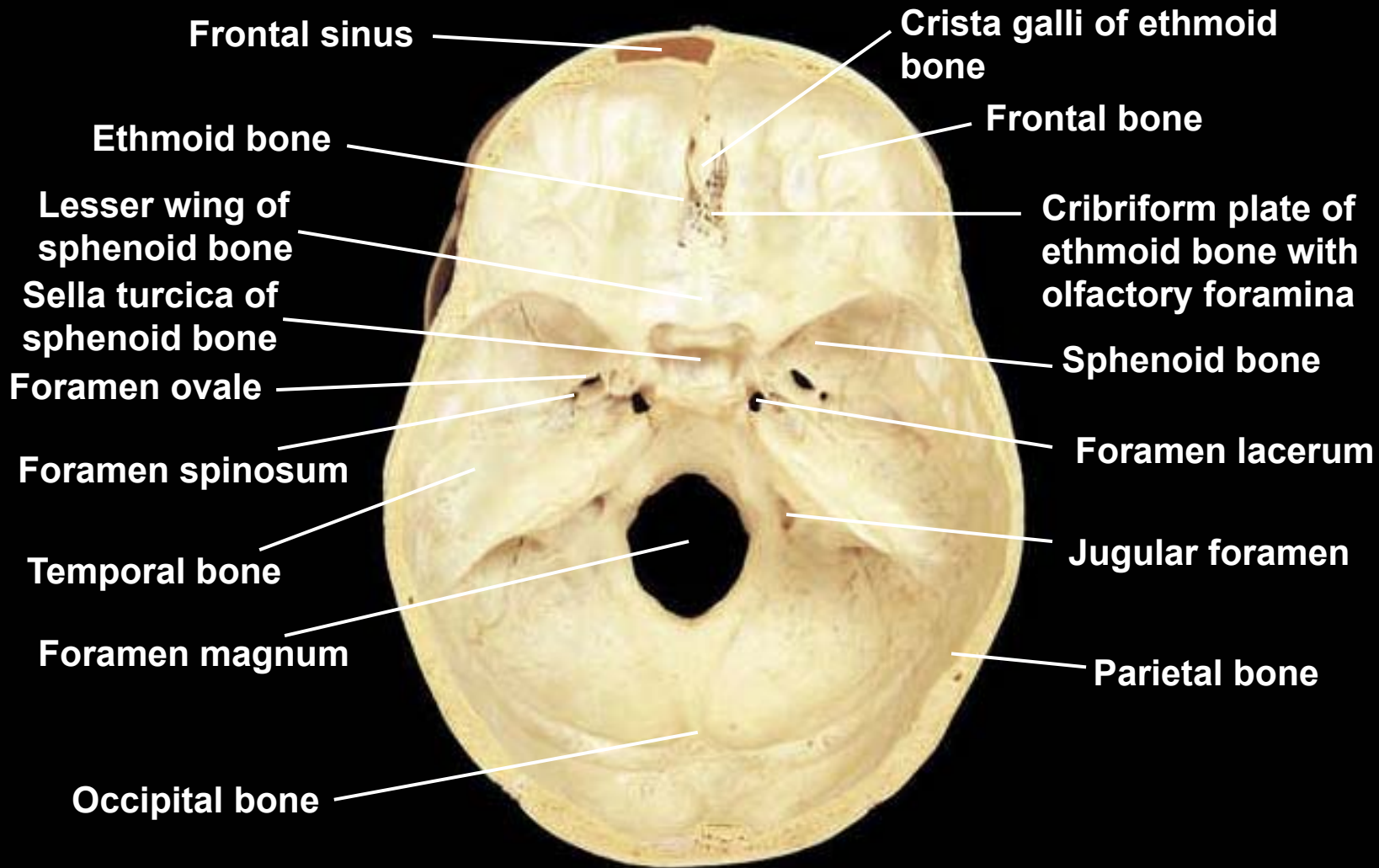
Skull, posterosuperior view of floor of cranial cavity



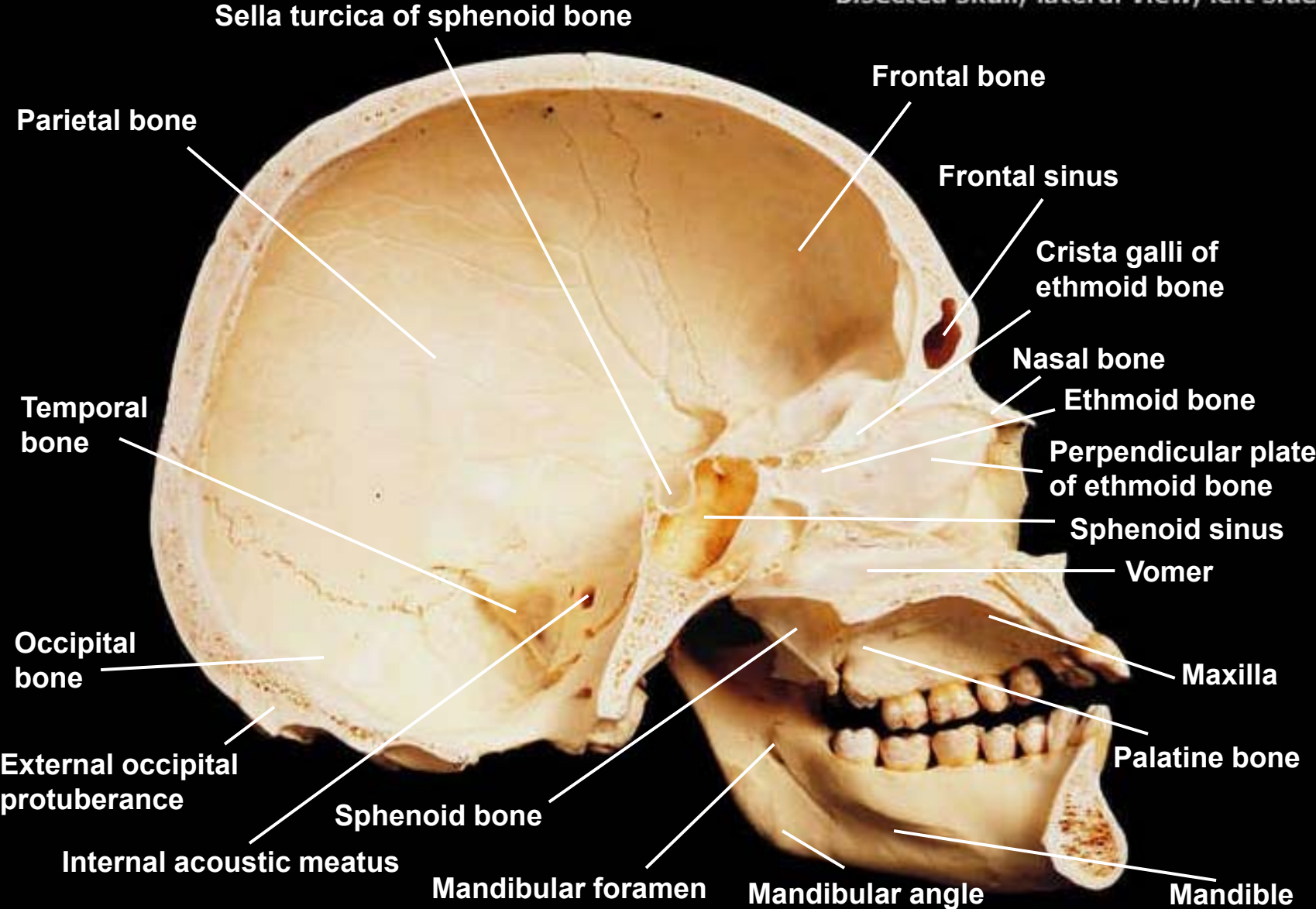
Skull, superior view of floor of cranial cavity



Skull, superior view of floor of cranial cavity



Bisected skull, lateral view, left side



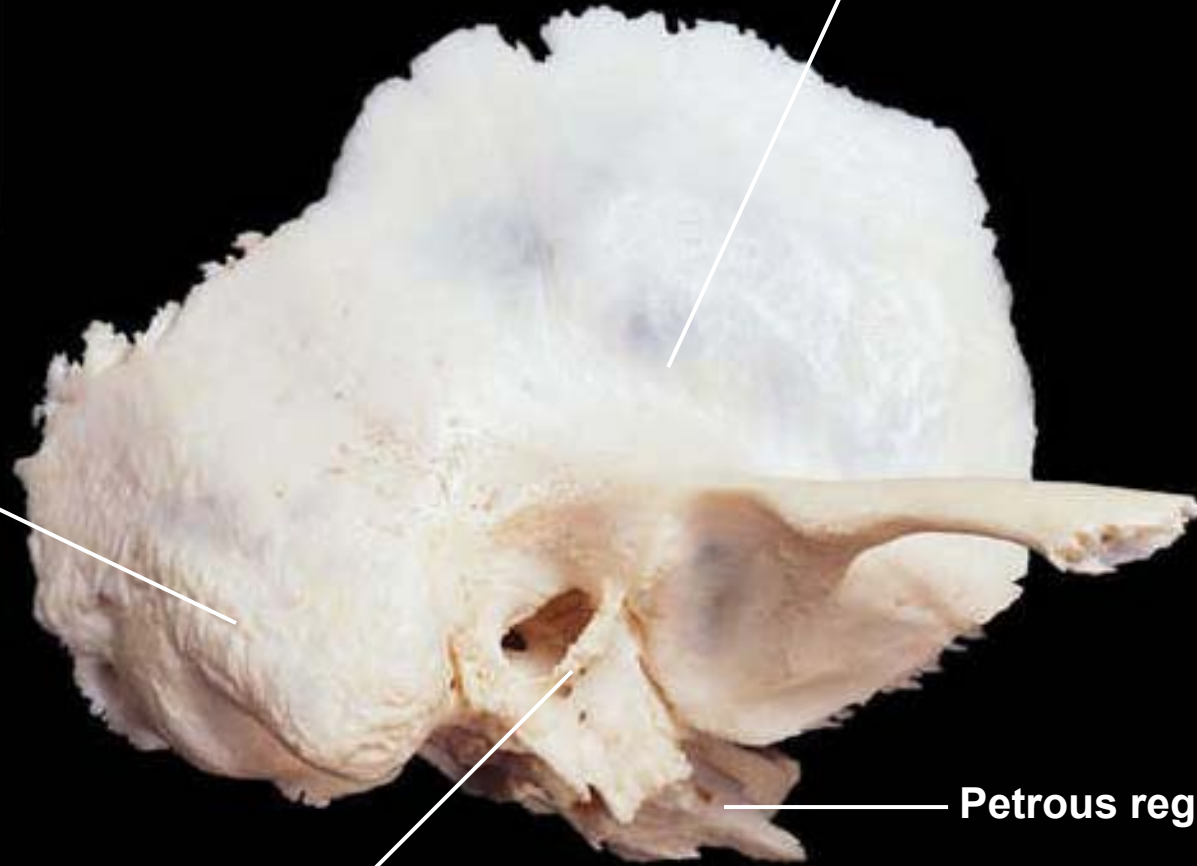
What bone is this one?

Squamous region

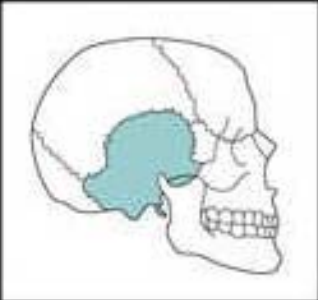
Mastoid region

Tympanic region

Petrous region



Temporal, lateral view, right side

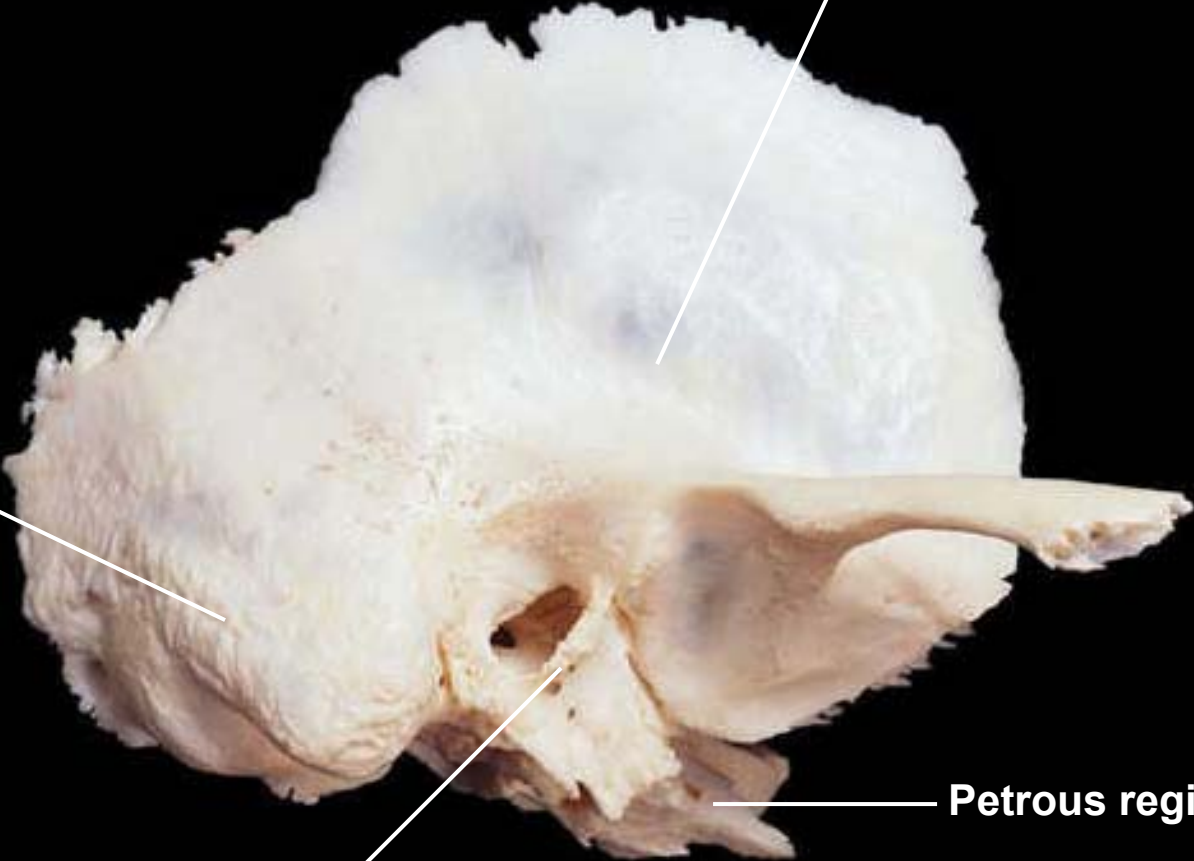


Squamous region

Mastoid region

Tympanic region

Petrous region



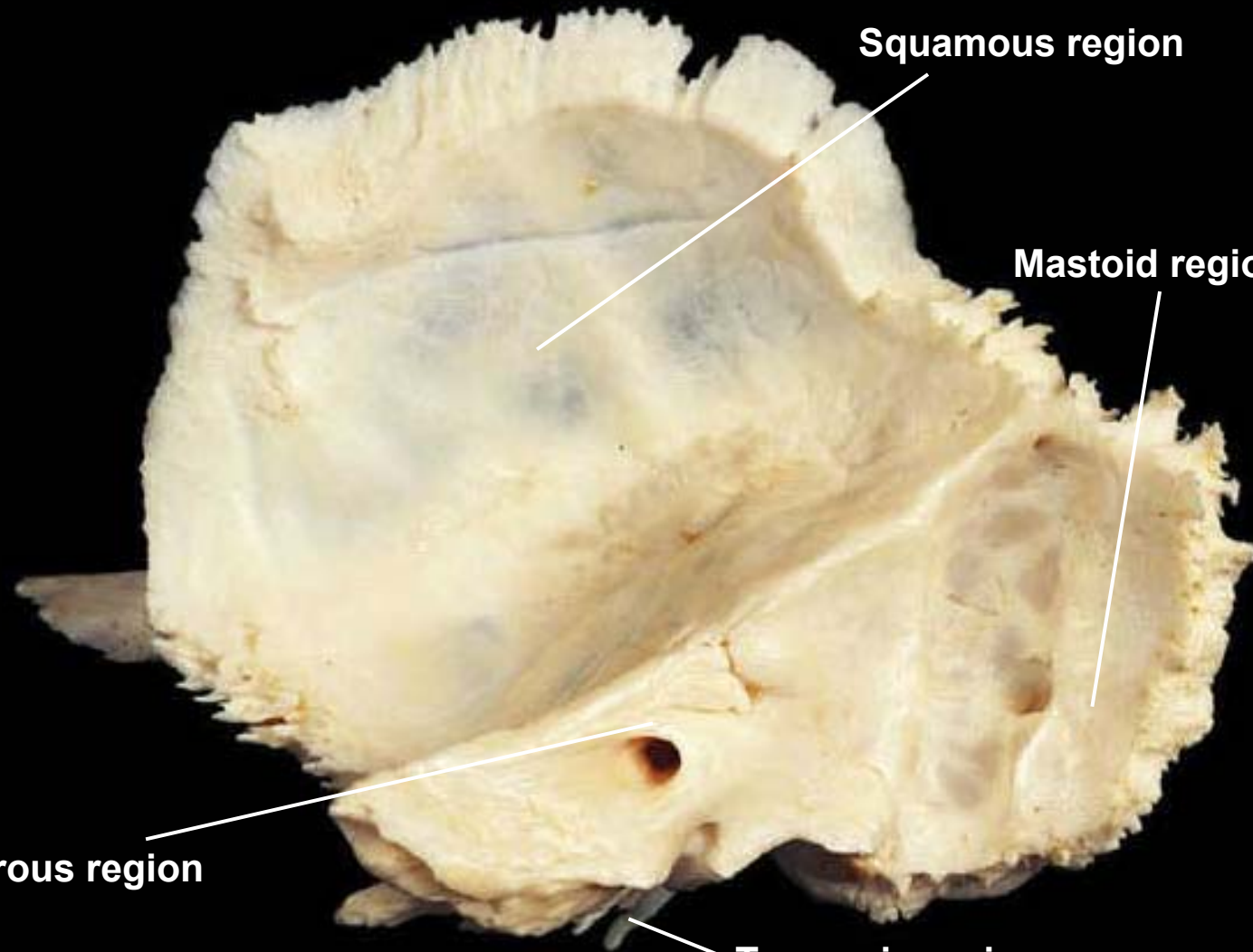
Temporal, medial view, right side

Squamous region

Mastoid region

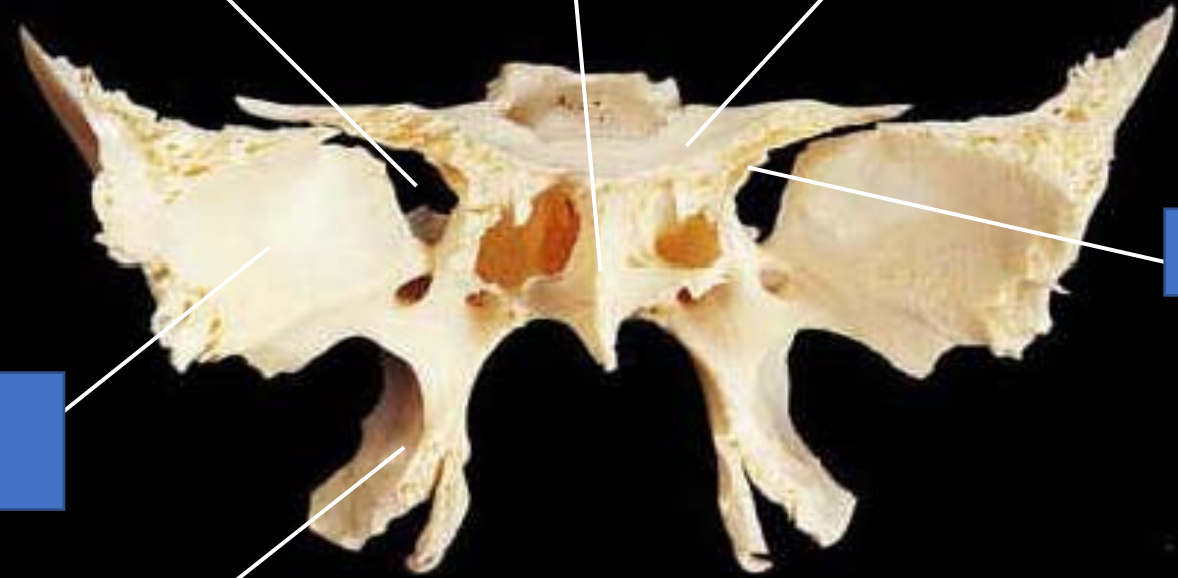Petrous region

Tympanic region

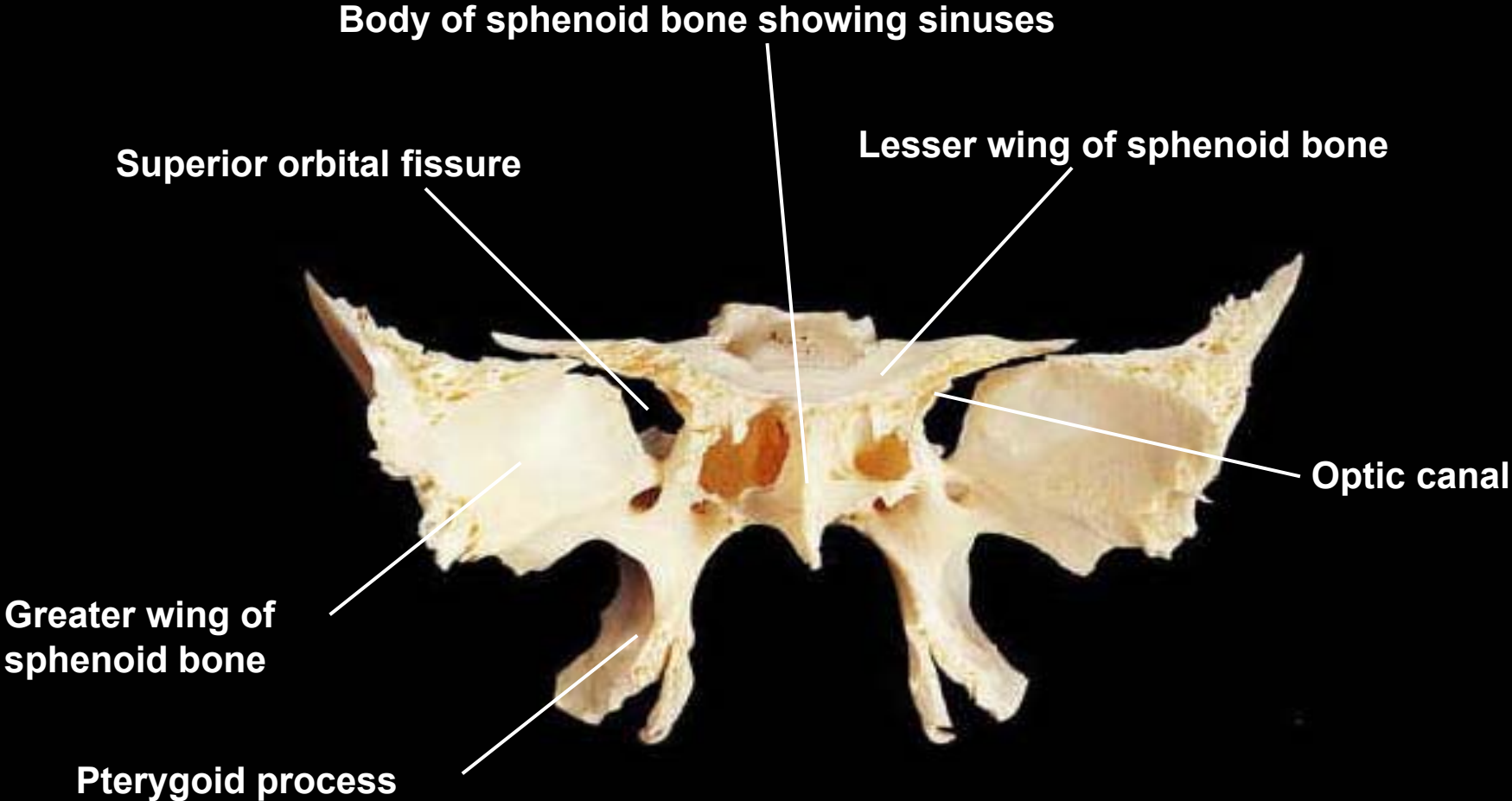



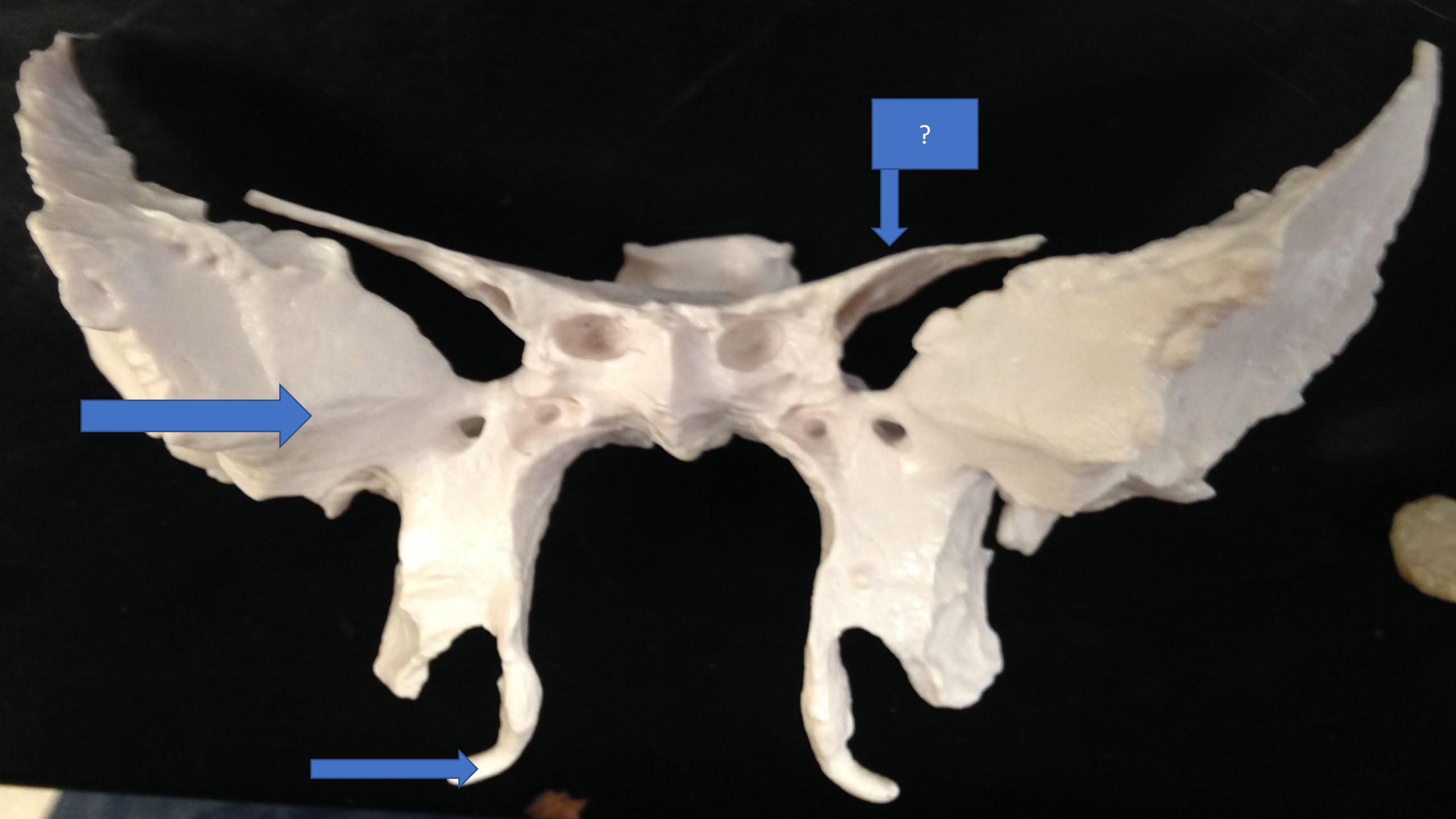
Body of sphenoid bone showing sinuses

Superior orbital fissure

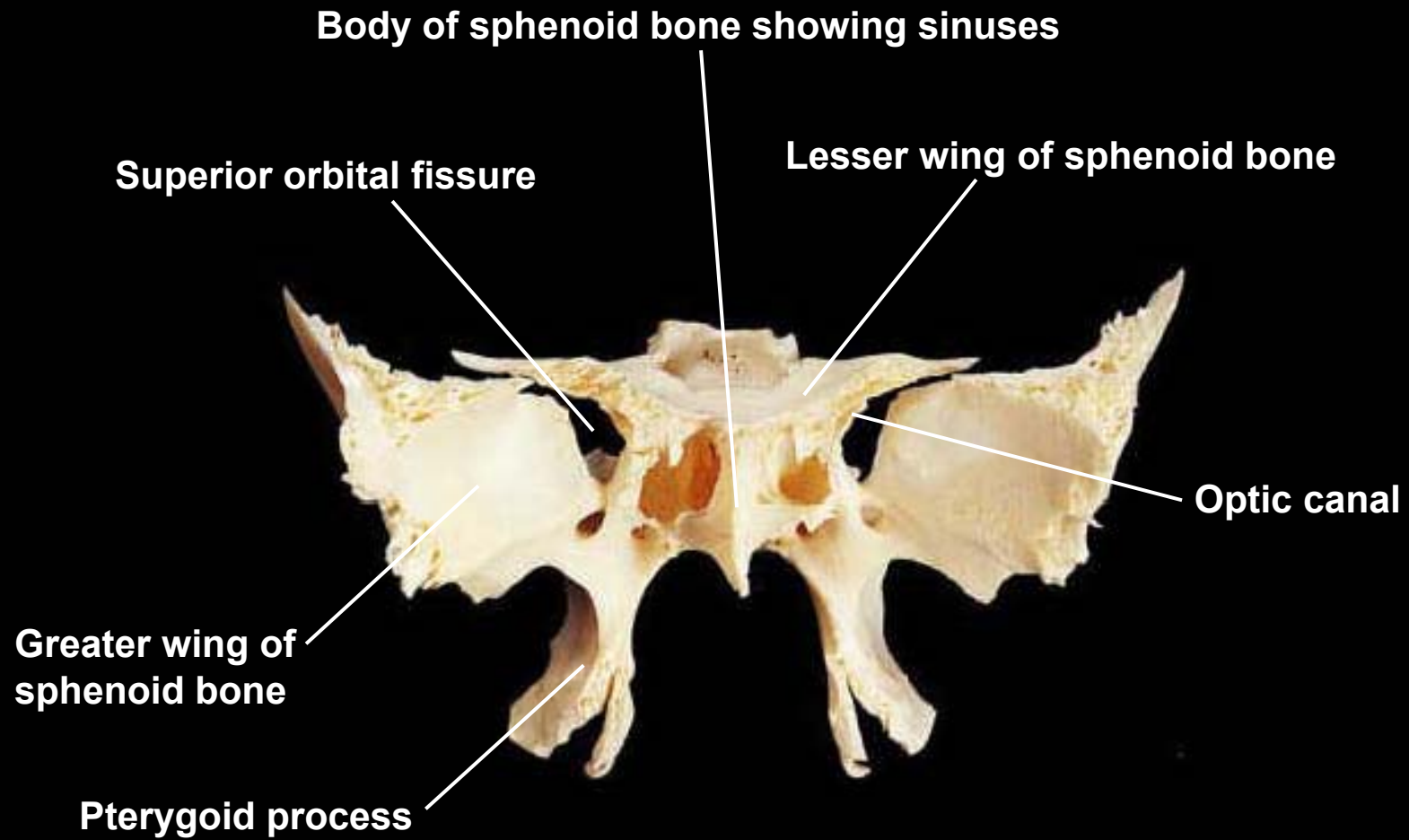


Sphenoid, anterior view

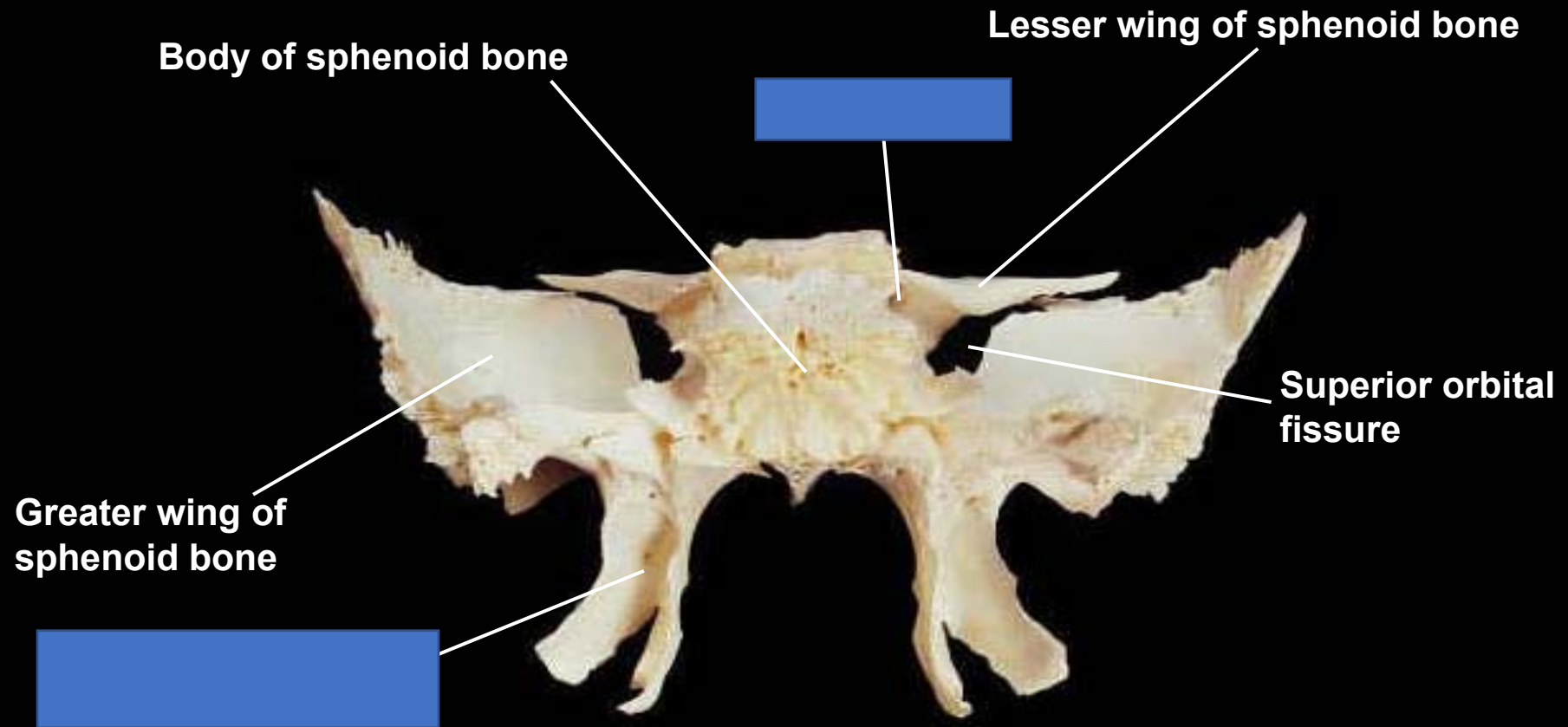




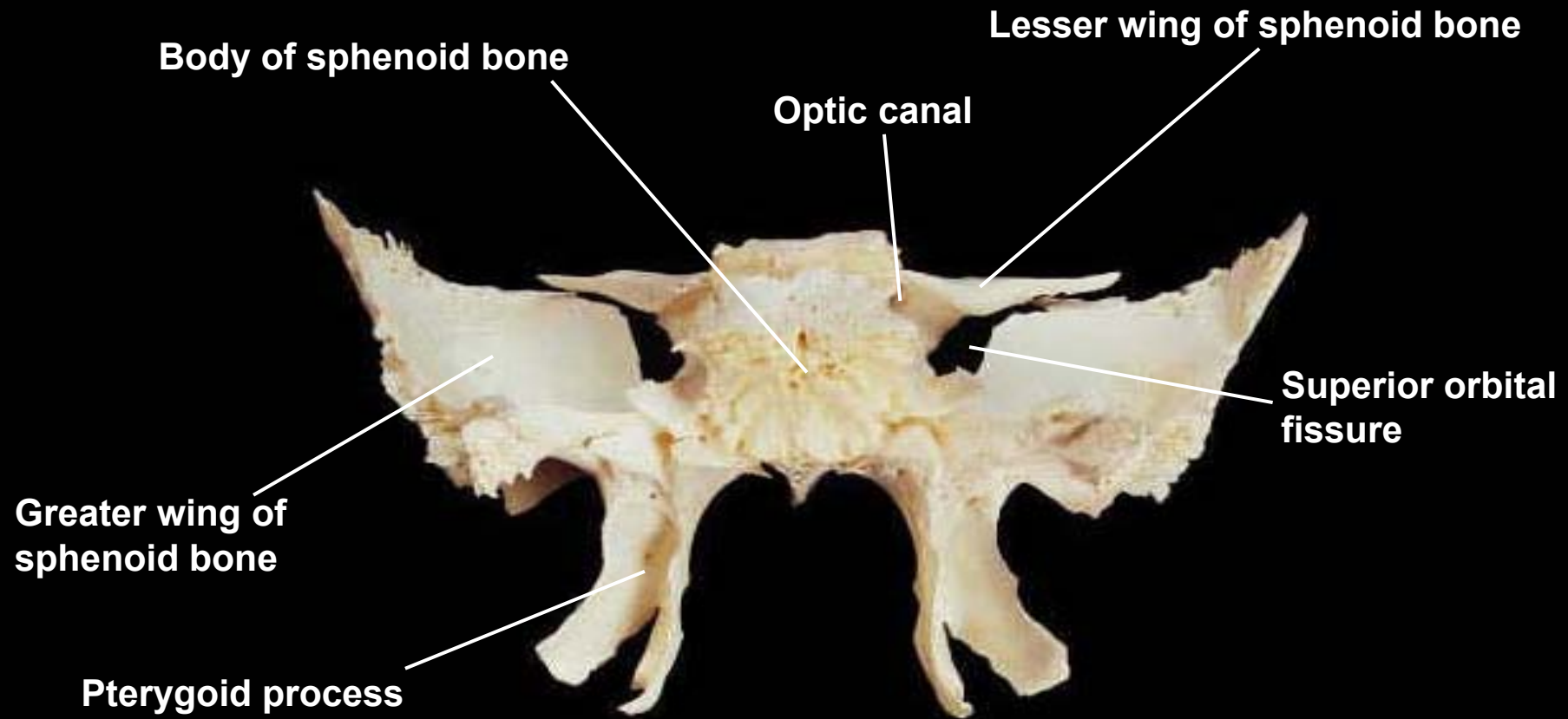
Sphenoid, anterior view



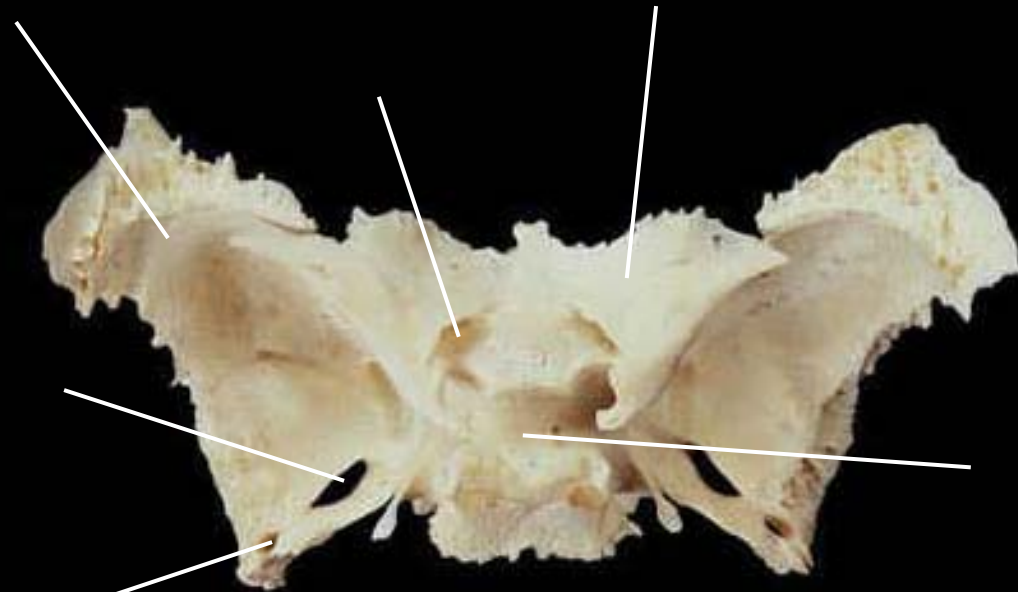
Sphenoid, posterior view



Sphenoid, posterior view

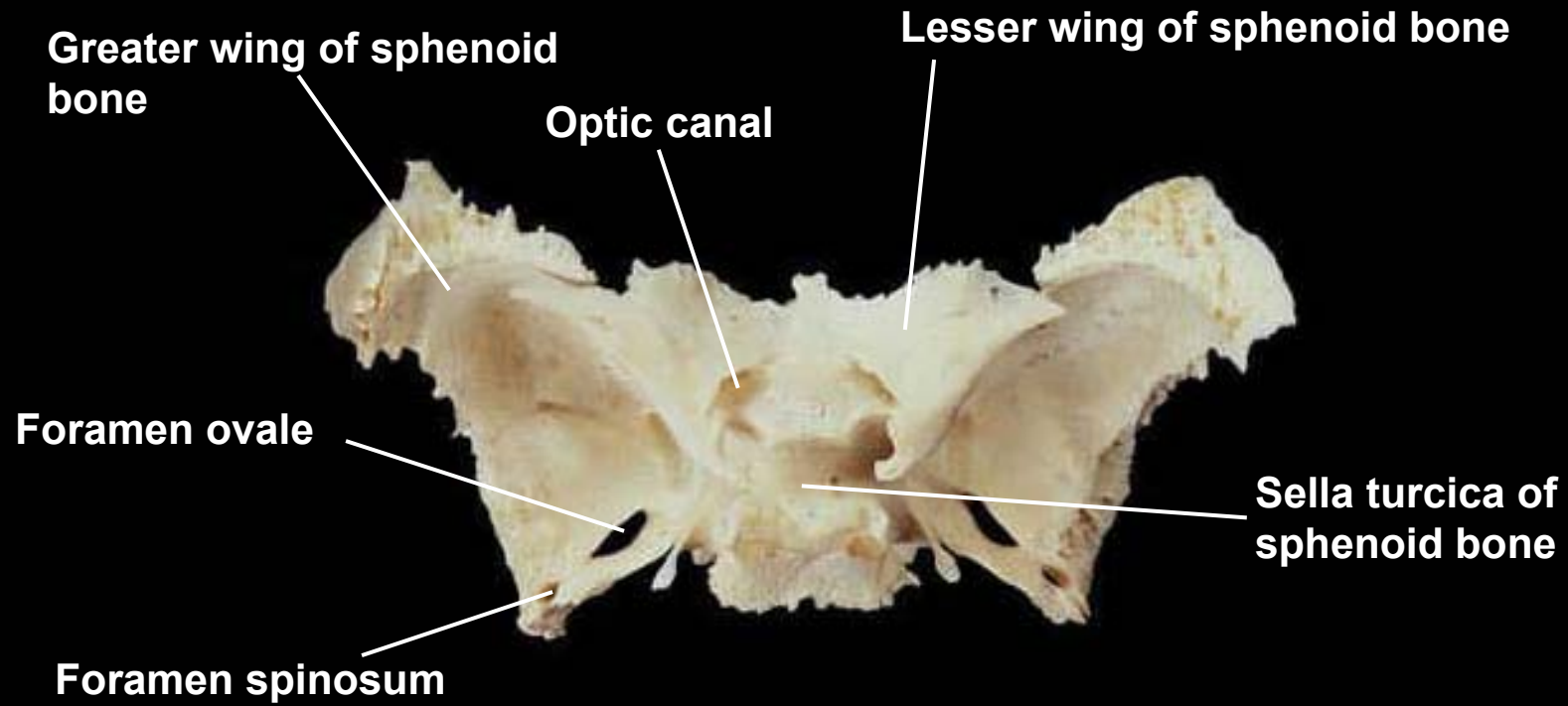


Sphenoid, superior view

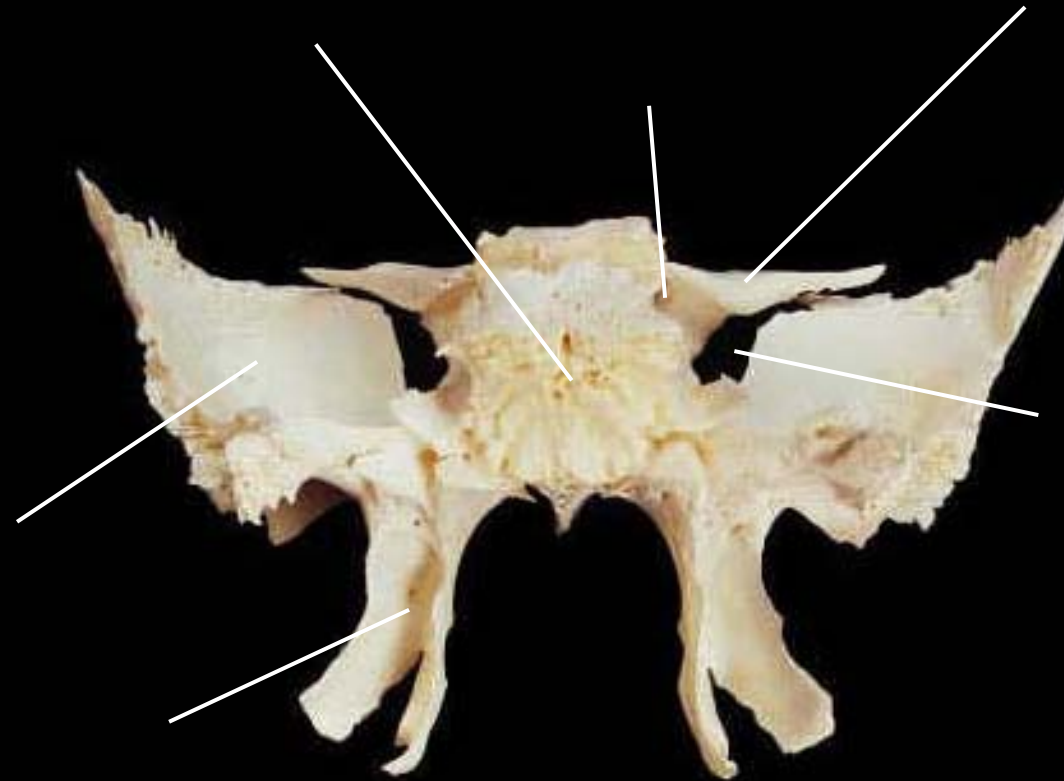


Foramen spinosum

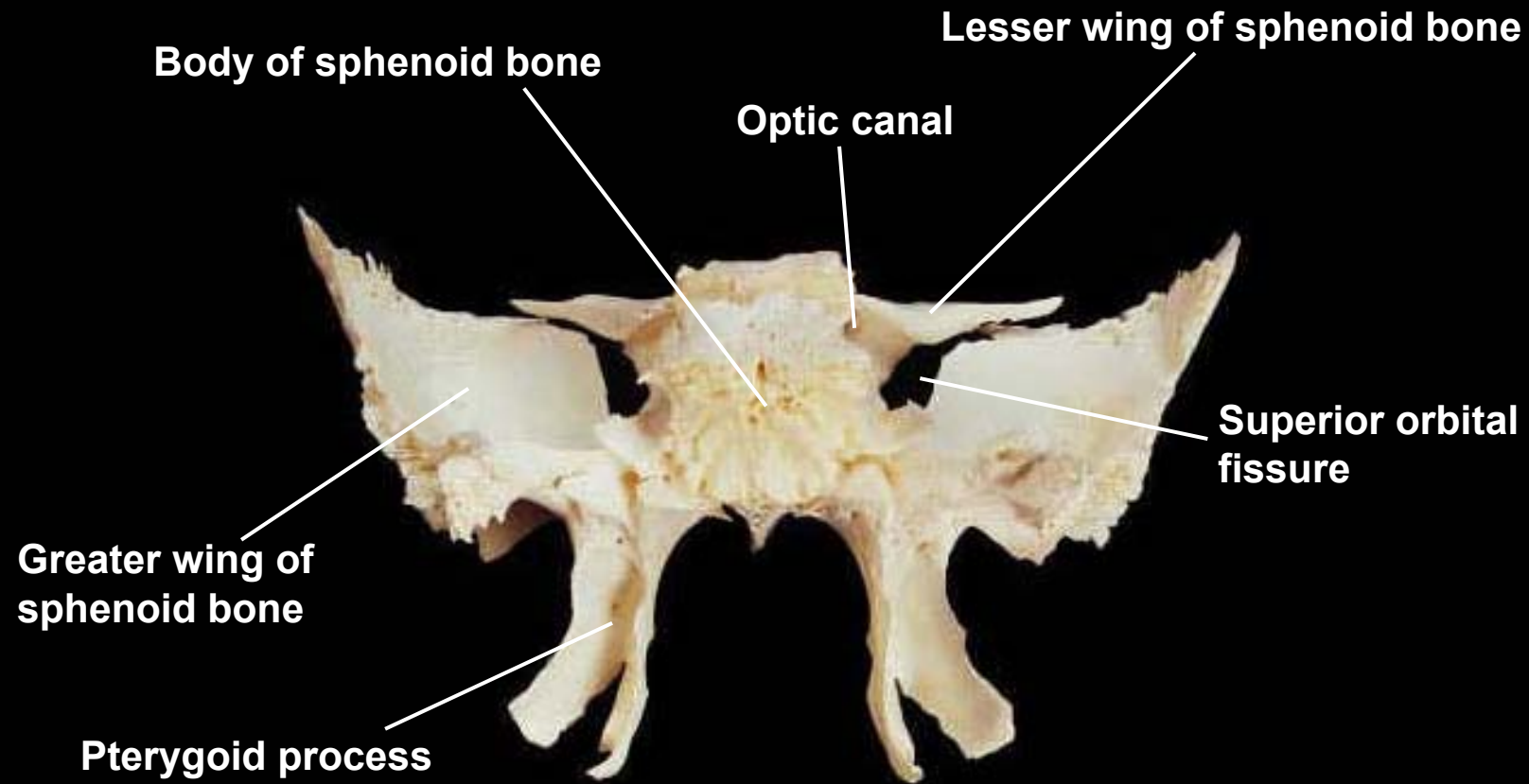
Sphenoid, superior view




Sphenoid, posterior view

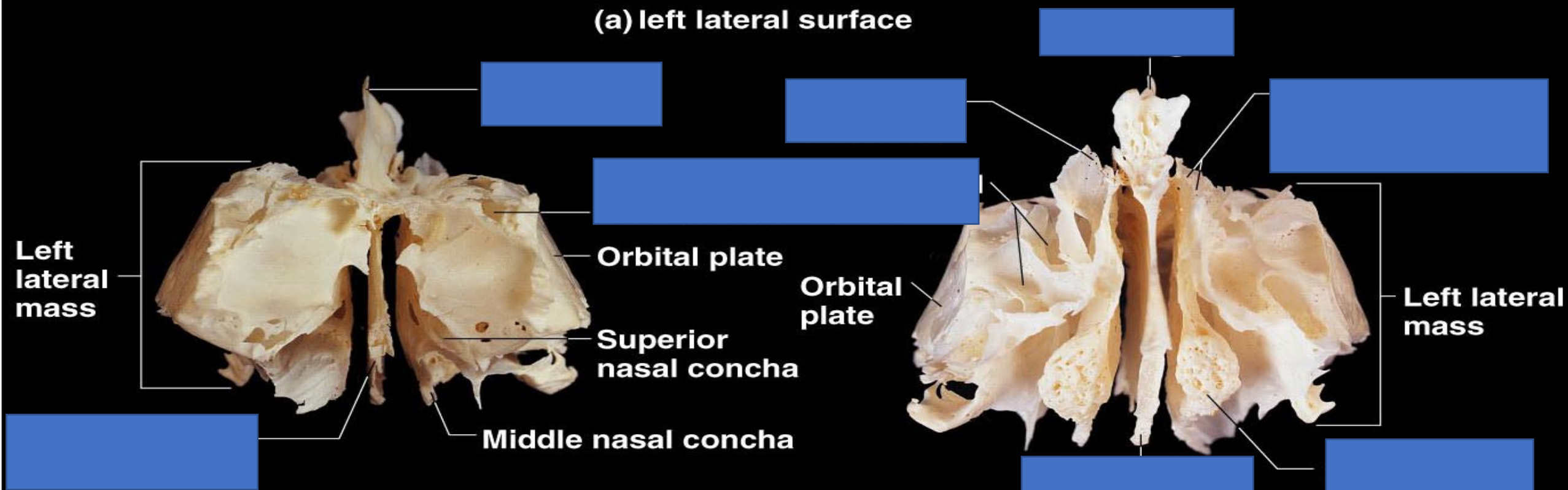


Sphenoid, posterior view





(a) left lateral surface



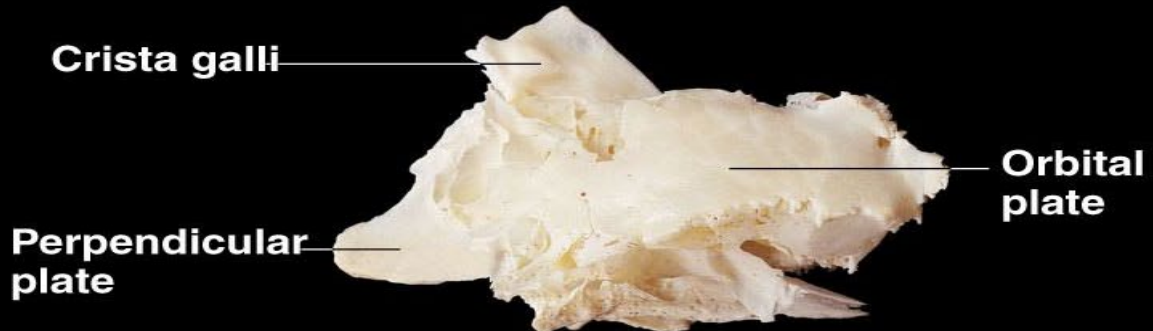
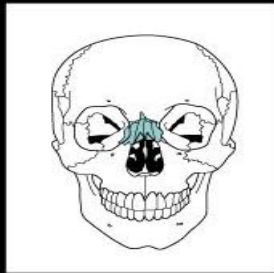
(b) posterior view

(c) anterior view

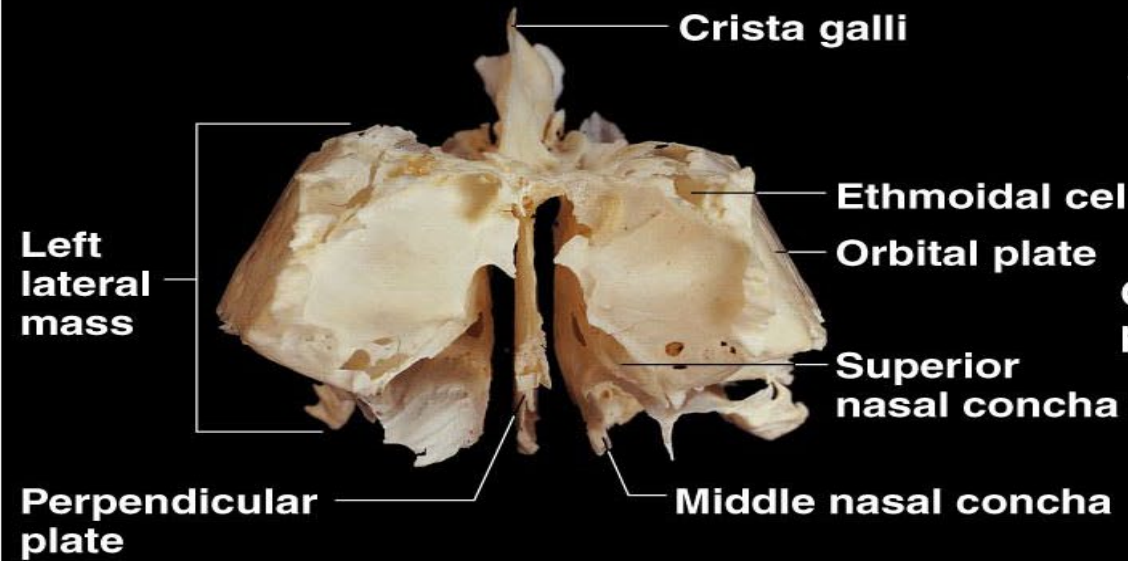
What do you call this bone?

The ethmoid forms the medial portions of the orbits and the roof of the nasal cavity.

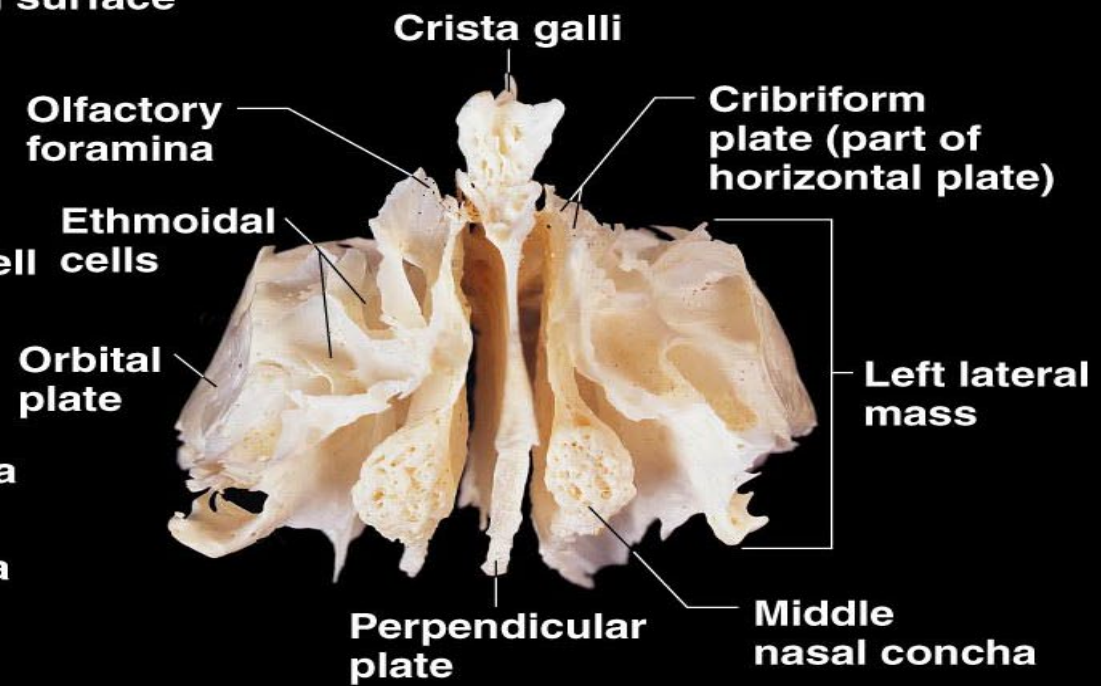
Major markings include the cribriform plate, crista galli, perpendicular plate, nasal conchae, and the ethmoid sinuses



(a) left lateral surface



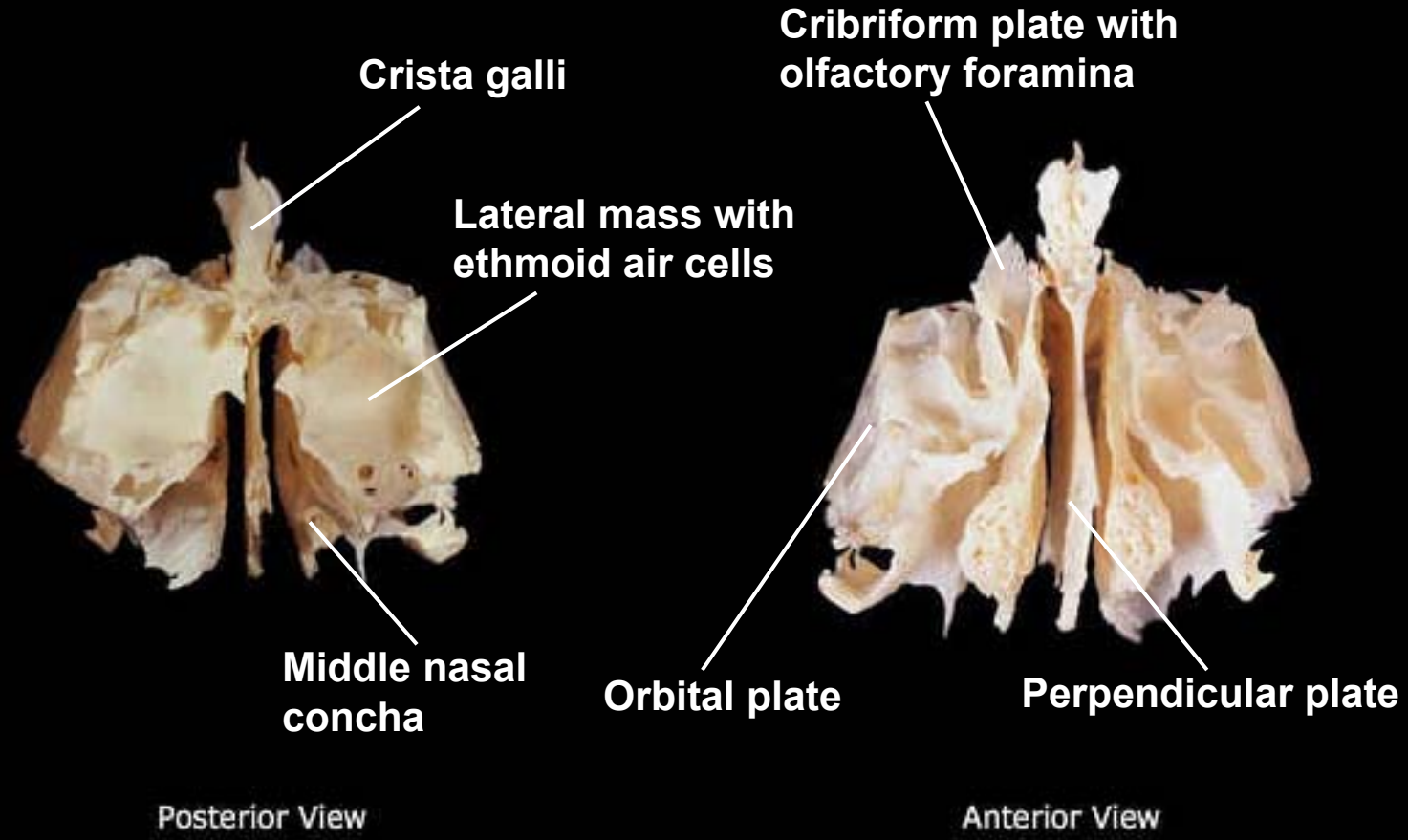
(b) posterior view



(c) anterior view

Figure 10 Ethmoid bone.

Ethmoid, posterior and anterior views





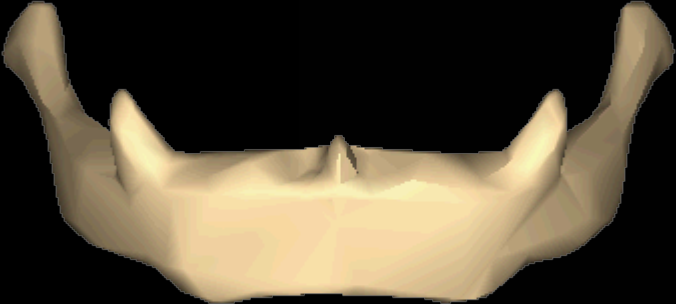

Greater horn

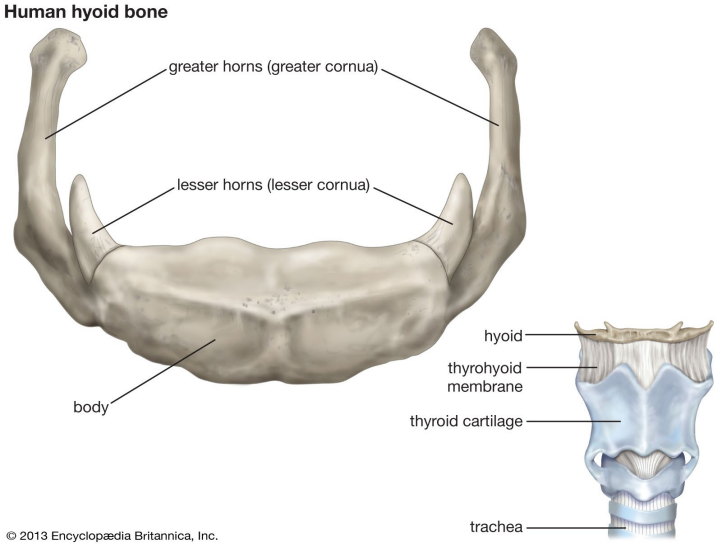


Body



Lesser horn



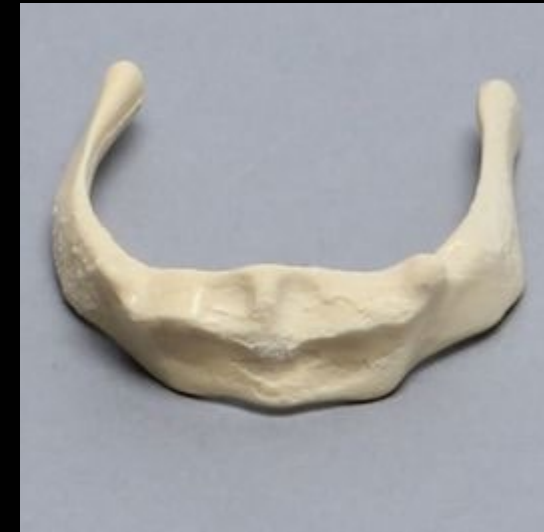
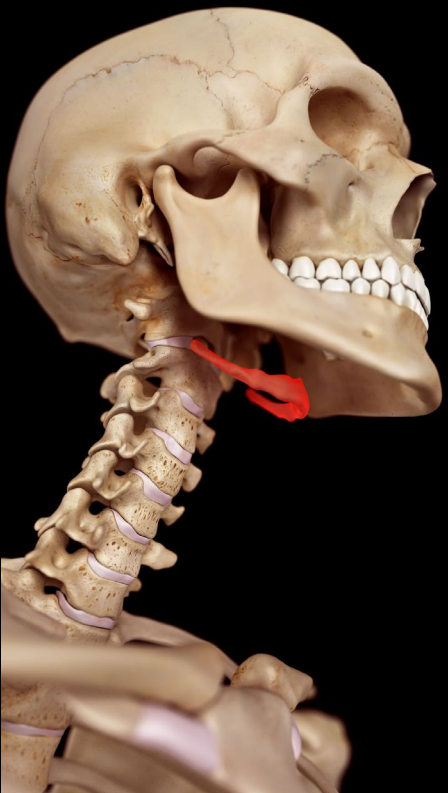
Hyoid, superior view

Greater horn

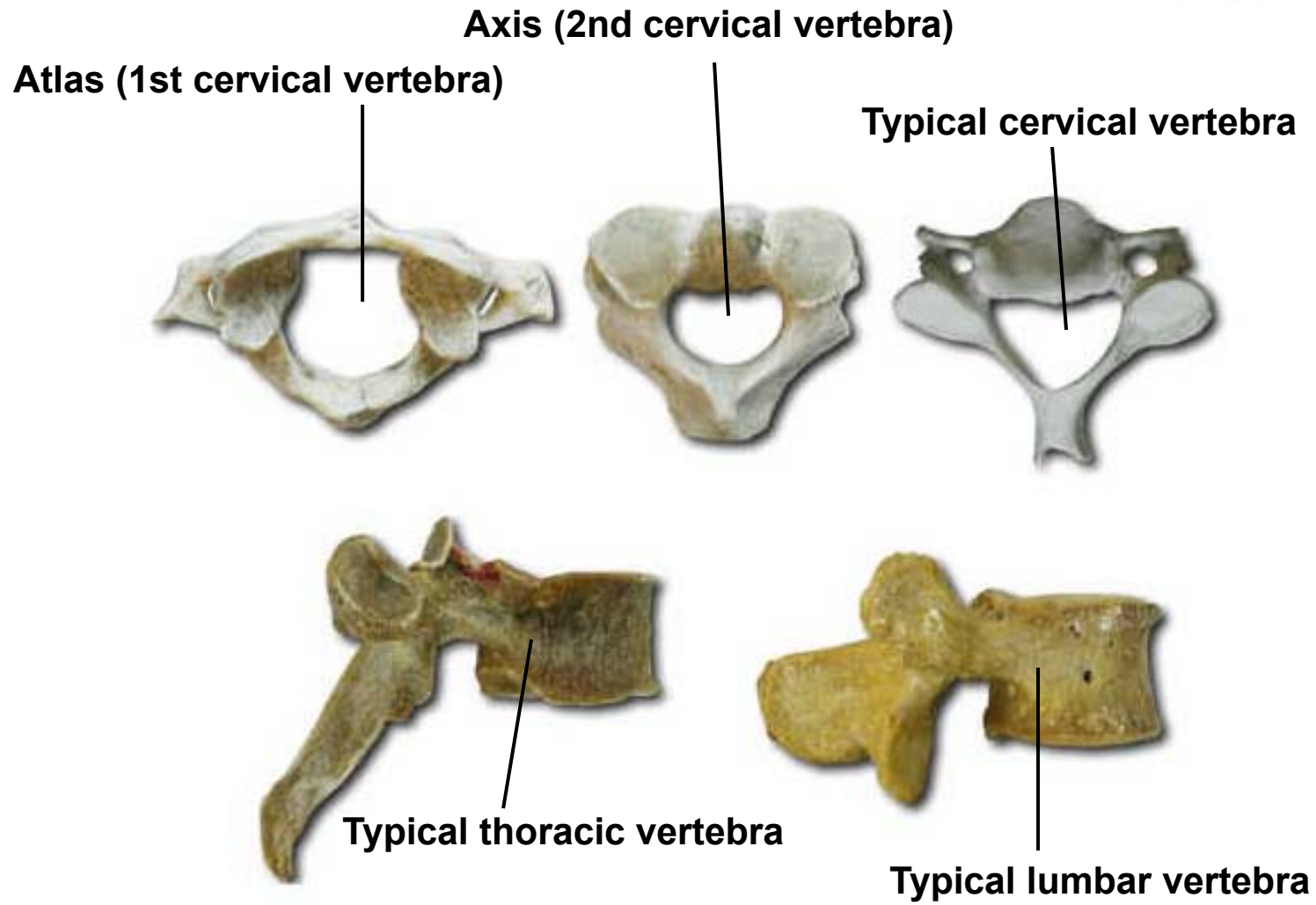
Body

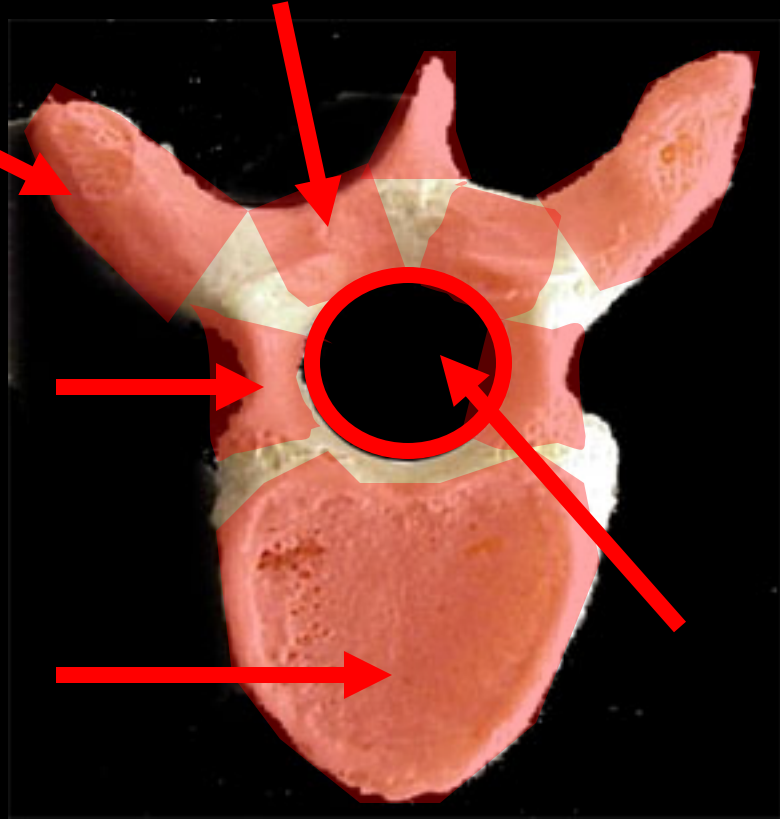
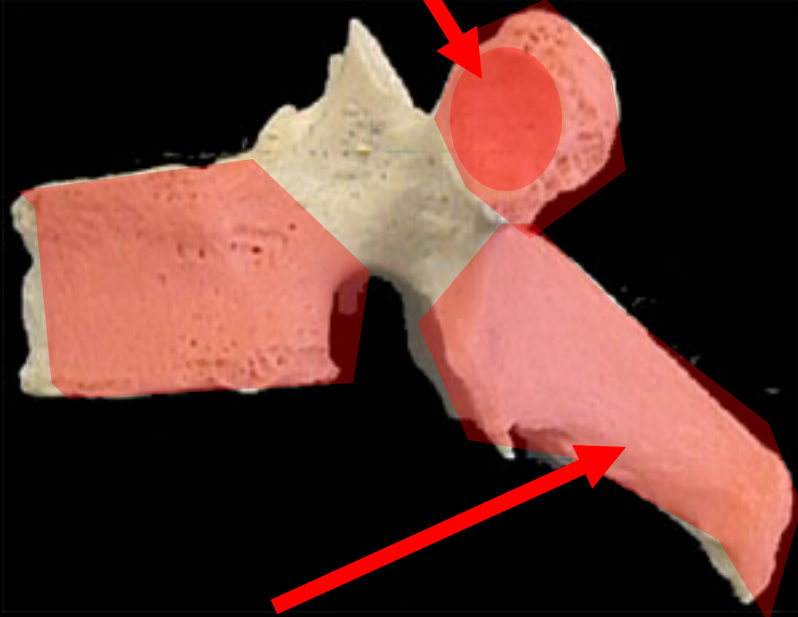
Lesser horn

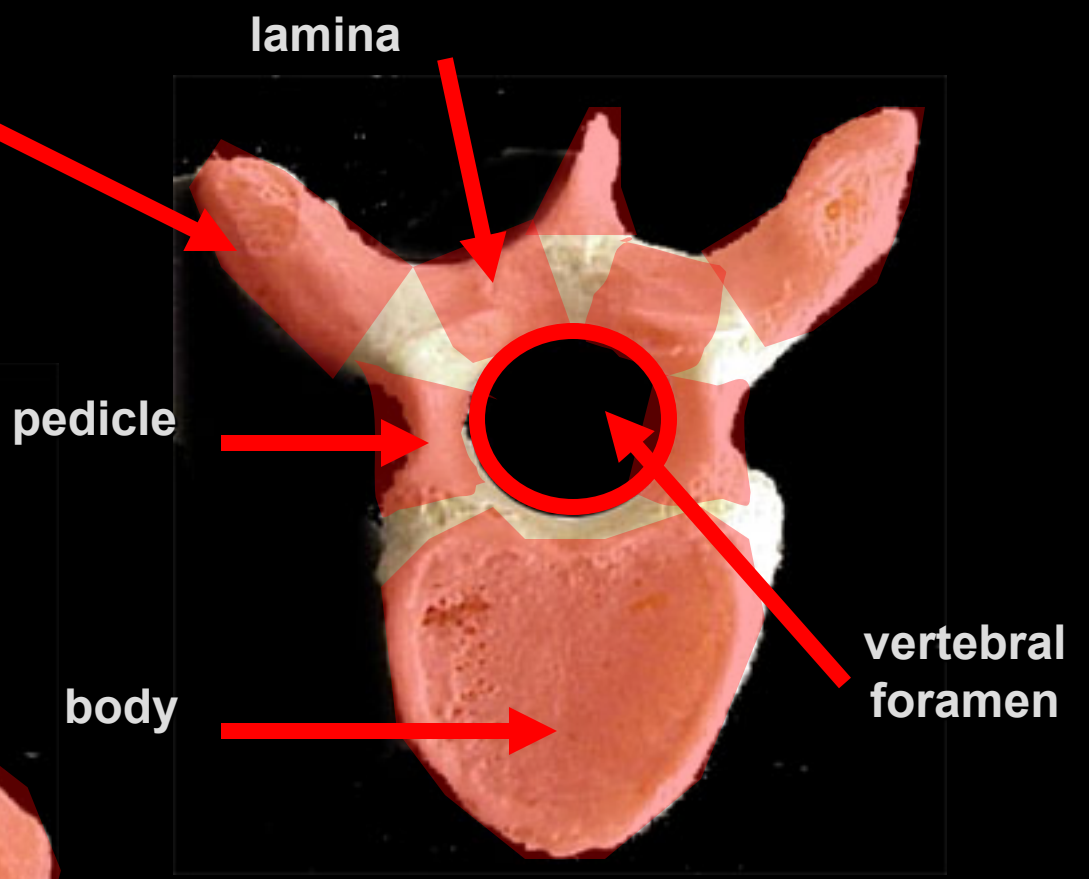
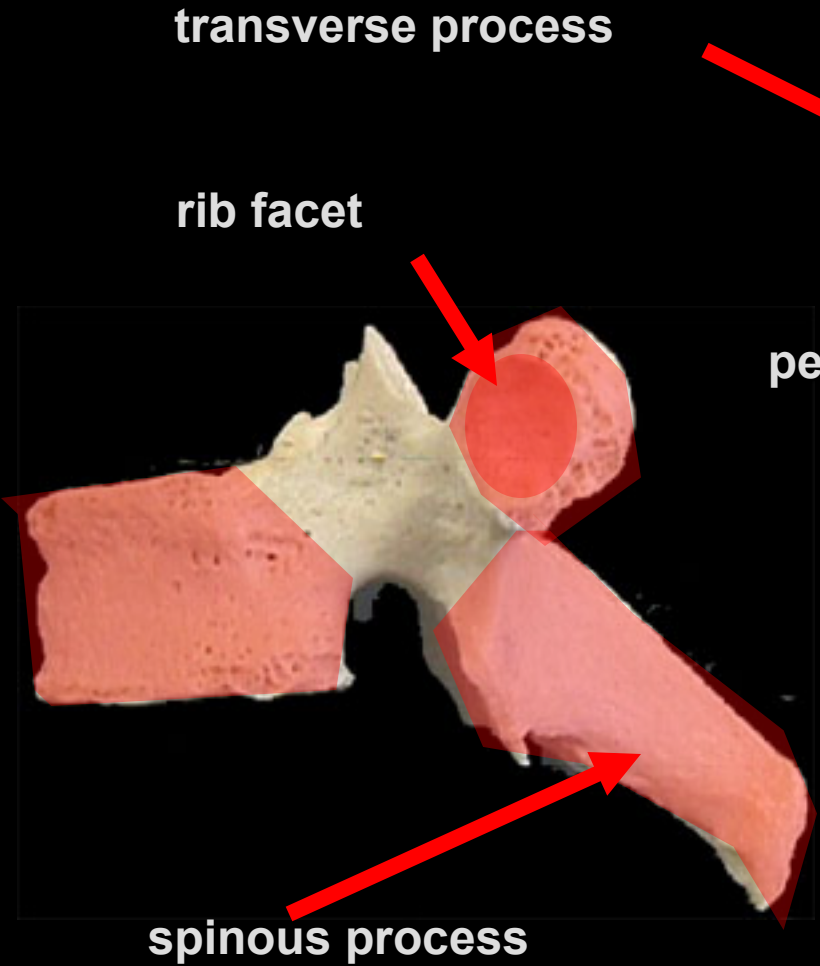


Spine

Types of vertebrae

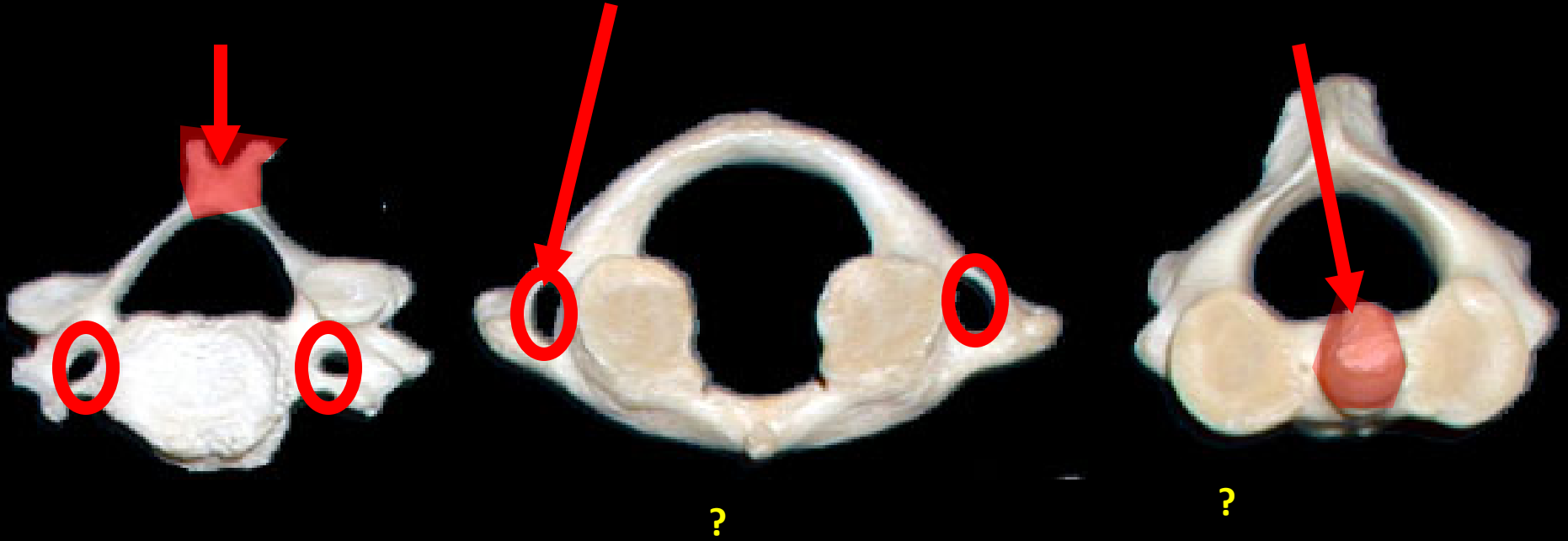


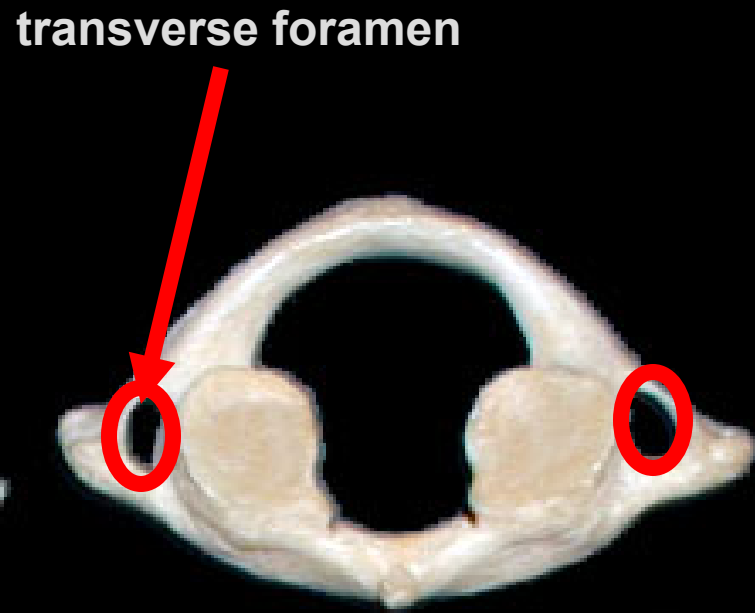
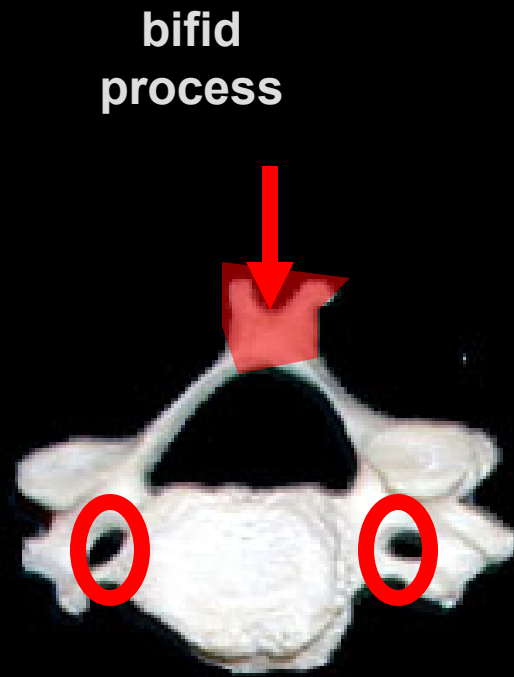




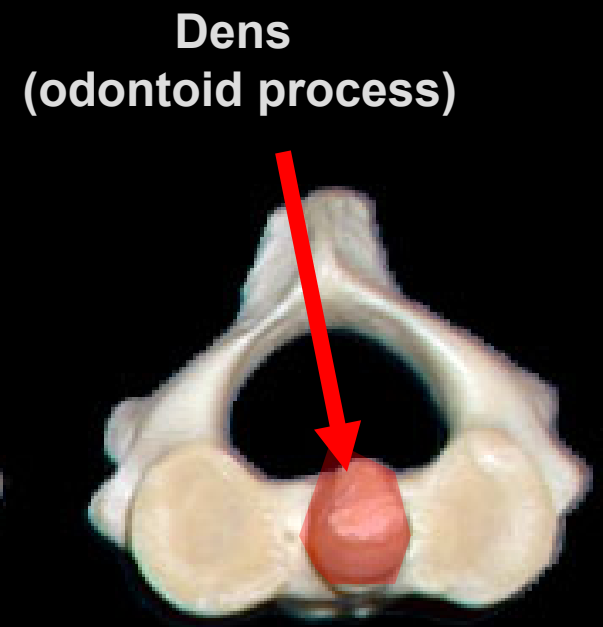
Vertebral Parts

[.....?...]Vertebrae



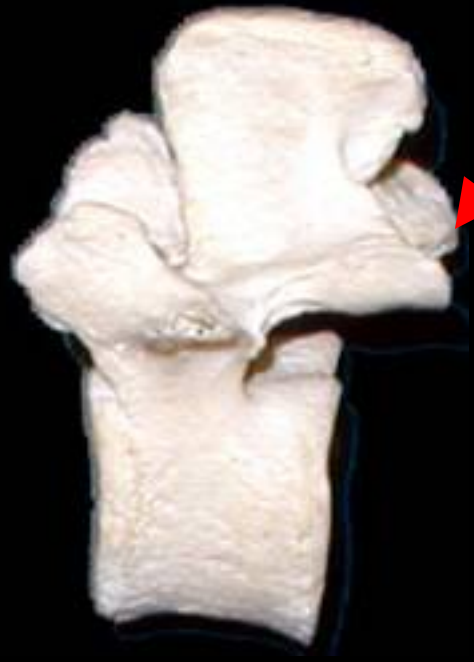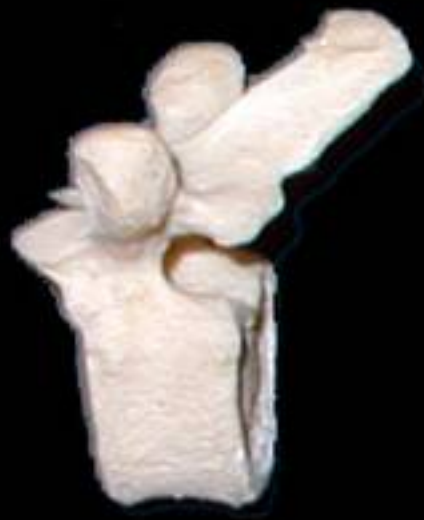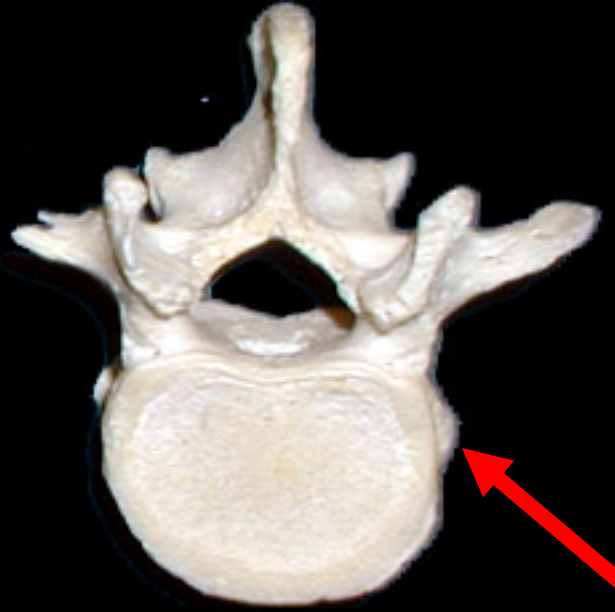


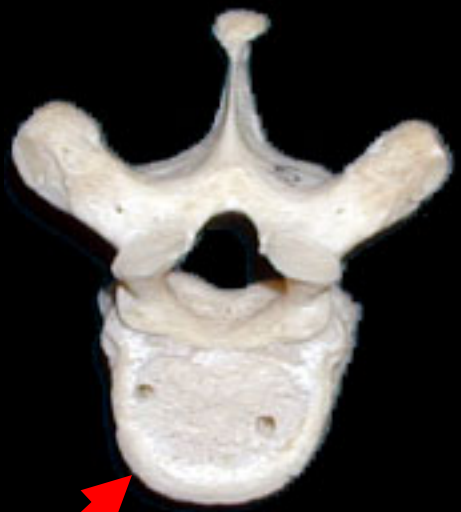Atlas (C1)

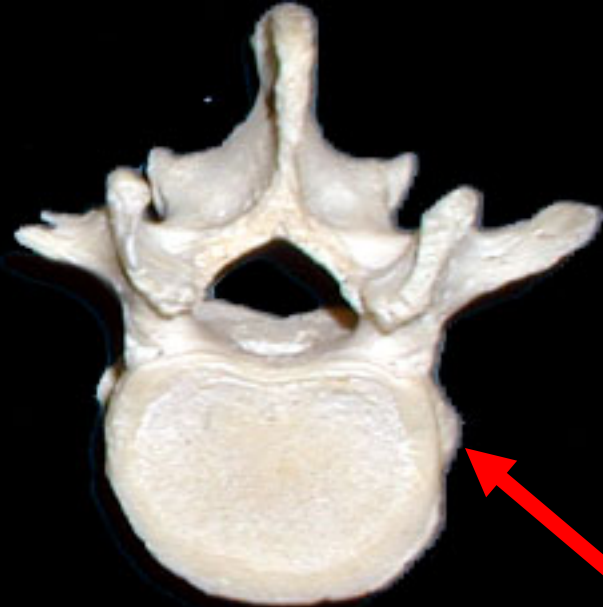
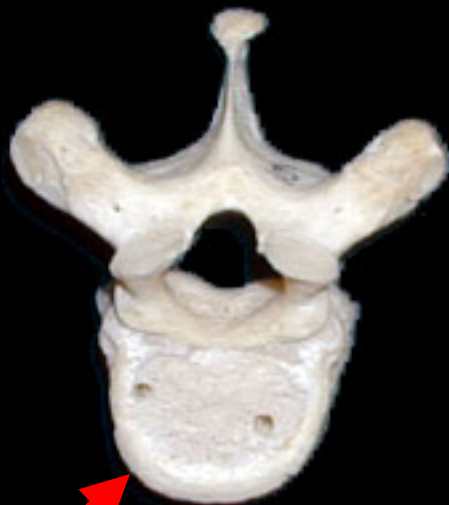

Axis (C2)

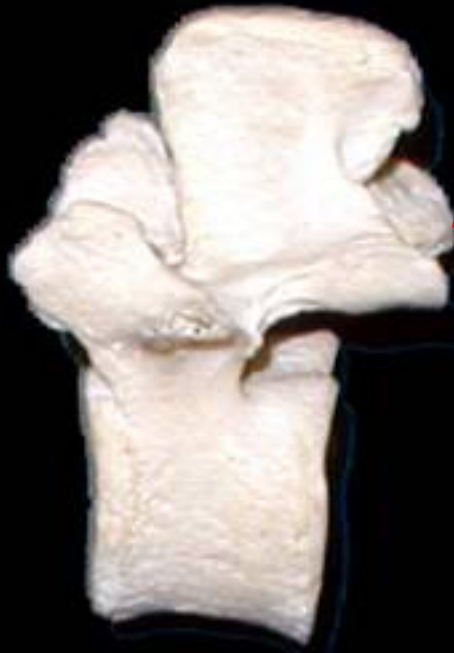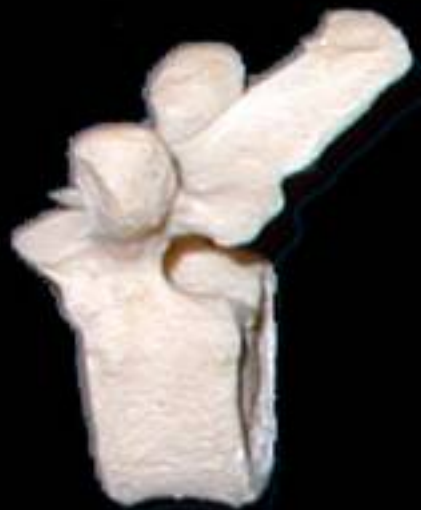Thoracic &
Lumbar
Vertebrae?



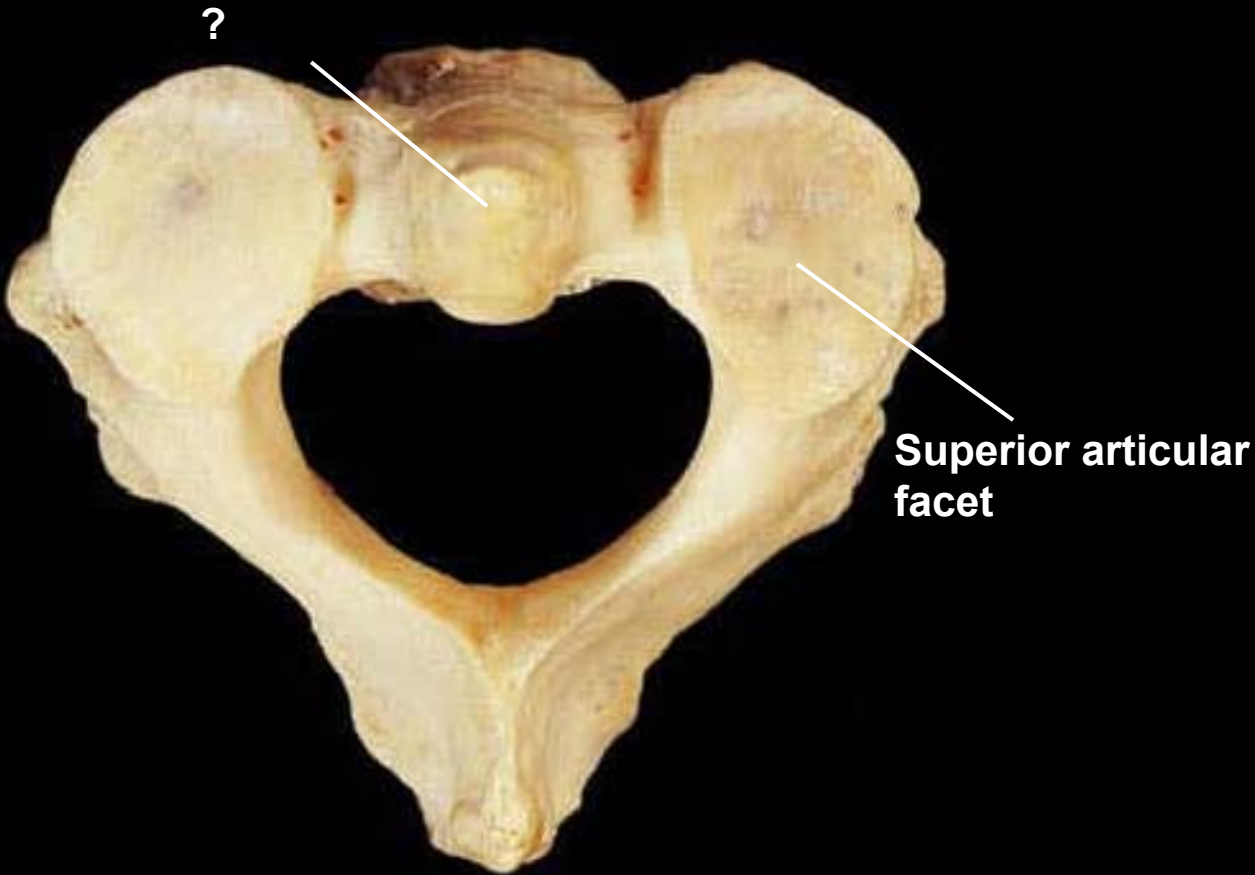
**thoracic
vertebrae**



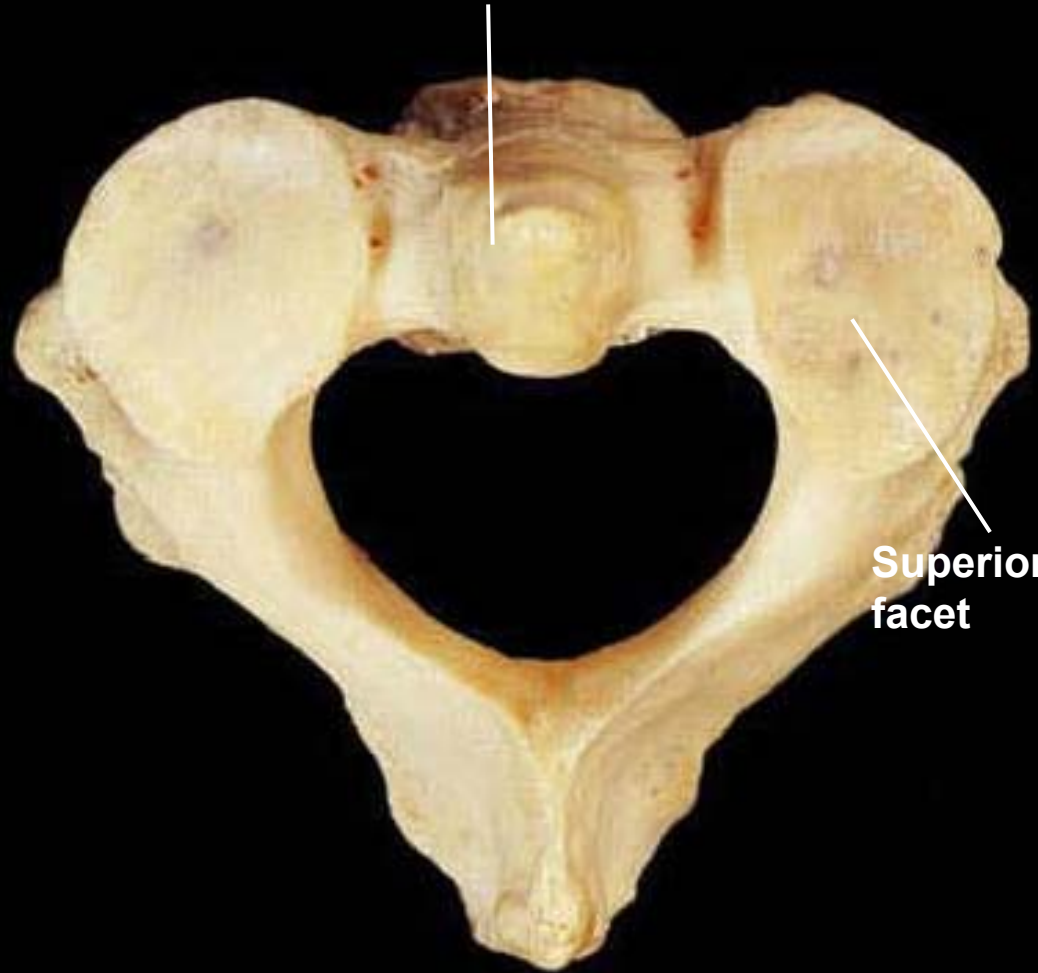
**lumbar
vertebrae**



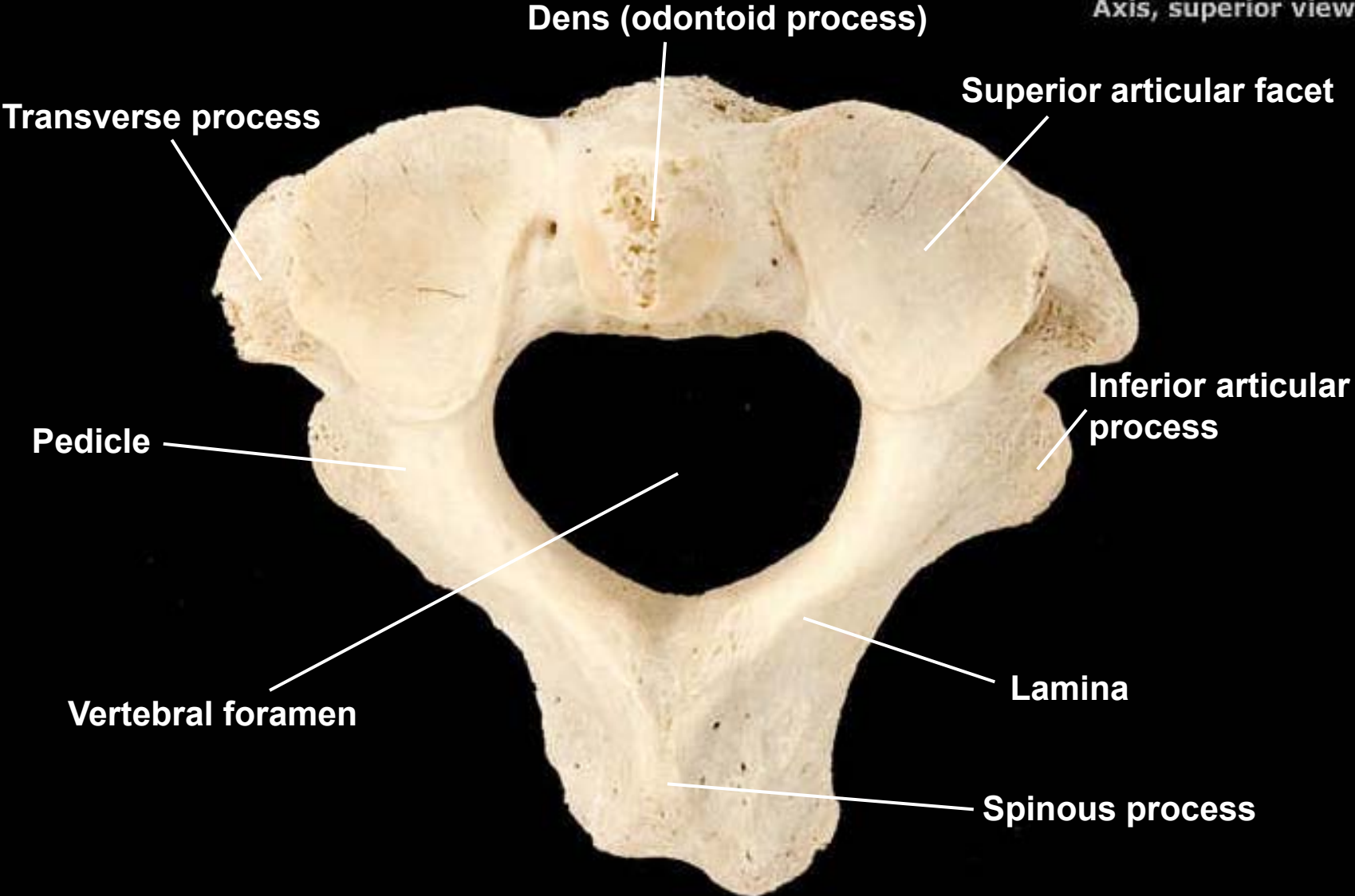
Name this vertebra
and why?



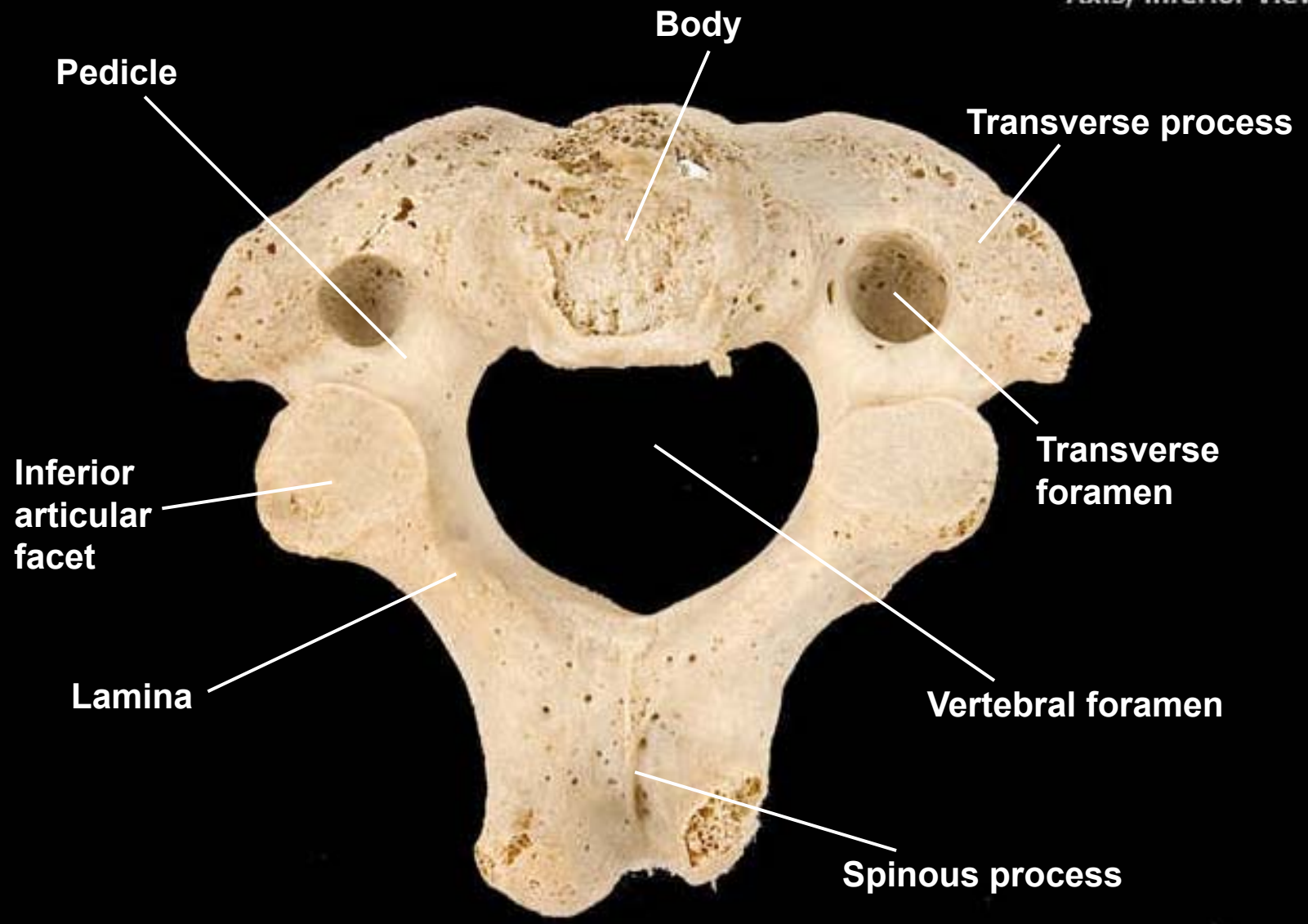
Dens



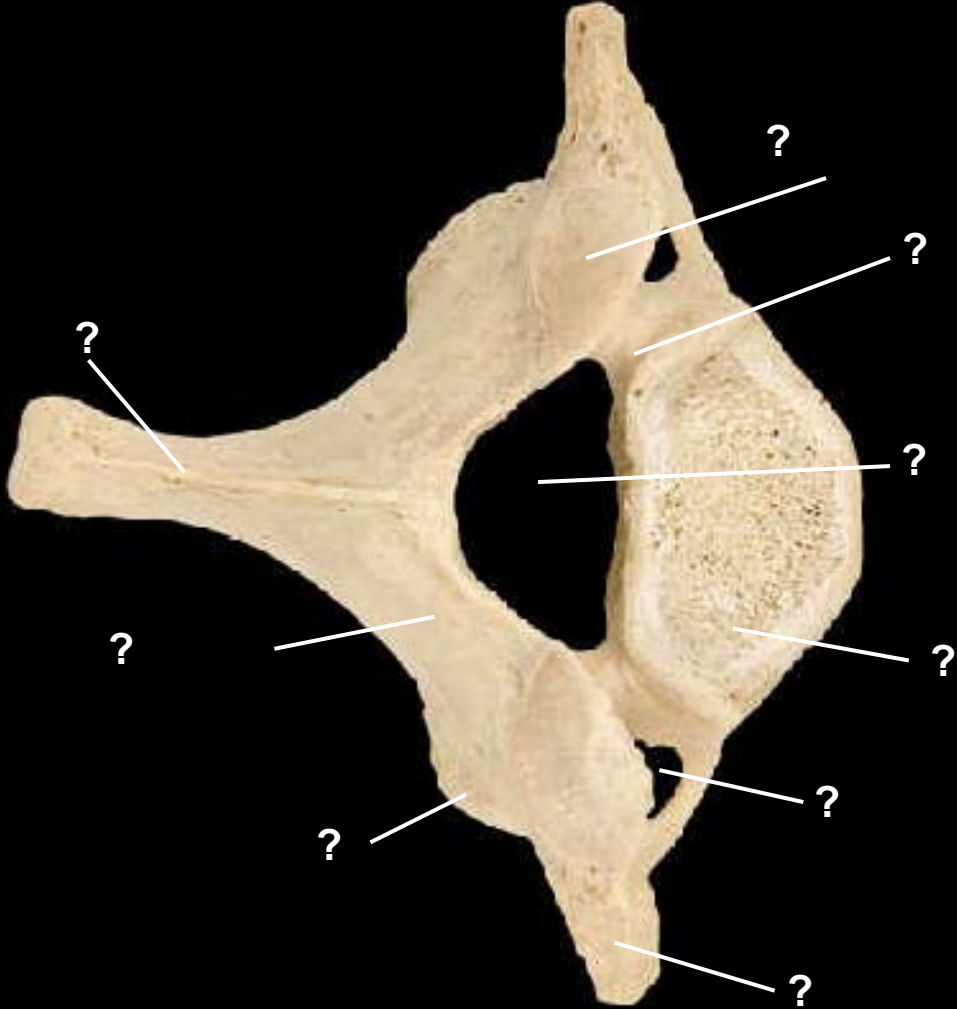
Superior articular
facet



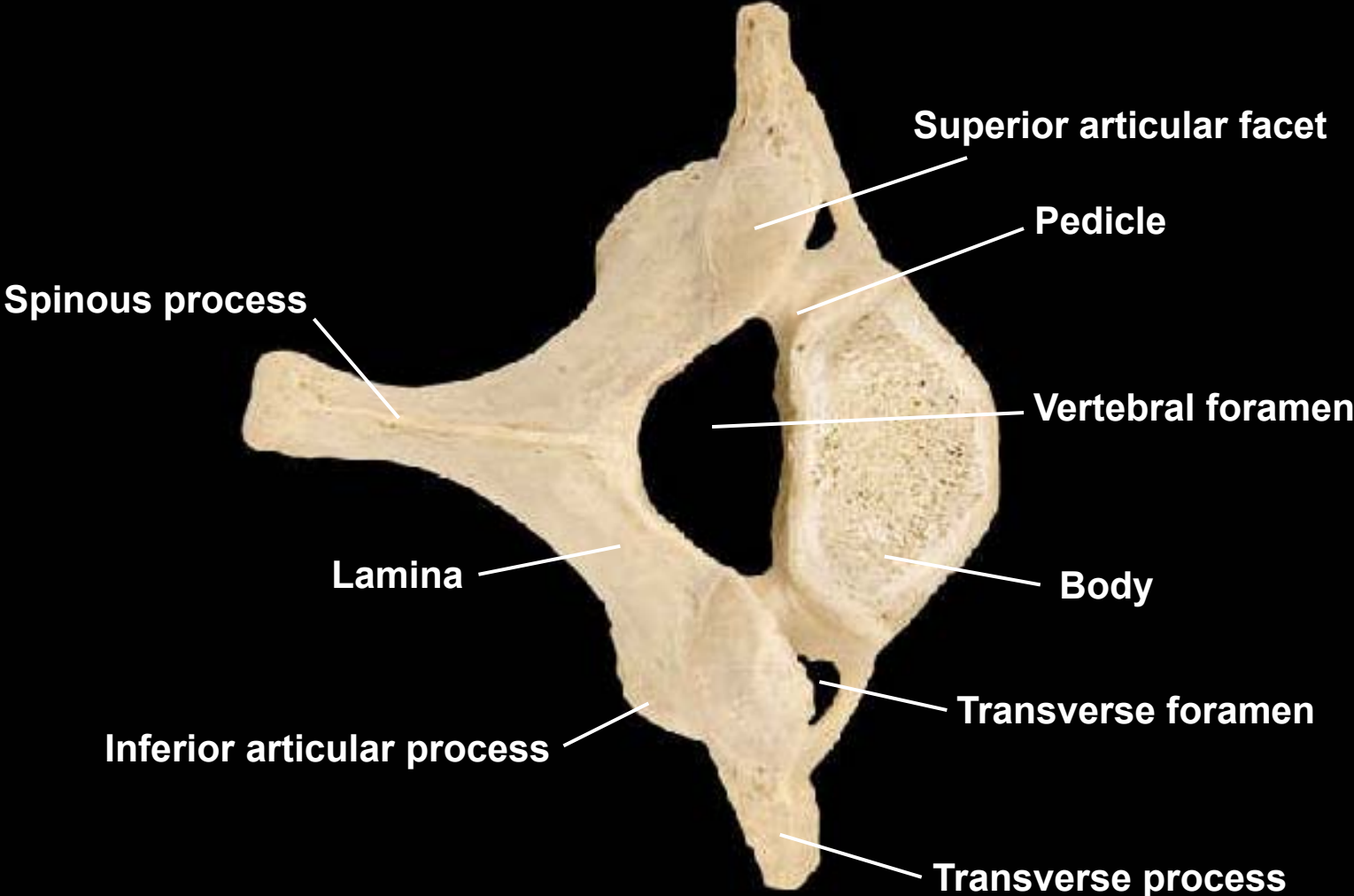
Axis, inferior view

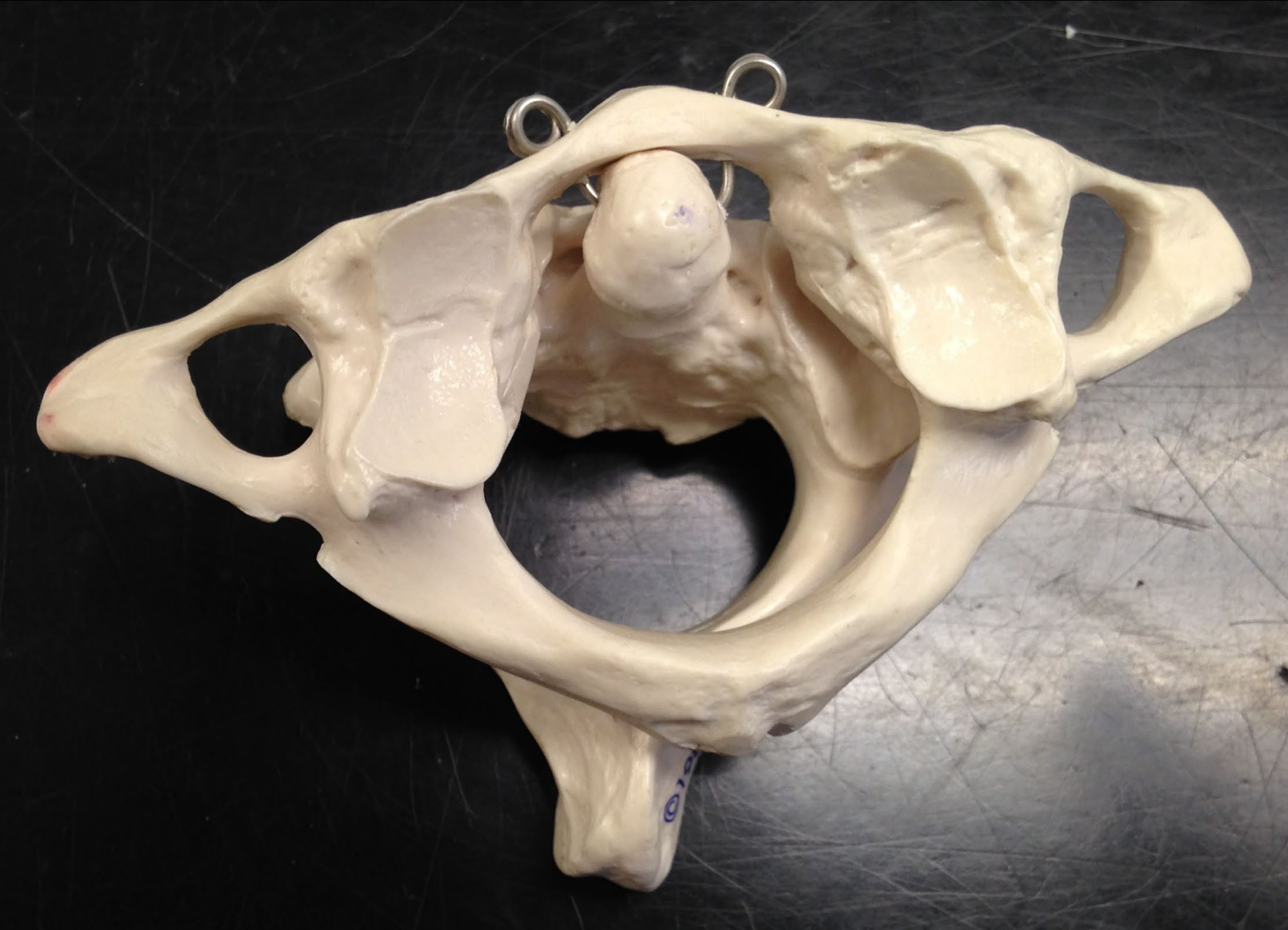

Cervical vertebra, superior view

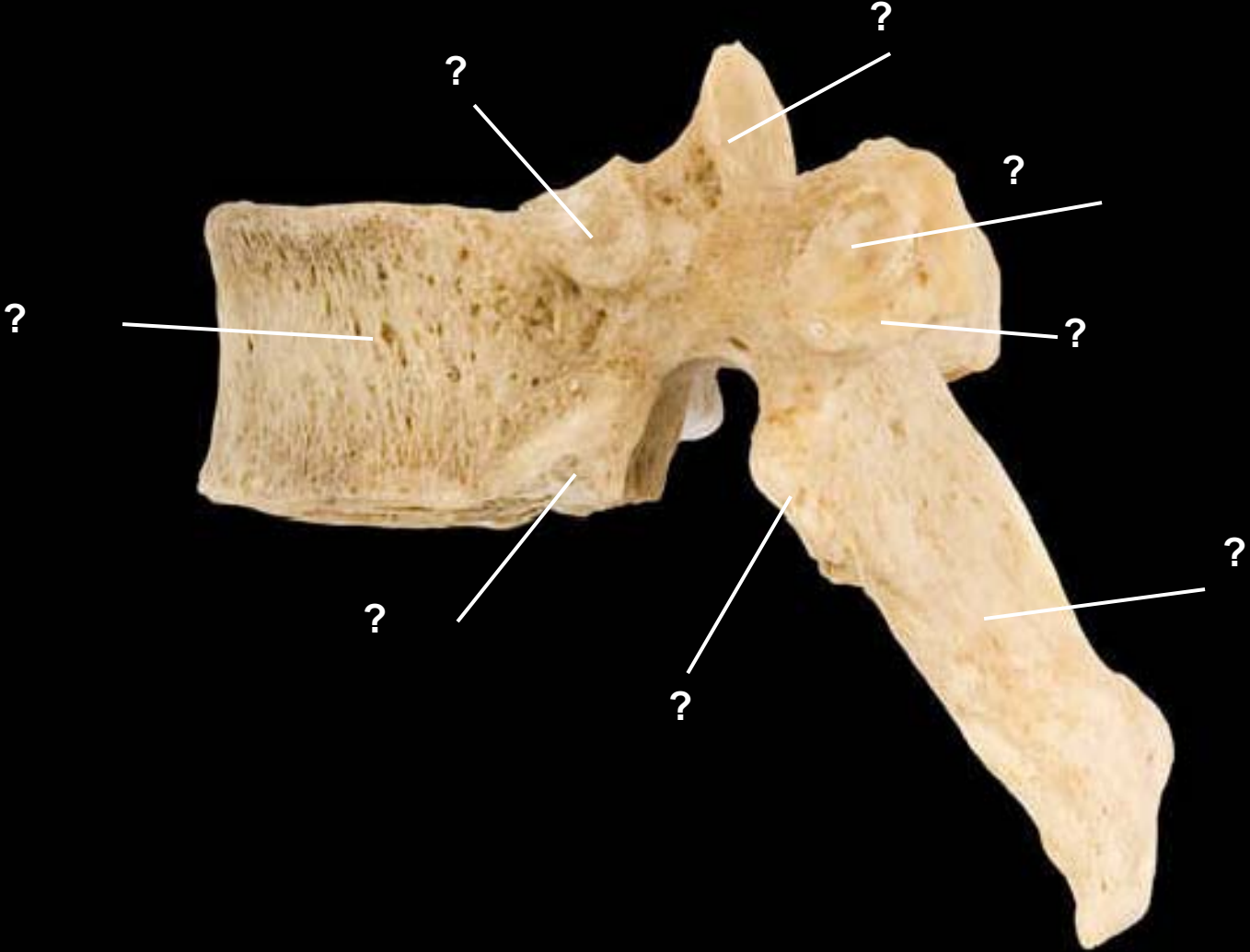


Cervical vertebra, superior view

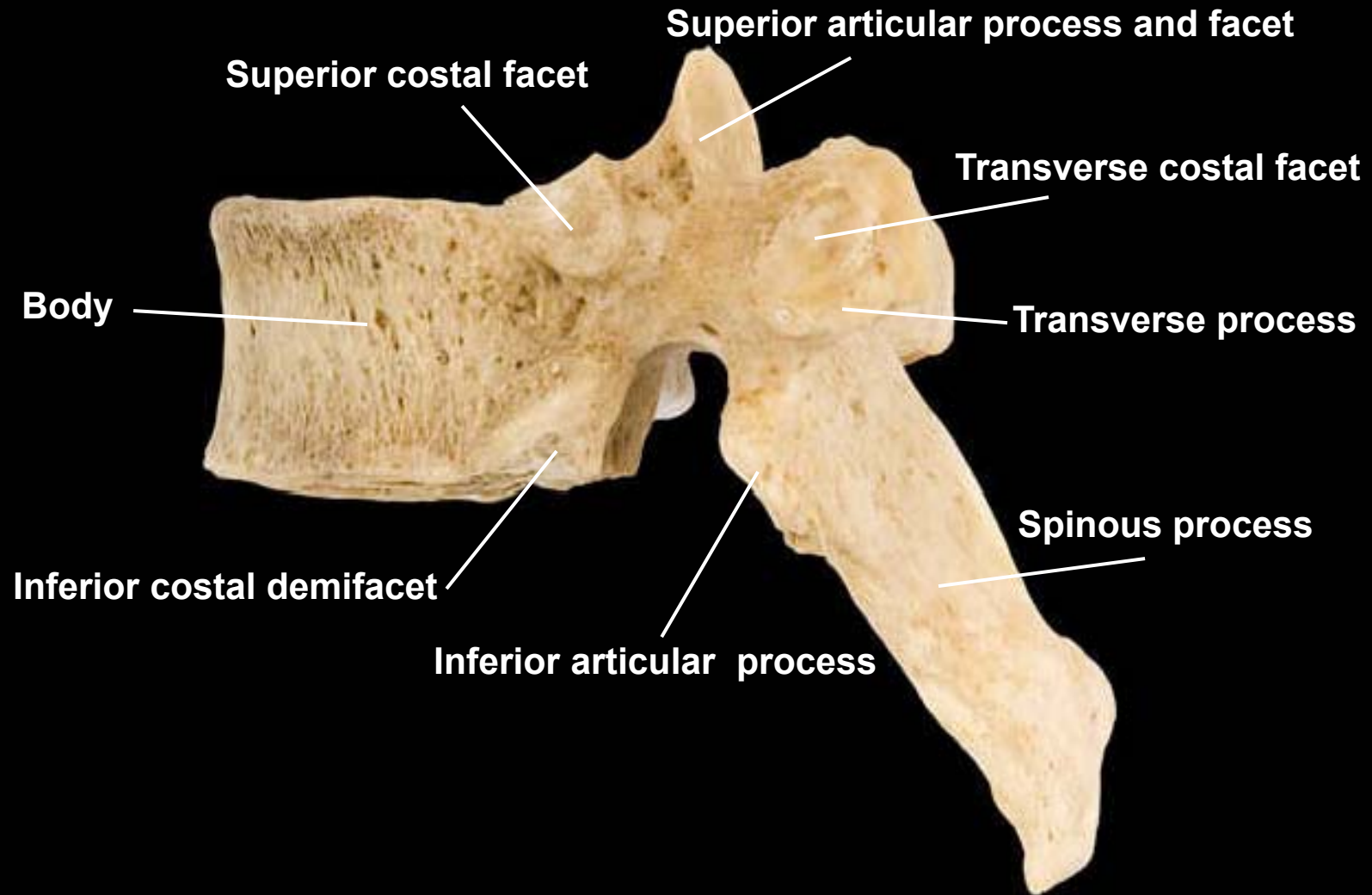




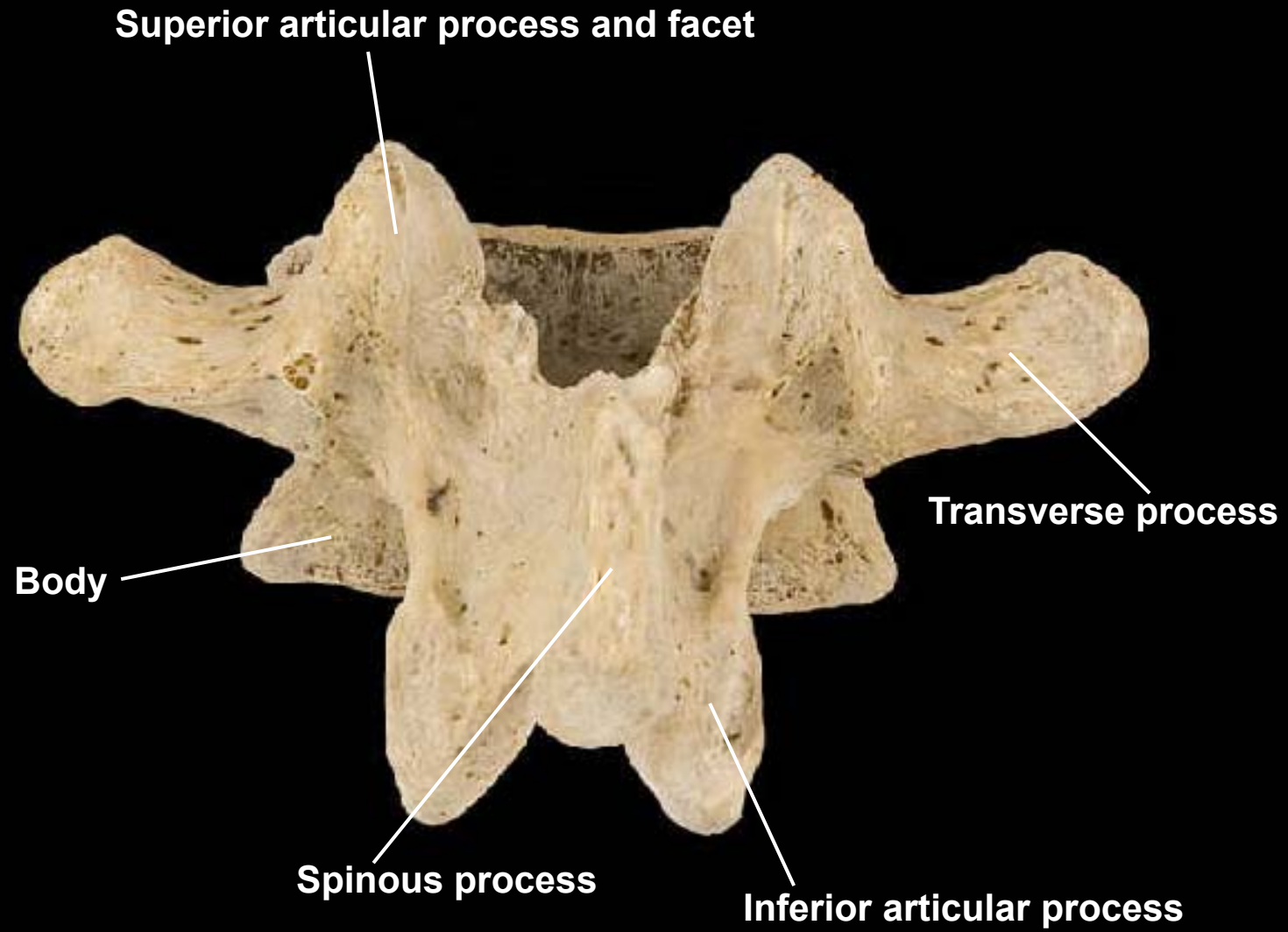
What type of vertebra?

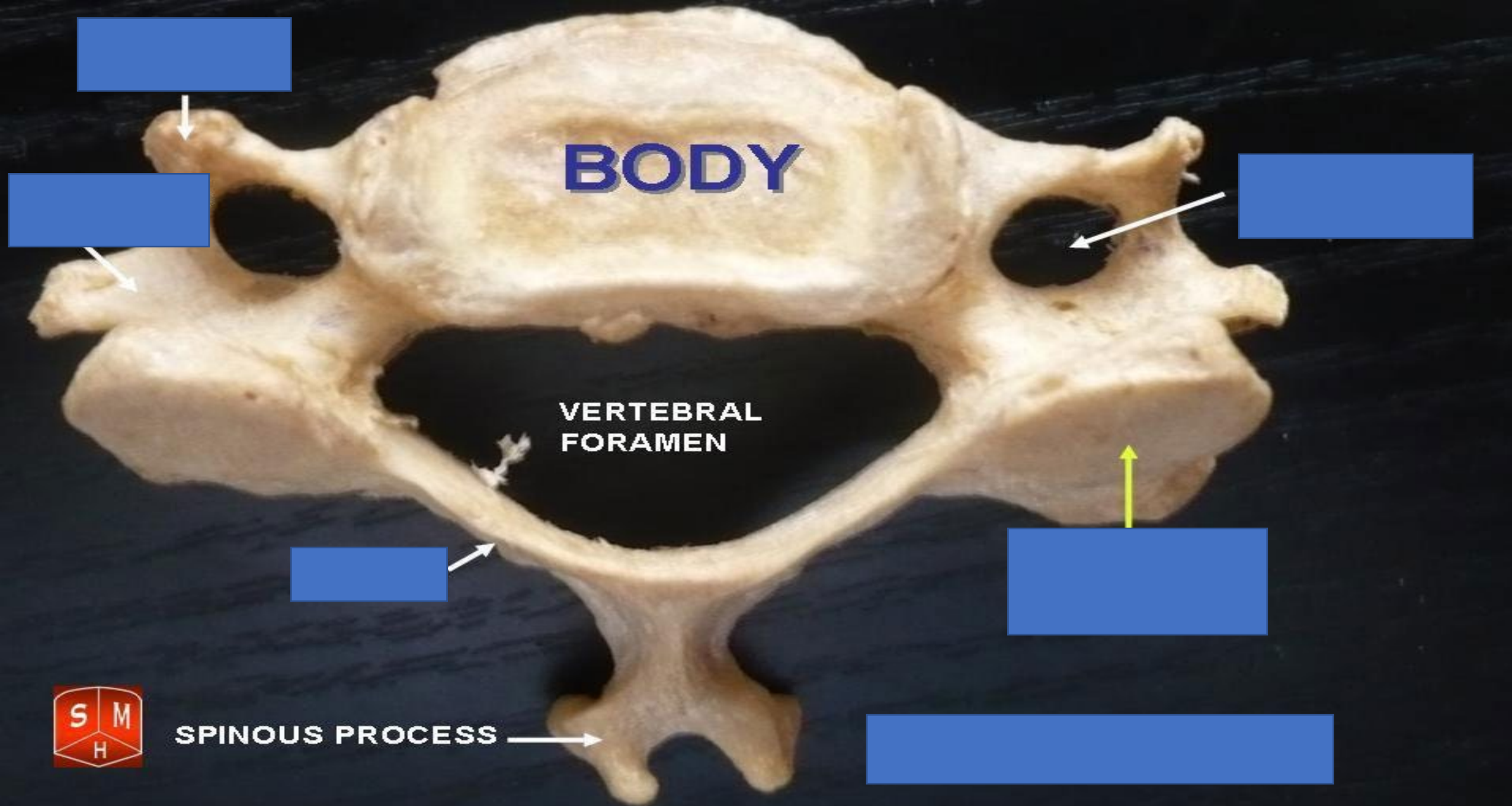


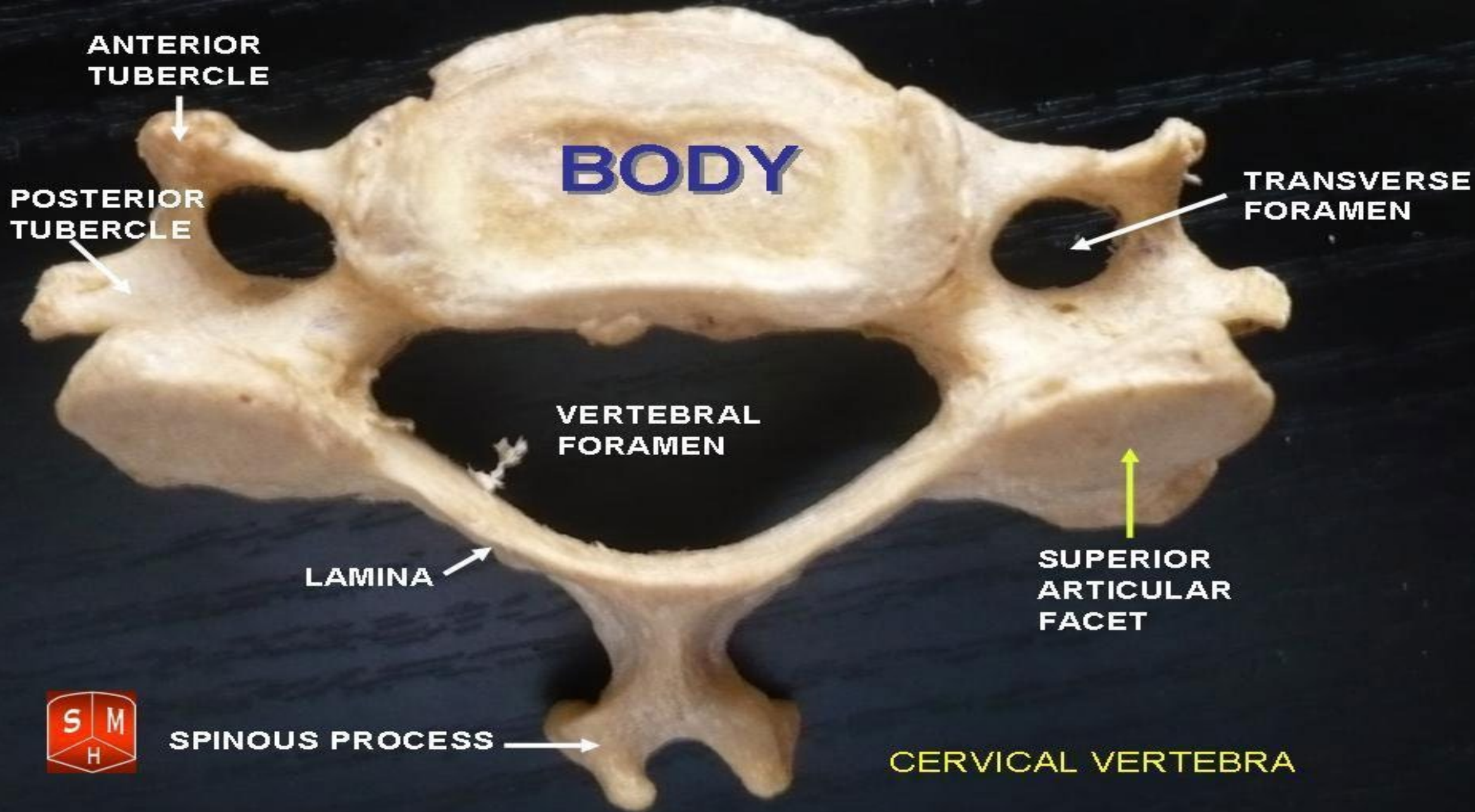
Thoracic vertebra, lateral view, left side



Lumbar vertebra, posterior view

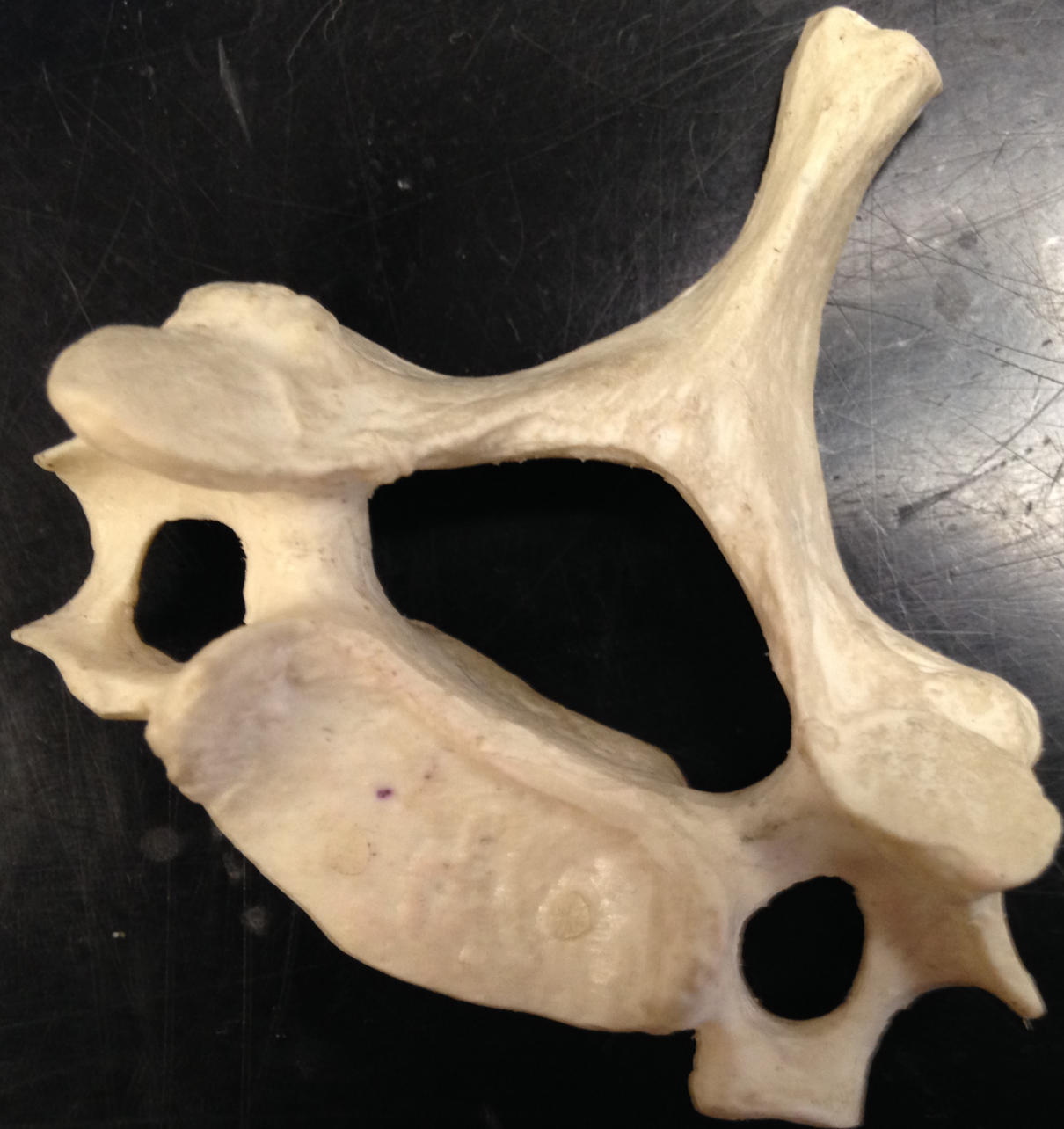




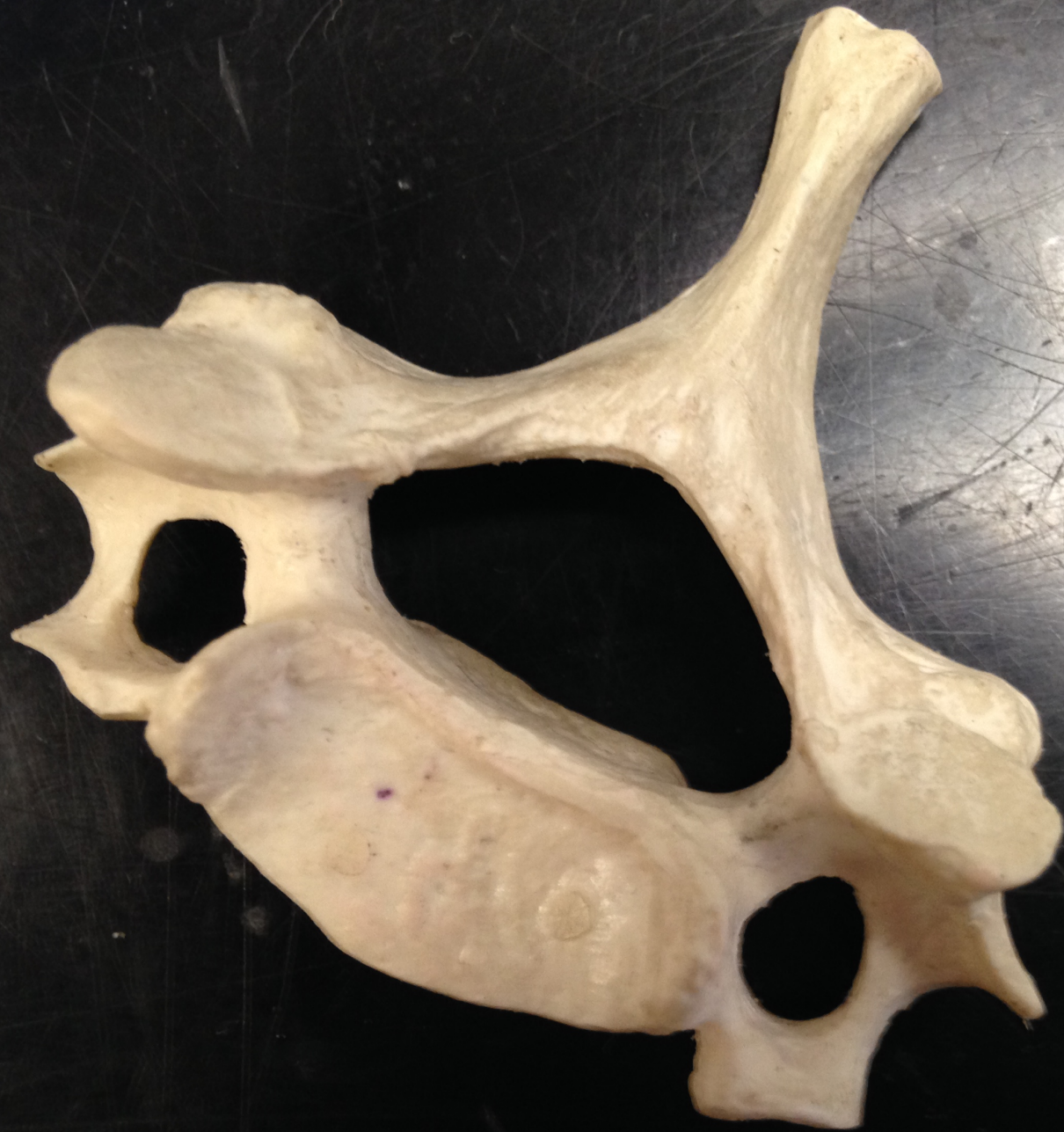
SPINOUS PROCESS

CERVICAL VERTEBRA

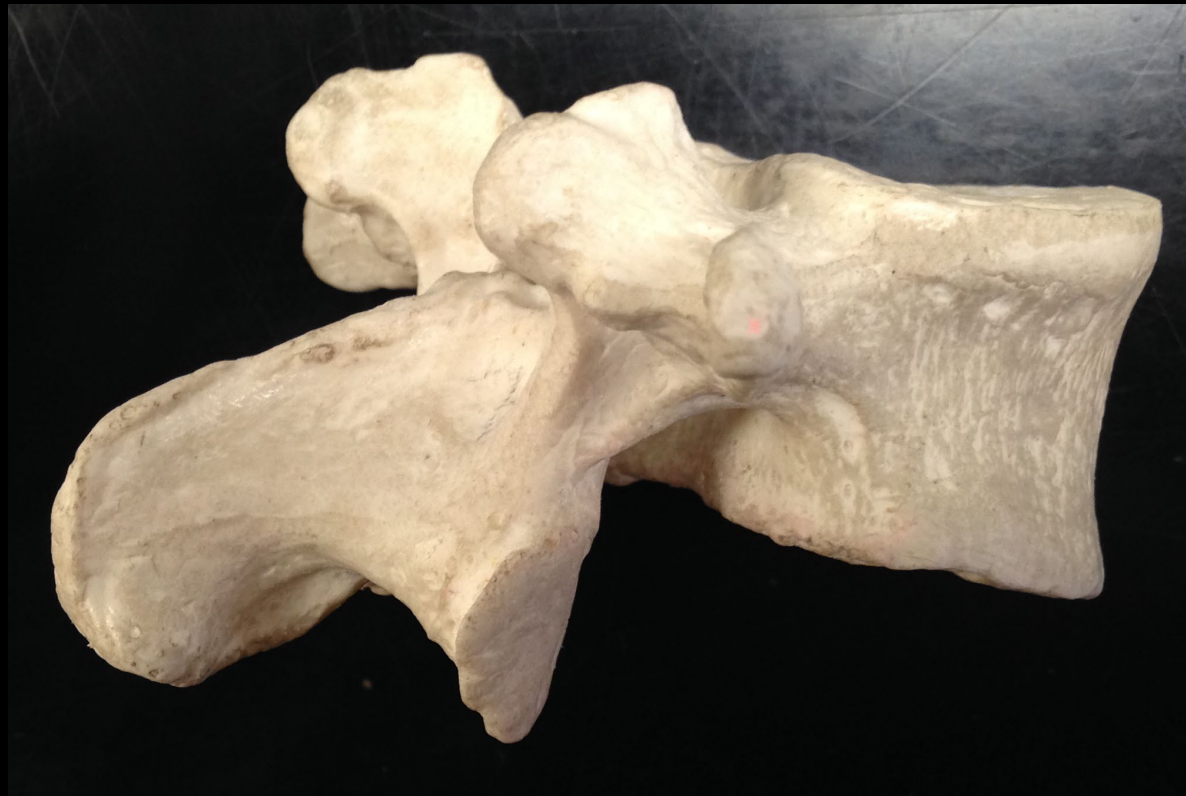

What type of vertebra?

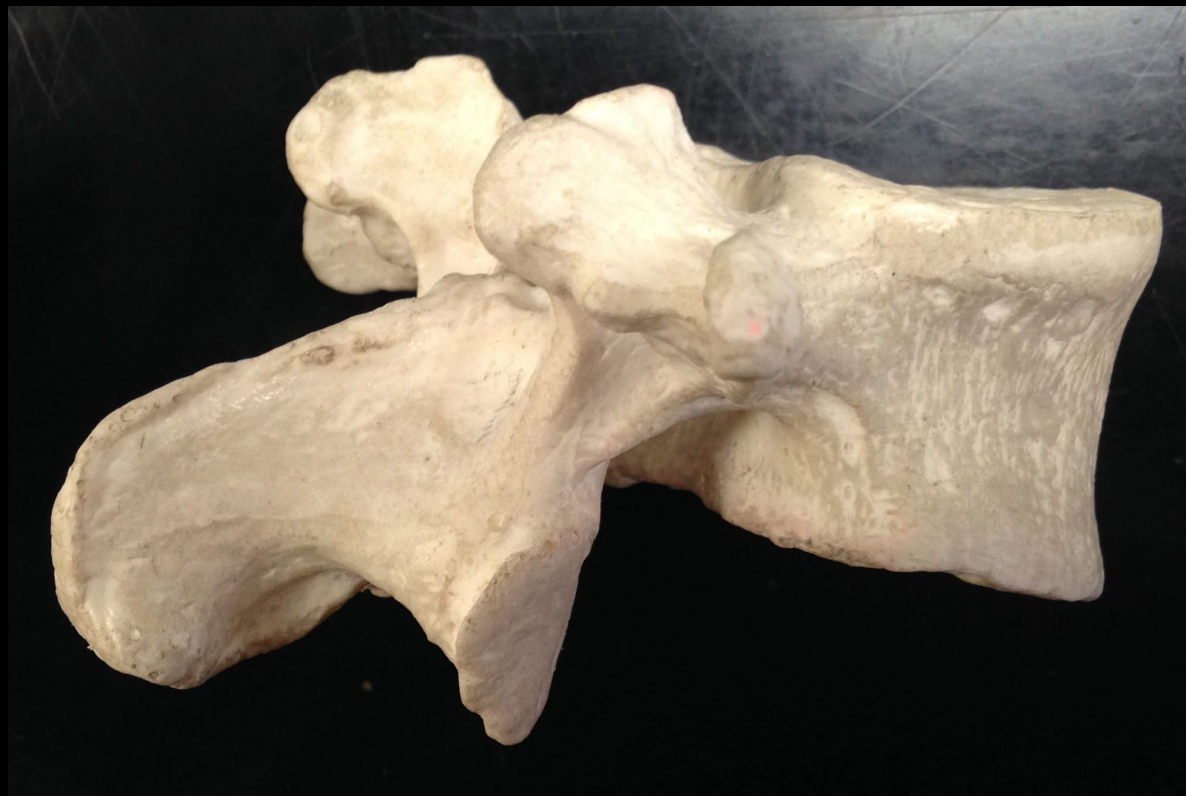

Cervical

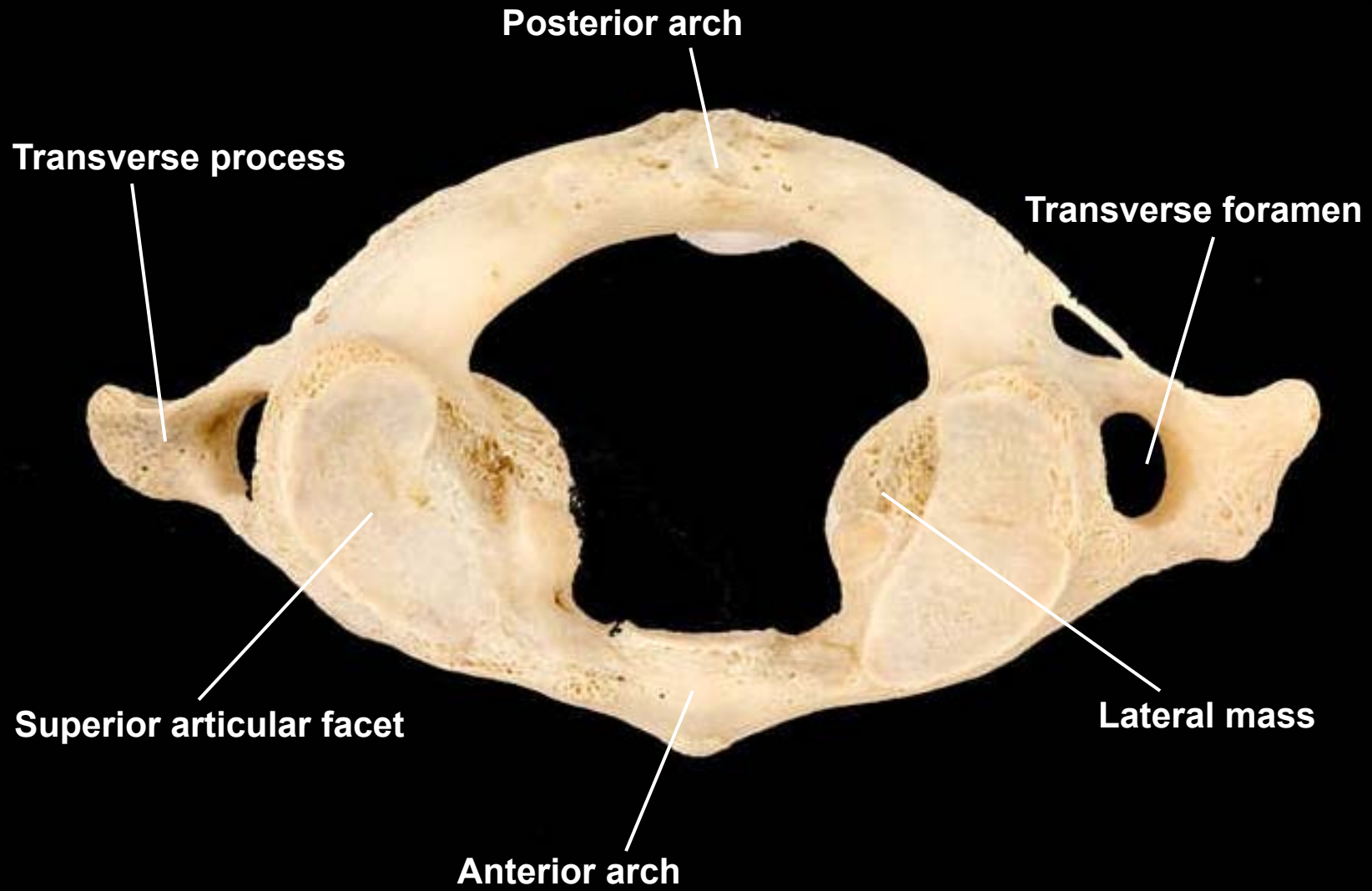
What type o vertebra?



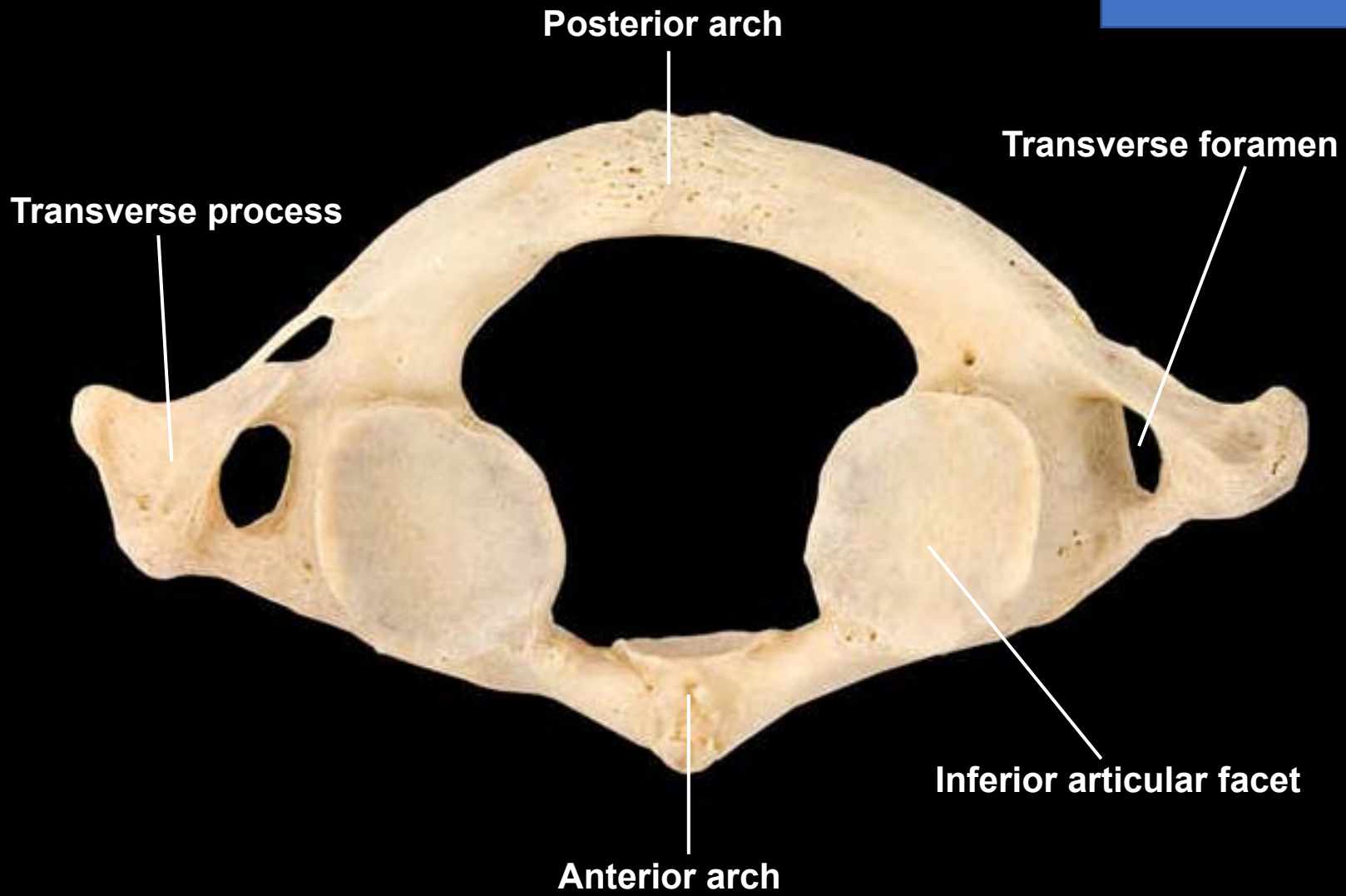
Lumbar



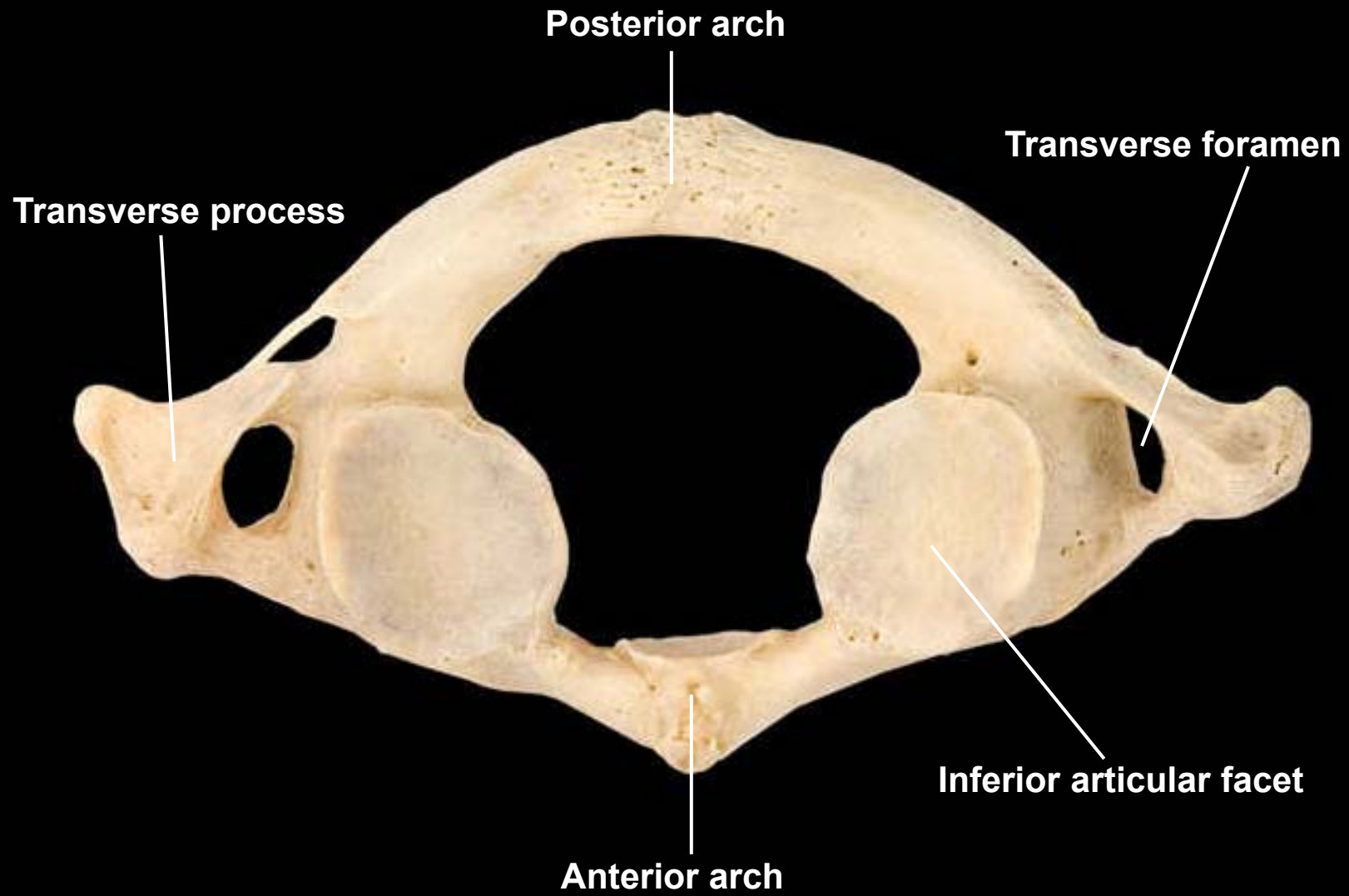
Atlas, superior view

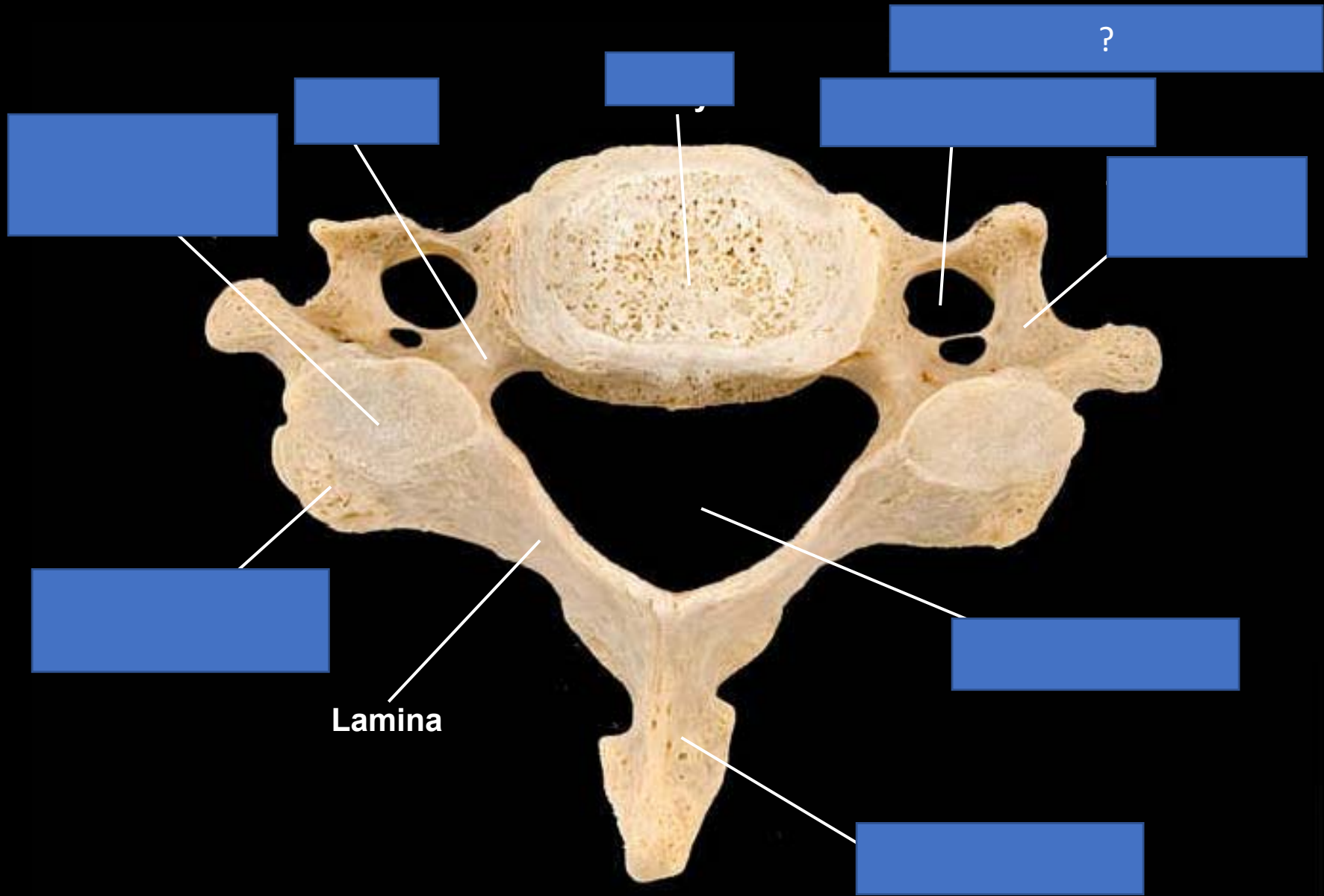


What view is this bone?

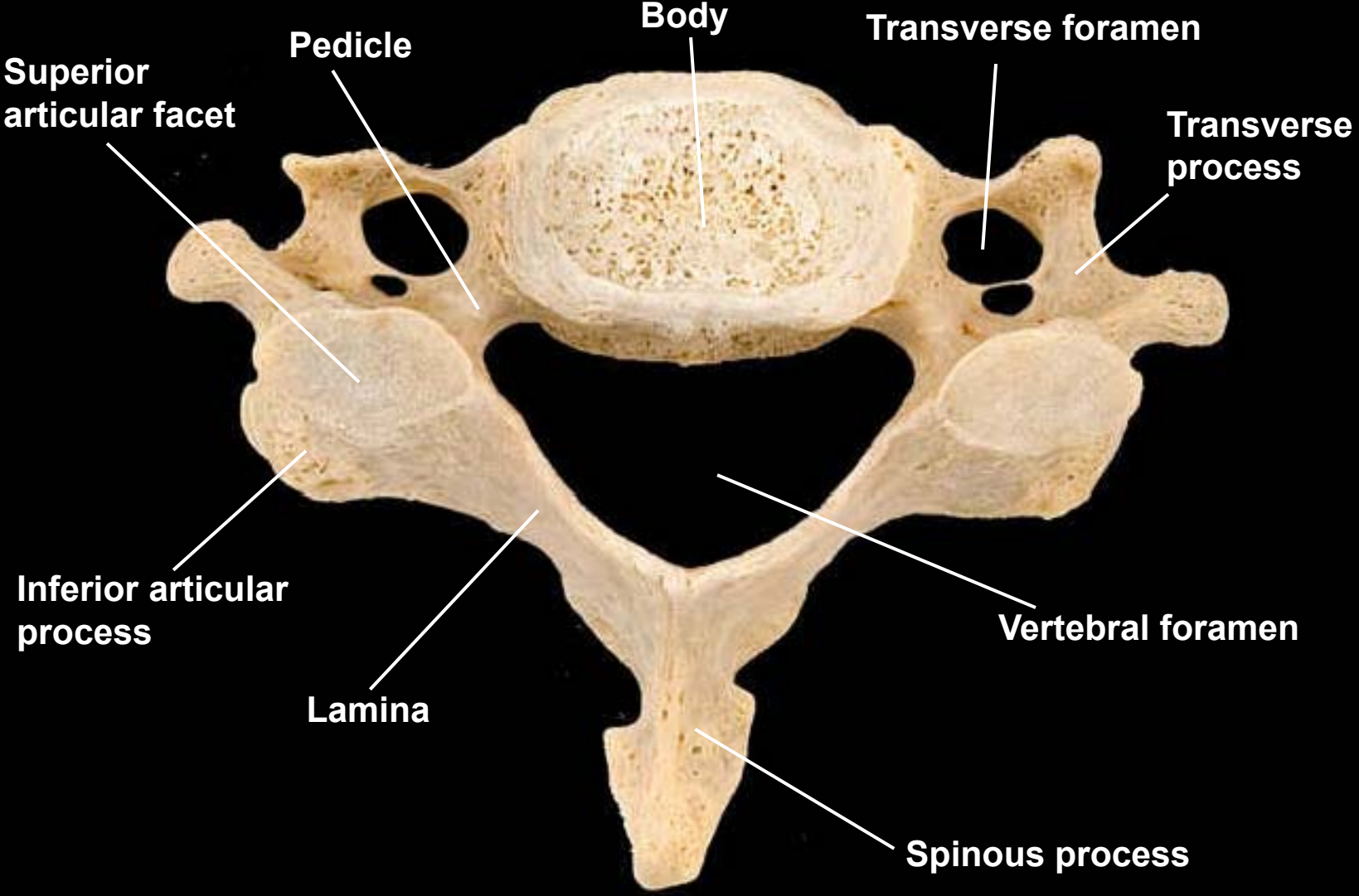


Atlas, inferior view

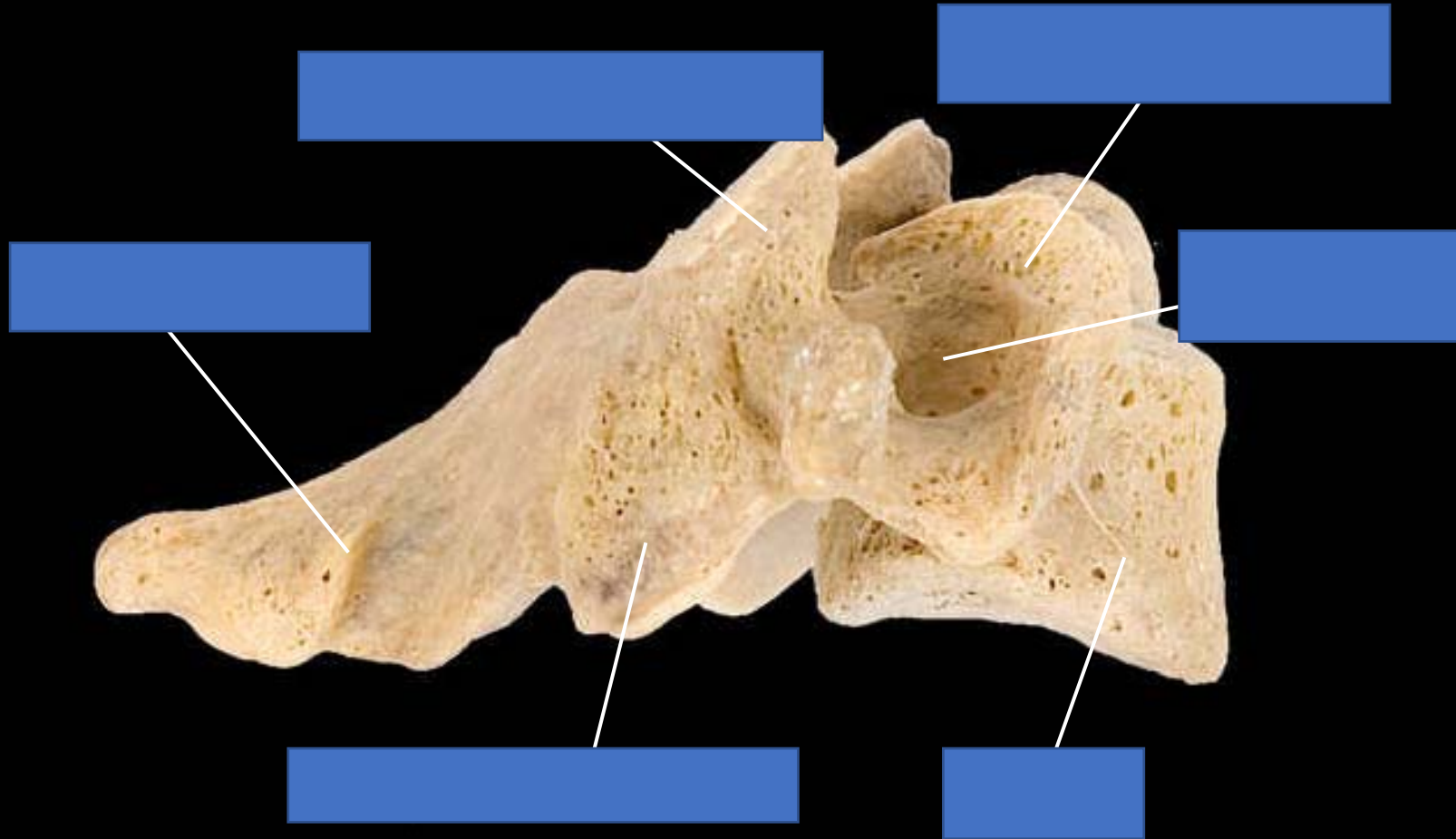




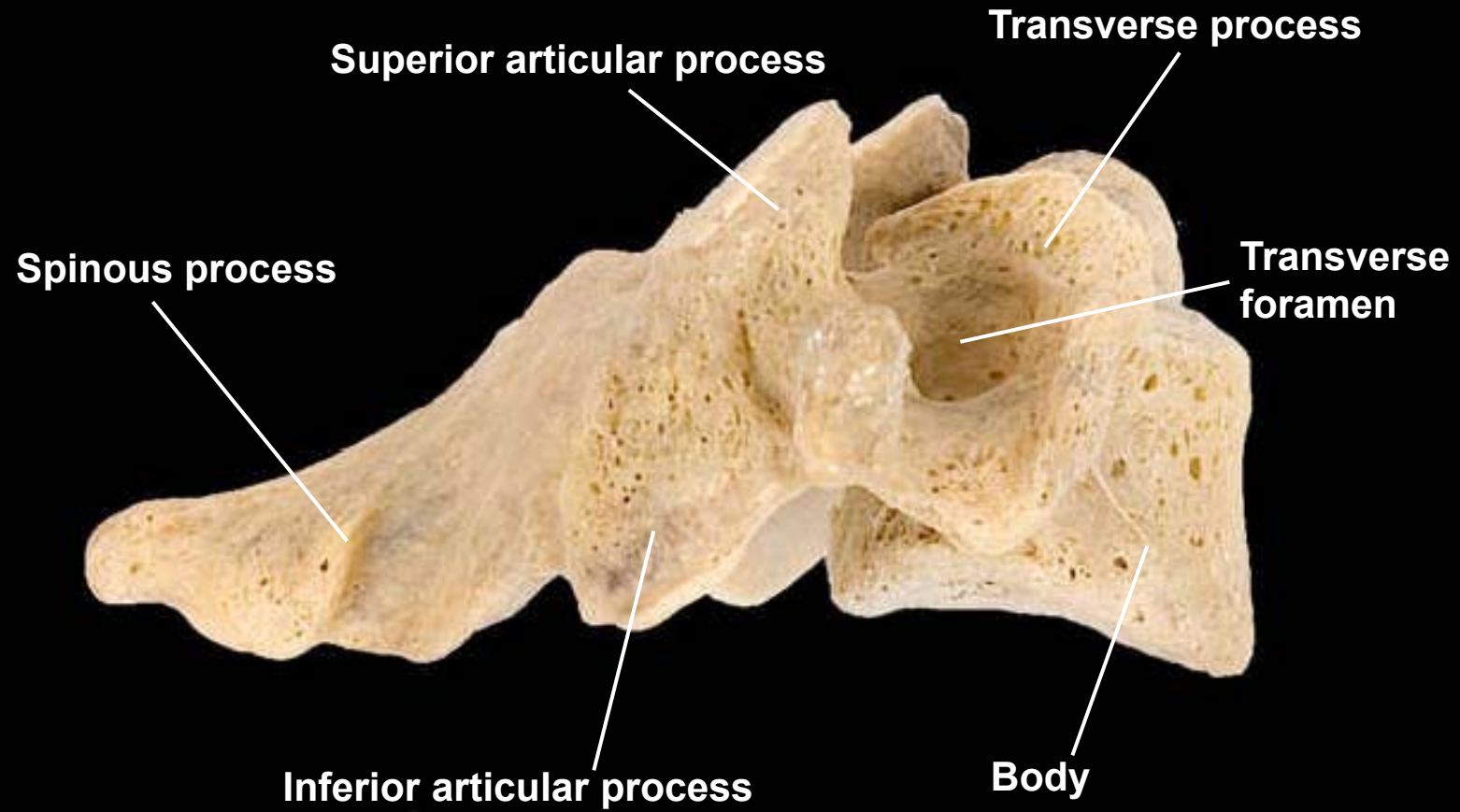
Cervical vertebra, superior view

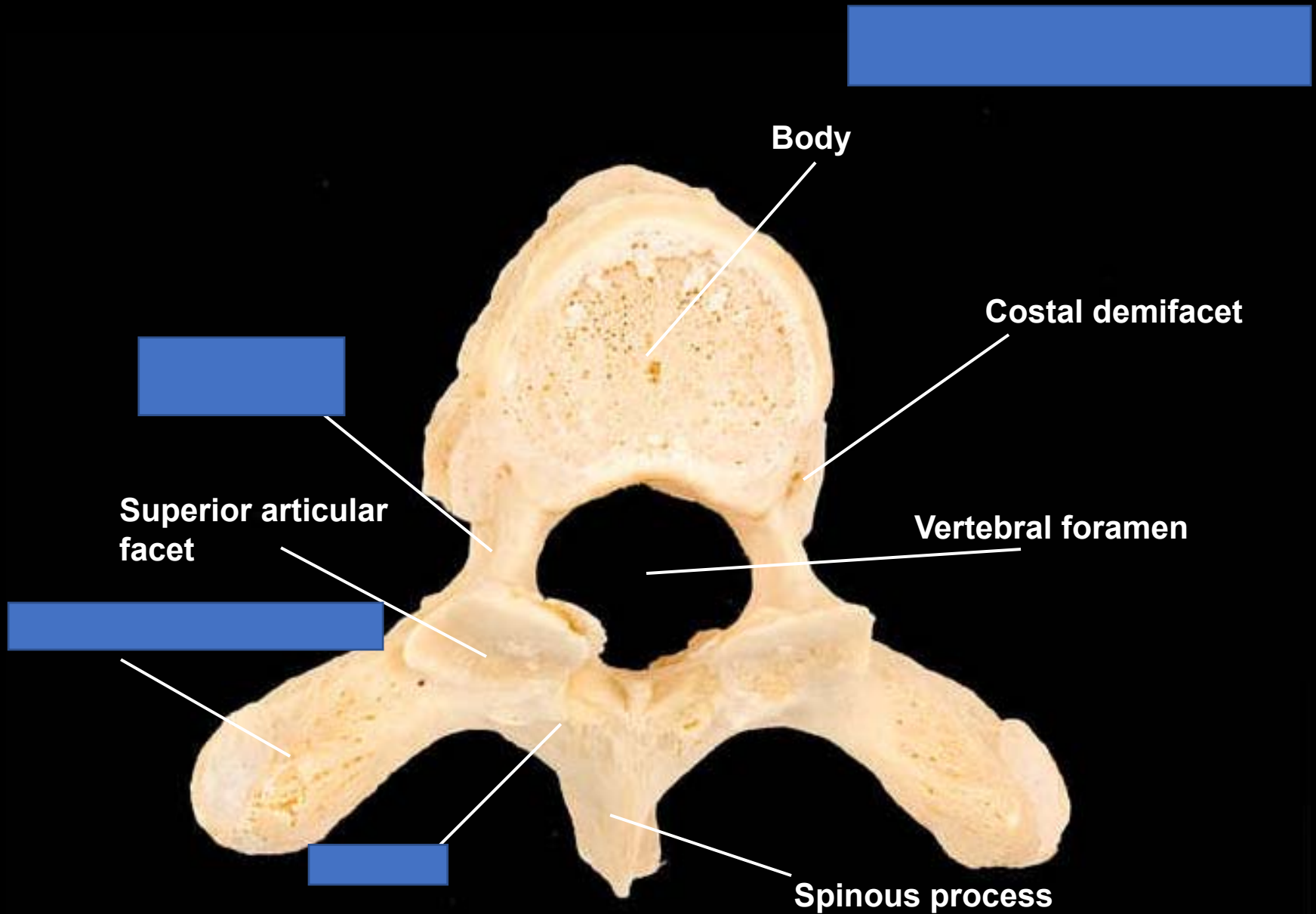


Cervical vertebra, lateral view, right side



Cervical vertebra, lateral view, right side





Body

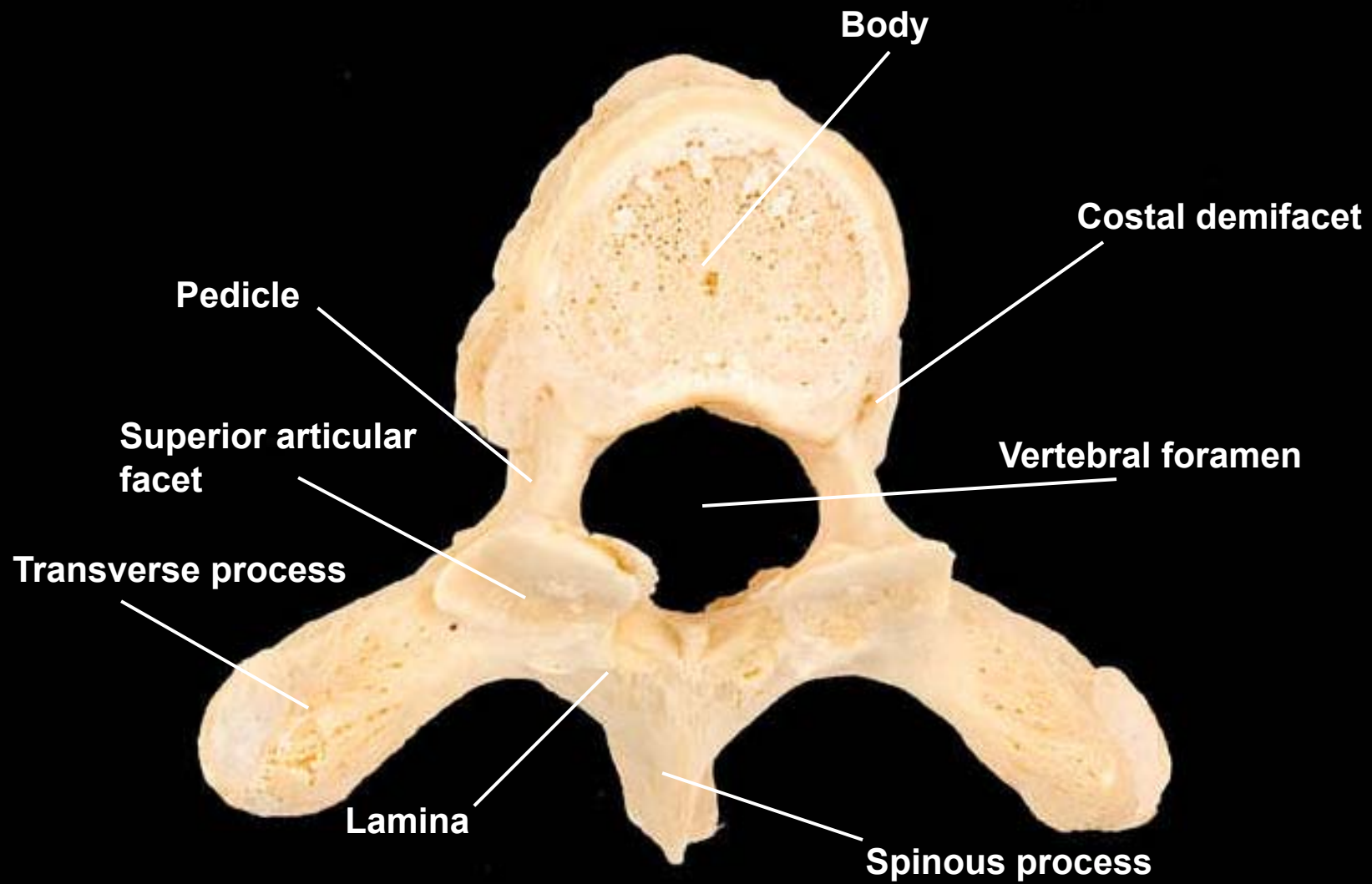
Costal demifacet

Superior articular
facet

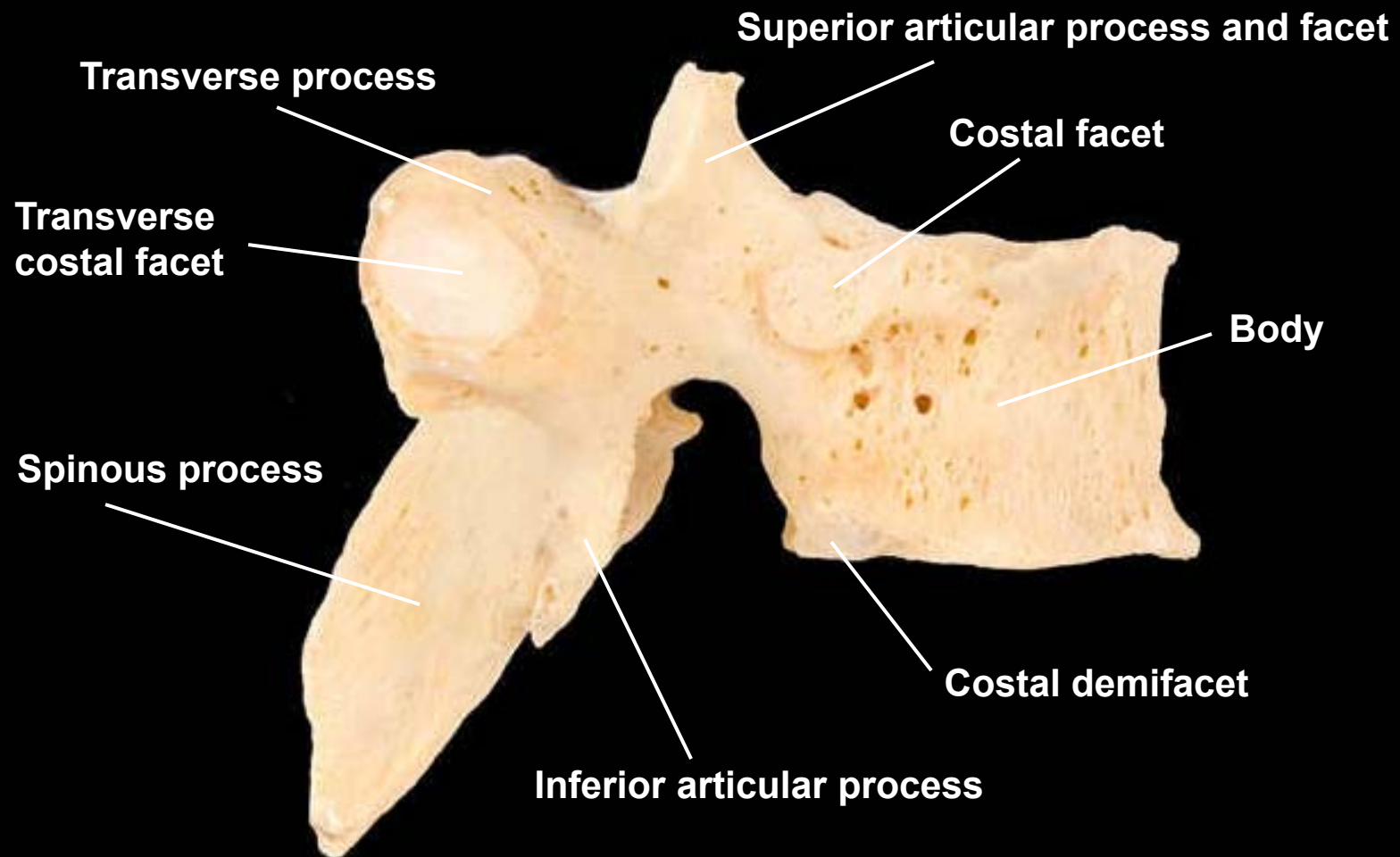
Vertebral foramen

Spinous process

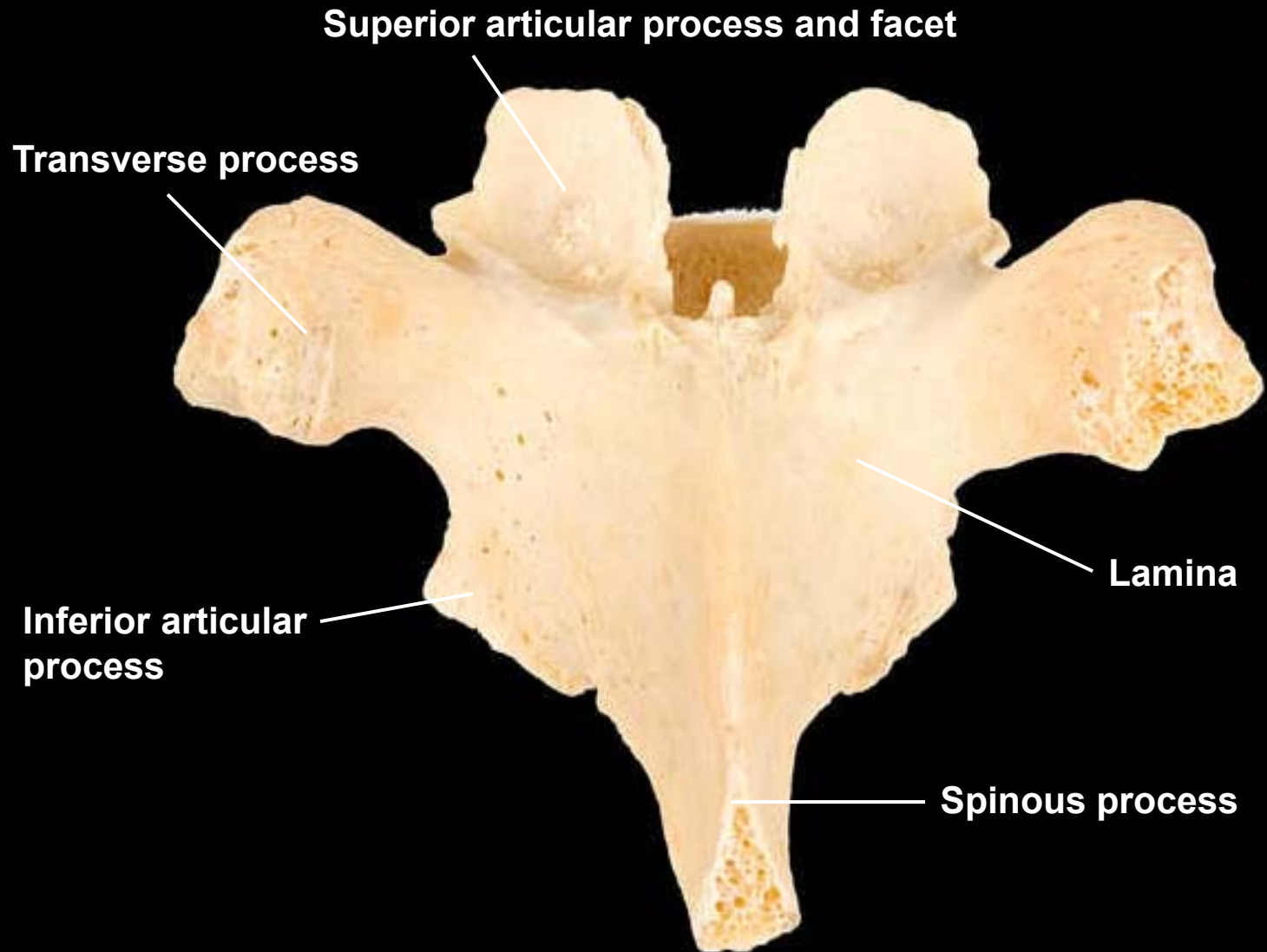
Thoracic vertebra, superior view



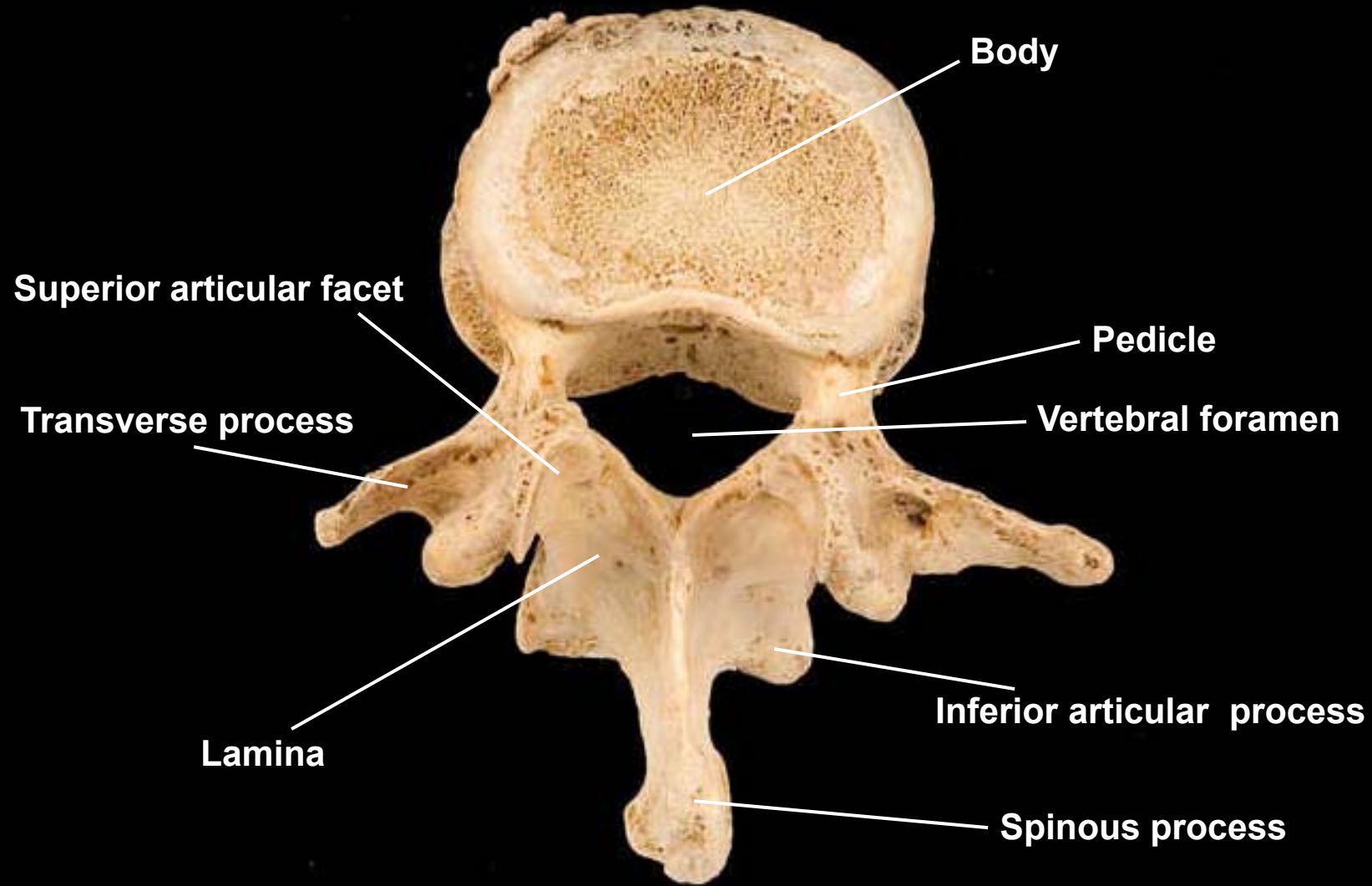
Thoracic vertebra, lateral view, right side



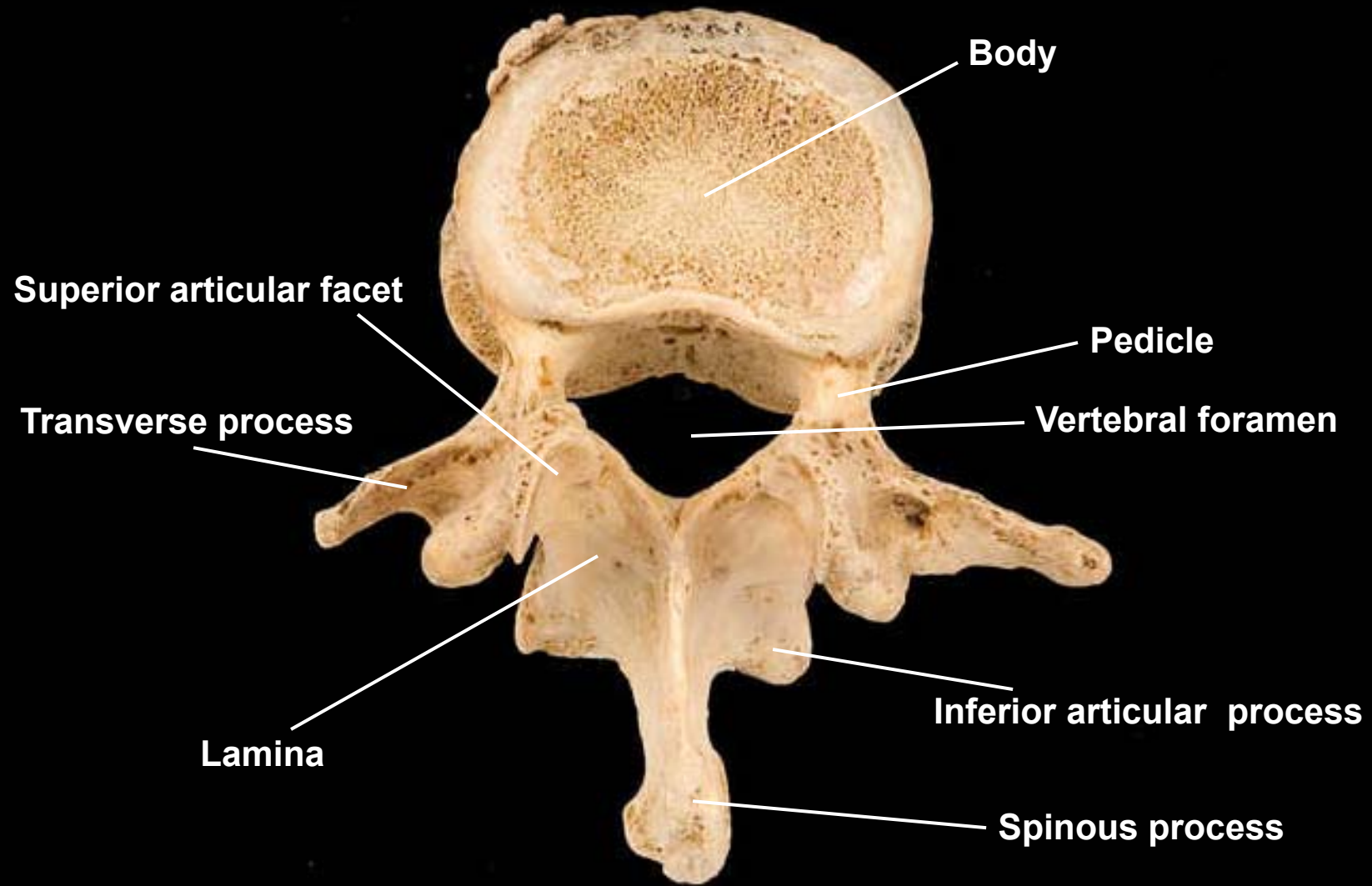
Thoracic vertebra, posterior view



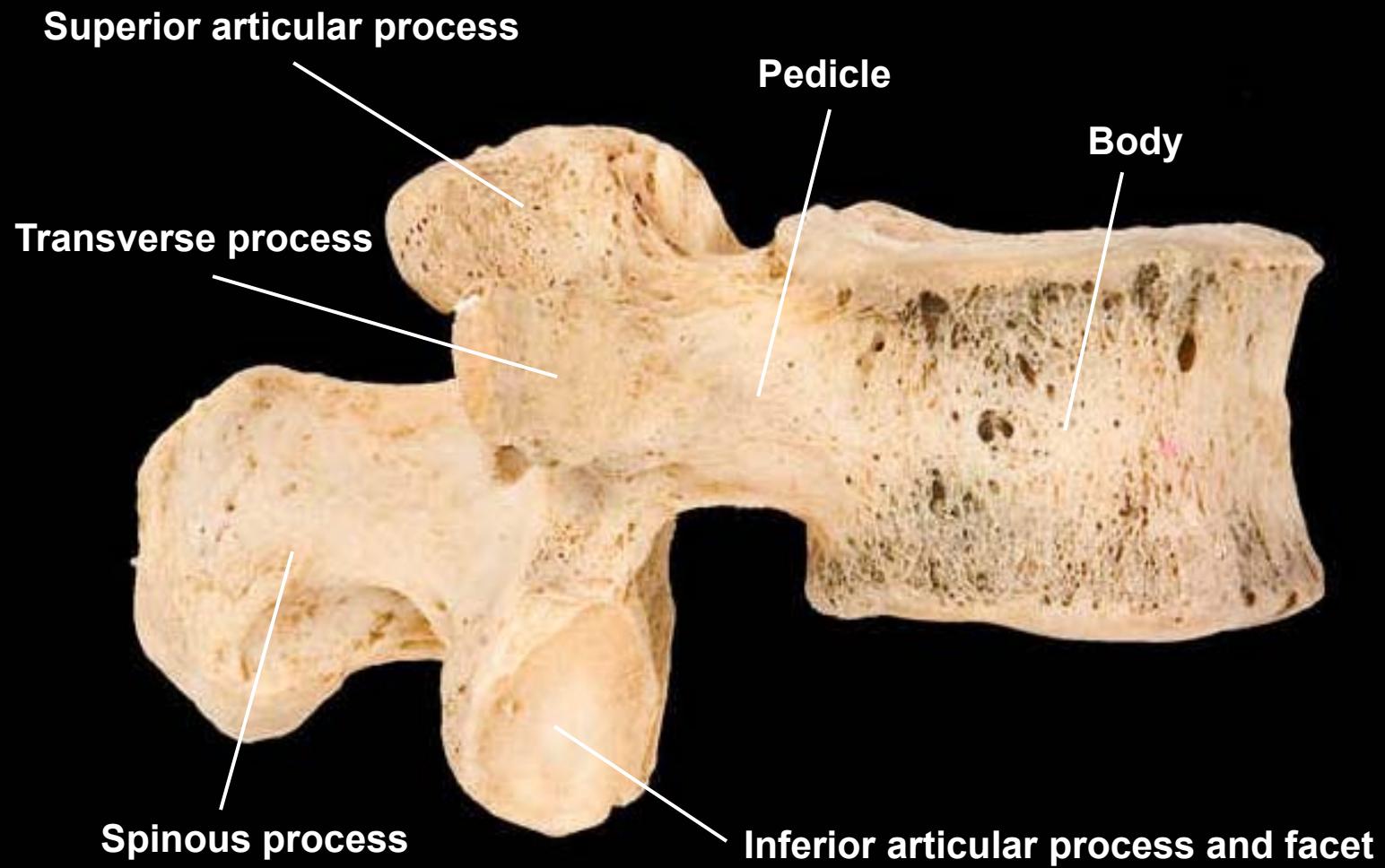
?



Lumbar vertebra, superior view



Lumbar vertebra, lateral view, right side

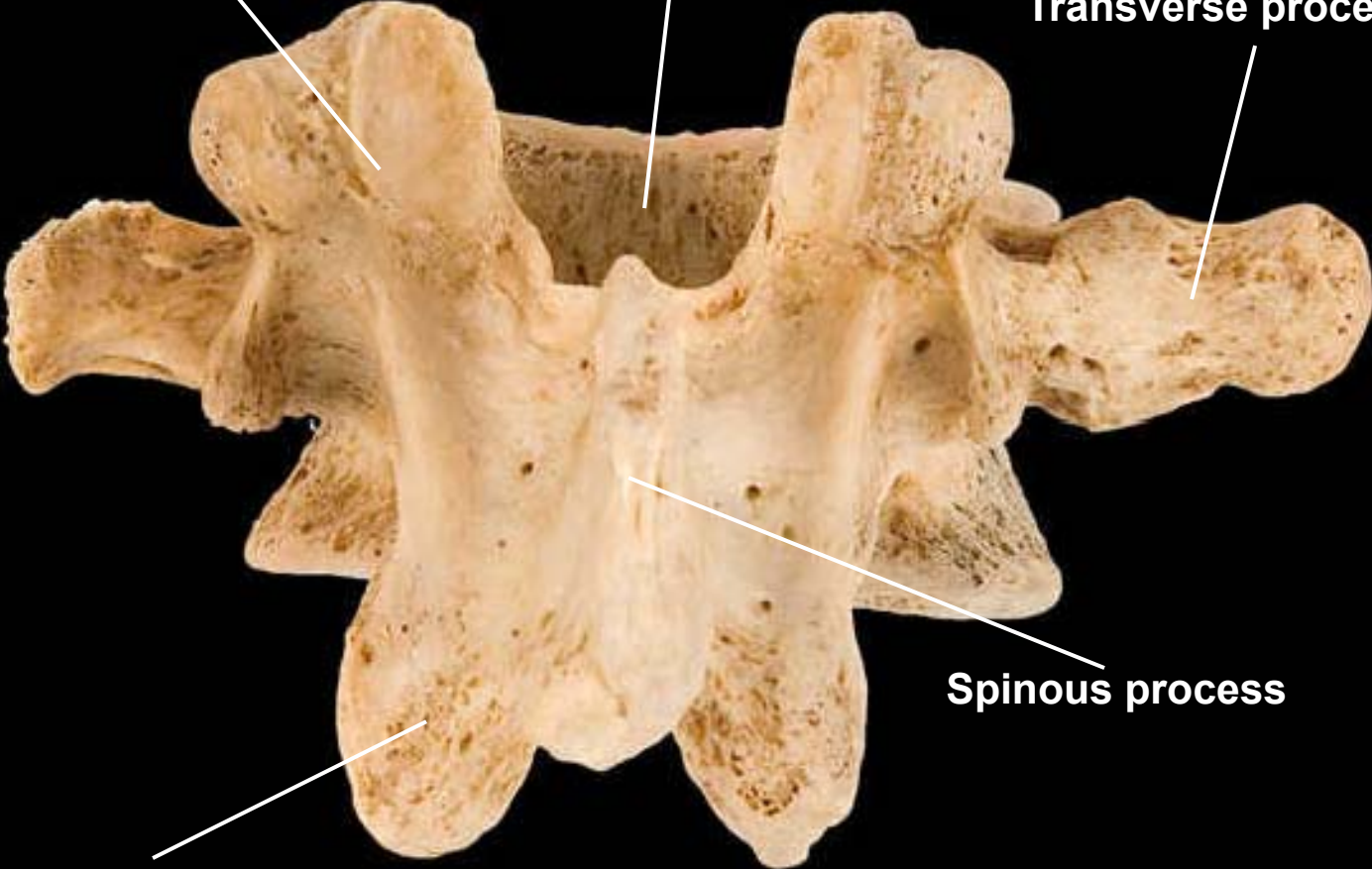


Lumbar vertebra, posterior view

Superior articular process and facet

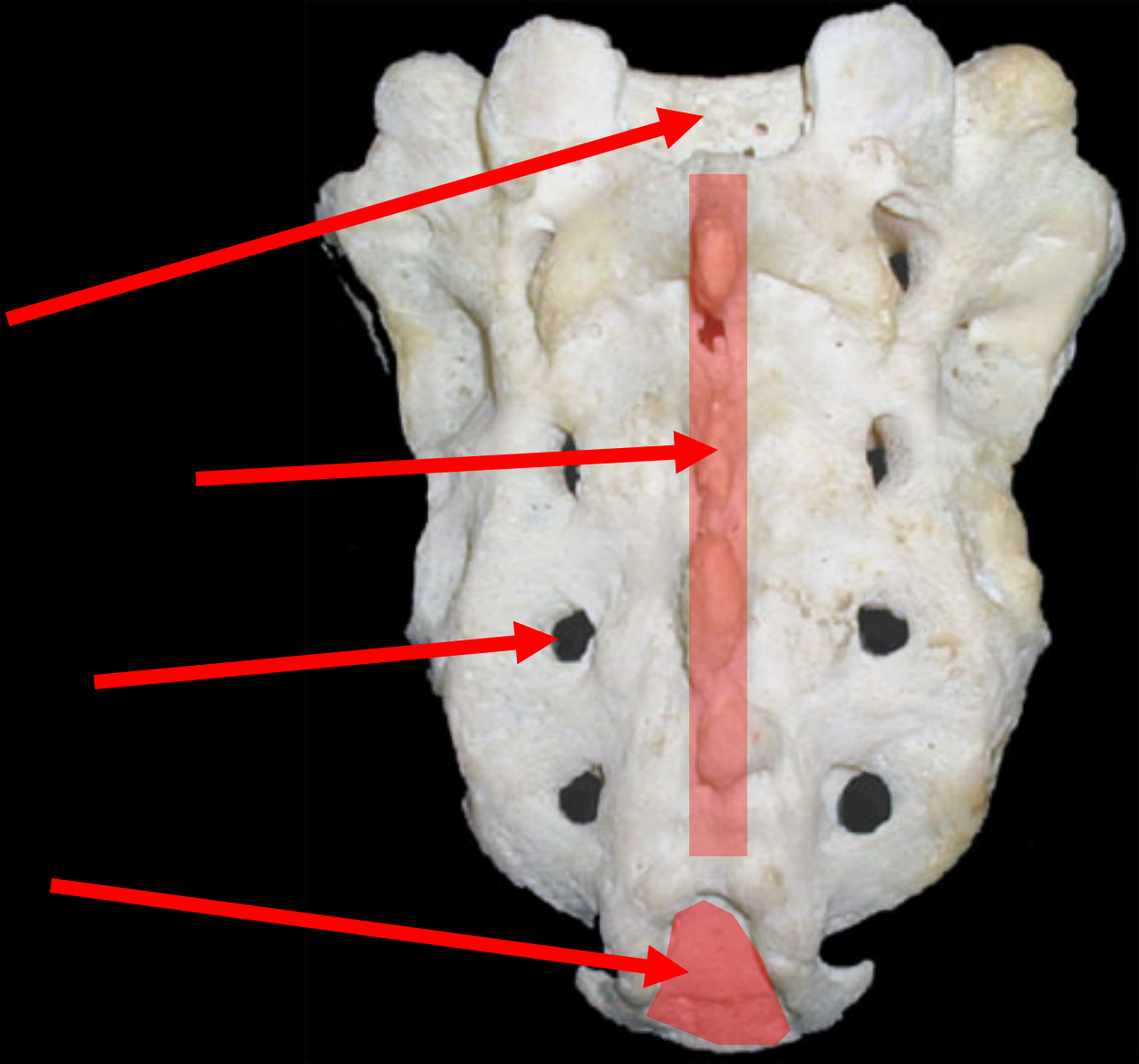
Body

Transverse process



Spinous process

Inferior articular process



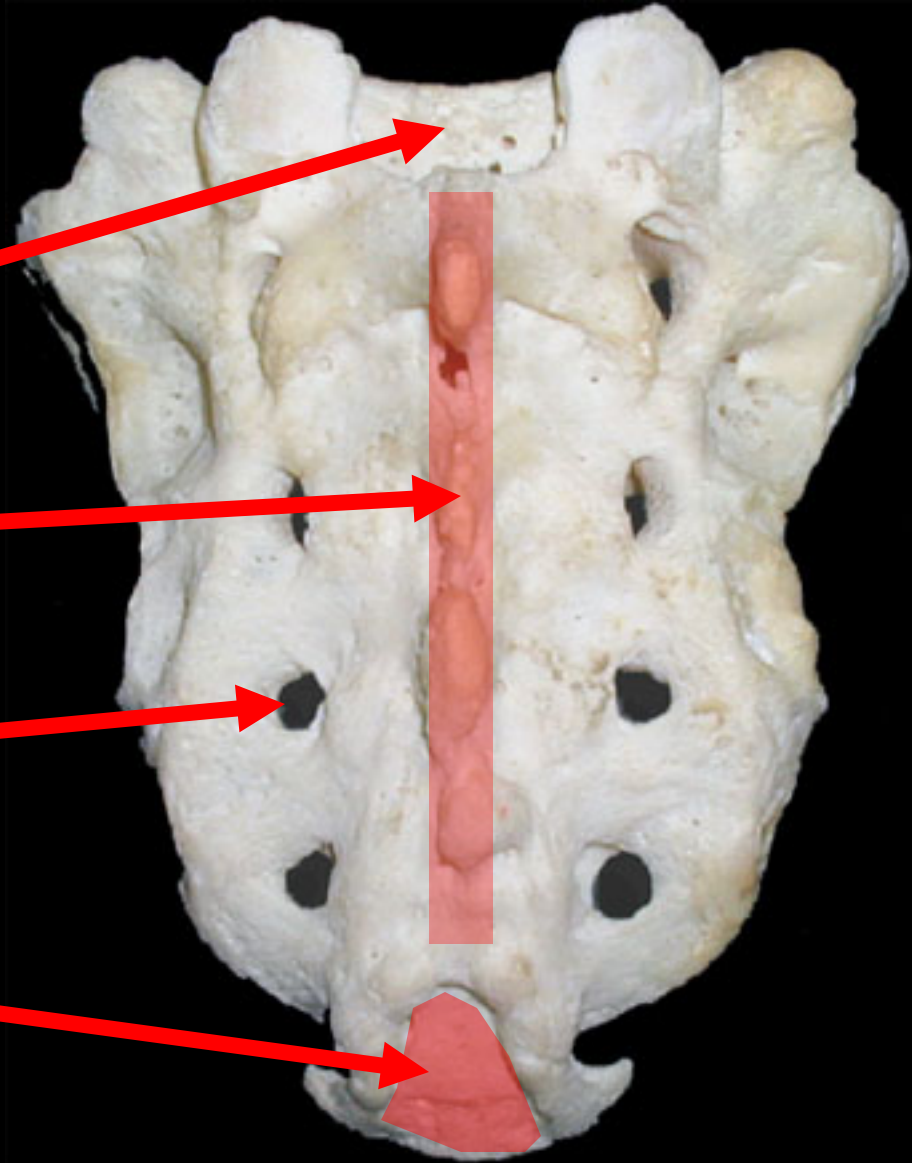
Sacrum (5 fused vertebrae)

sacral canal

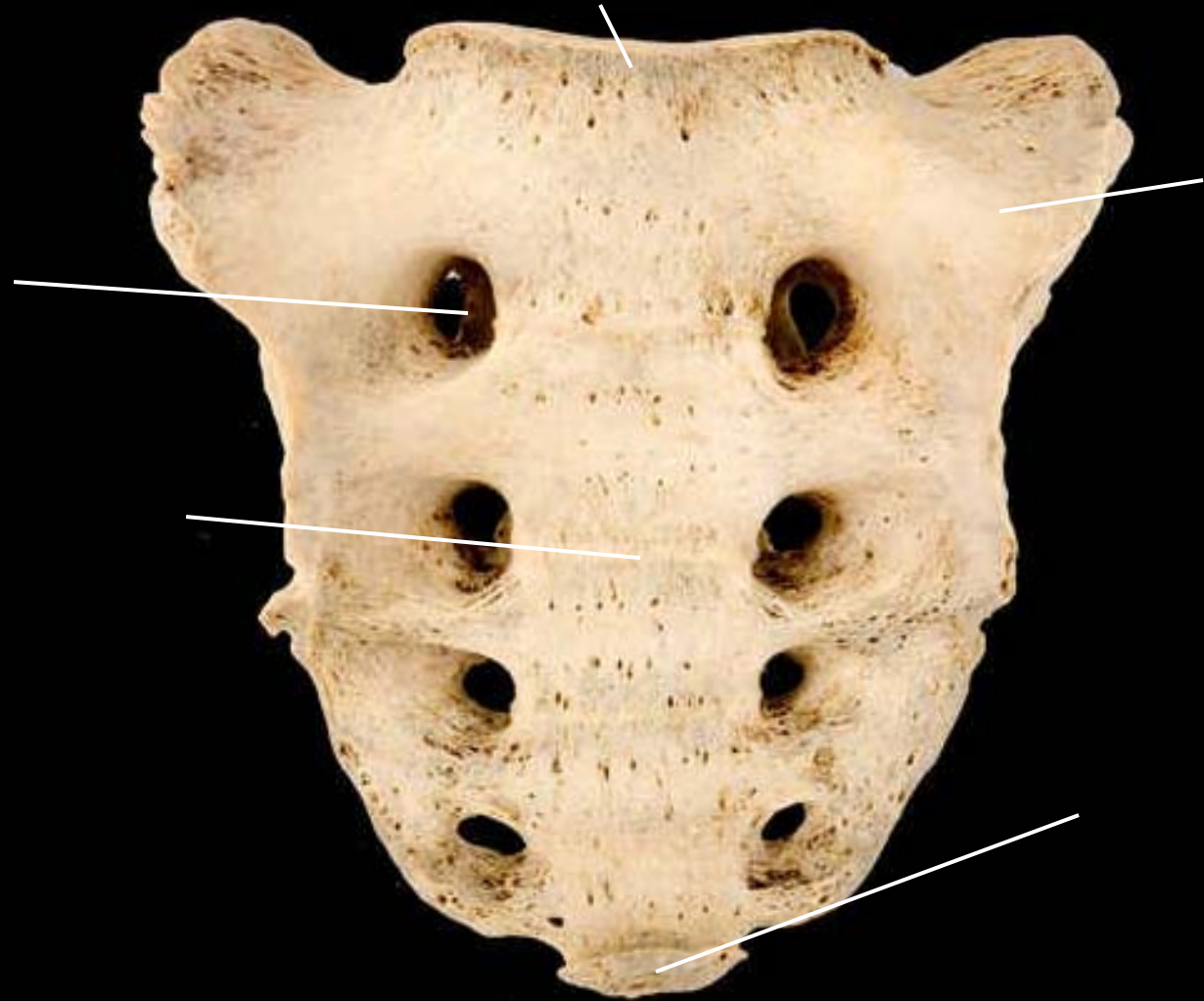medial sacral
crest

sacral foramen

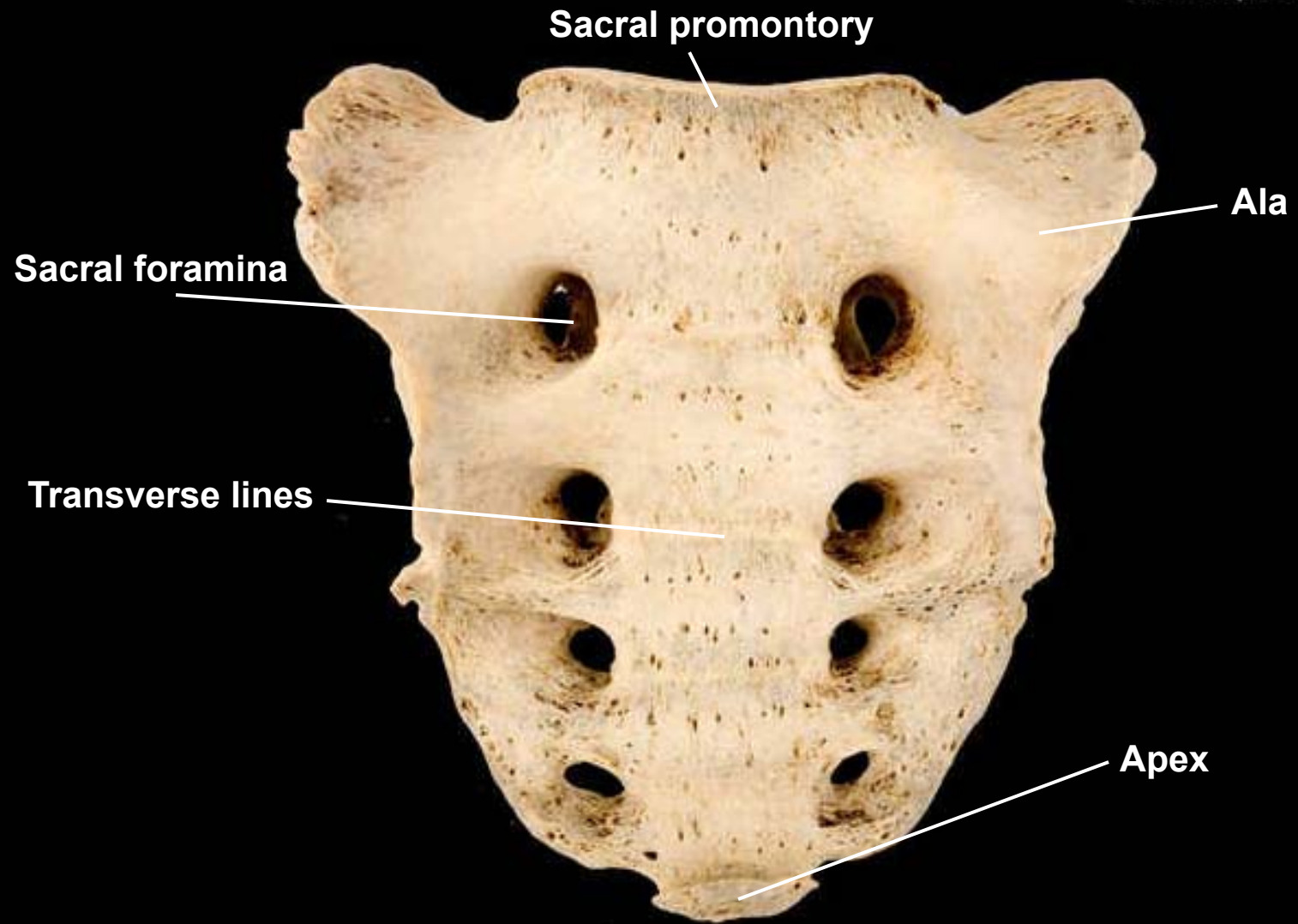
sacral hiatus

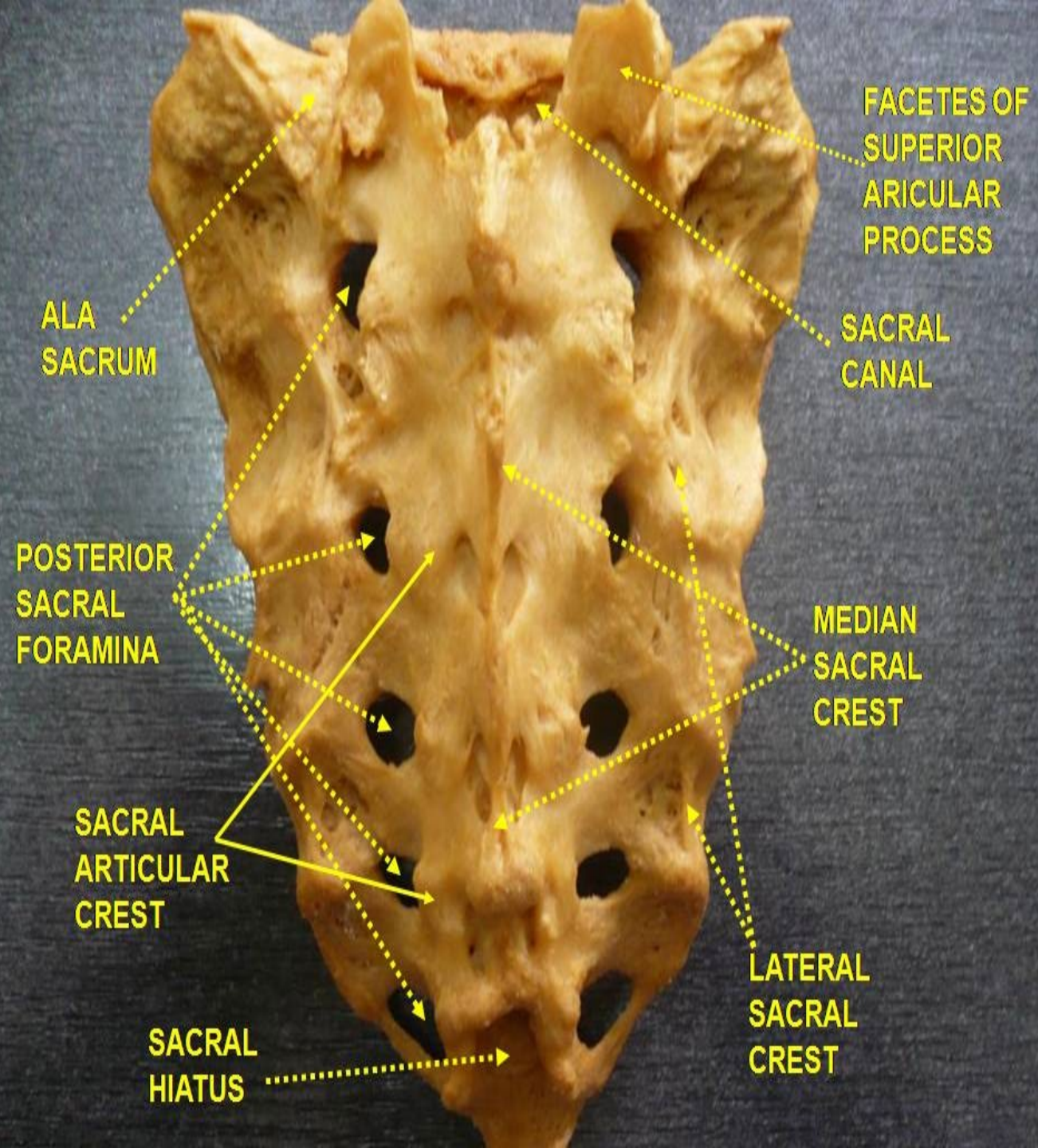
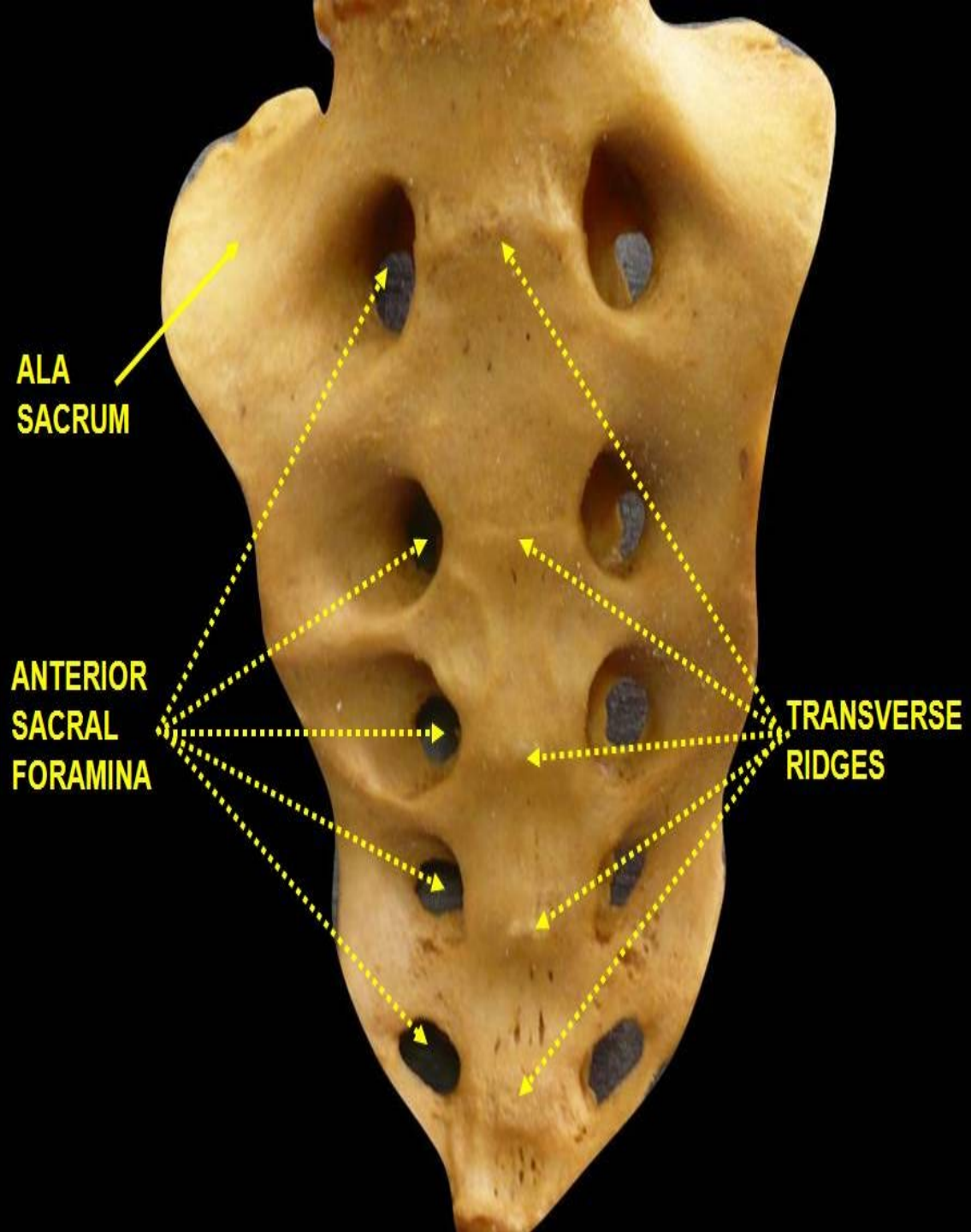


Sacrum, anterior view

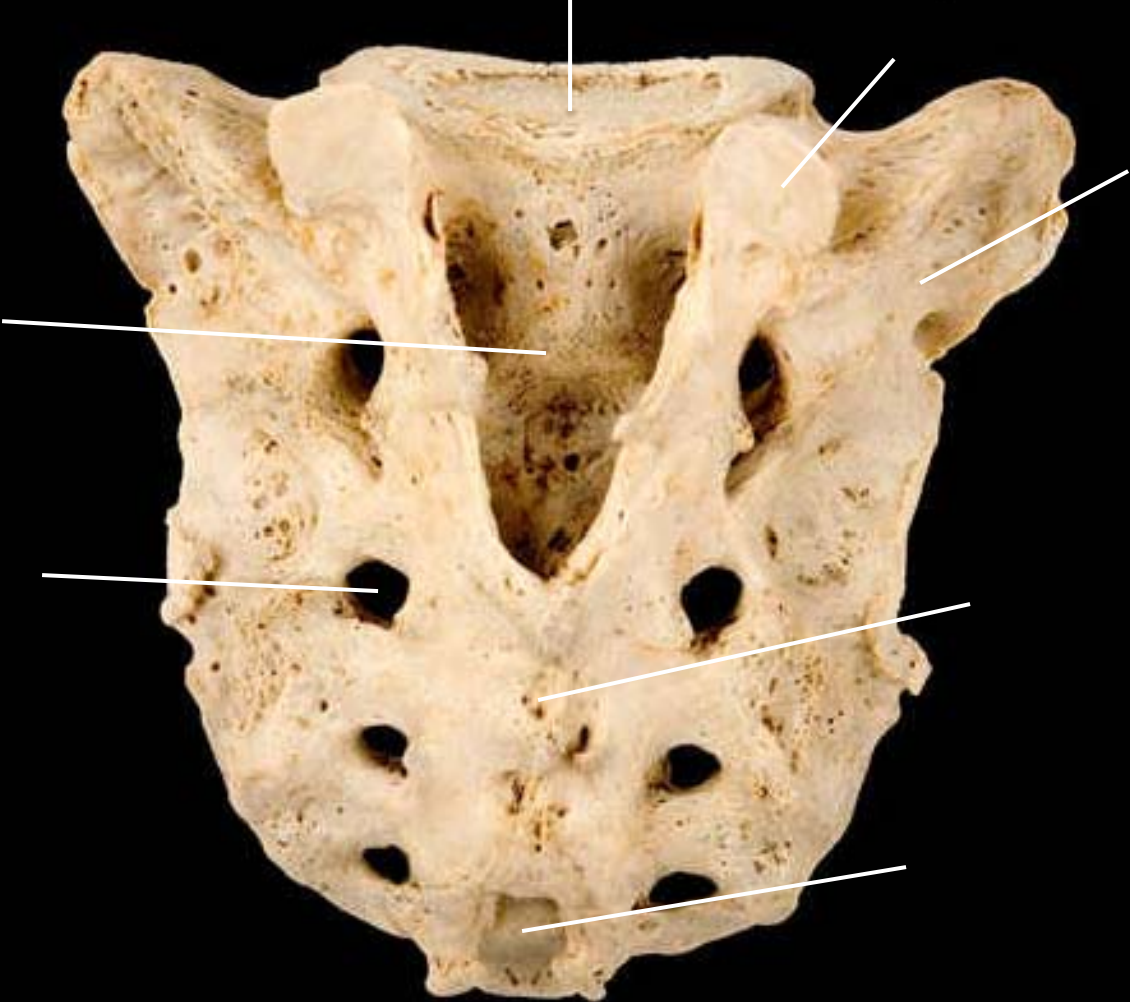


Sacrum, anterior view

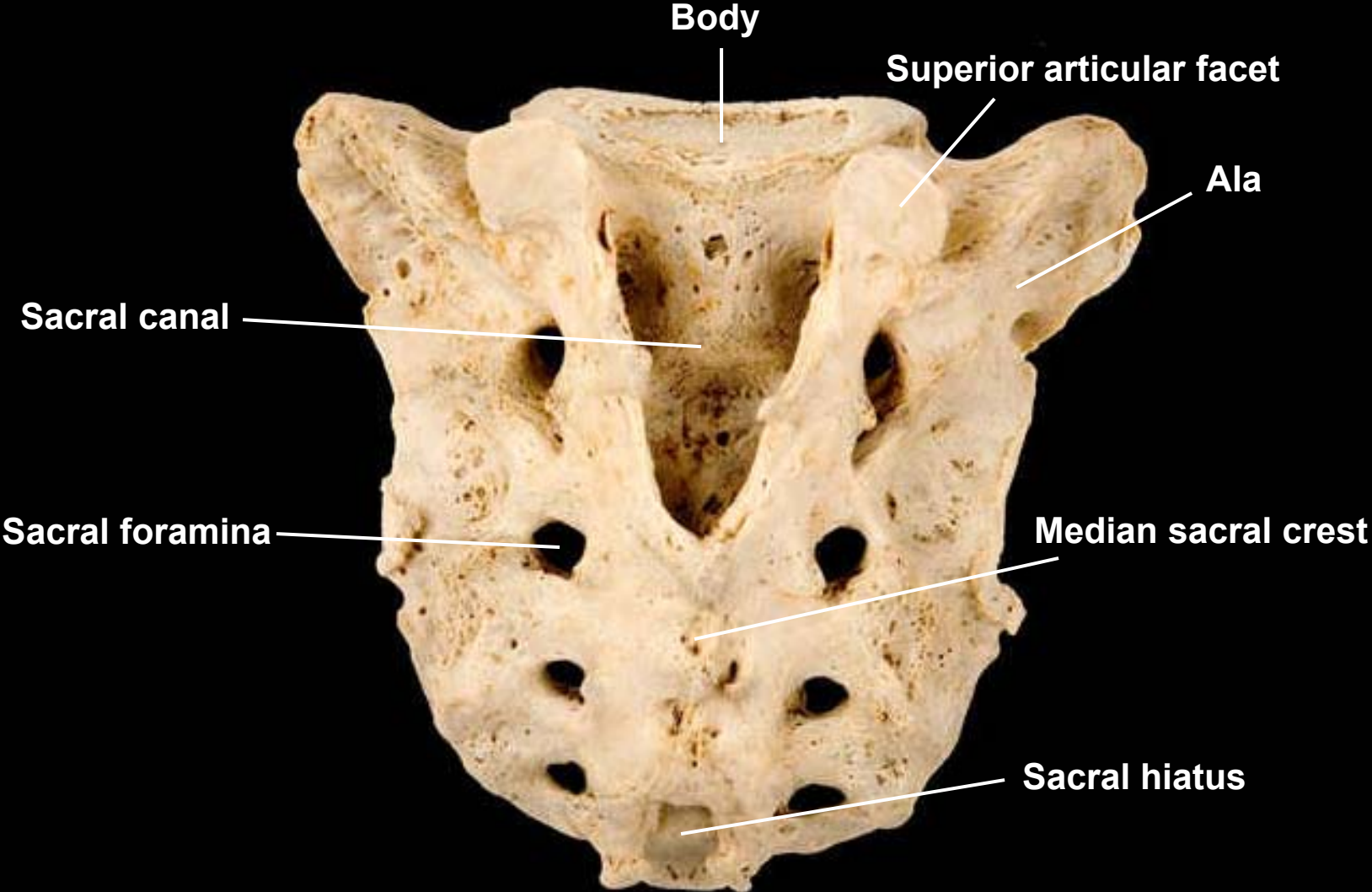




Sacrum, posterior view

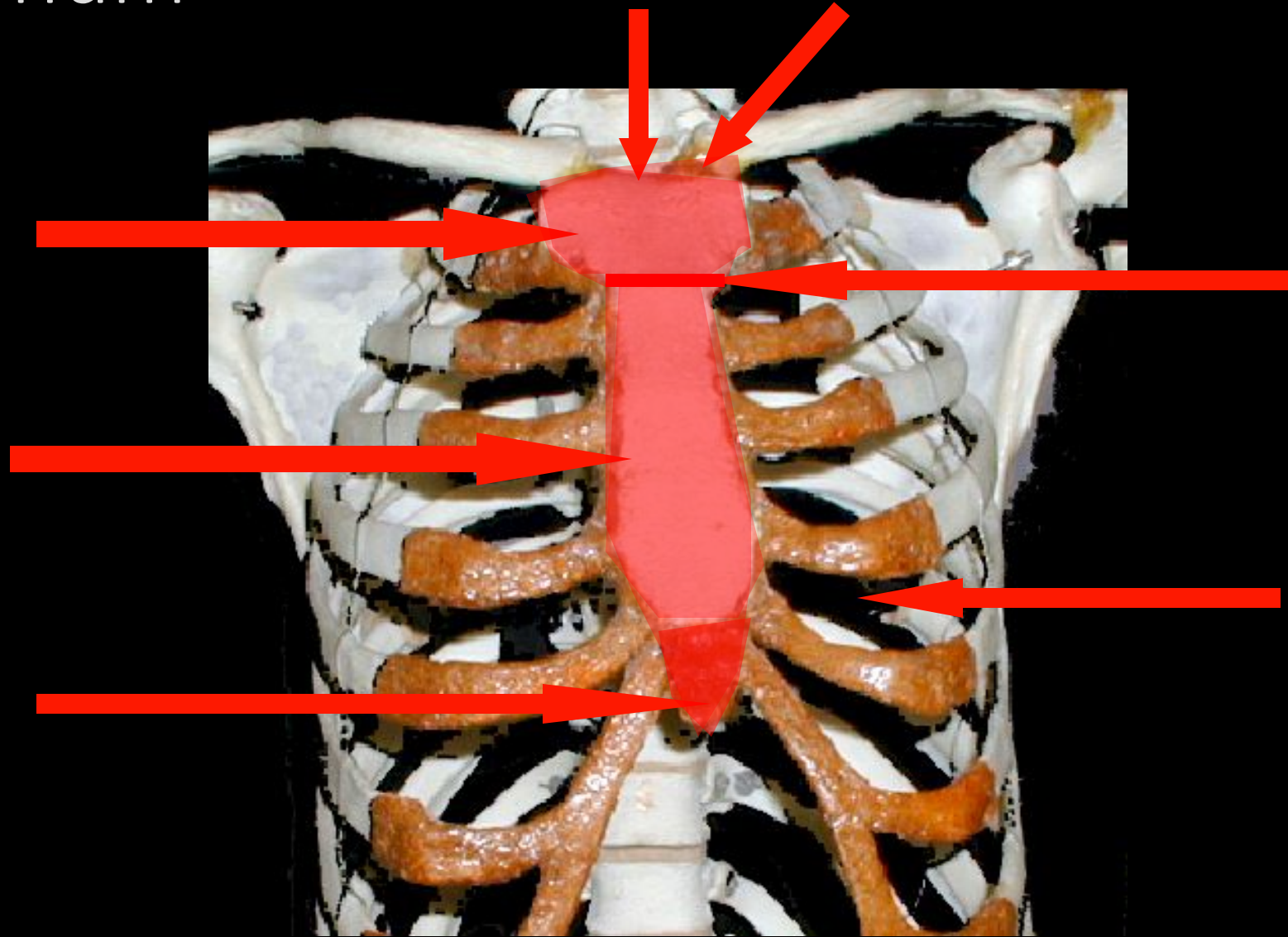


Sacrum, posterior view



The Thorax

Sternum



Sternum

sternal notch

clavicular notch

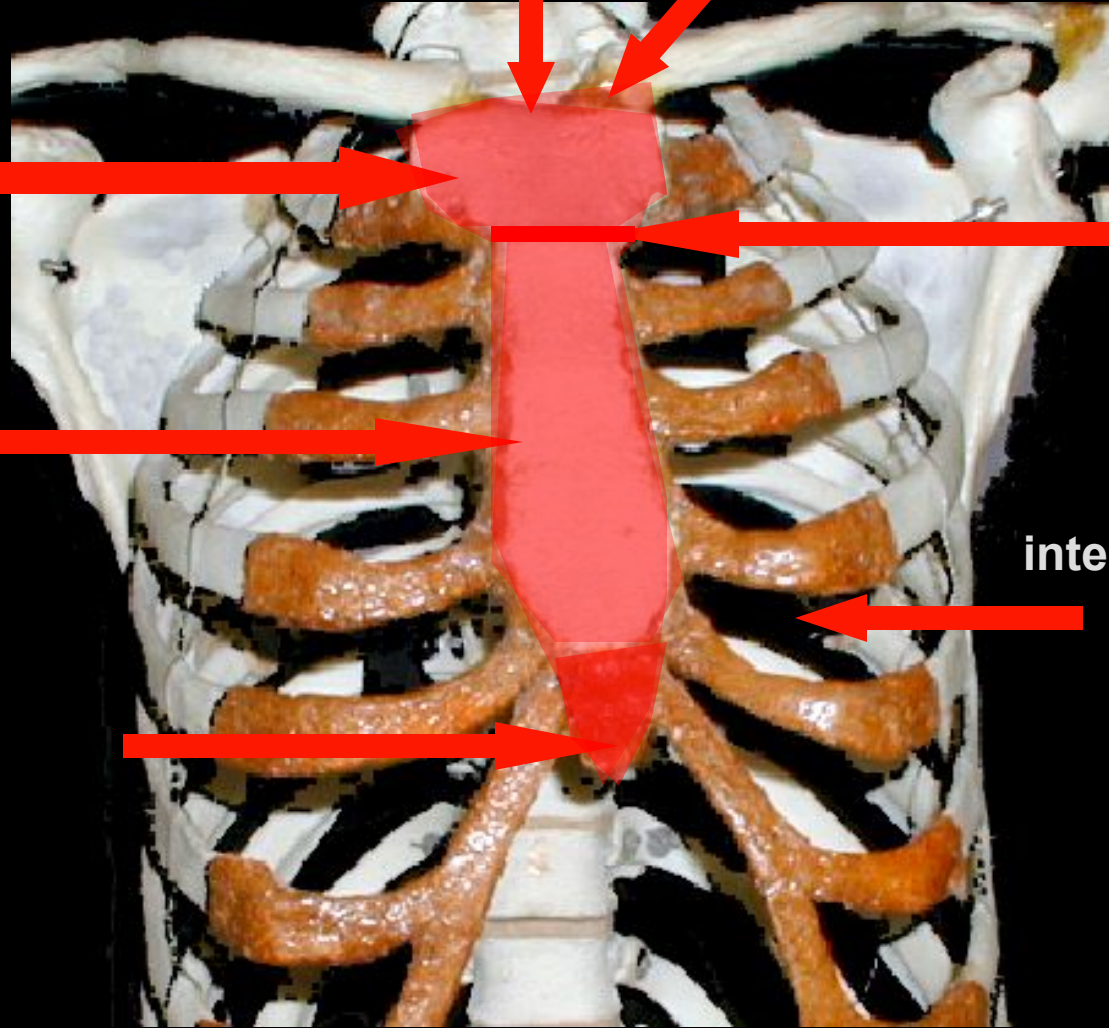
manubrium

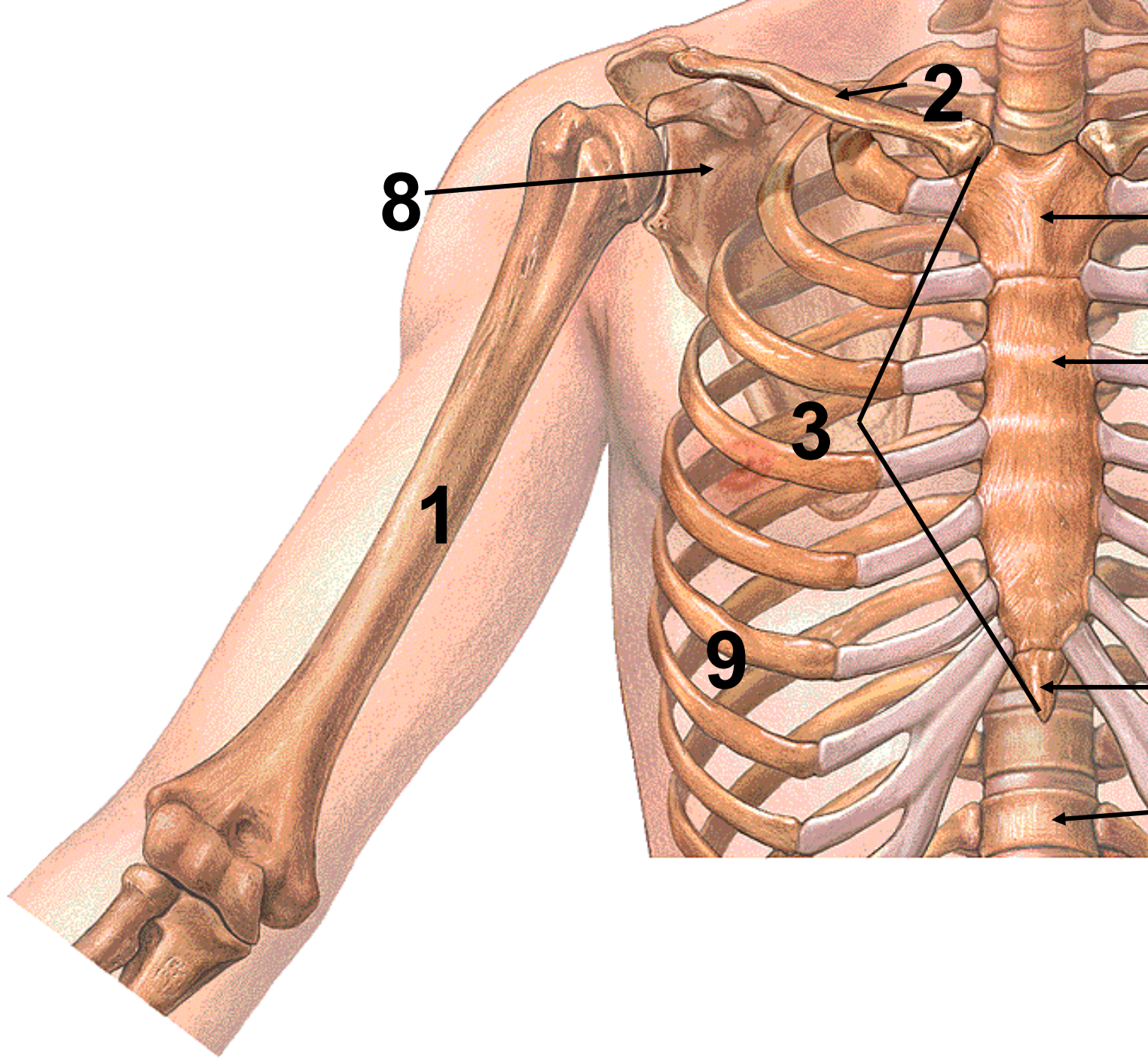
sternal angle

body

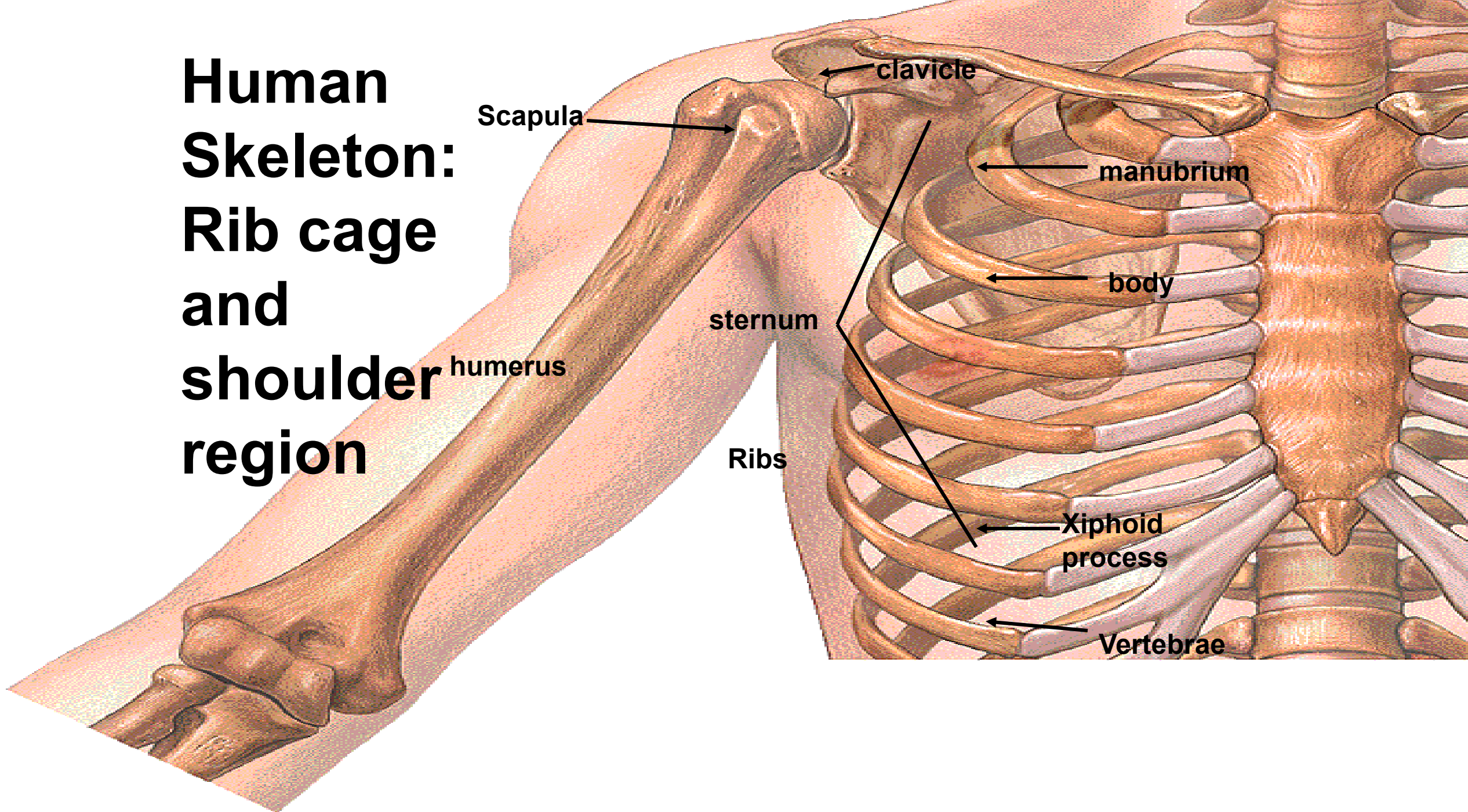
intercostal space

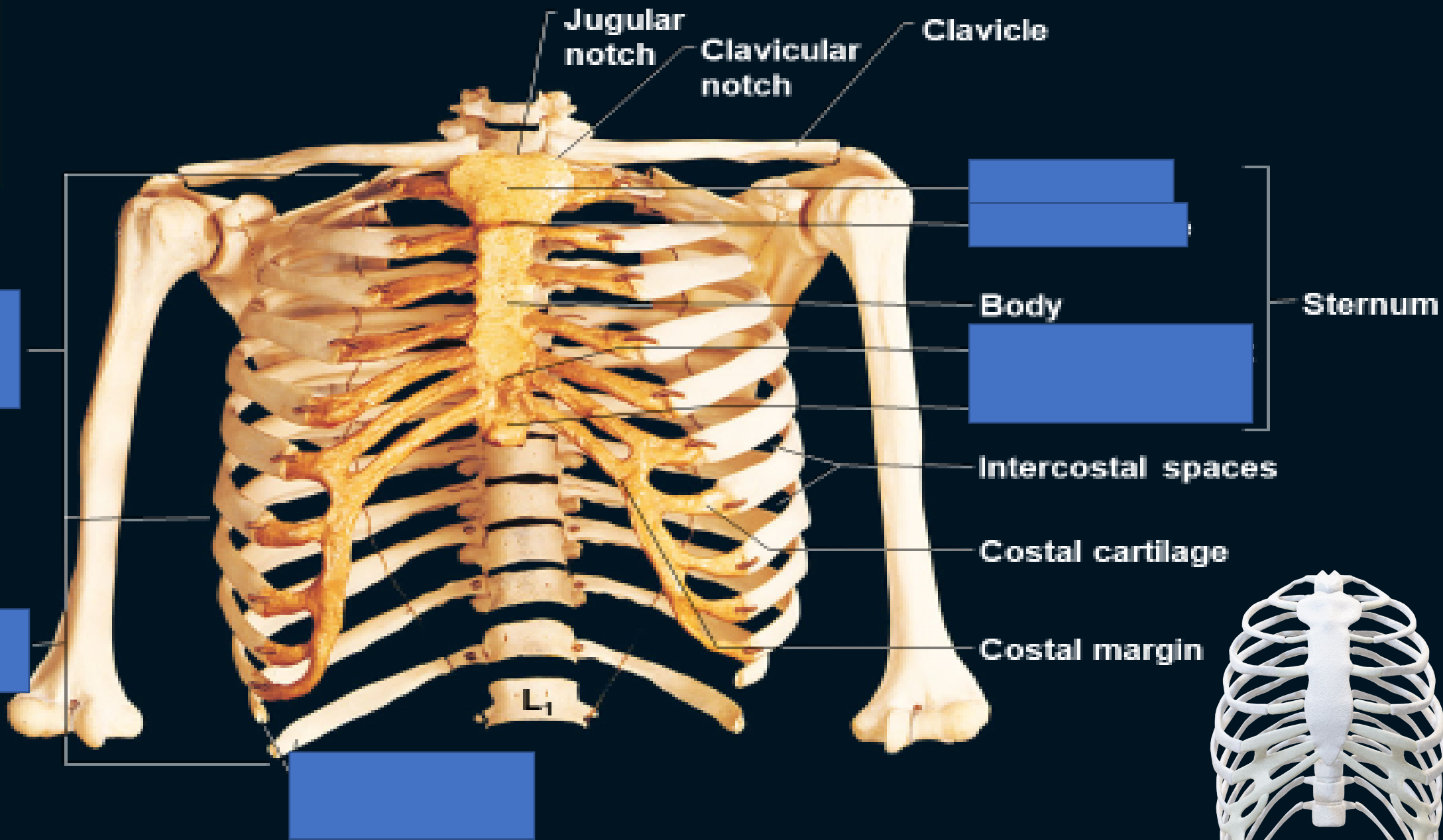
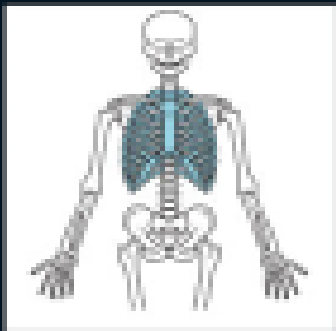
xiphoid process





Human Skeleton: Rib cage and shoulder region





(a) anterior view

How many ribs?
What type?

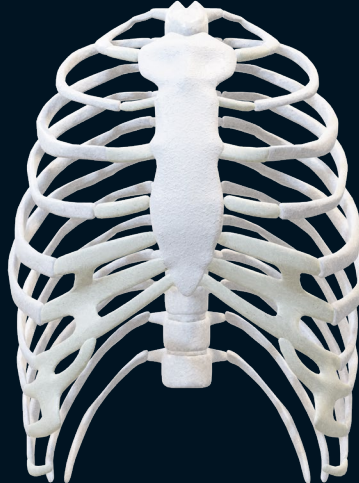[Redacted]

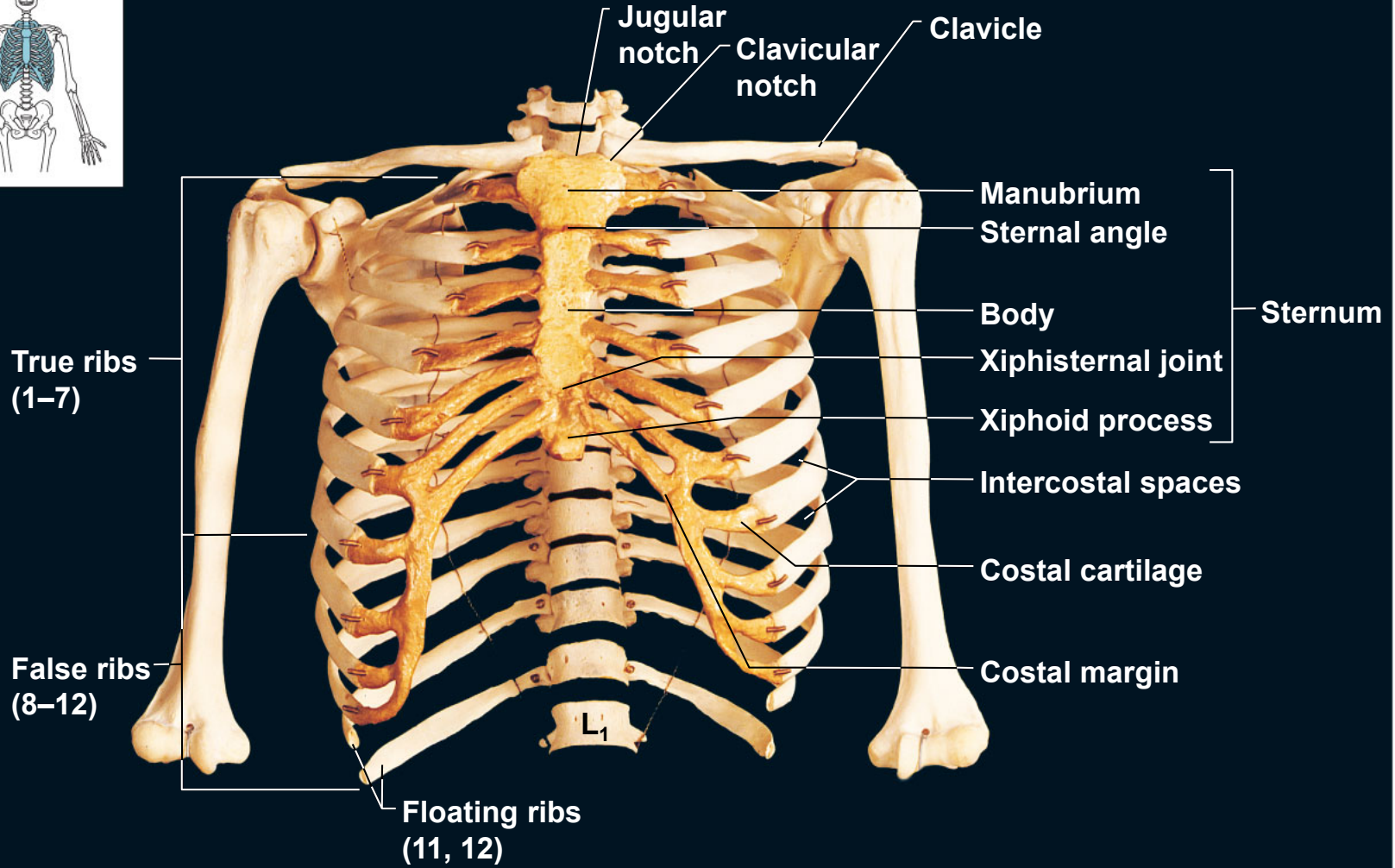
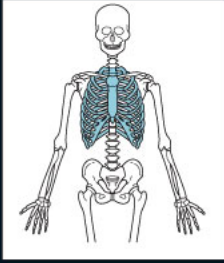
[Redacted]

[Redacted]

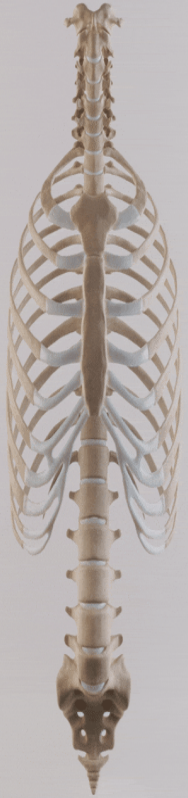[Redacted]

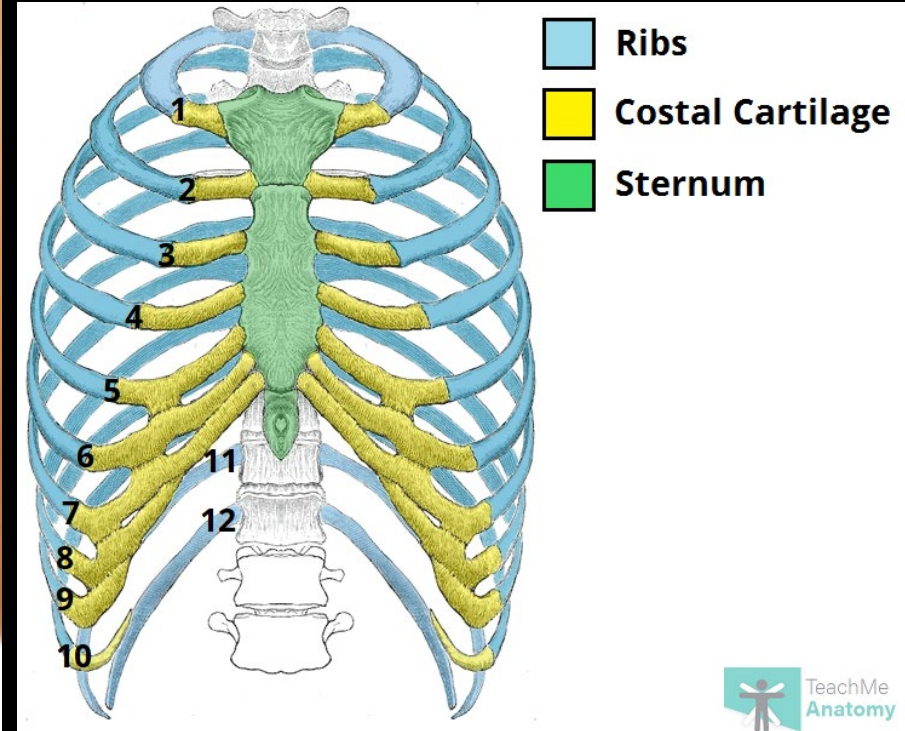
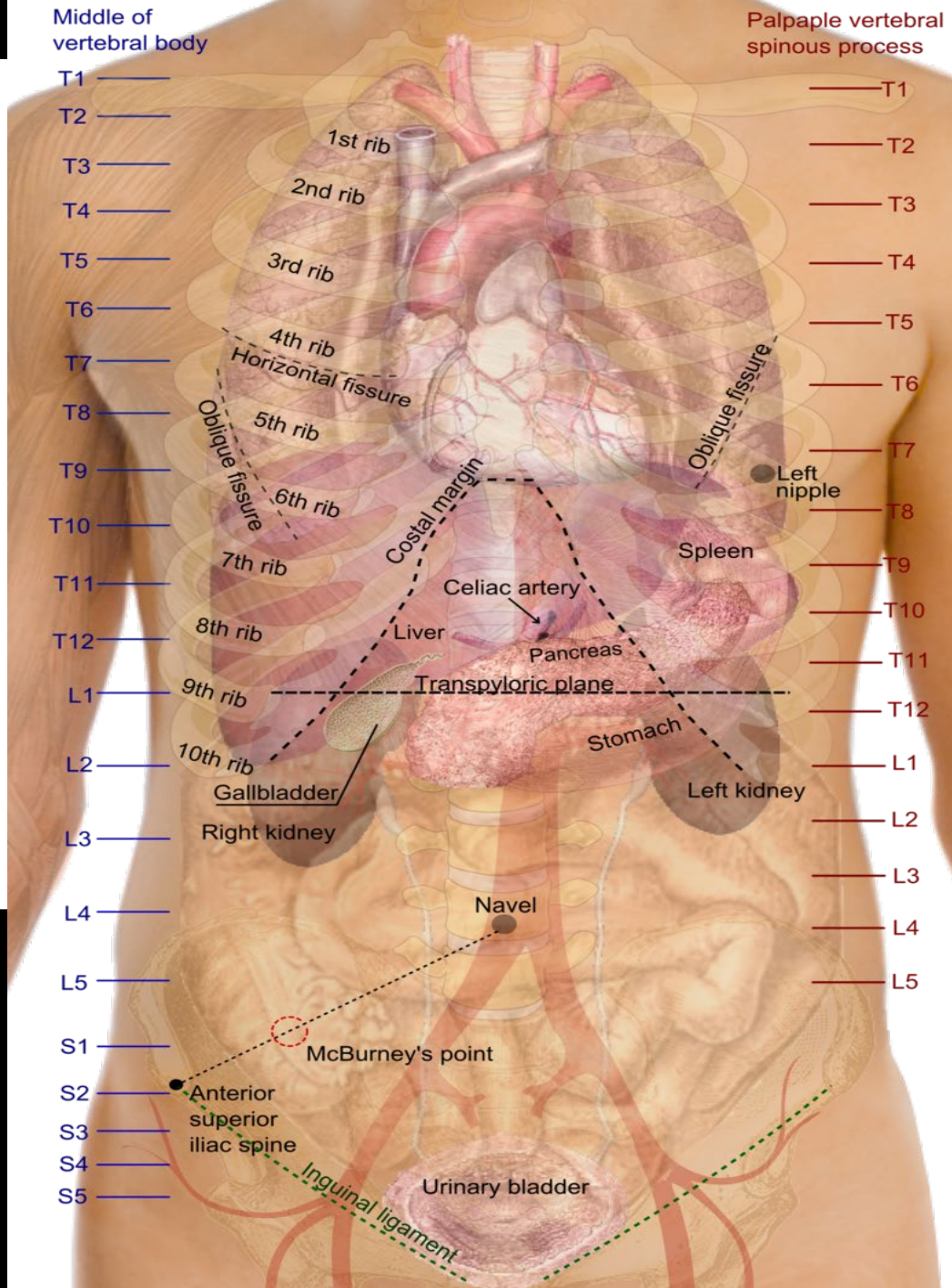
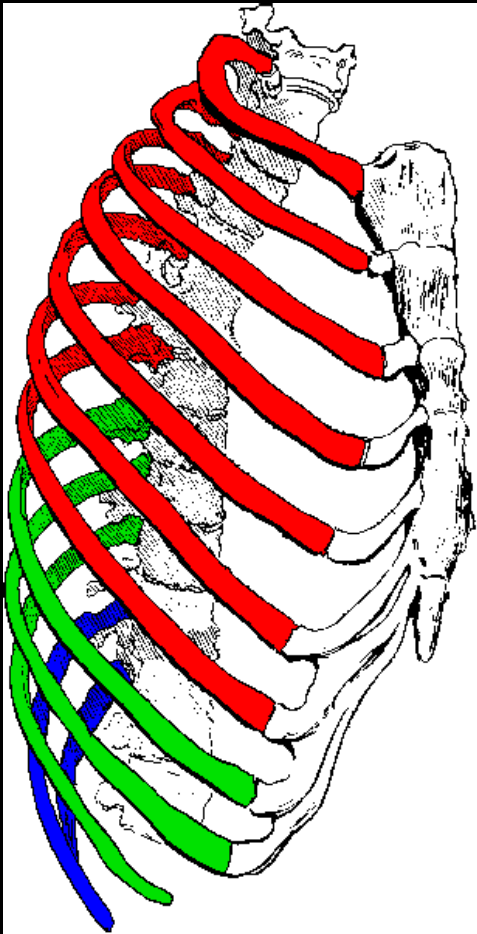
Costal margin

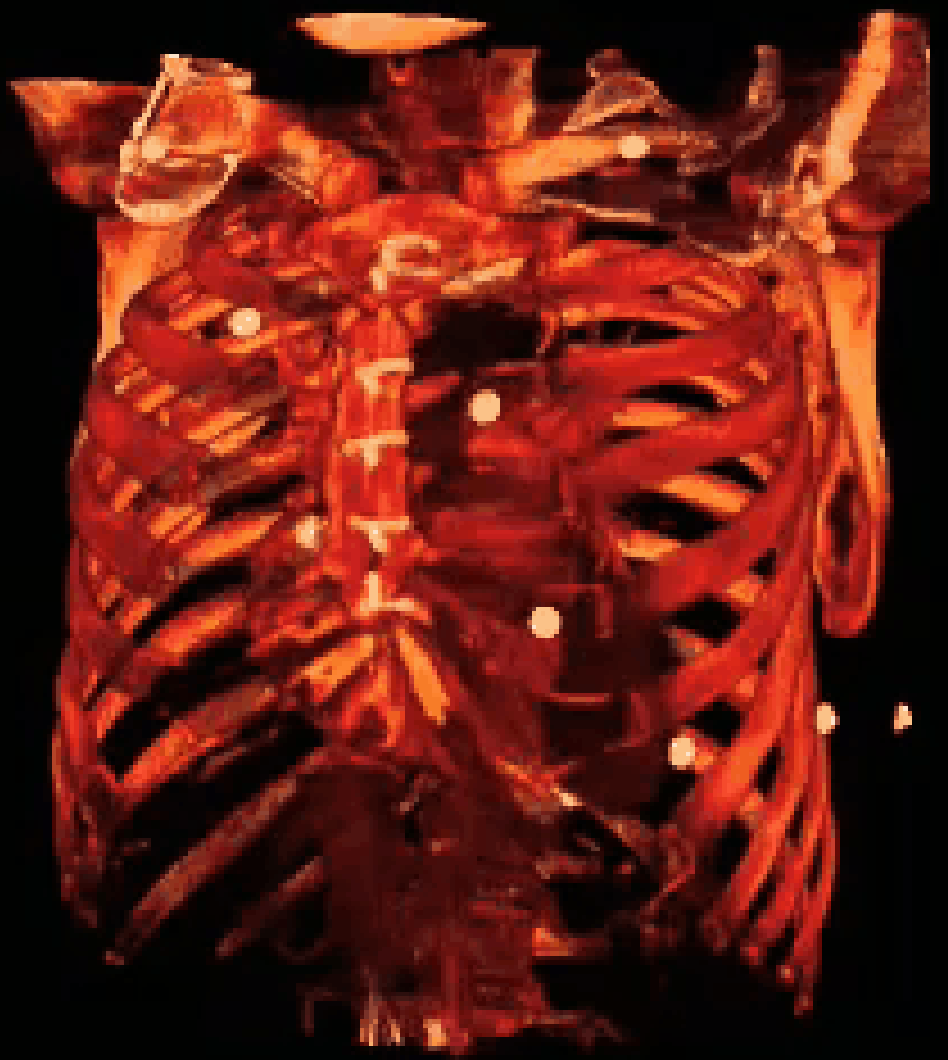
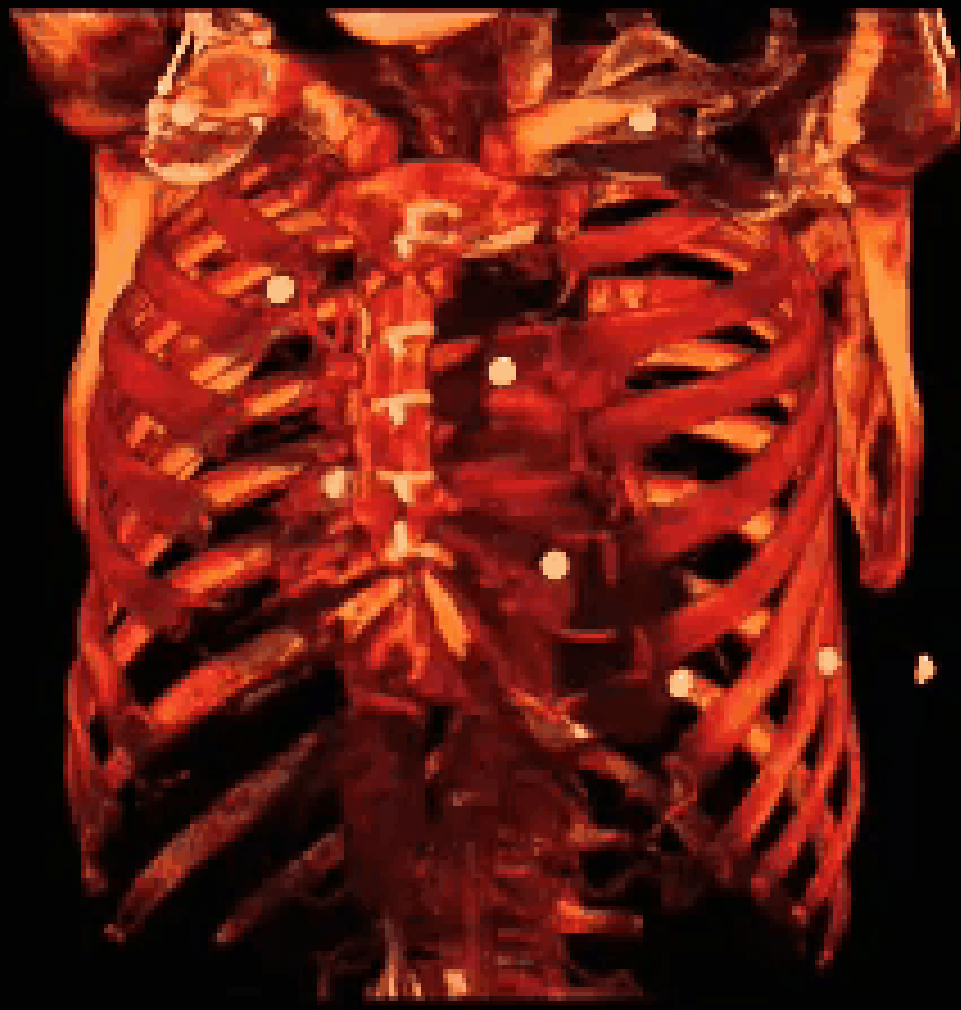


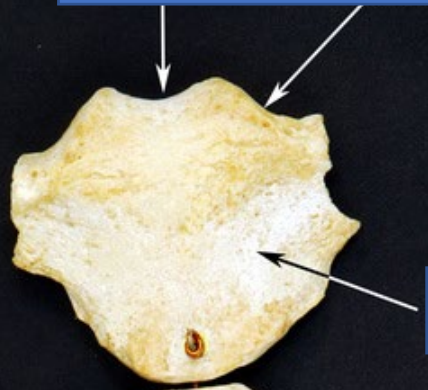
(a) anterior view



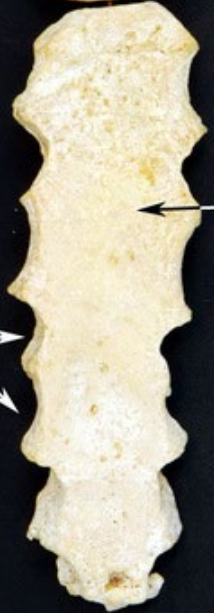



[Redacted]



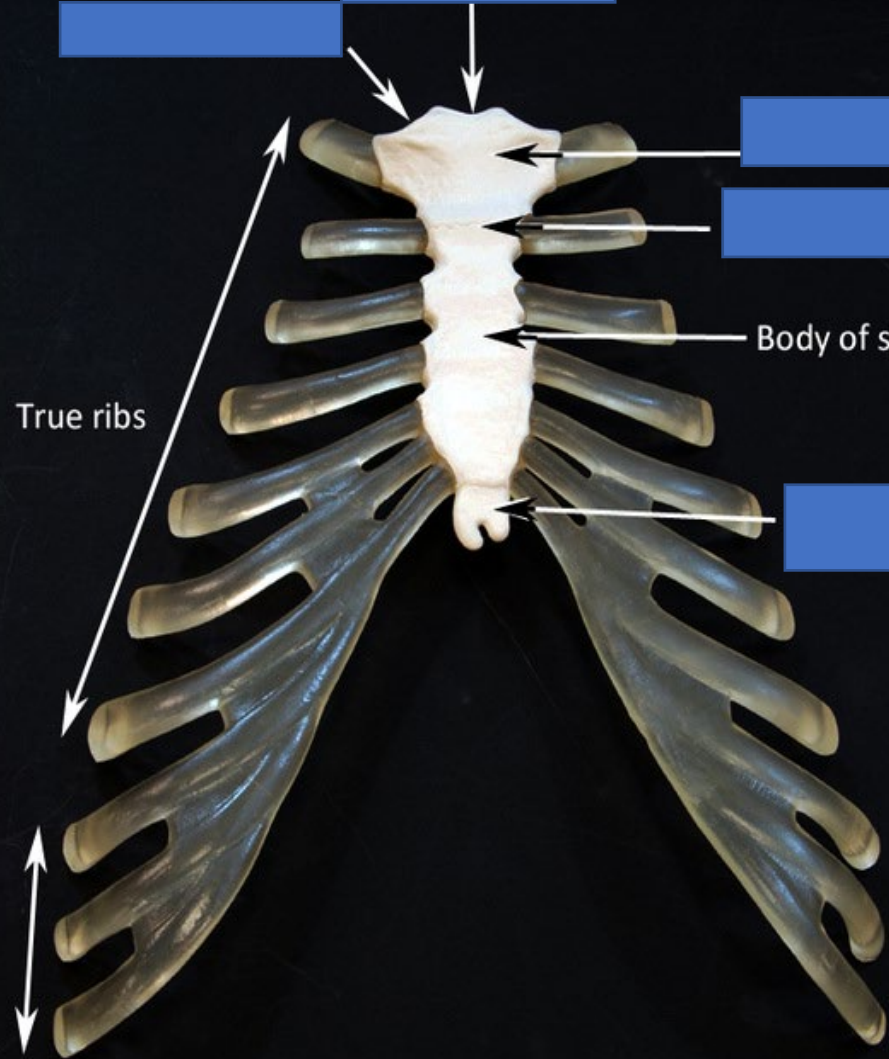
[Redacted]



[Redacted]

[Redacted]

[Redacted]



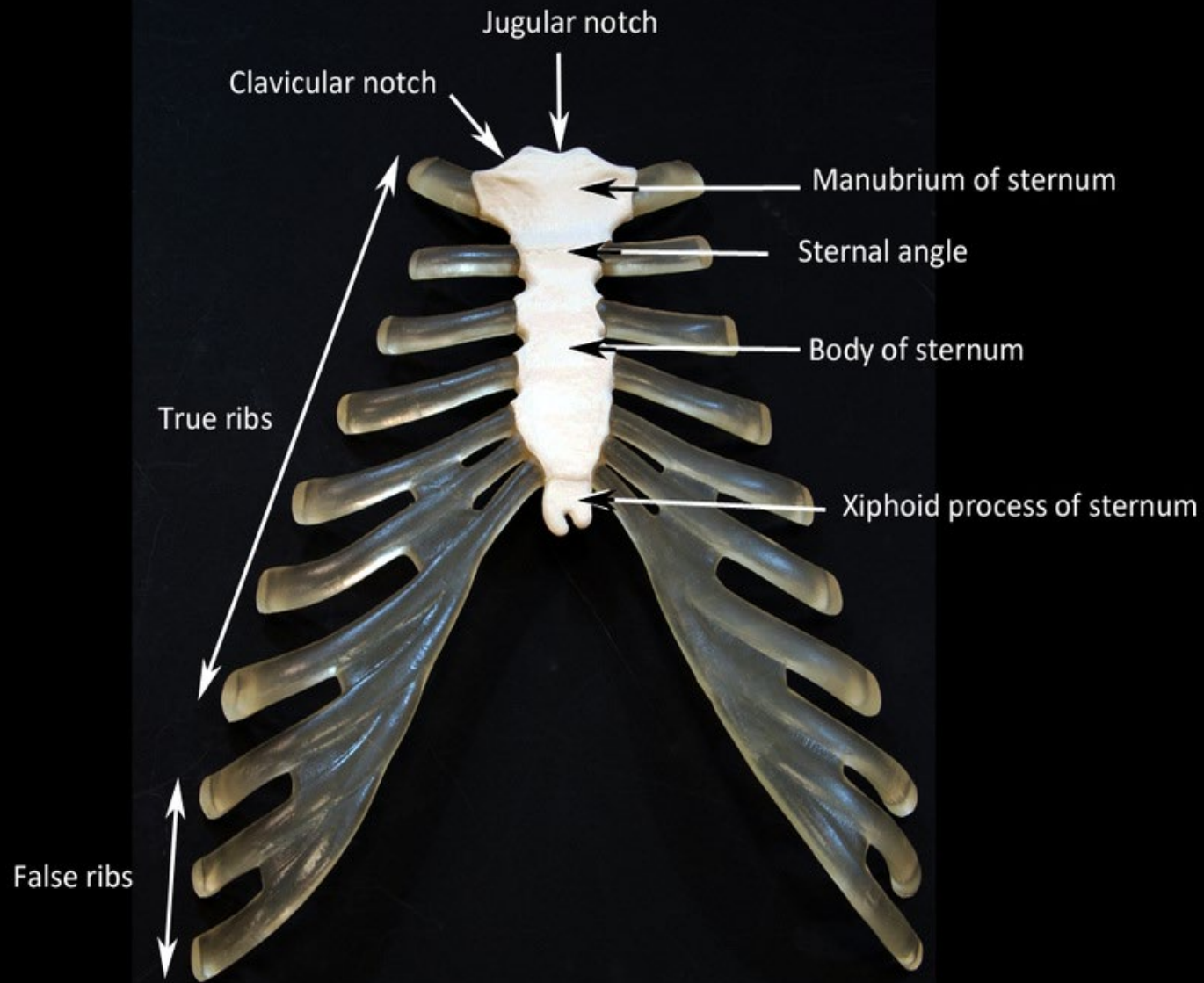
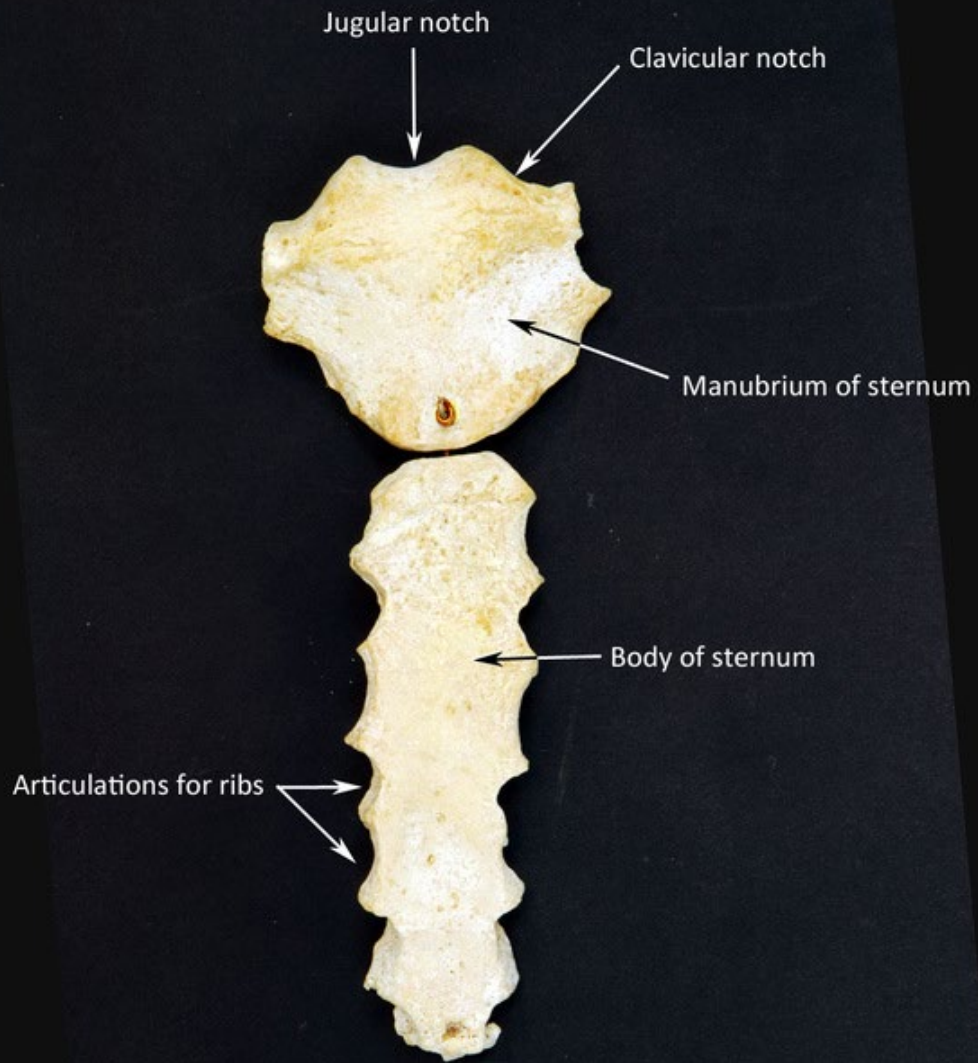
[Redacted]

[Redacted]

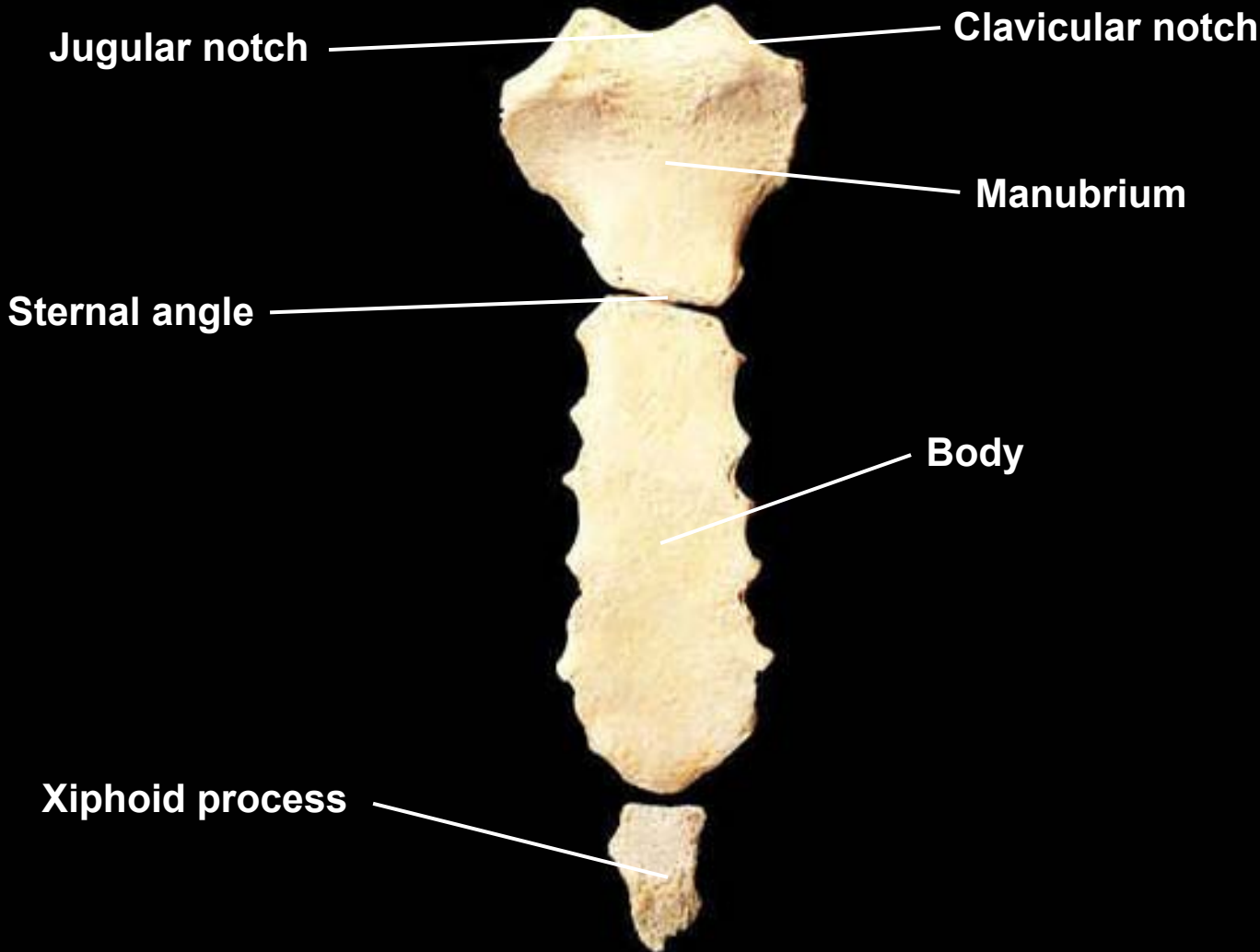
Body of sternum

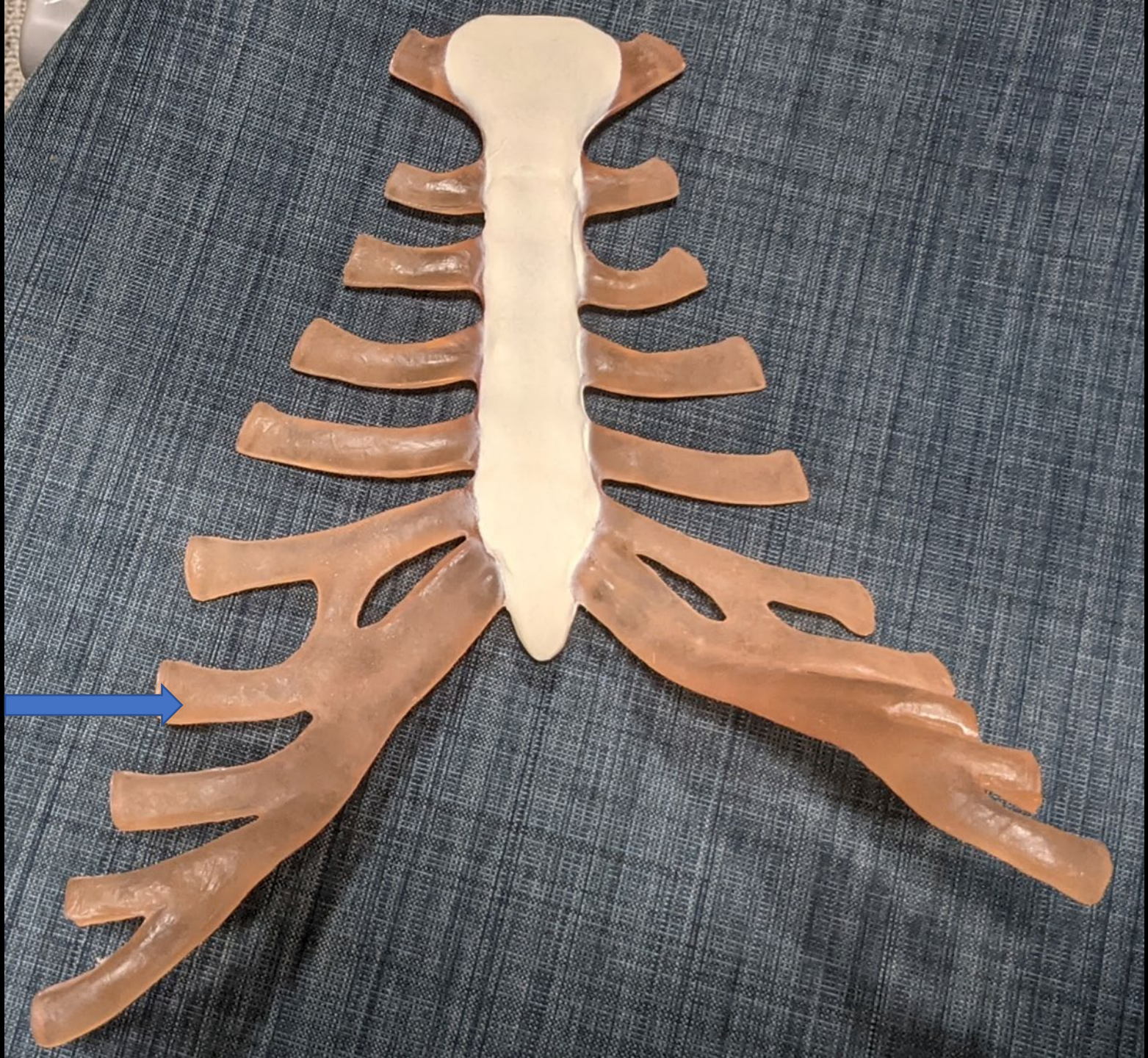
[Redacted]

False ribs

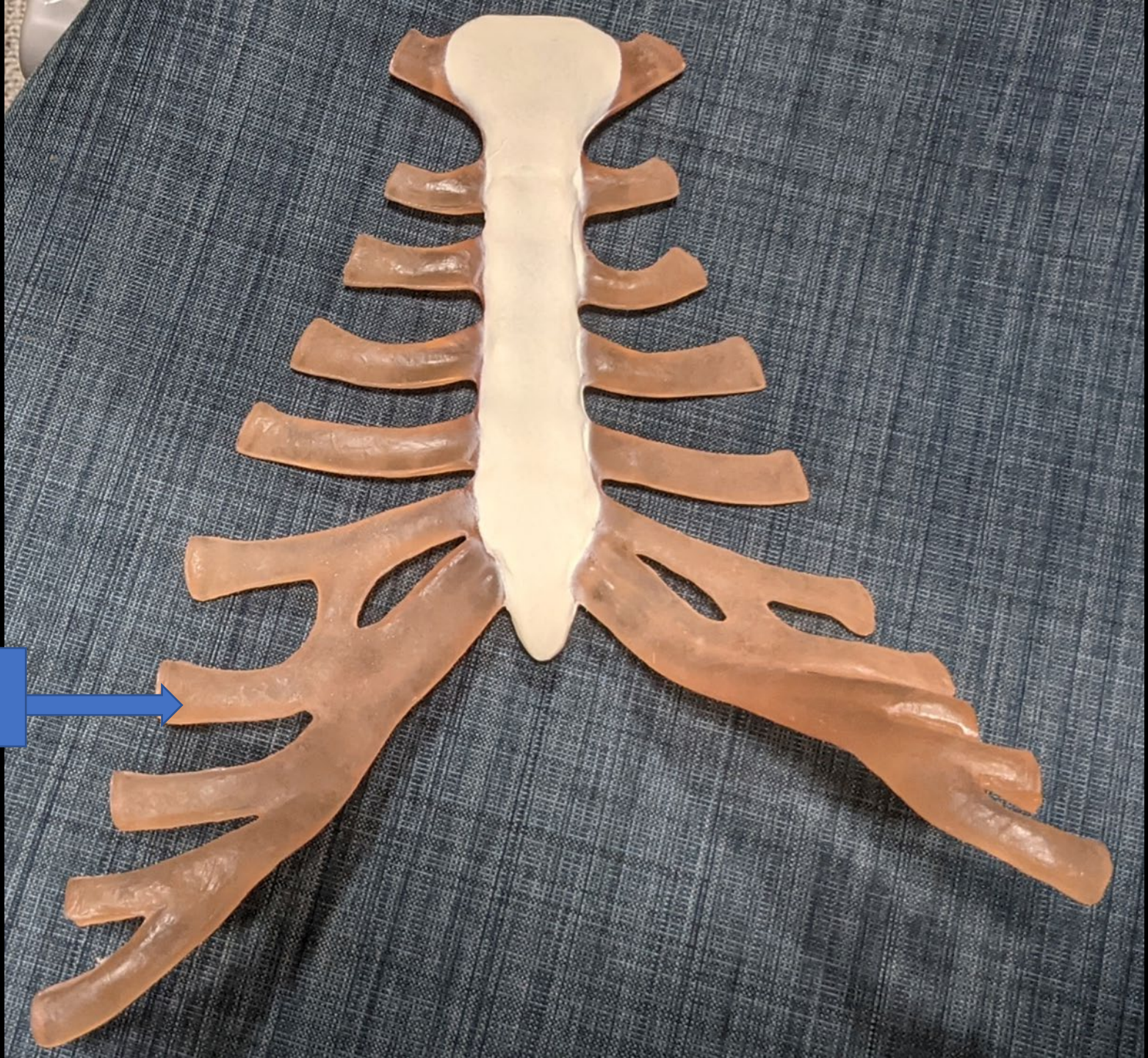


Sternum, anterior view



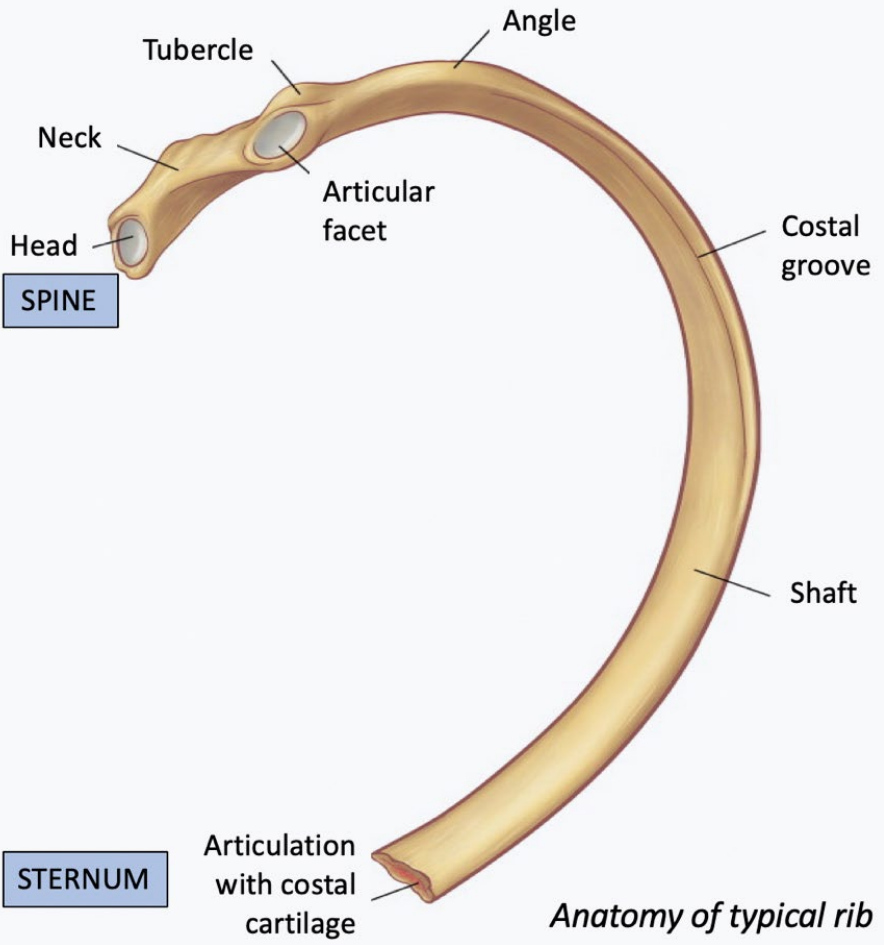


Intercostal
cartilage



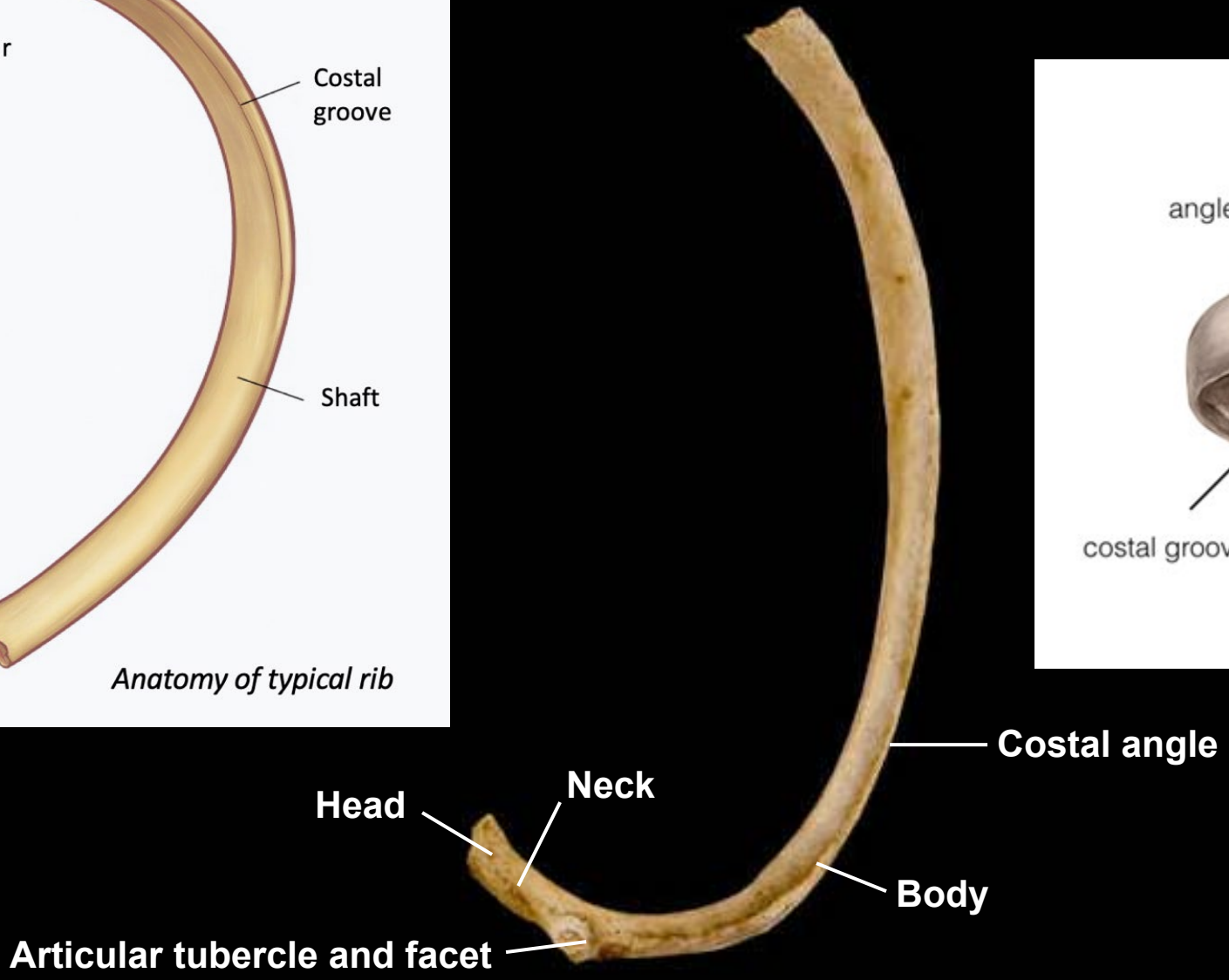
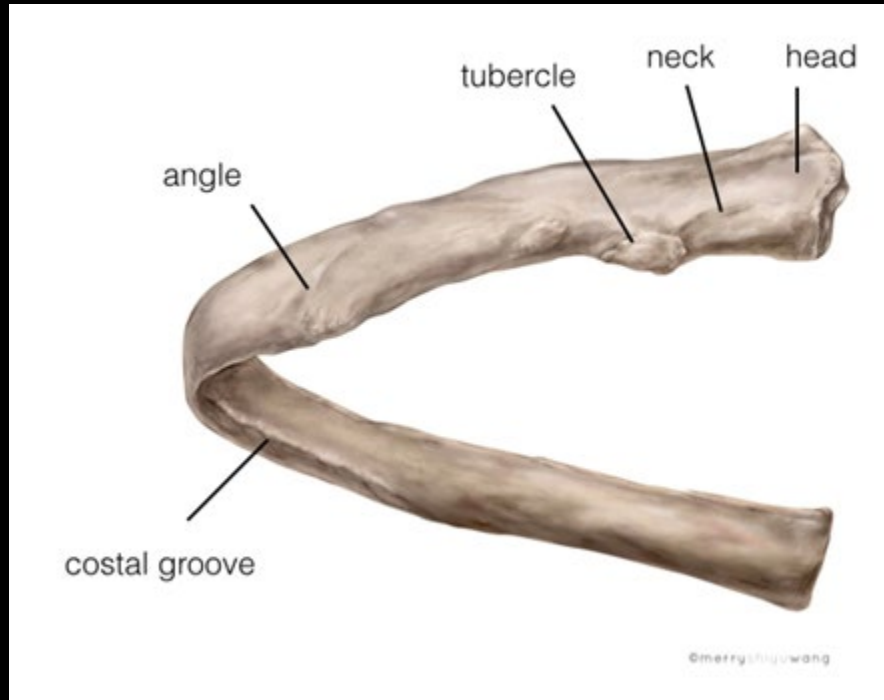
Rib, superior view, right side



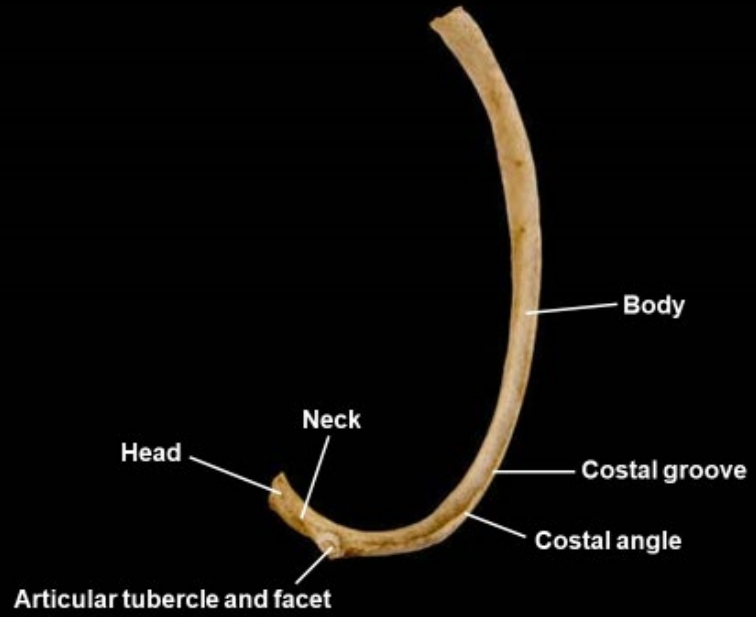


Anatomy of typical rib

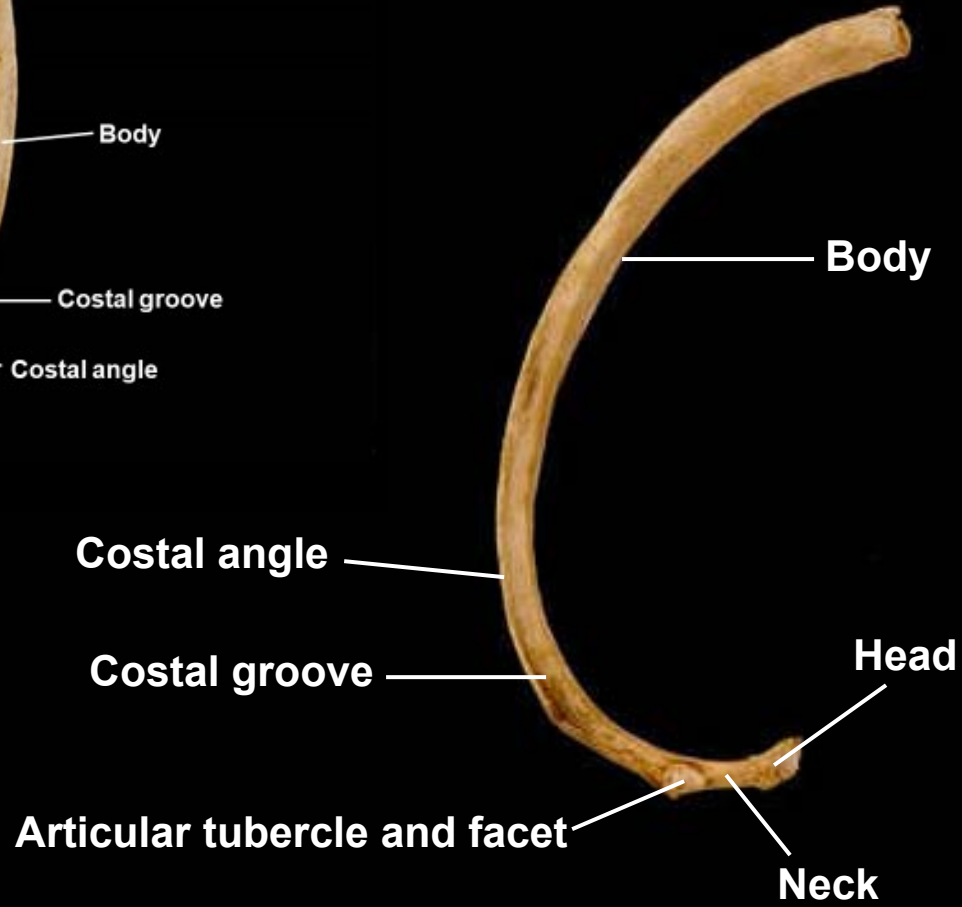
Rib, superior view, right side



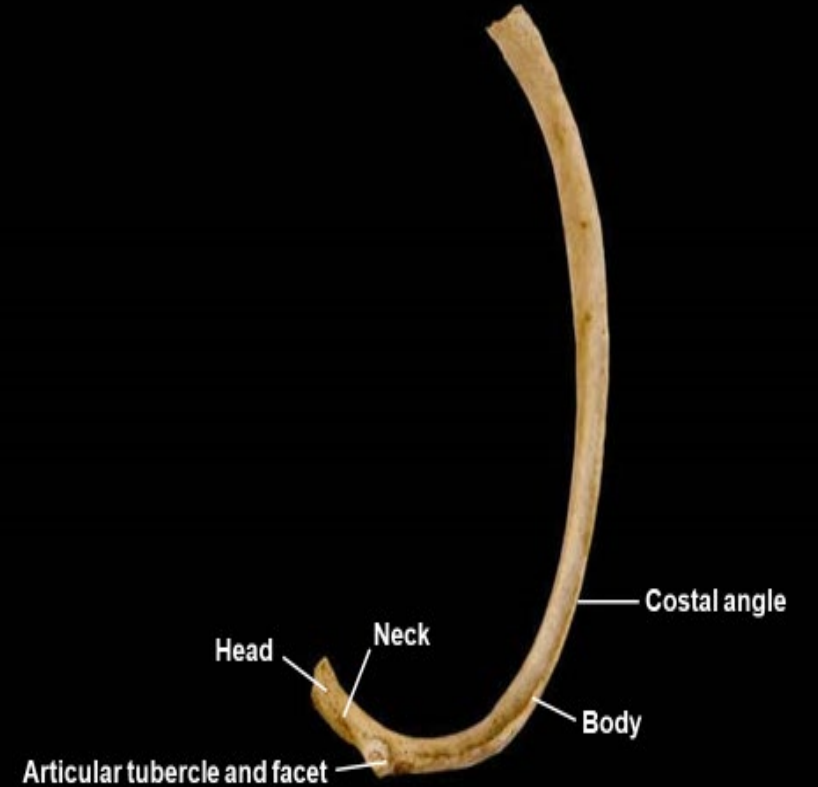
Rib, inferior view, left side

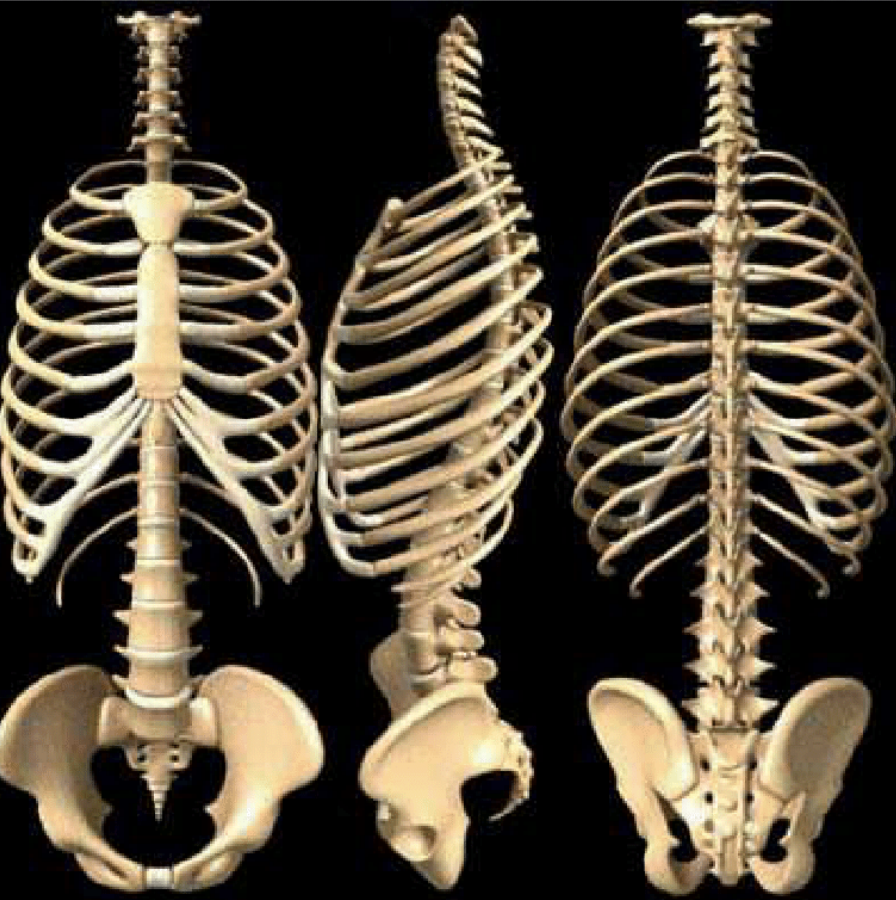


Rib, inferior view, right side

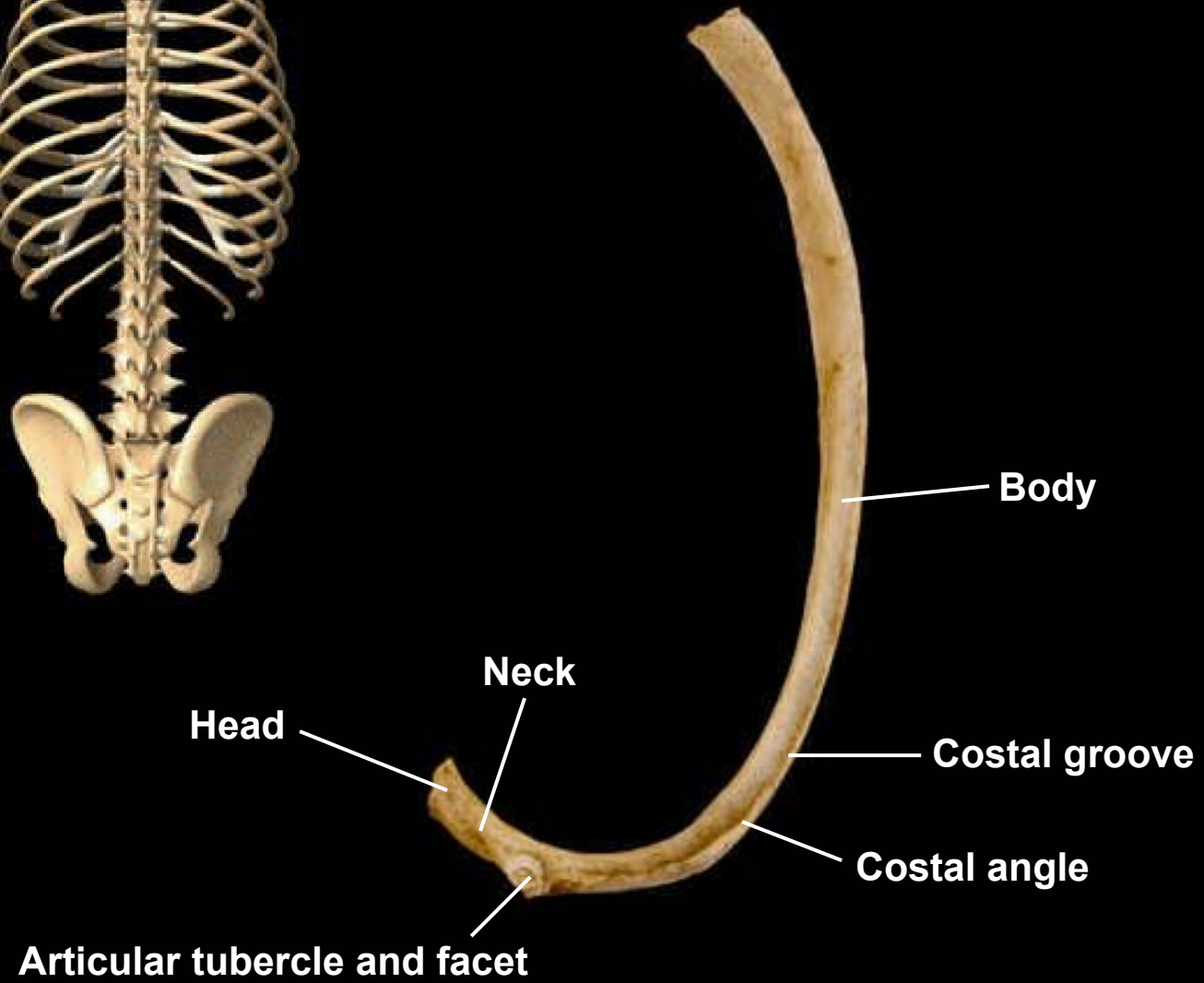


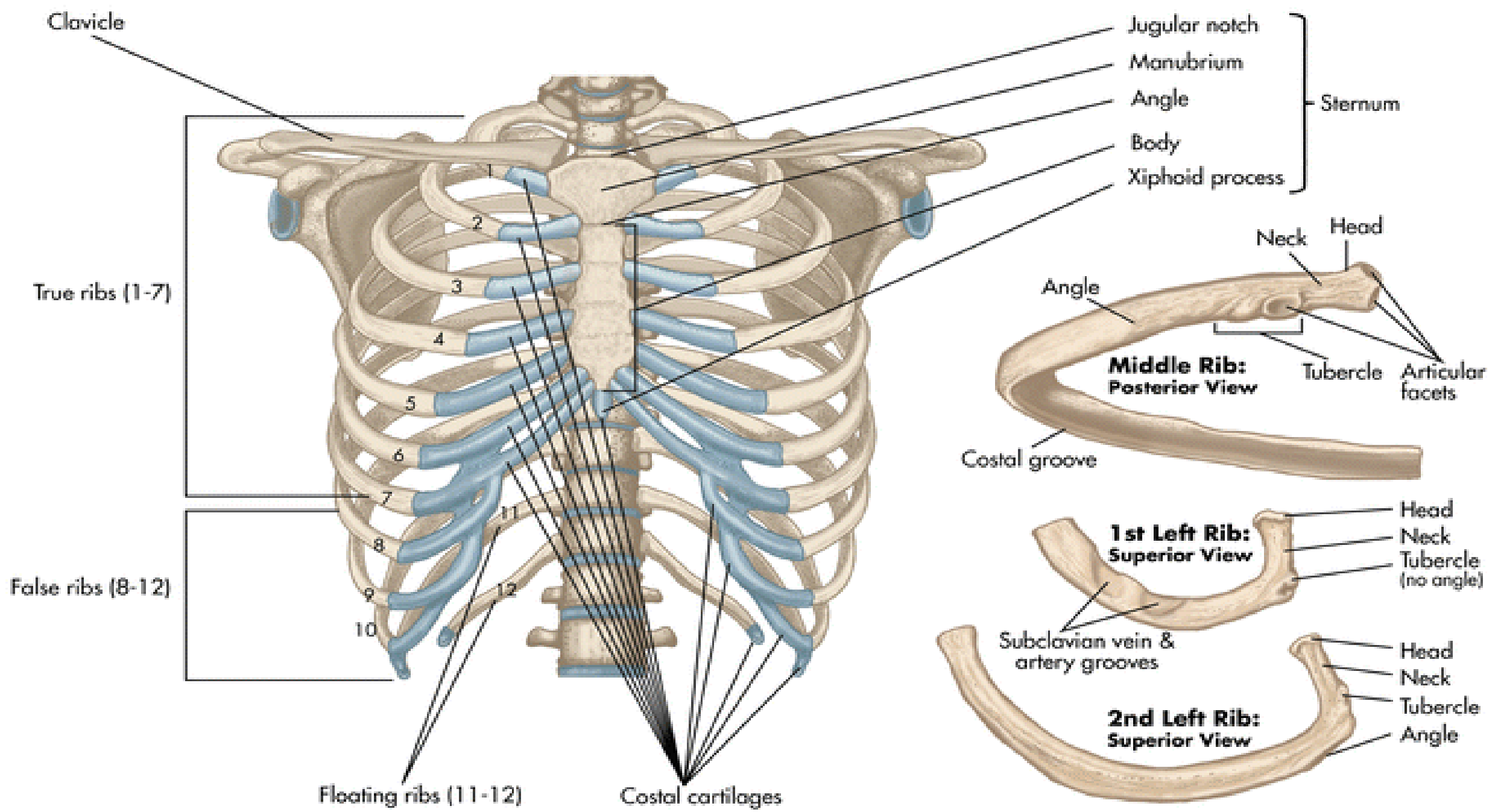
Rib, superior view, right side



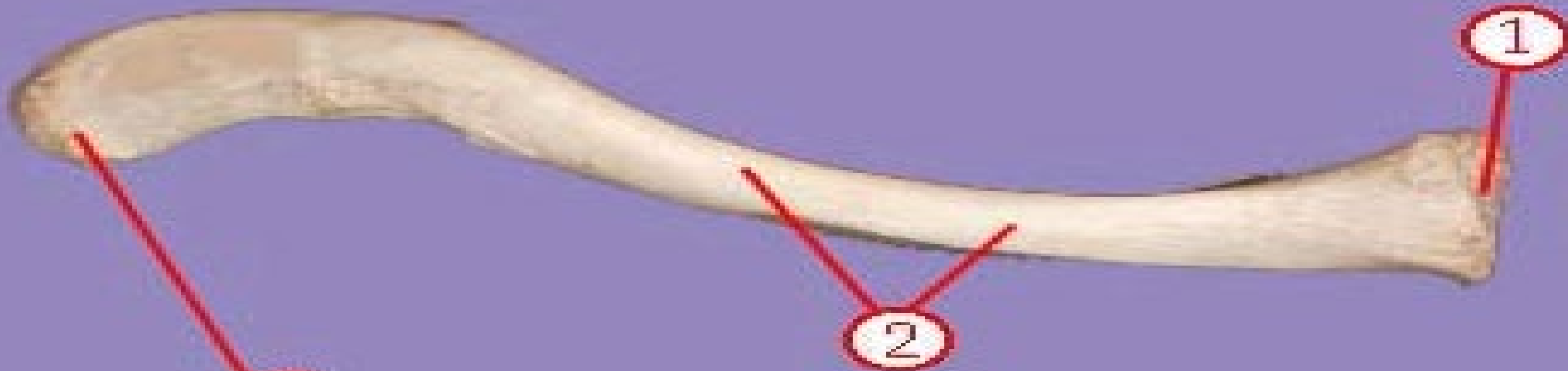


Rib, inferior view, left side





Superior appendages



Identify #8

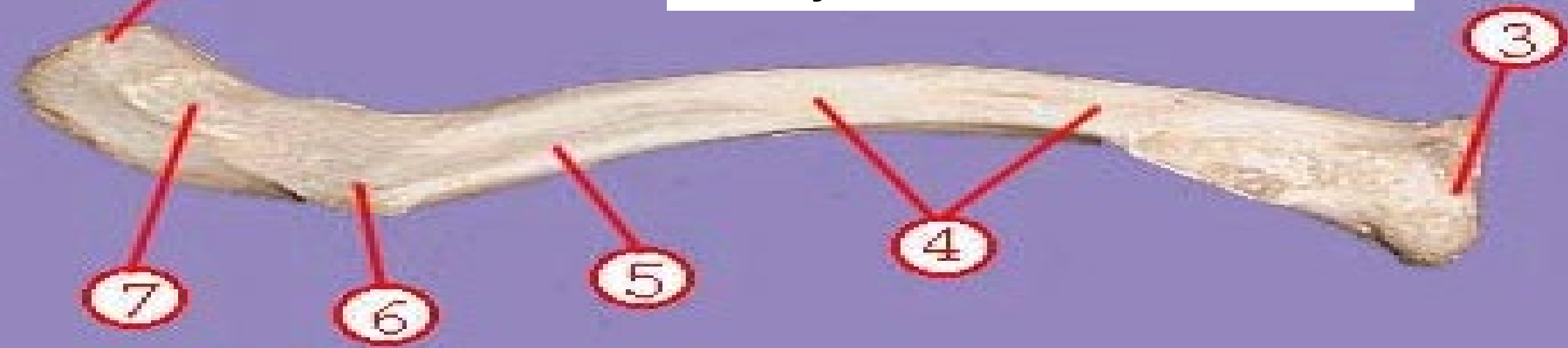Identify # 2

Identify # 3

8

2

1



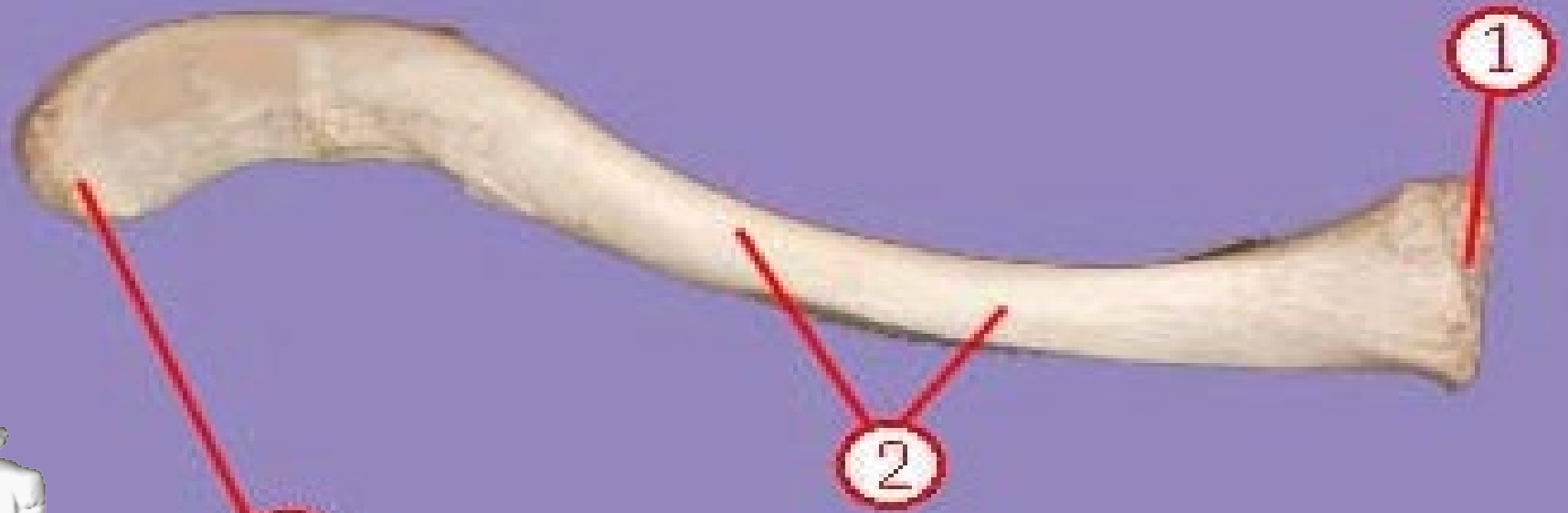
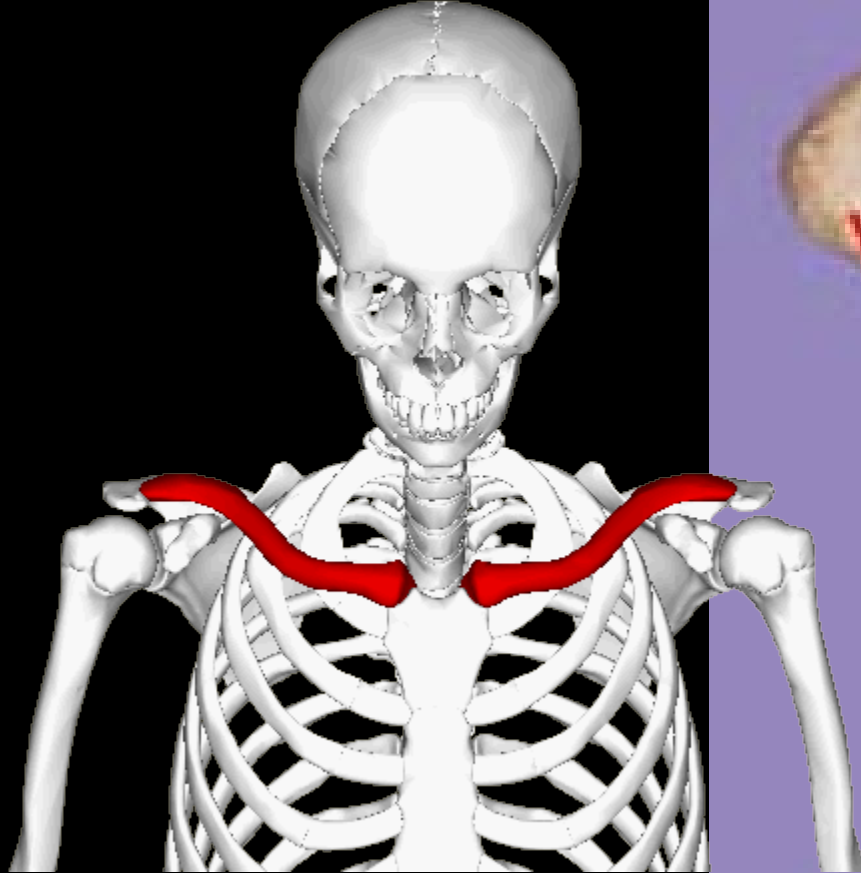
3

4

5

6

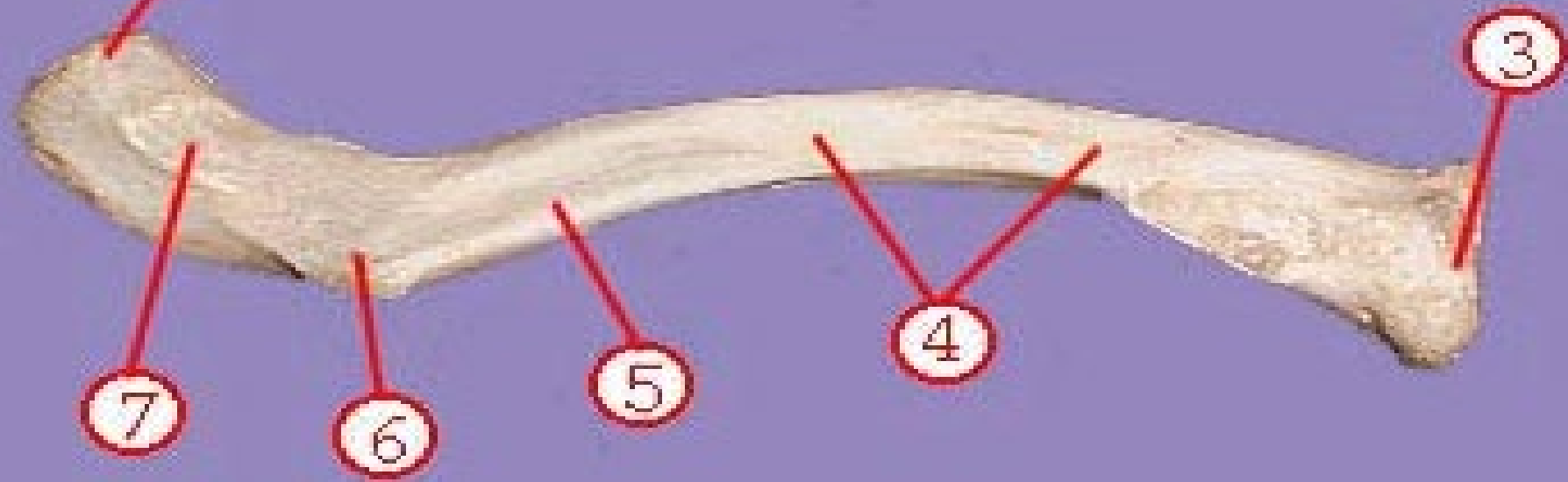
7




Identify #8 acromial head of the clavicle

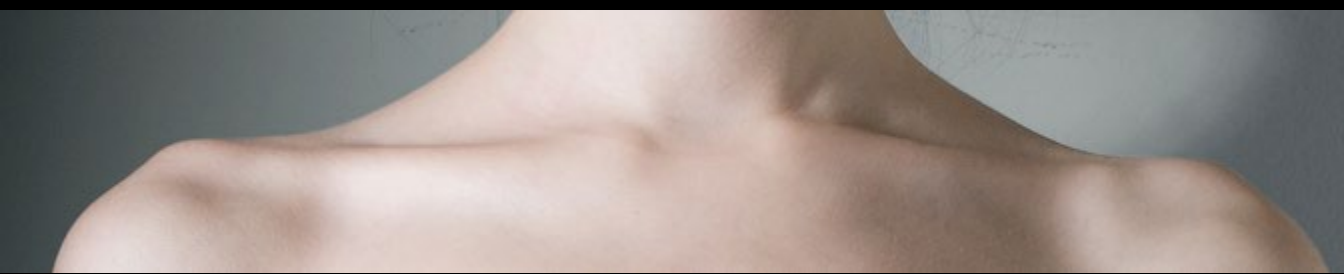Identify # 2 superior surface of clavicle,shaft

Identify # 3 sternal head of clavicle



Clavicle, anterior view, right side





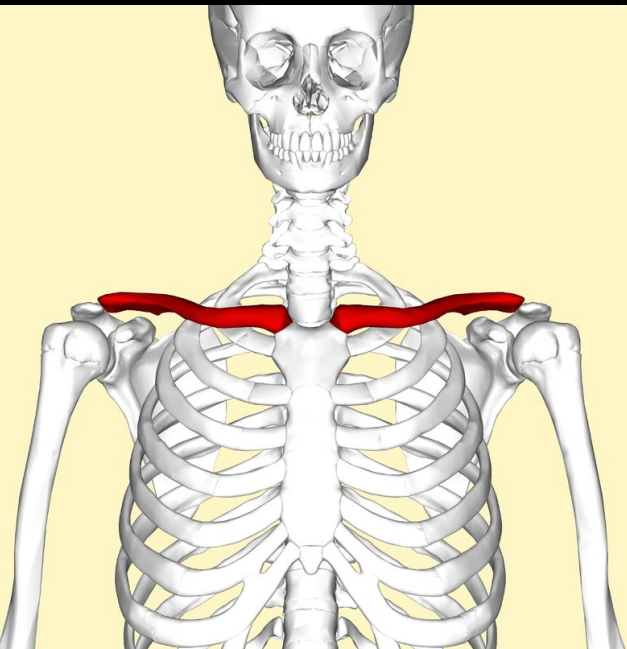
Clavicle, anterior view, right side

Acromial end

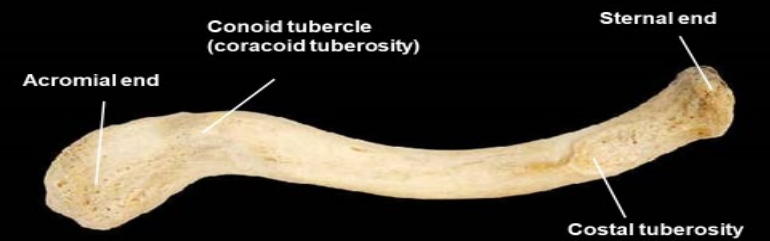Sternal end



Conoid tubercle
(coracoid tuberosity)



Clavicle, inferior view, right side



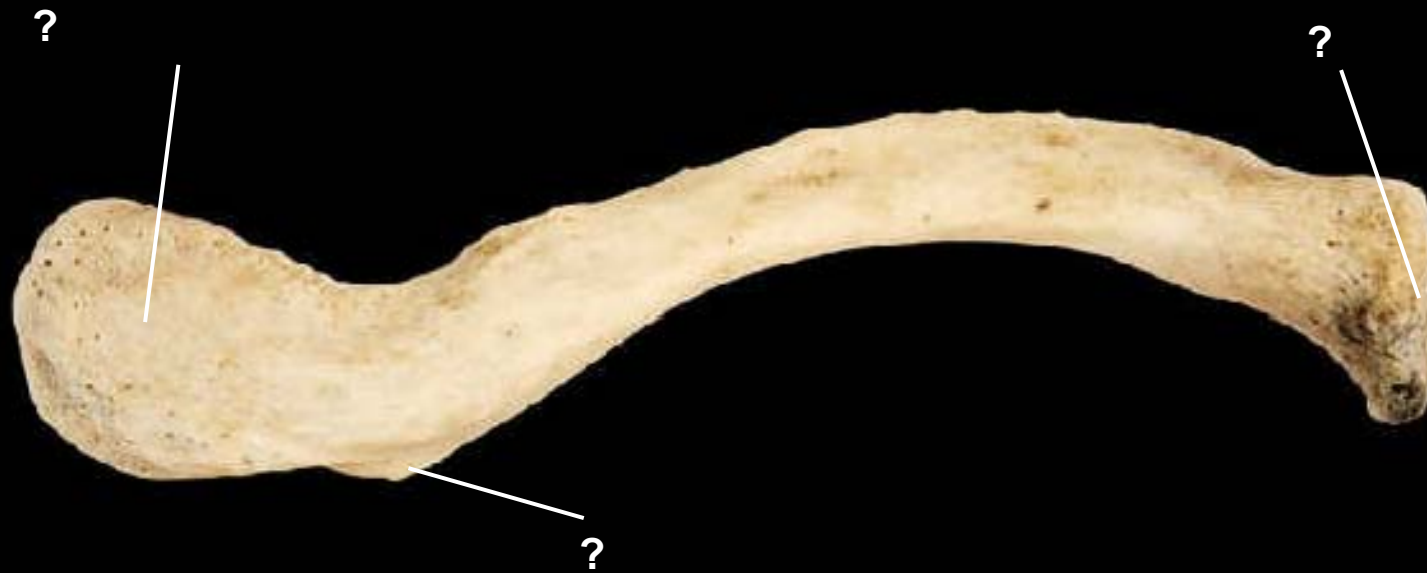Acromial end

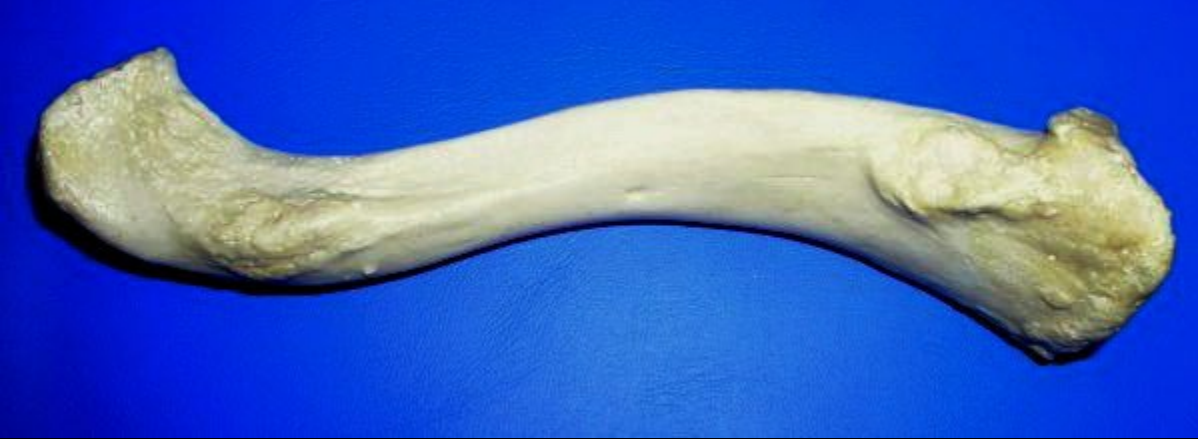Conoid tubercle
(coracoid tuberosity)

Sternal end

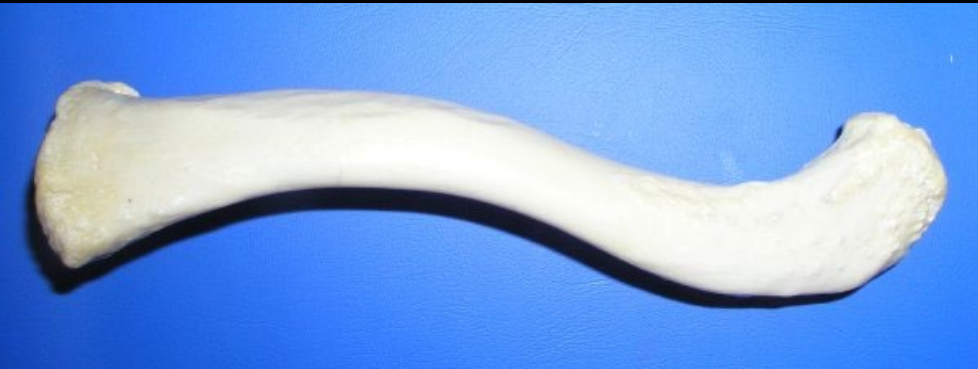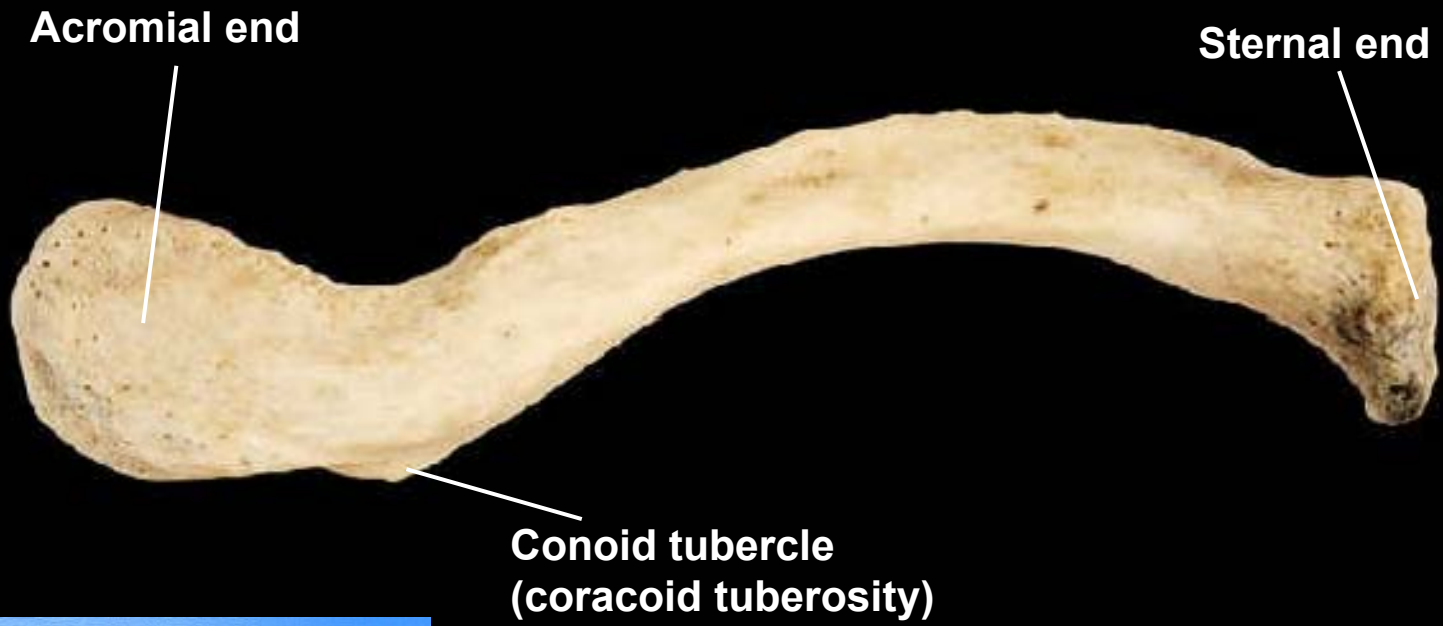
Costal tuberosity

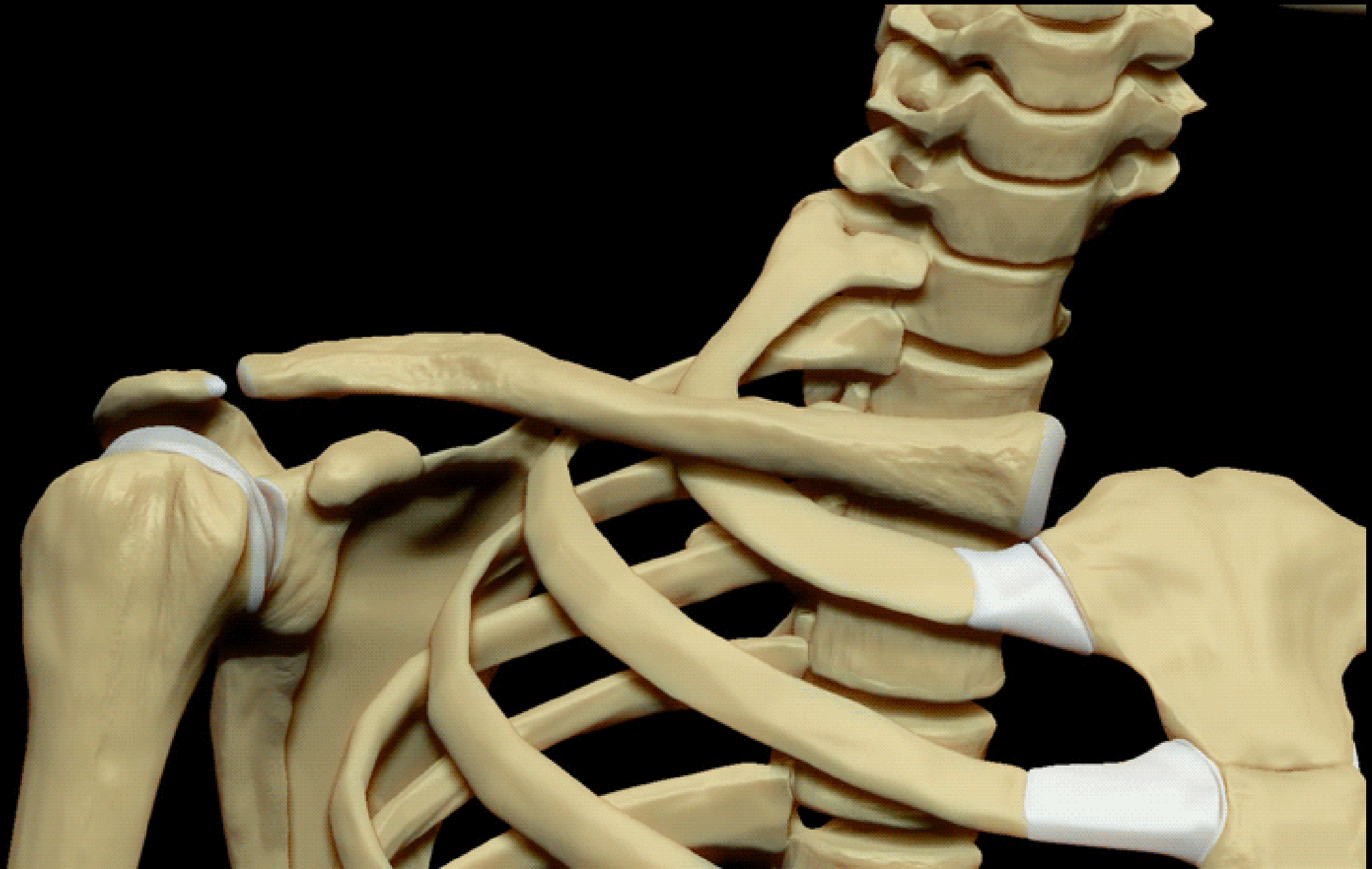
Clavicle, superior view, right side

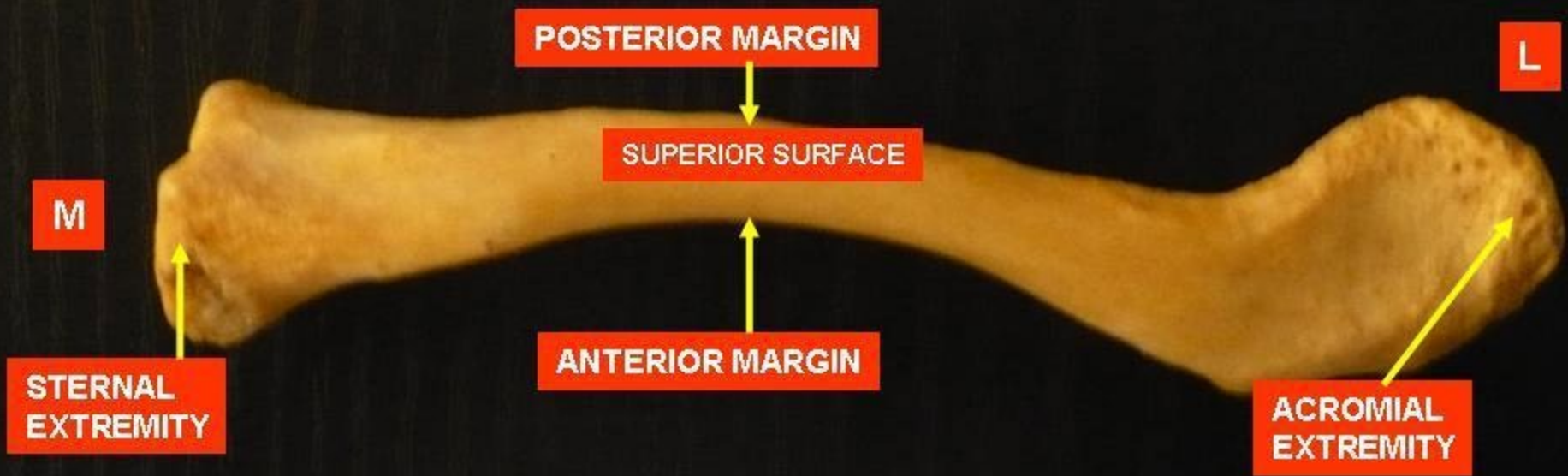




Clavicle, superior view, right side







M

POSTERIOR MARGIN

L

SUPERIOR SURFACE

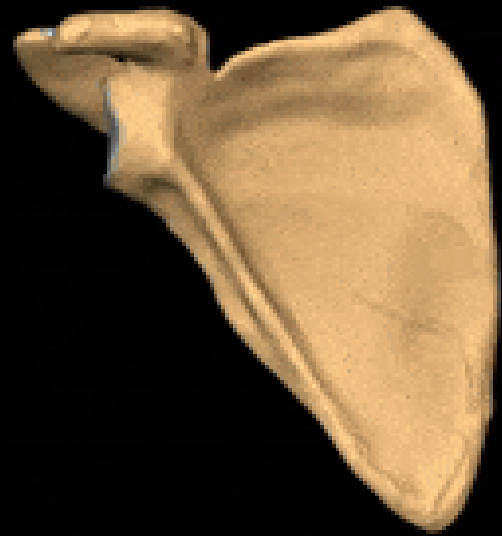STERNAL
EXTREMITY

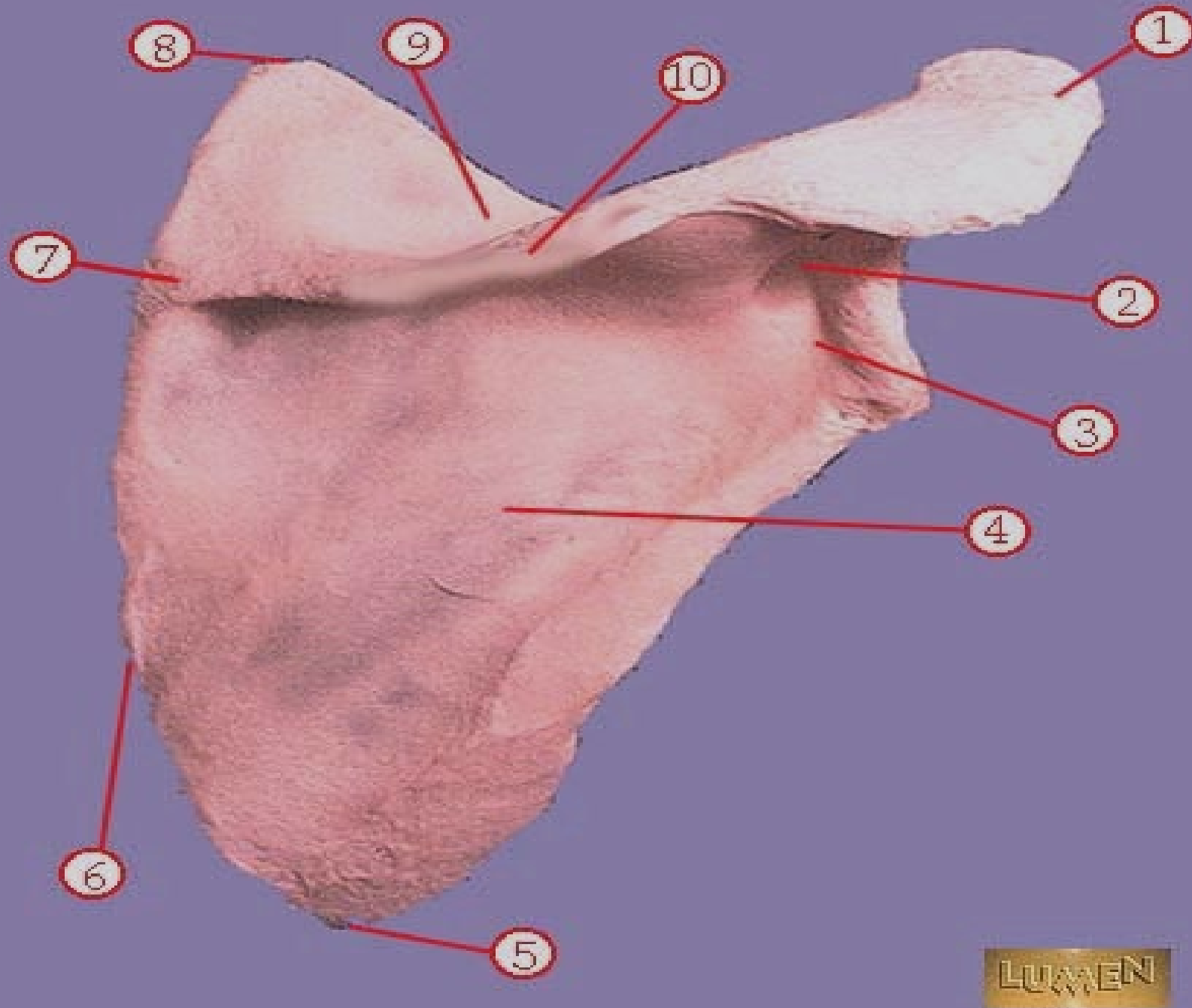
ANTERIOR MARGIN

ACROMIAL
EXTREMITY

CLAVICLE



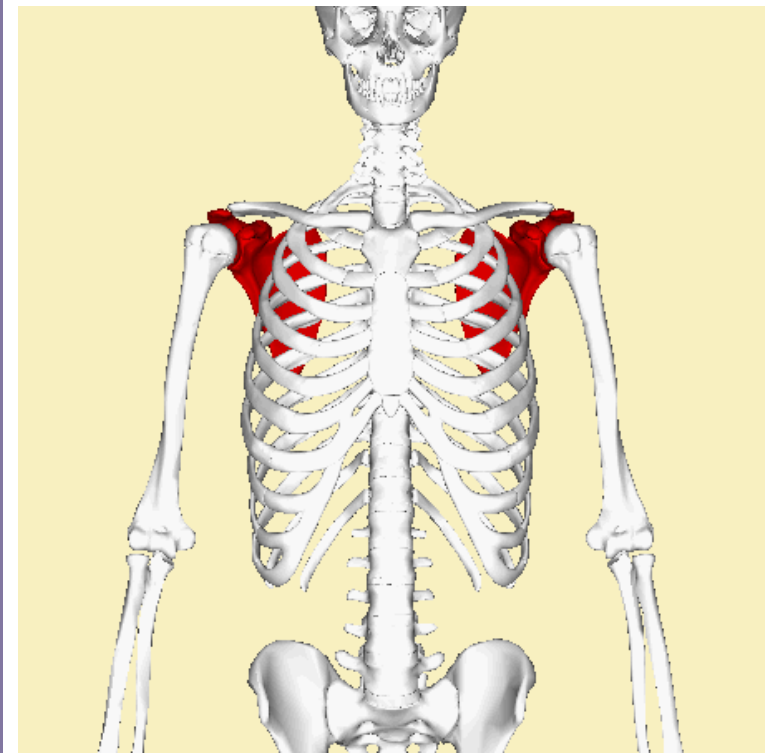


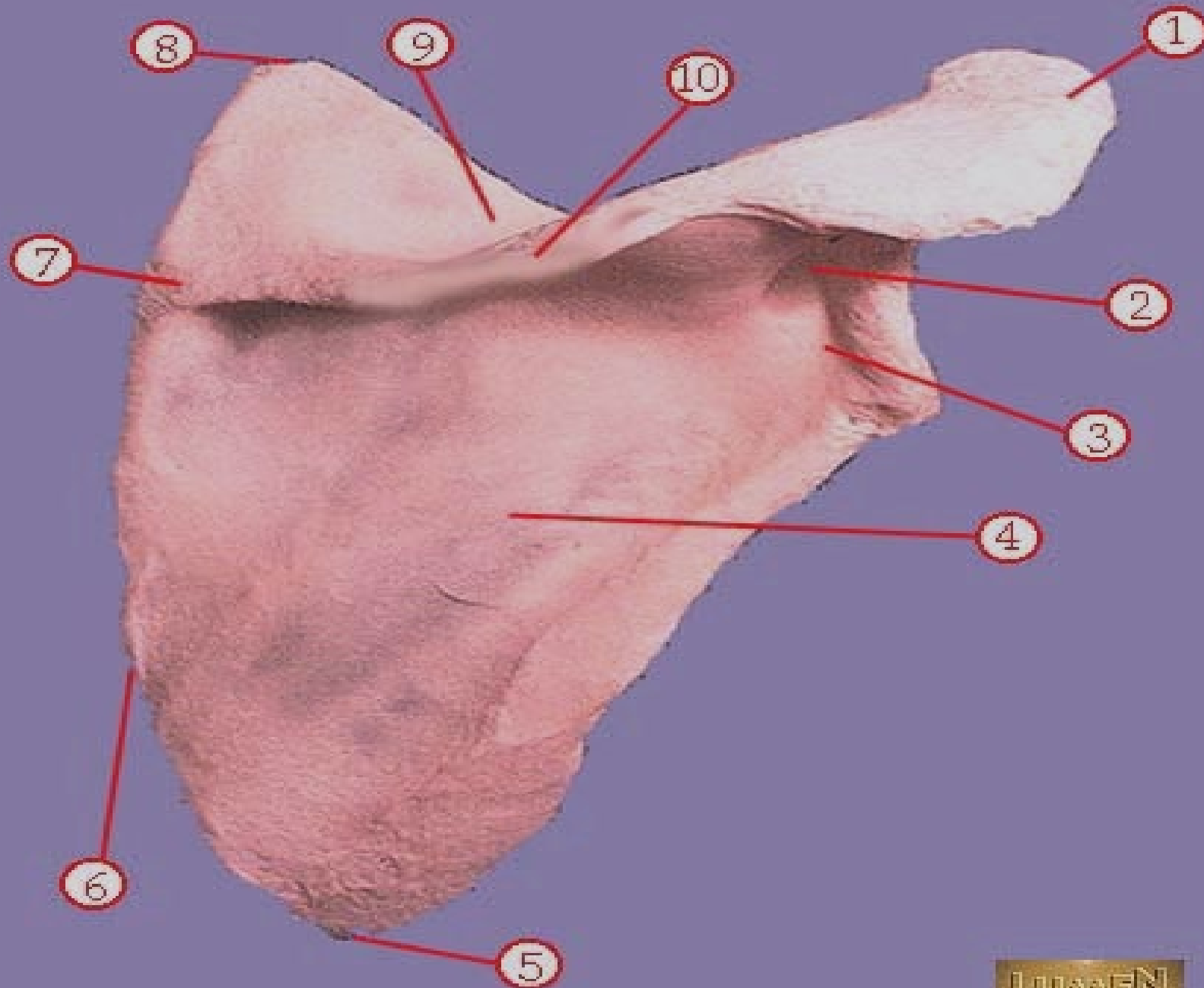


Identify # 1

Identify #10

Identify # 6



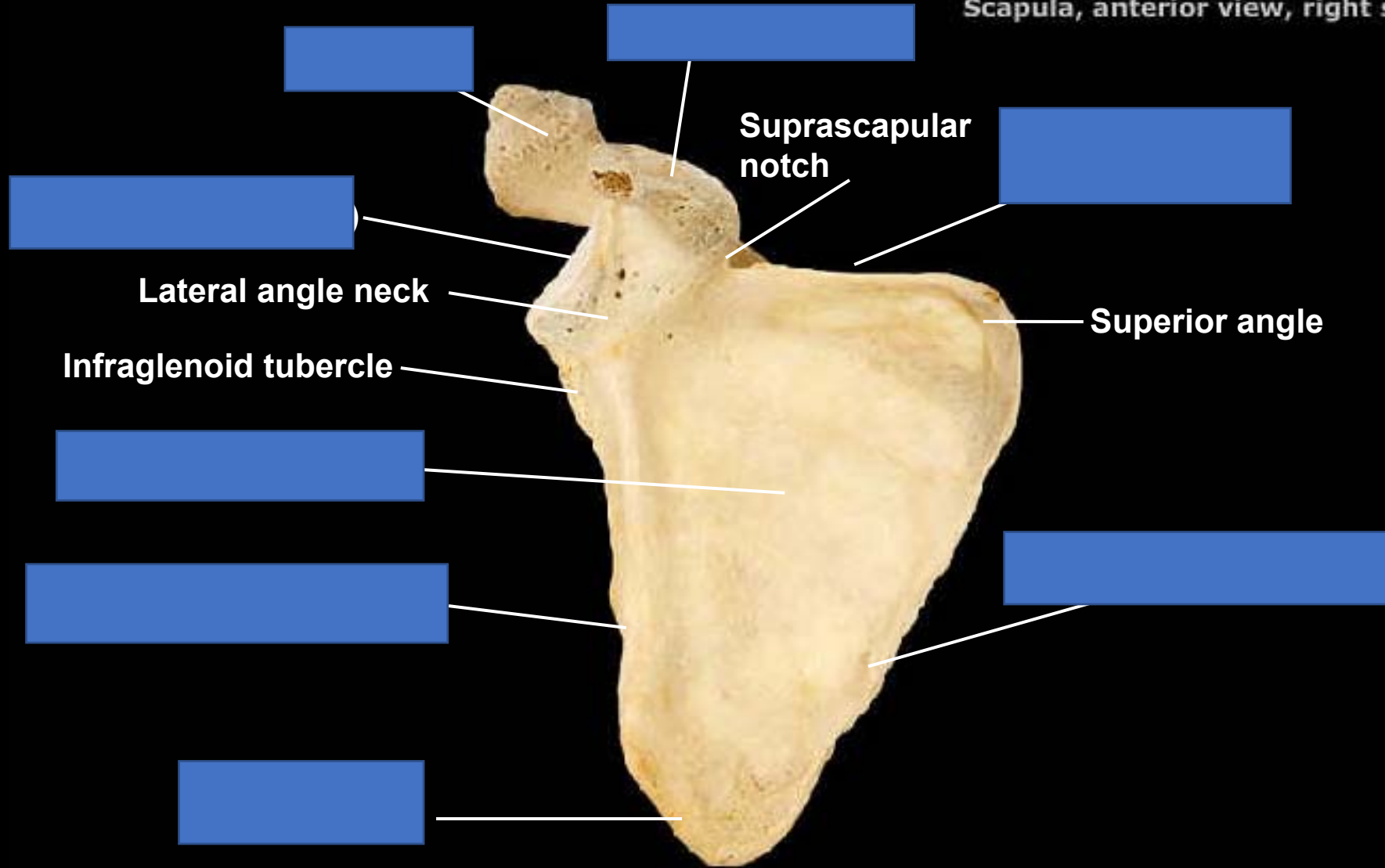


Identify # 1 acromion

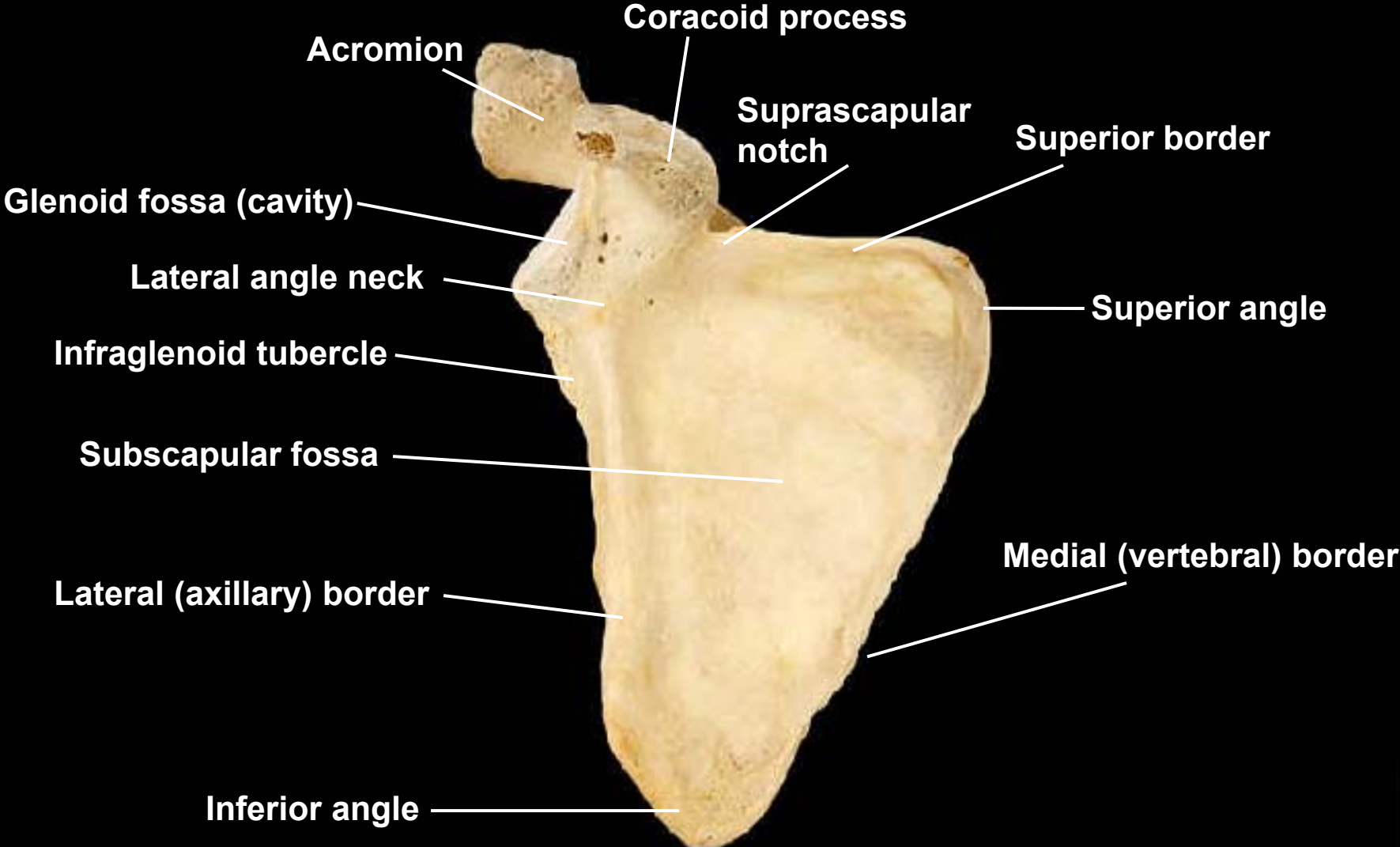
Identify #10 scapular spine
(crest)

Identify # 6 vertebral border
,lateral border

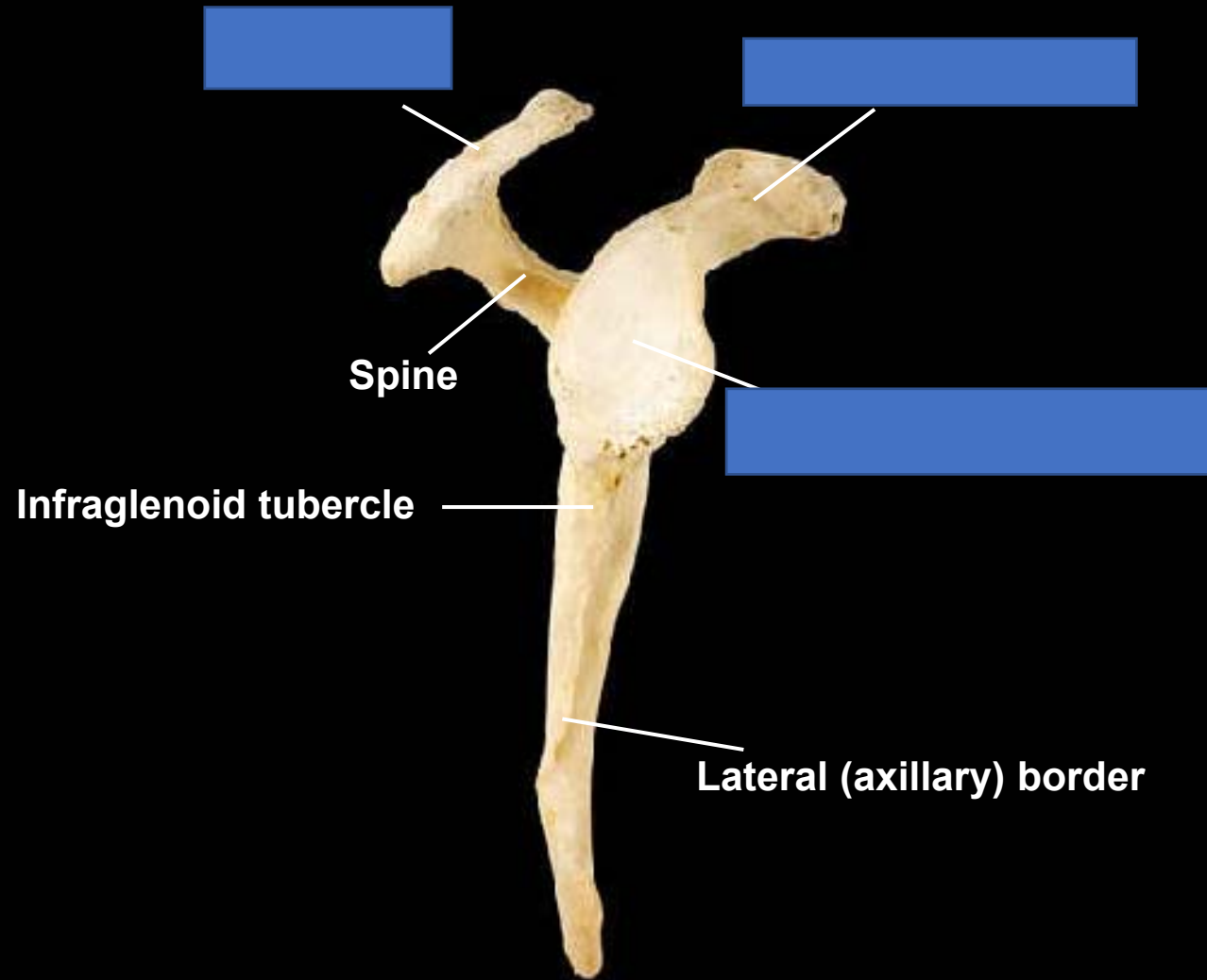
Scapula, anterior view, right side



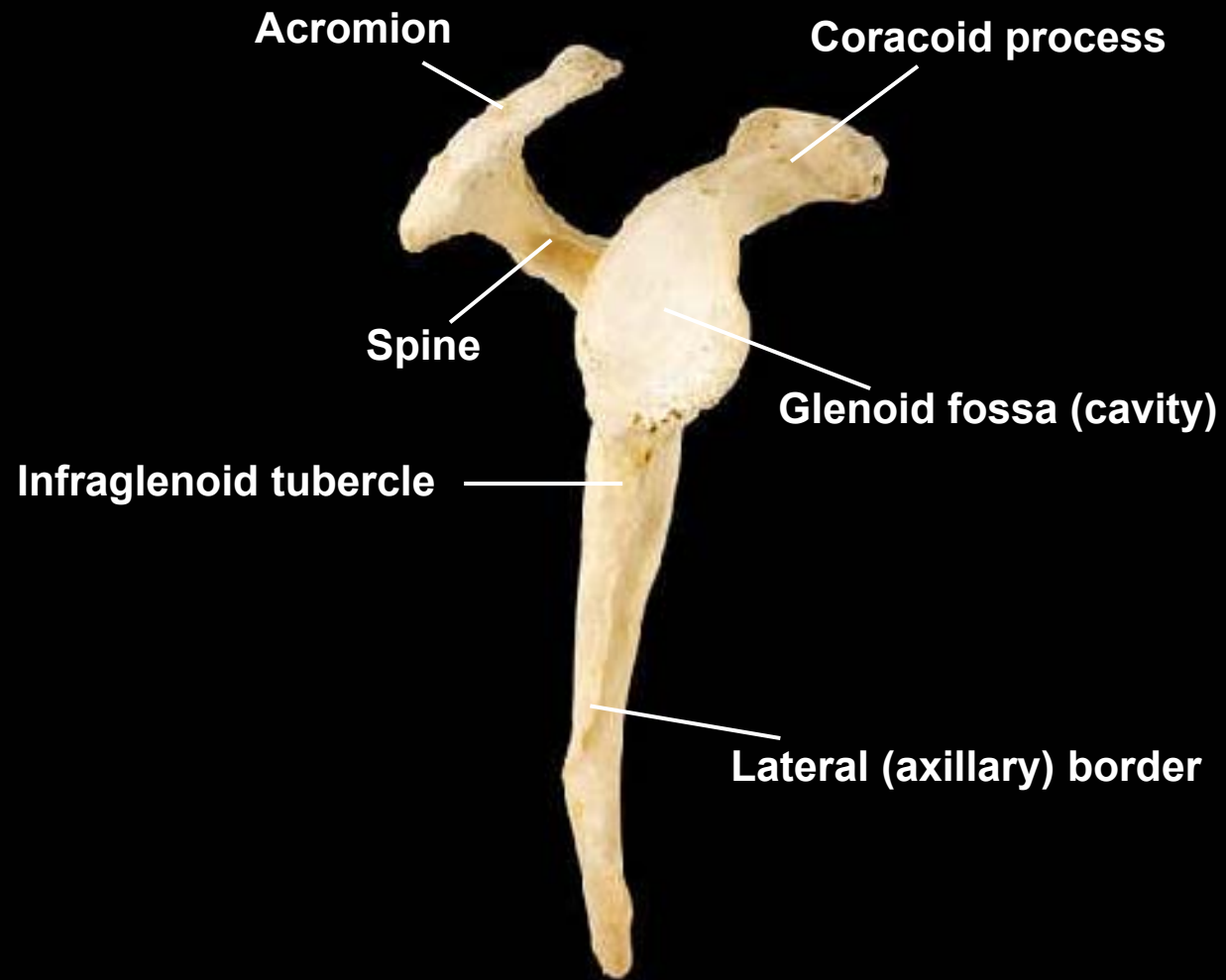
Scapula, anterior view, right side



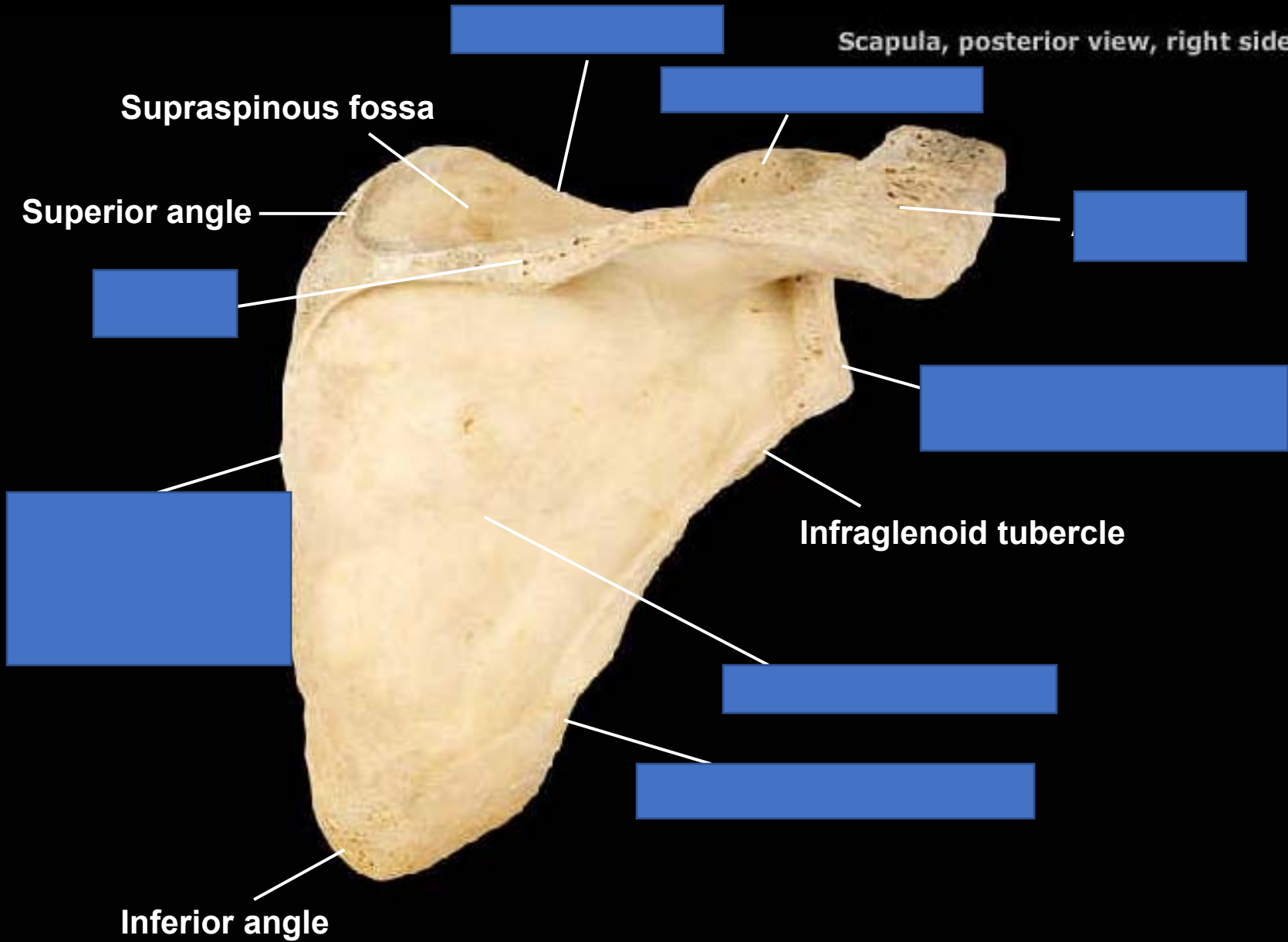
Scapula, lateral view, right side



Scapula, lateral view, right side



Scapula, posterior view, right side

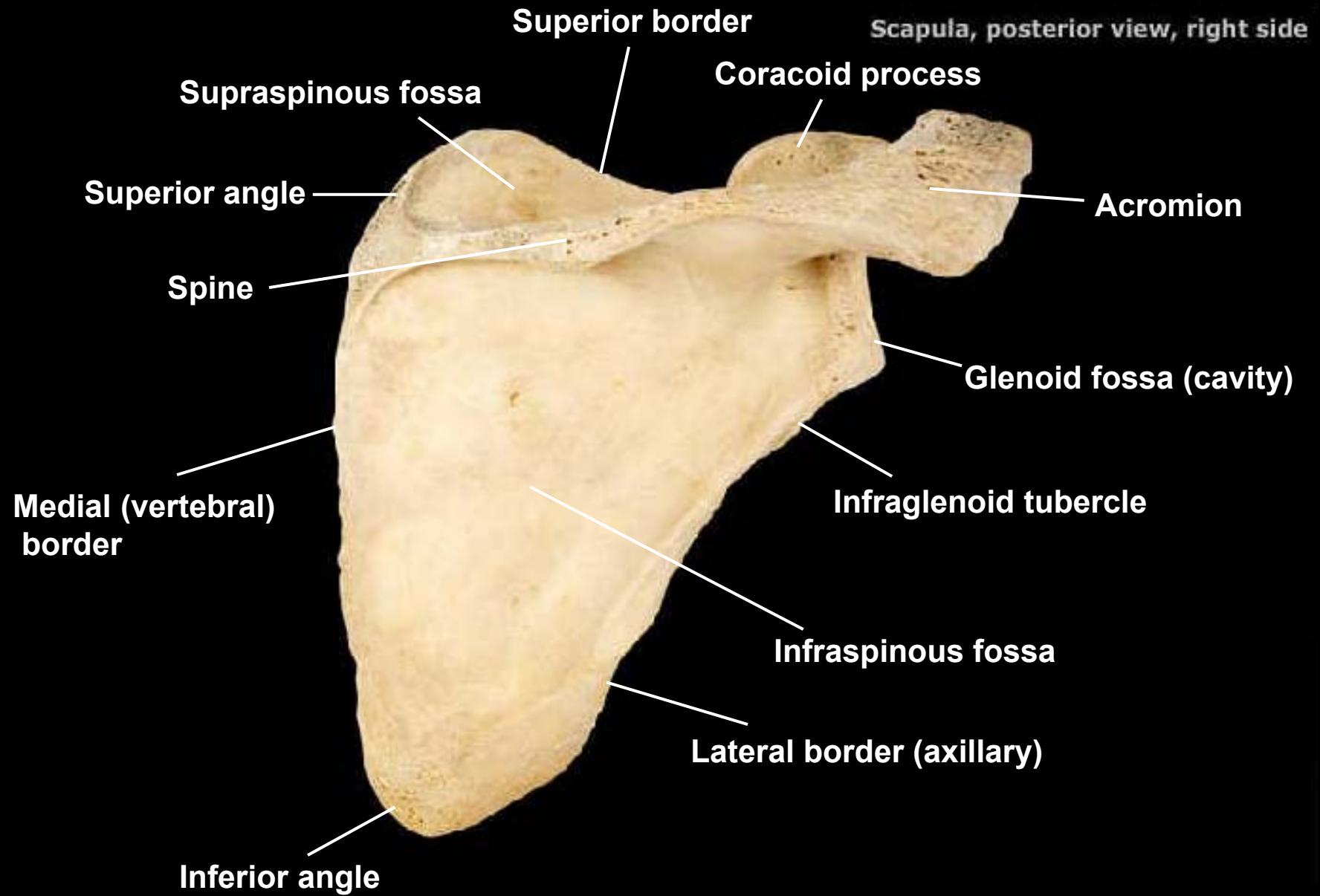


Supraspinous fossa

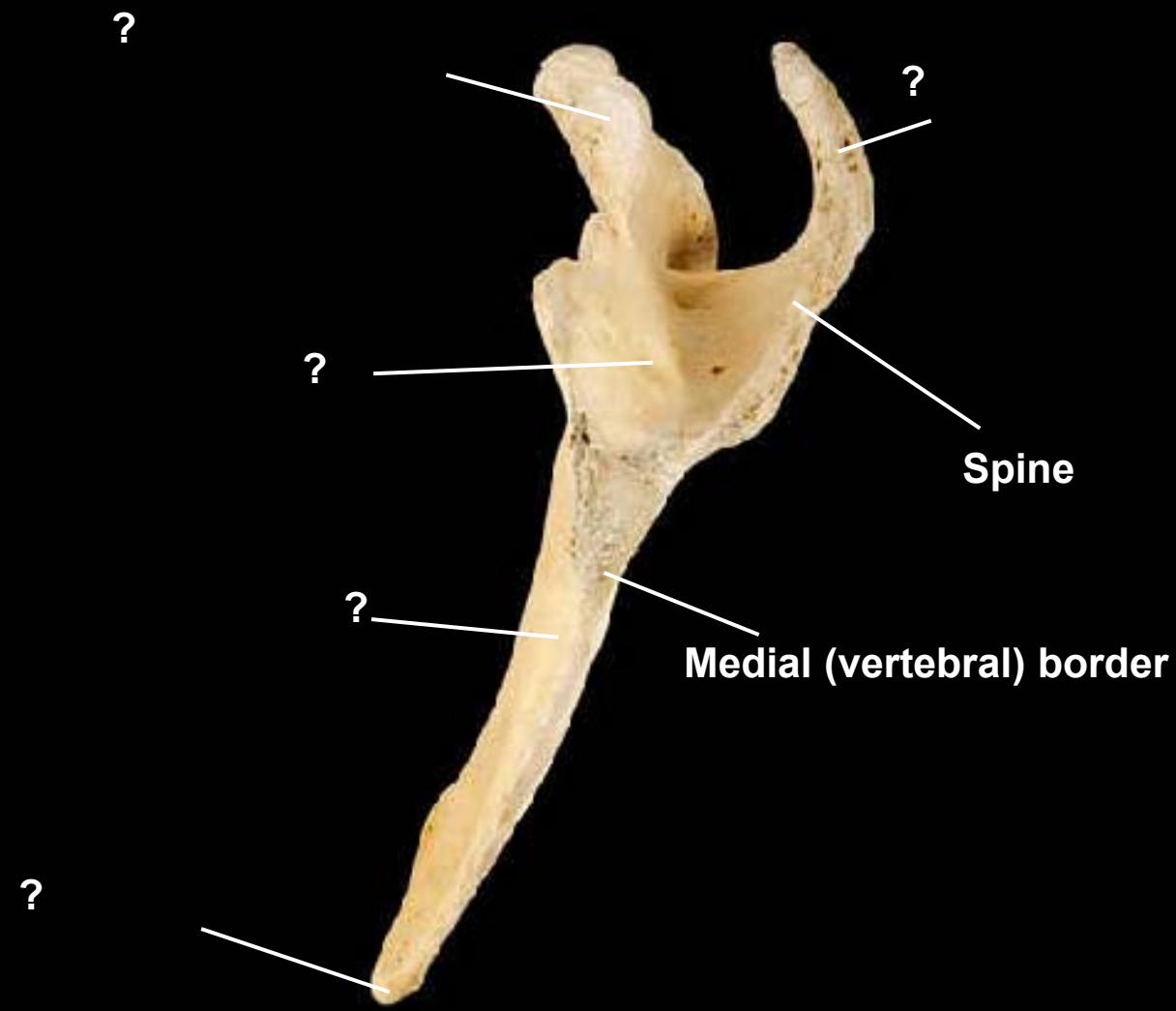
Superior angle

Infraglenoid tubercle

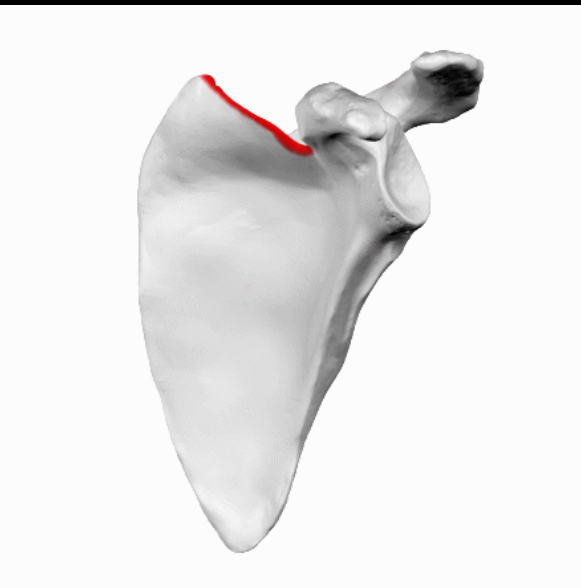
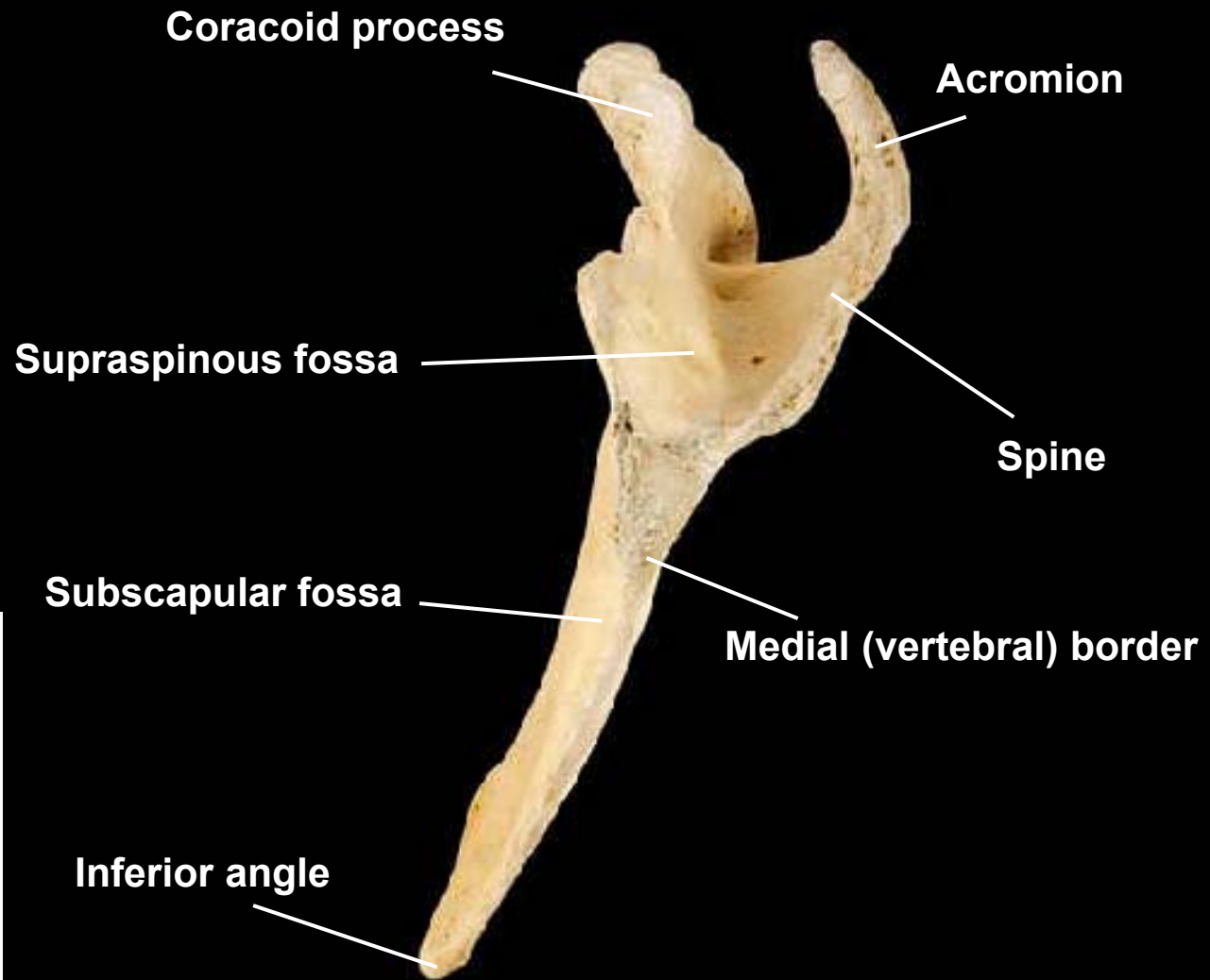
Inferior angle



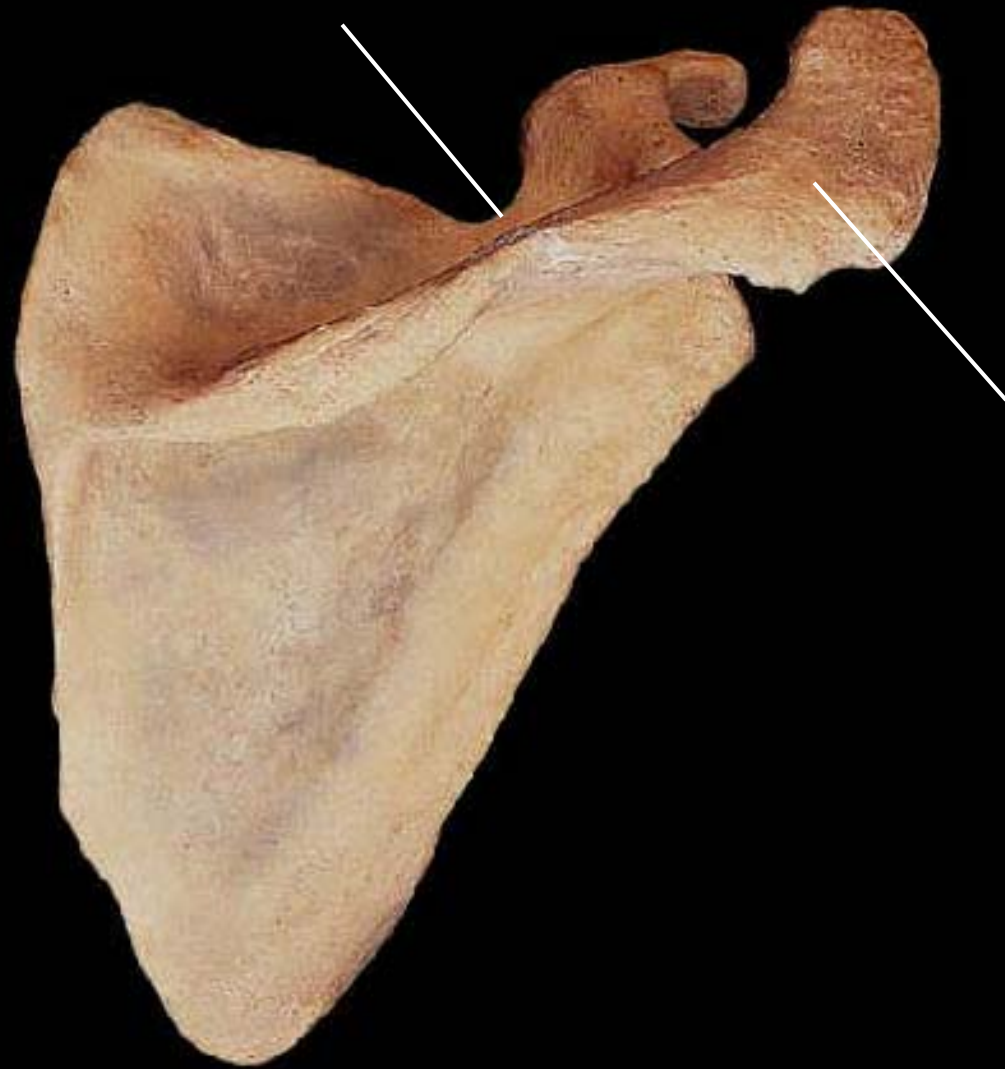Scapula, medial view, right side



Scapula, medial view, right side



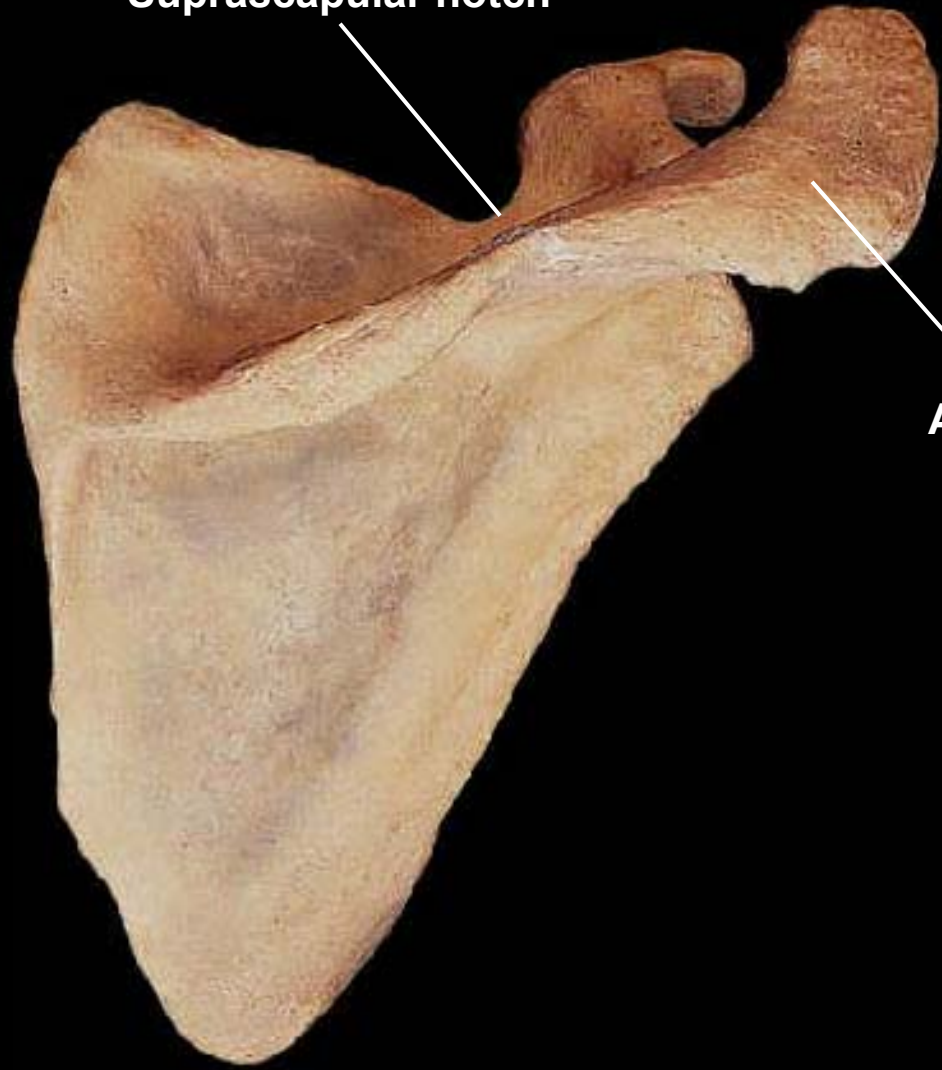
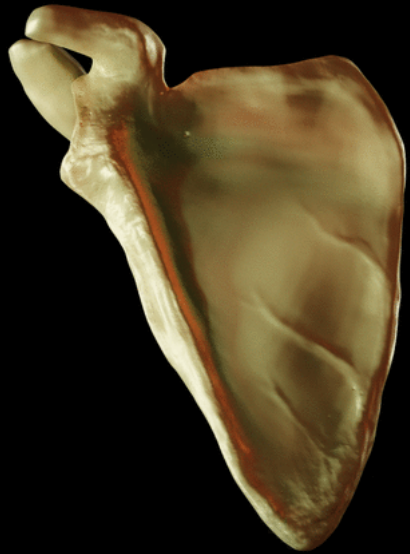Scapula, posterior view, right side

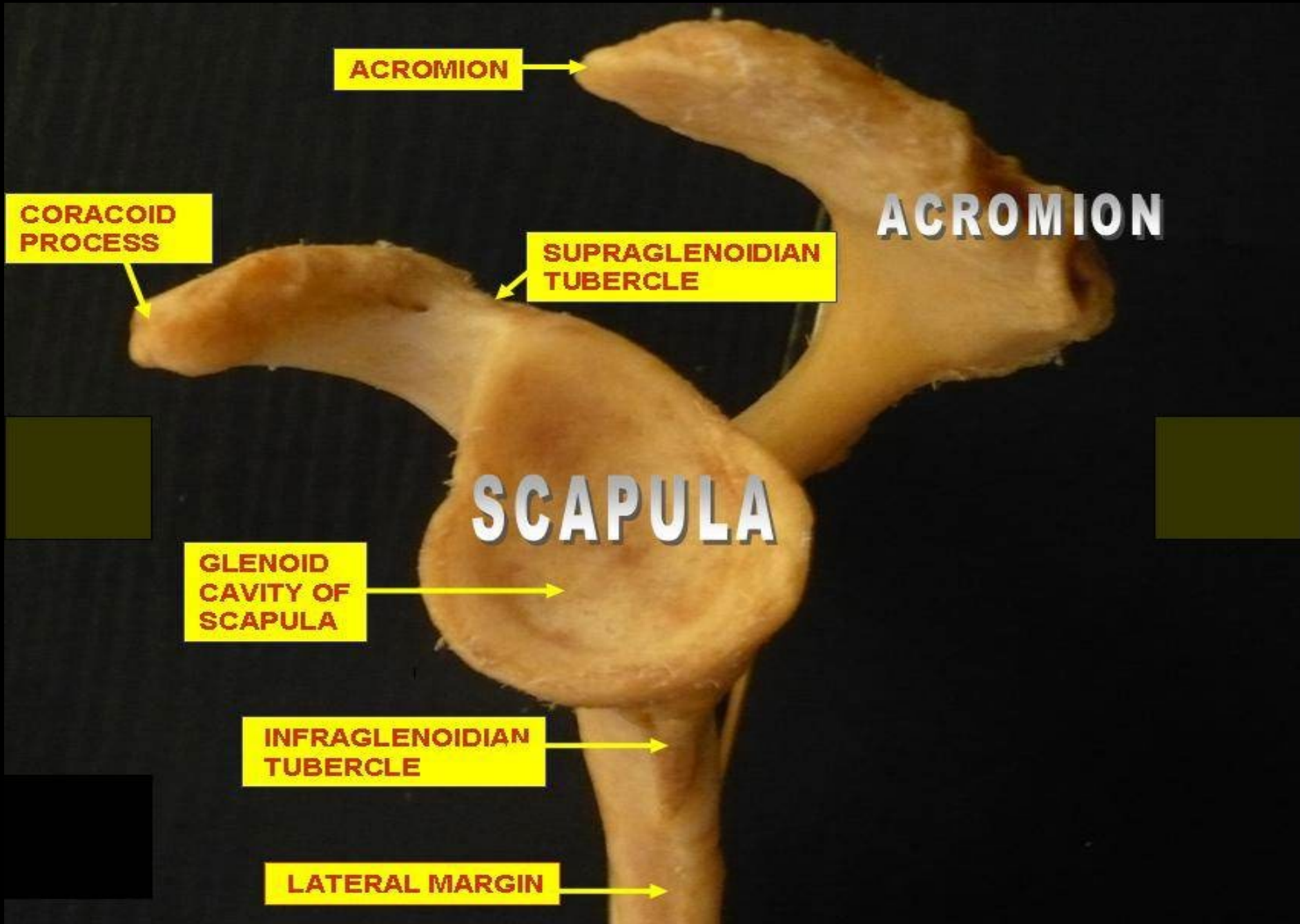


Scapula, posterior view, right side

Suprascapular notch

Acromion





ACROMION

CORACOID
PROCESS

SUPRAGLENOIDIAN
TUBERCLE

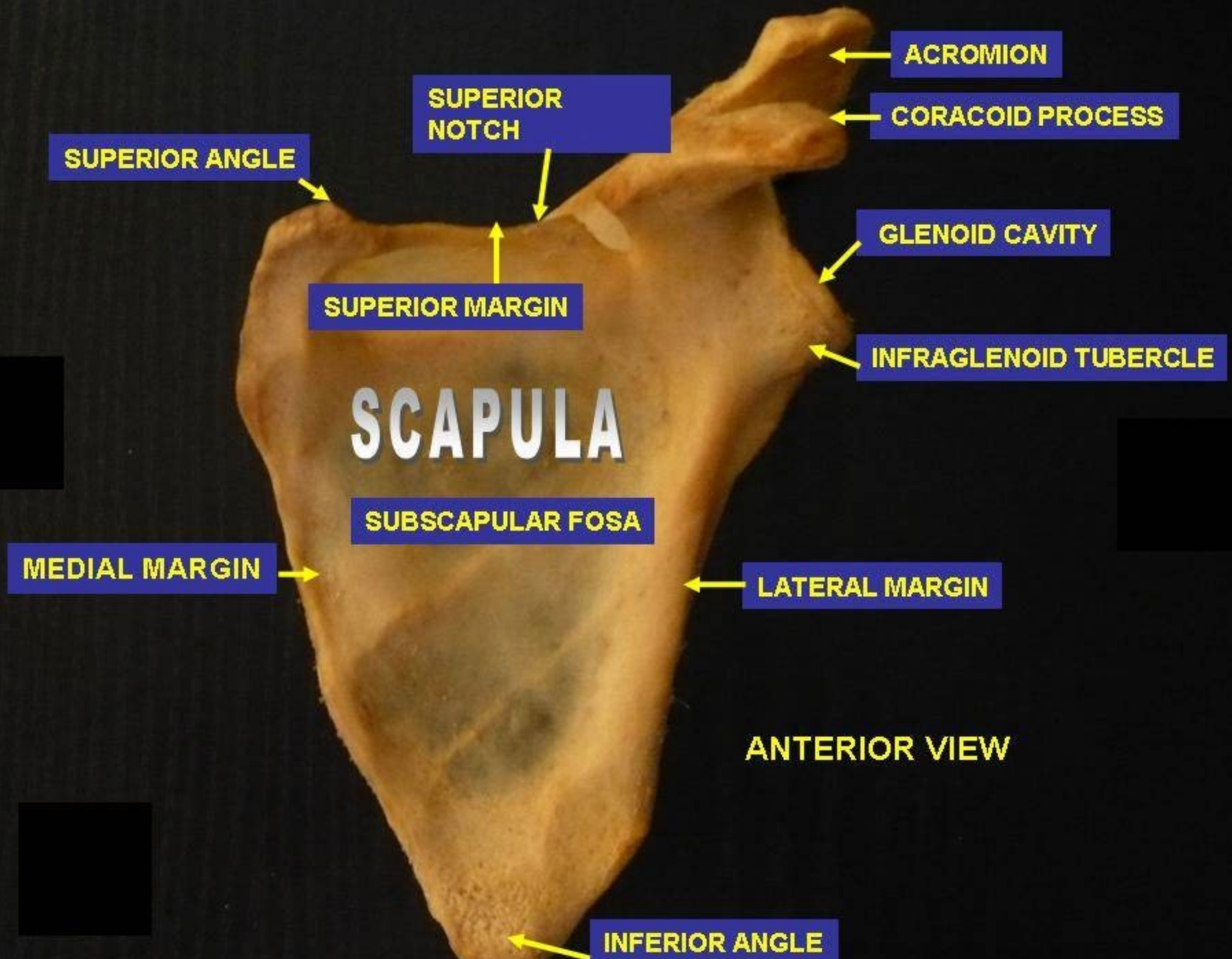
ACROMION

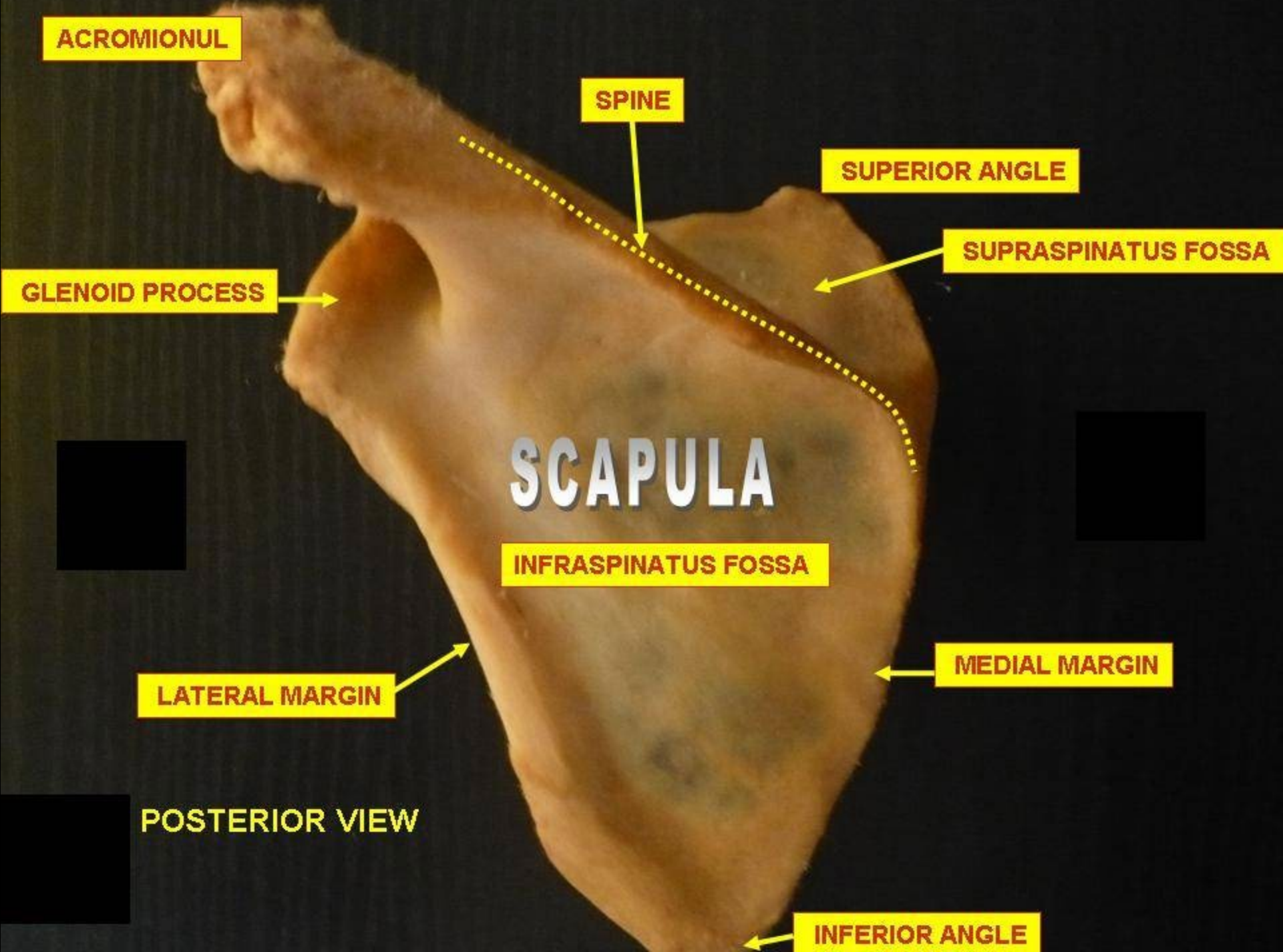
SCAPULA

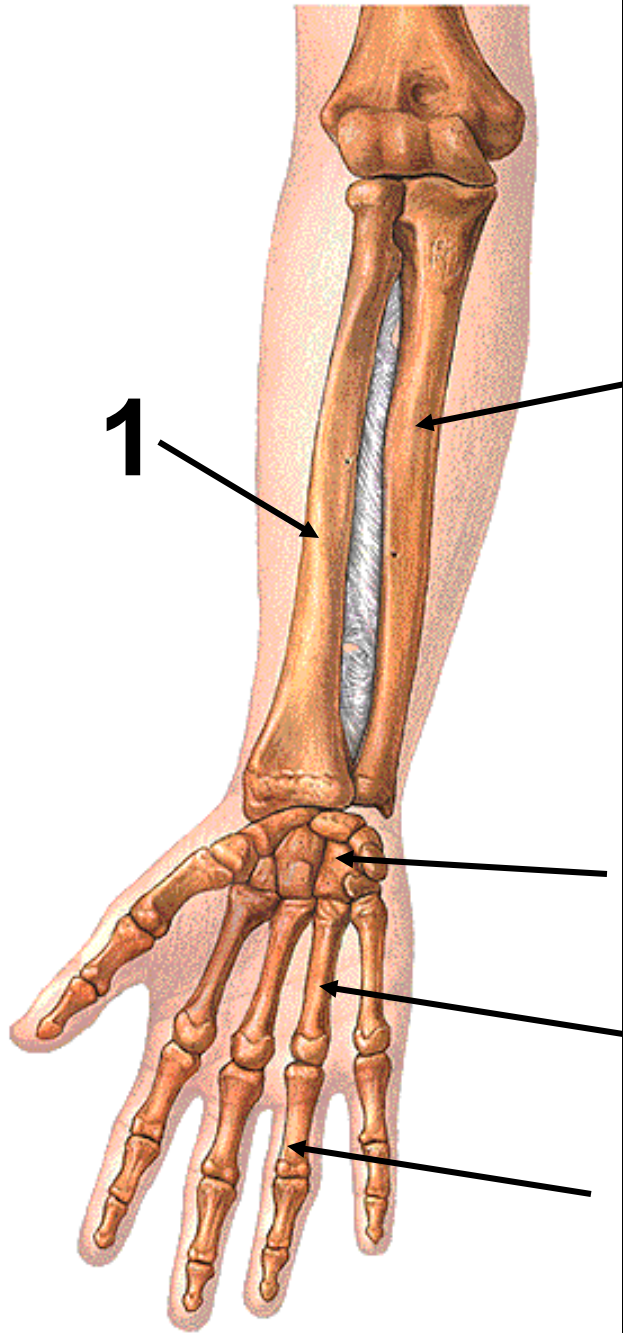
GLENOID
CAVITY OF
SCAPULA

INFRAGLENOIDIAN
TUBERCLE

LATERAL MARGIN







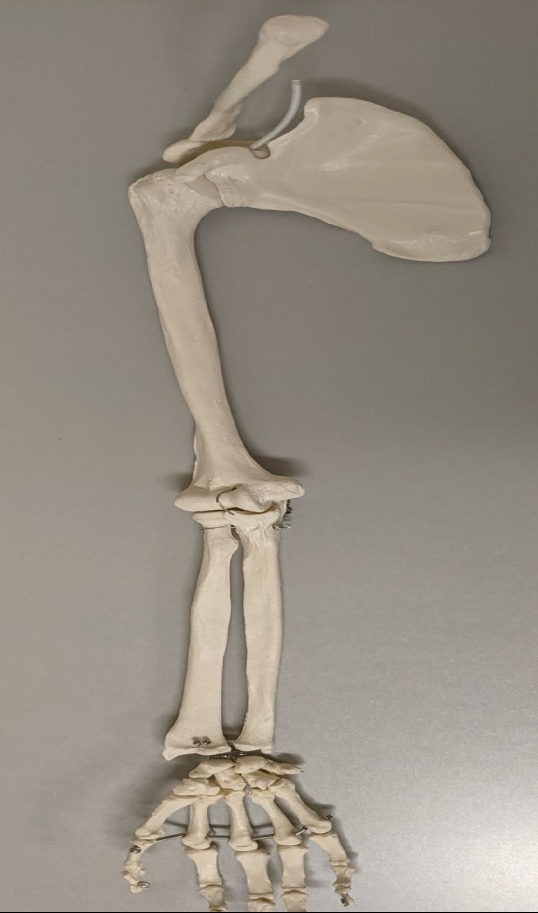1

2

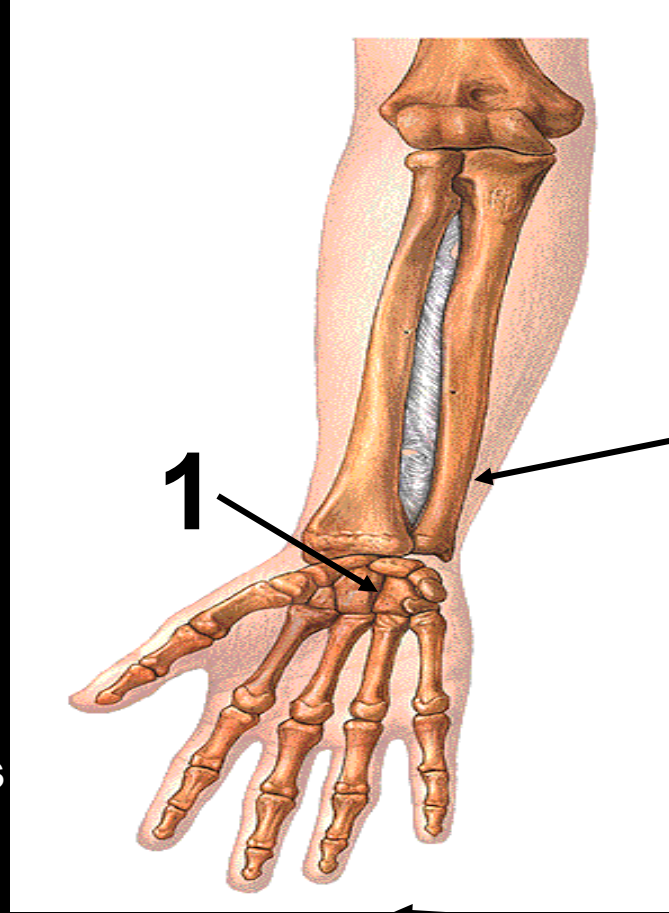
3

4

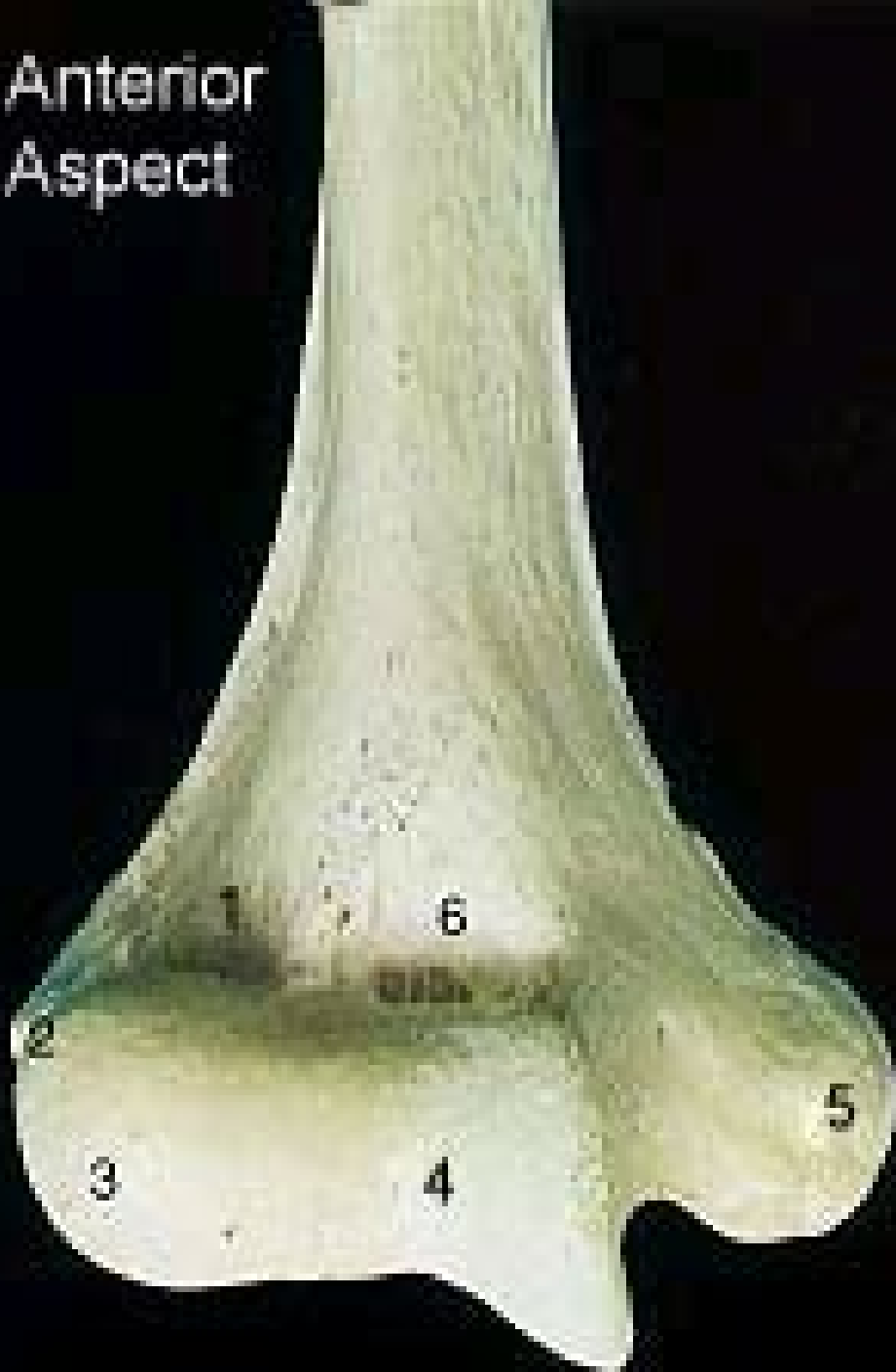
5



1. Radius
2. Ulna
3. Carpals
4. Metacarpals
5. Phalanges



Anterior
Aspect

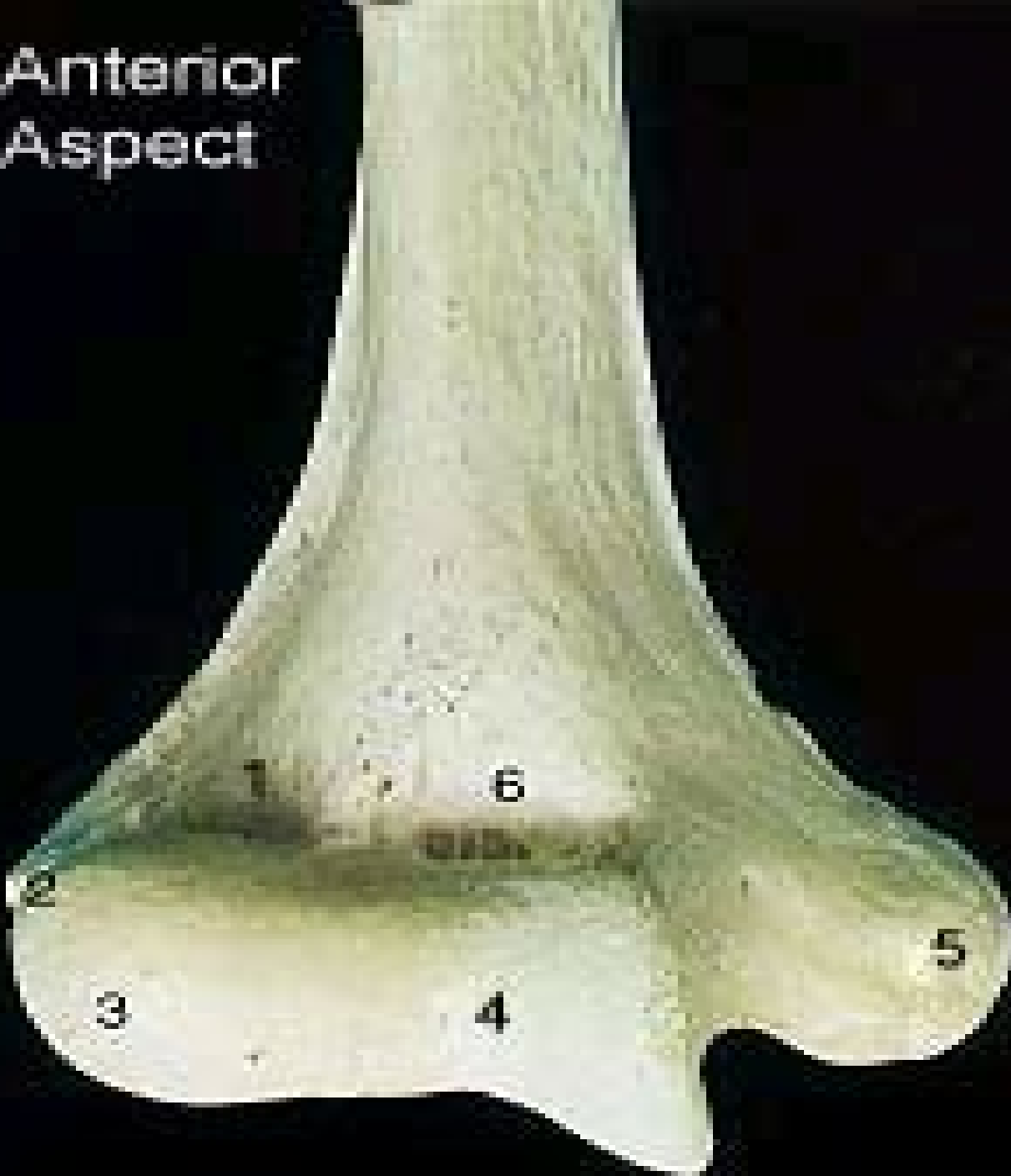

What bone is this?

Identify structure # 5

Identify structure # 6

Anterior
Aspect

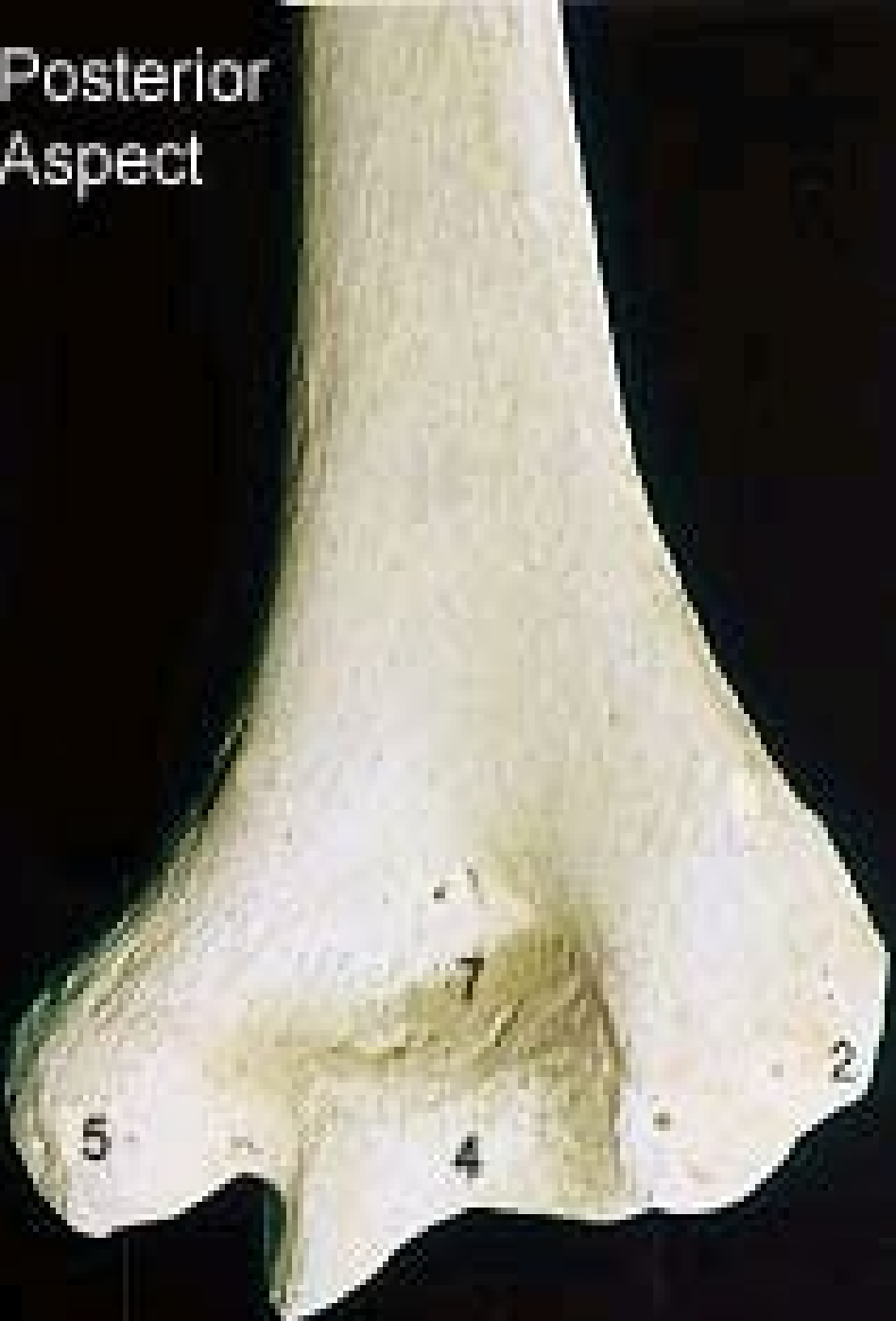

What bone is this? **humerus**

Identify structure # 5 **Medial Epicondyle**

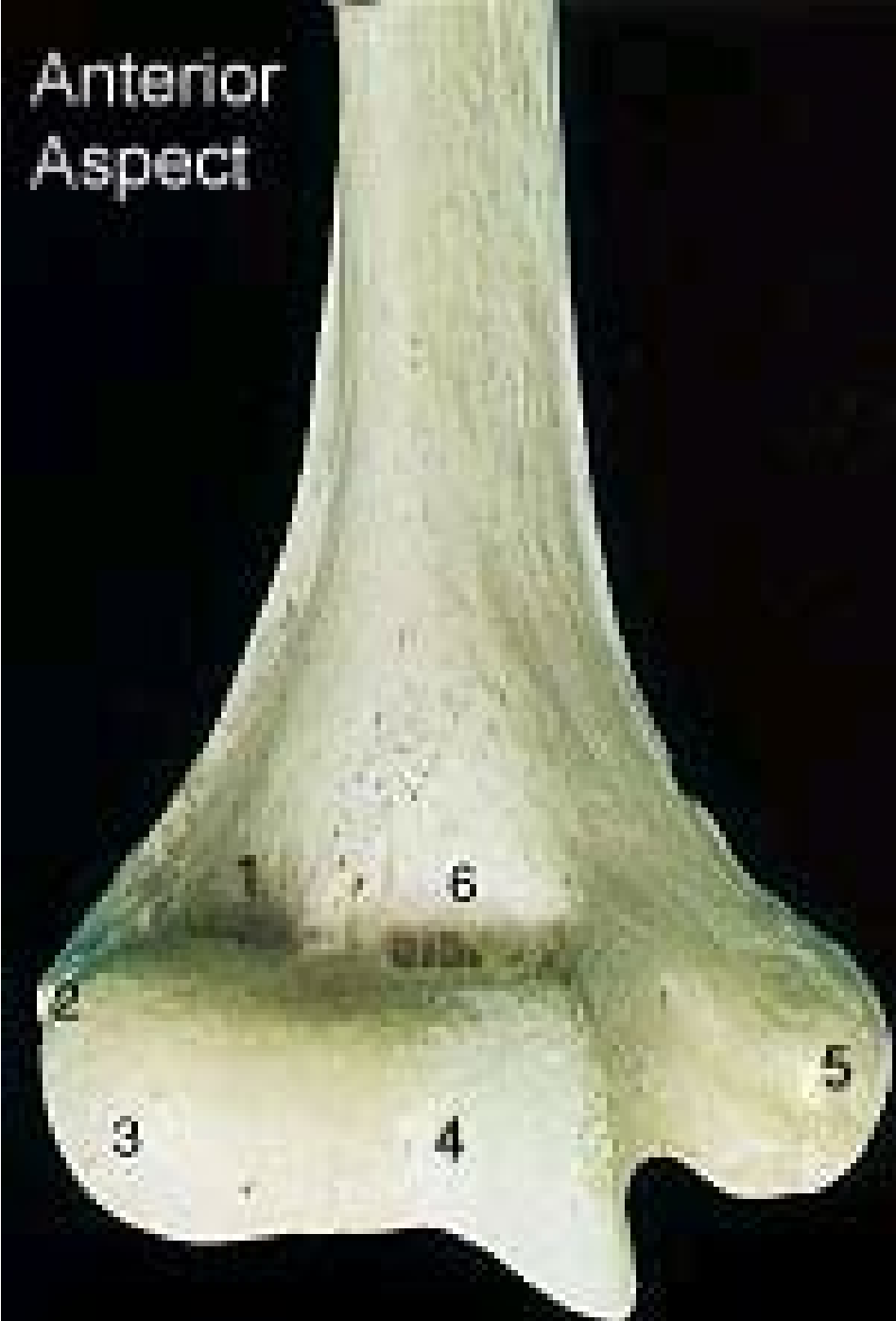
Identify structure # 6 **Coronoid Fossa**

Posterior Aspect

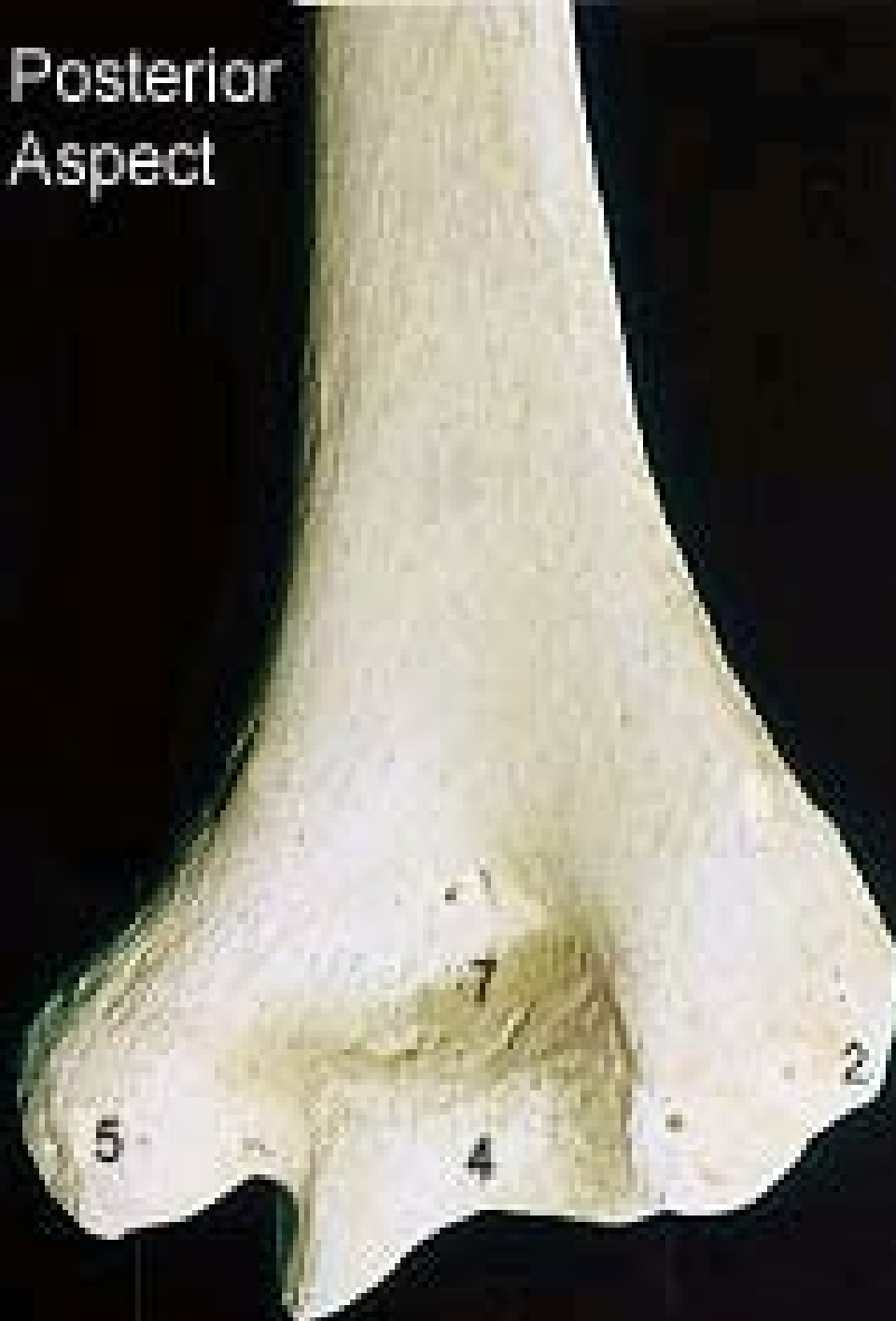

- 1.
- 2.
- 3.
- 4.
- 5.
- 6.
- 7.

Anterior Aspect

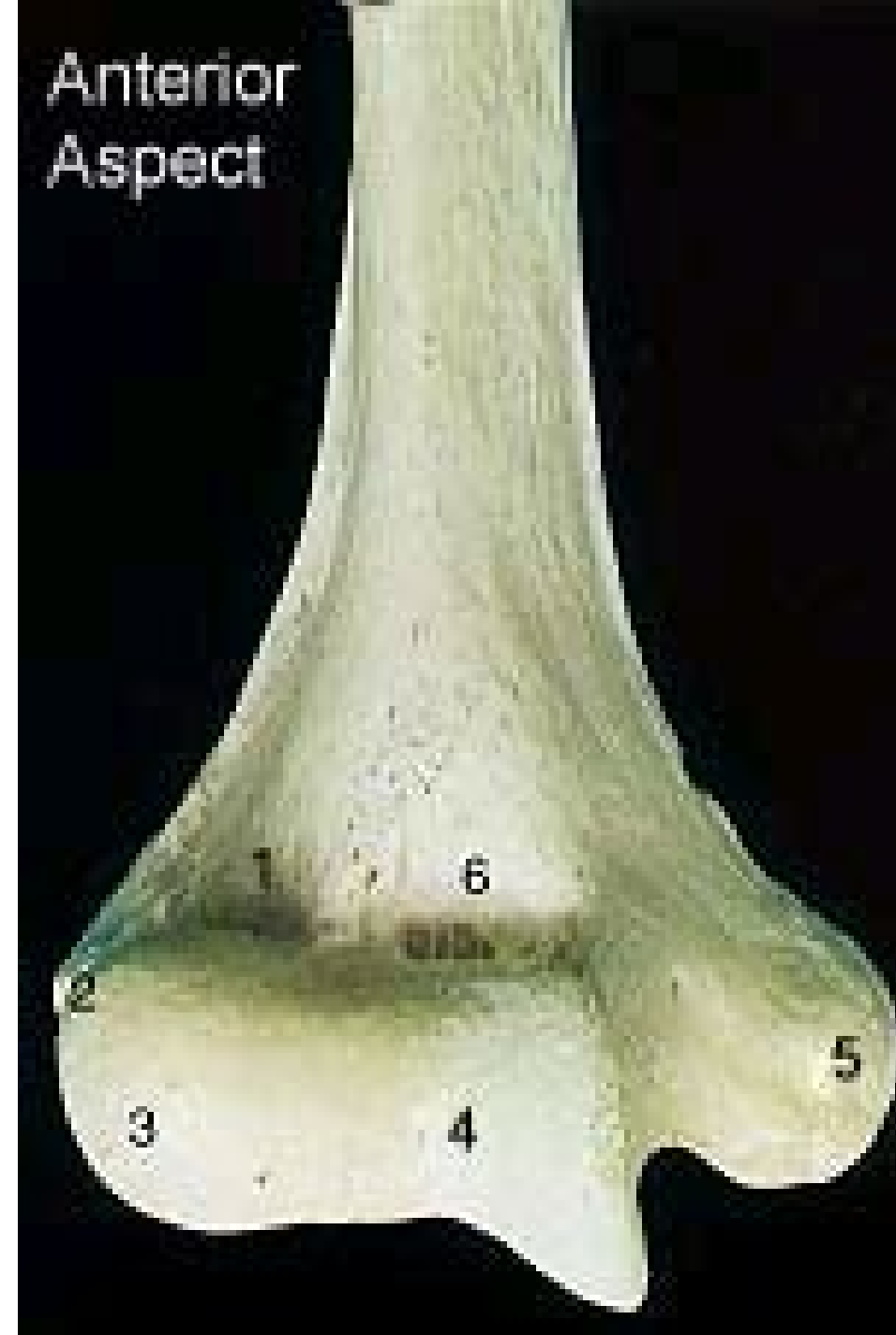


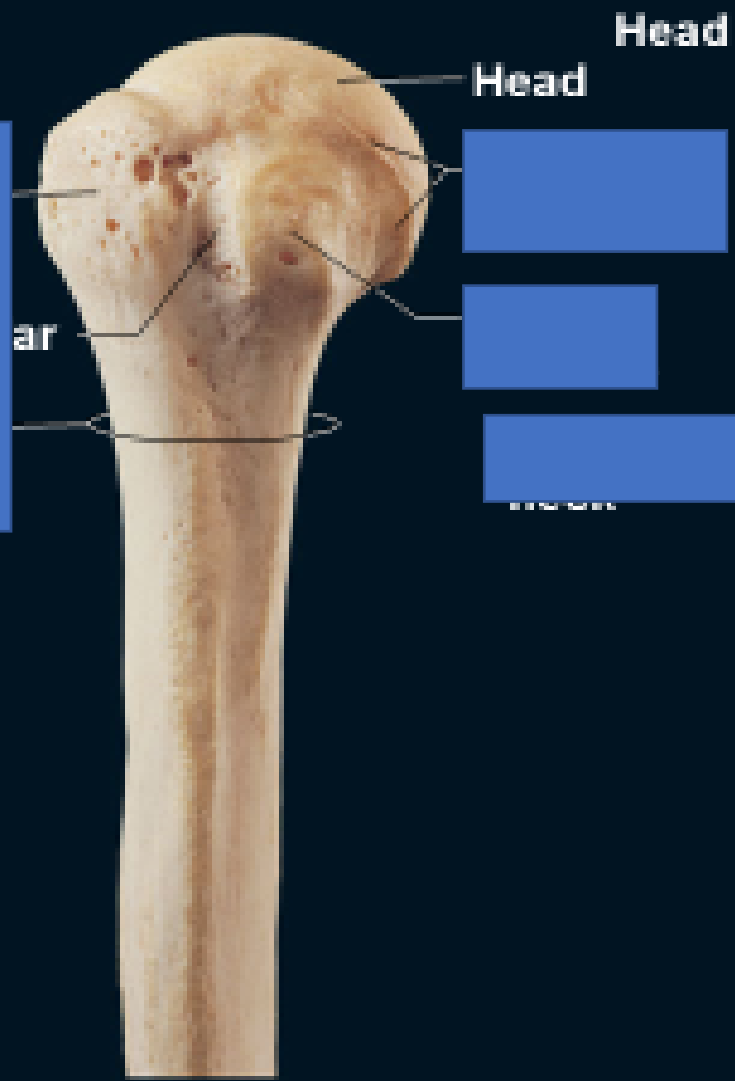
Posterior Aspect



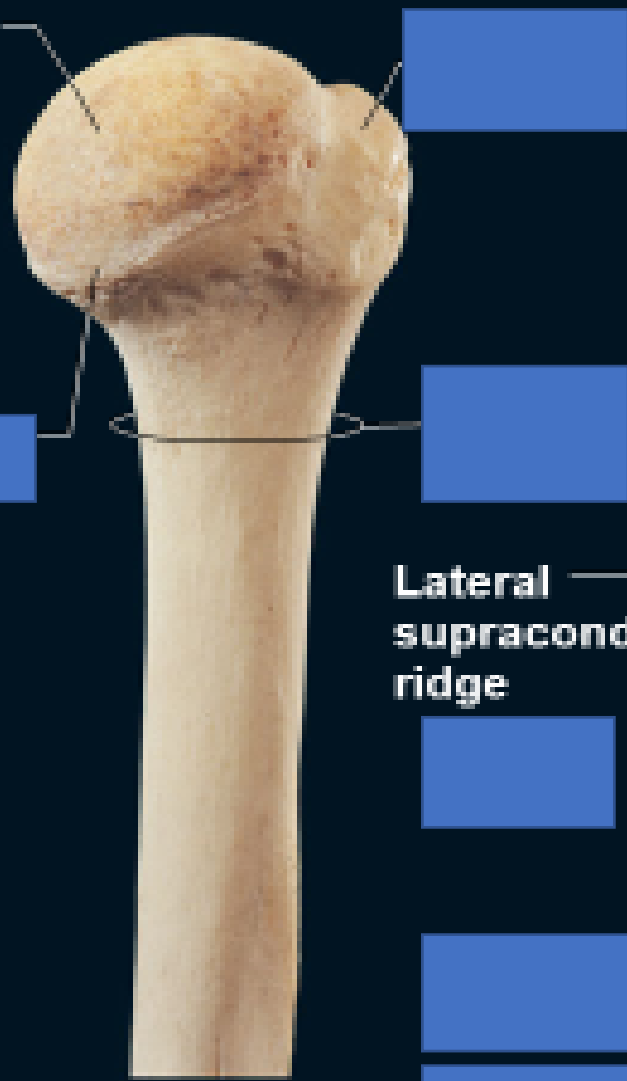
1. Radial Fossa
2. Lateral Epicondyle
3. Capitulum
4. Trochlea
5. Medial Epicondyle
6. Coronoid Fossa
7. Olecranon Fossa

Anterior Aspect

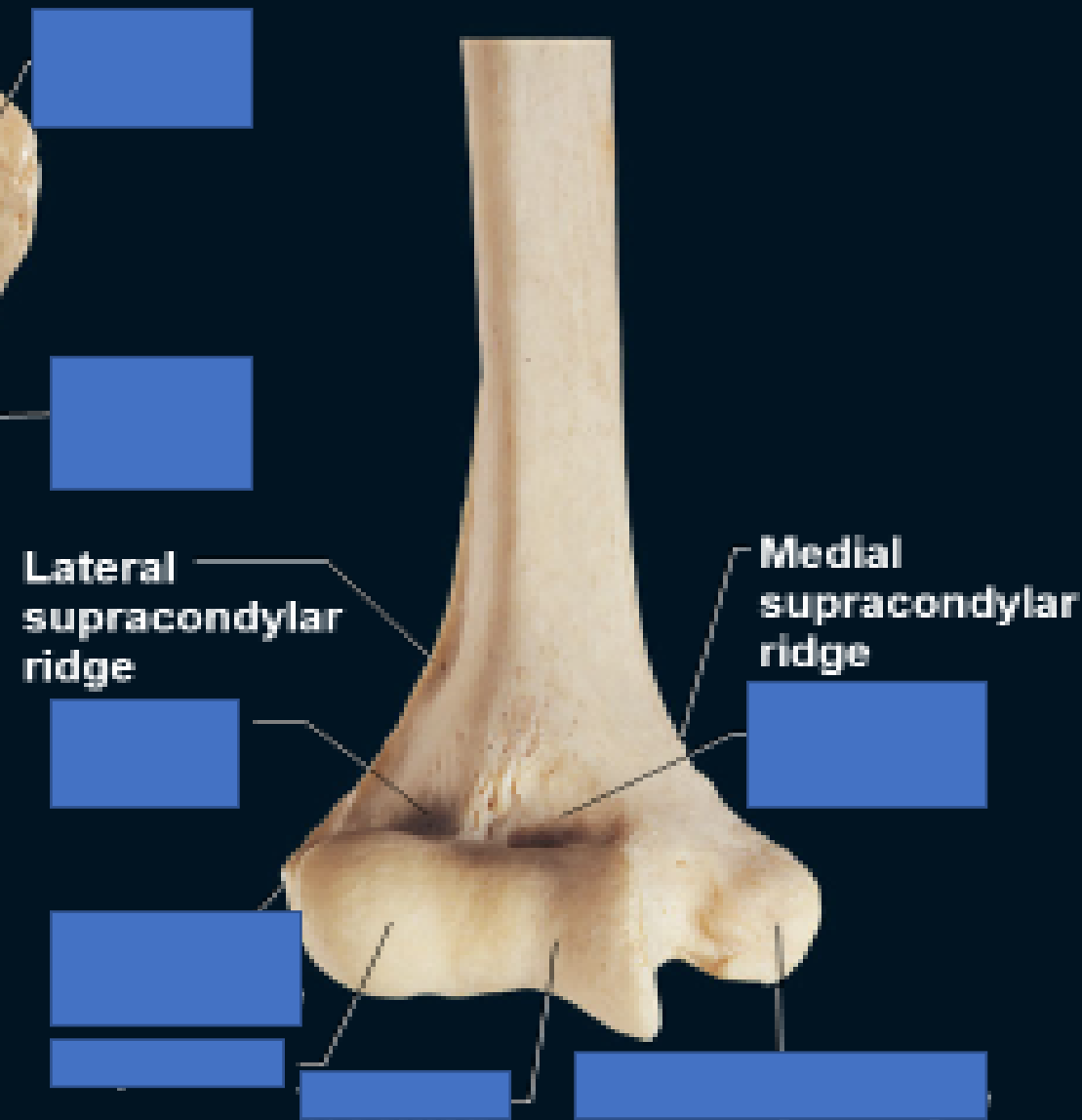




(c) proximal end, anterior view

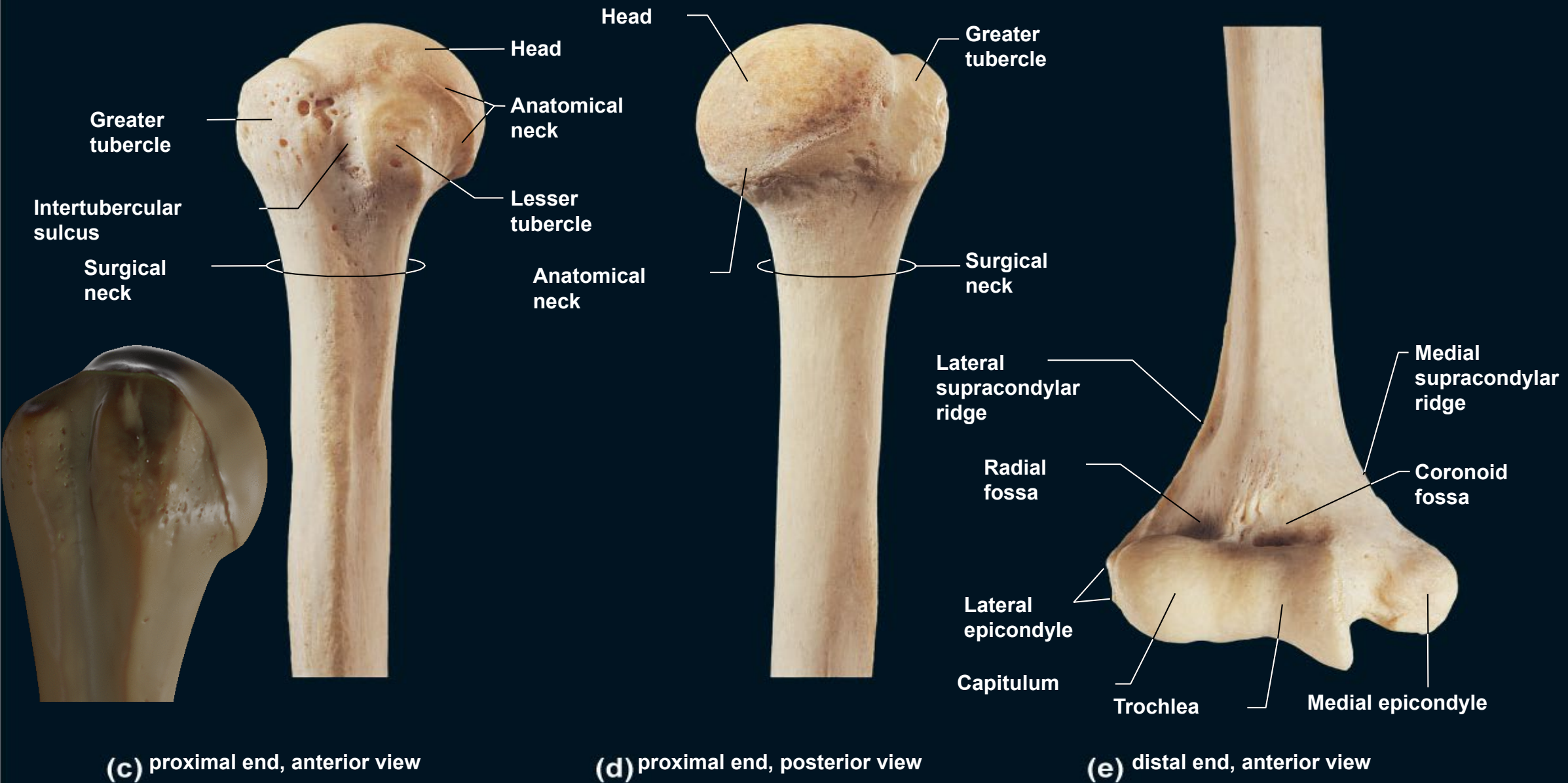


(d) proximal end, posterior view



(e) distal end, anterior view

Figure 25 Right humerus.



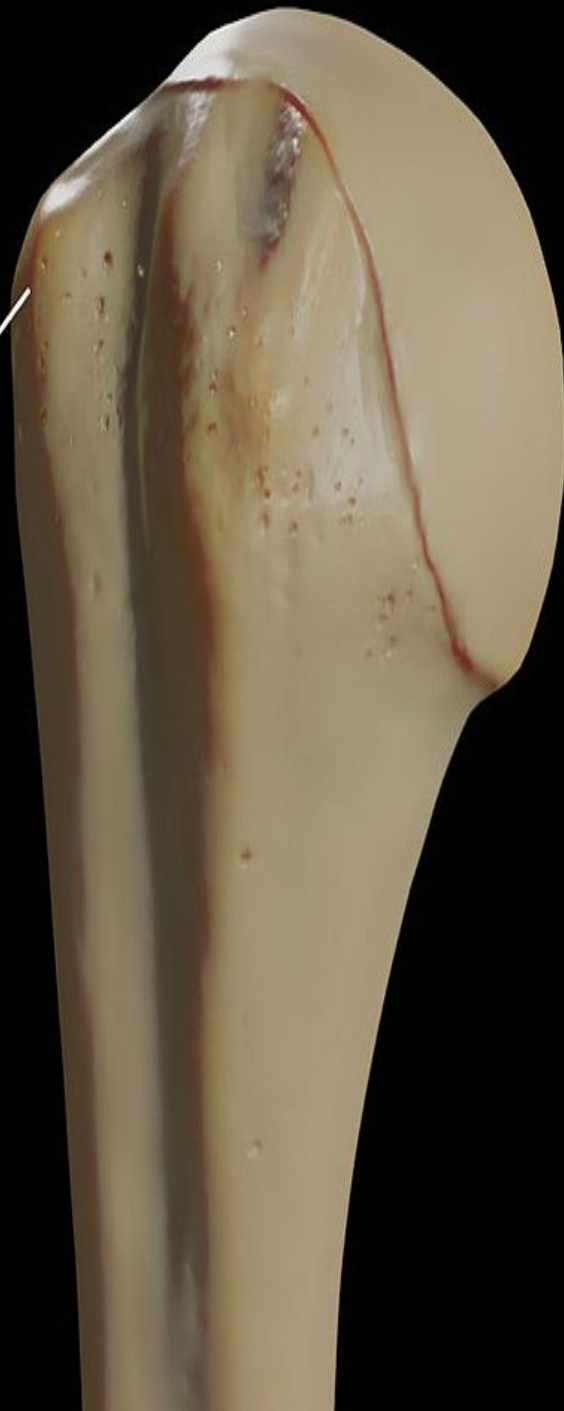(c) proximal end, anterior view

(d) proximal end, posterior view

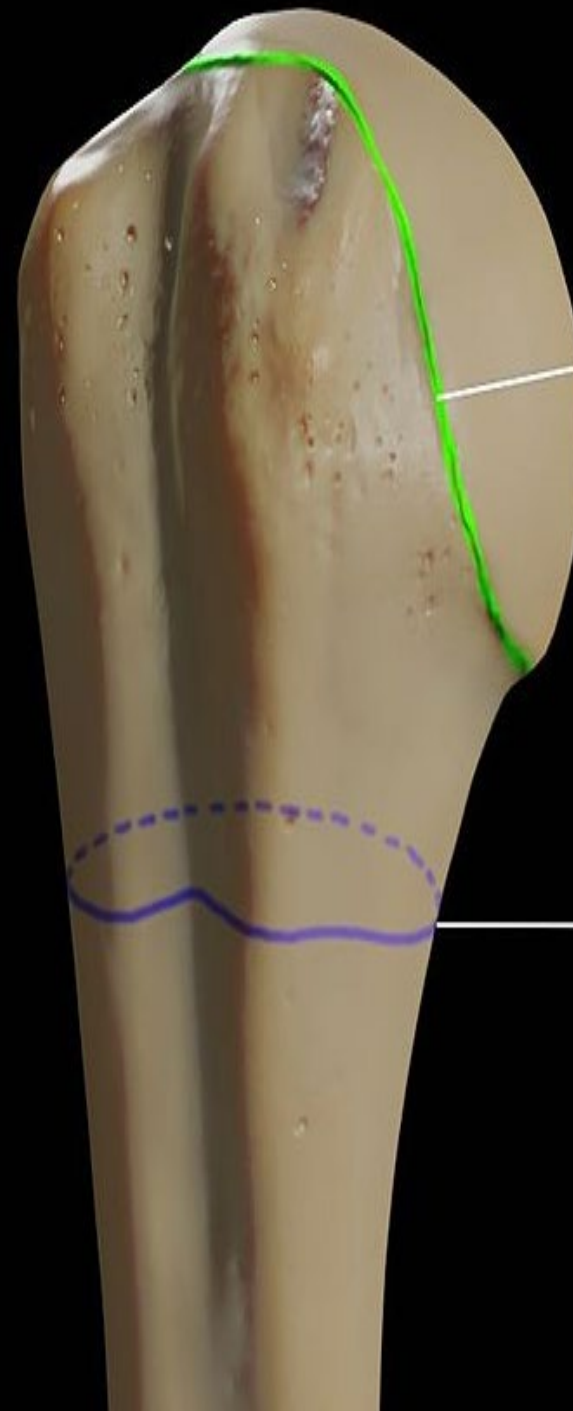
(e) distal end, anterior view

Figure 25 Right humerus.

Greater Tubercle

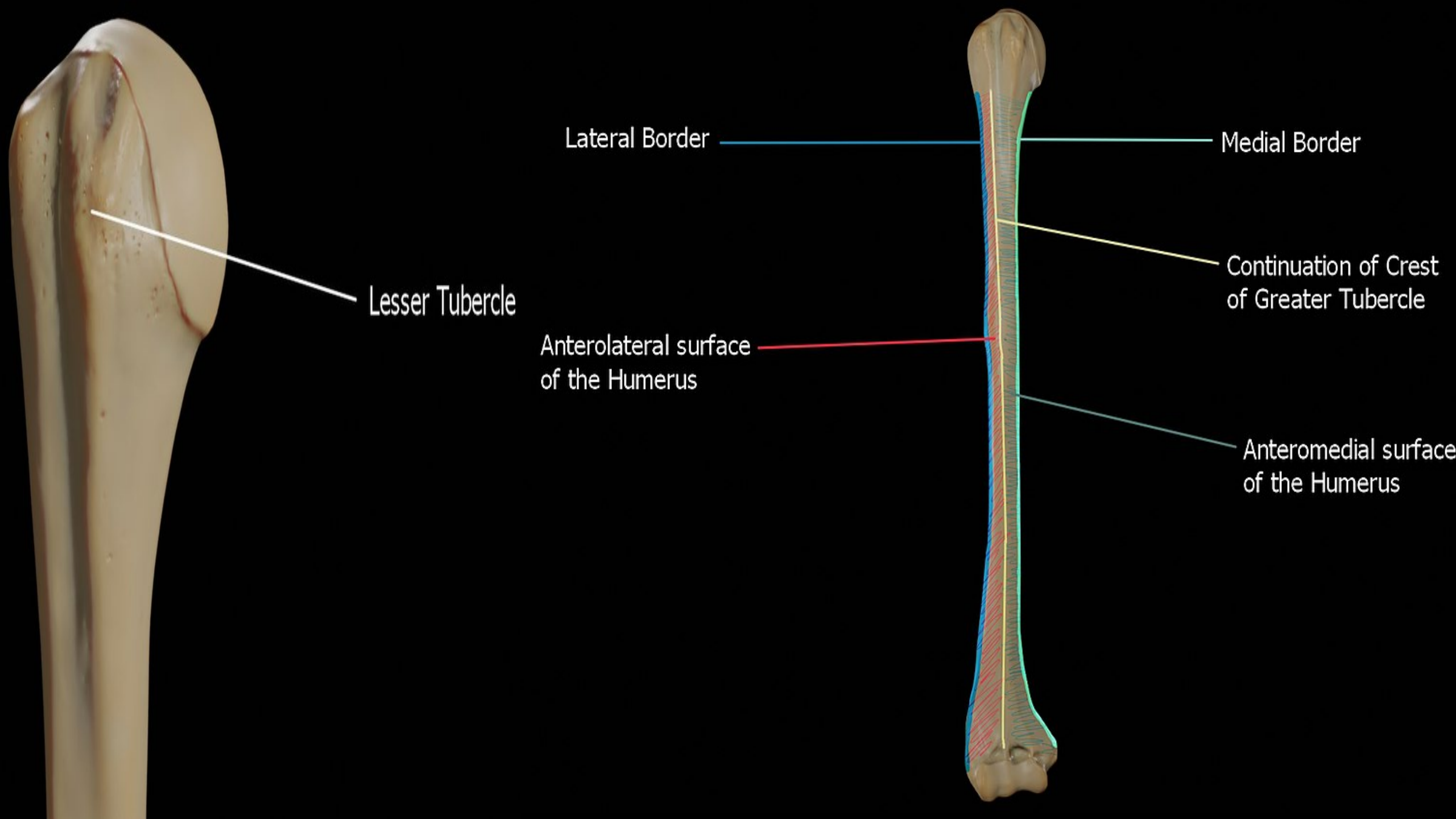


Anatomical Neck of Humerus



Surgical Neck of Humerus





Lesser Tubercle

Lateral Border

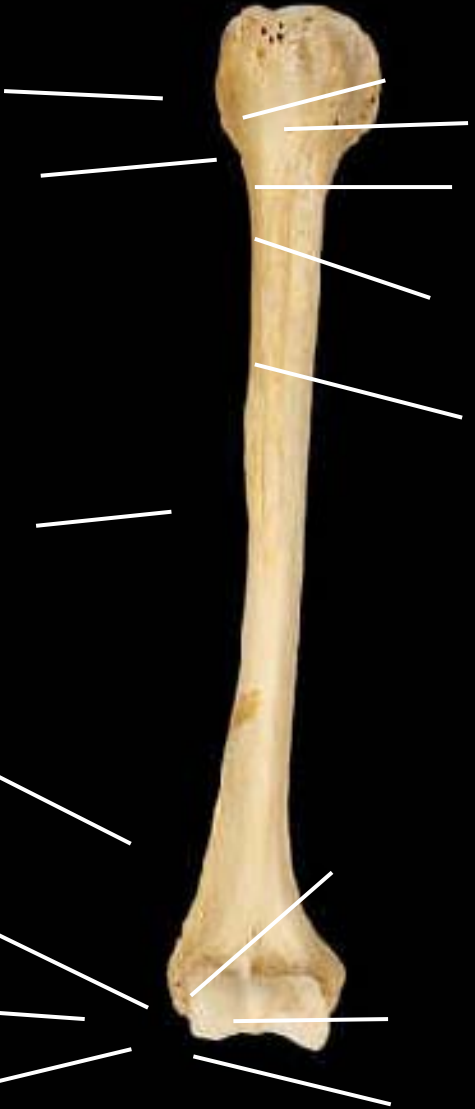Medial Border

Anterolateral surface
of the Humerus

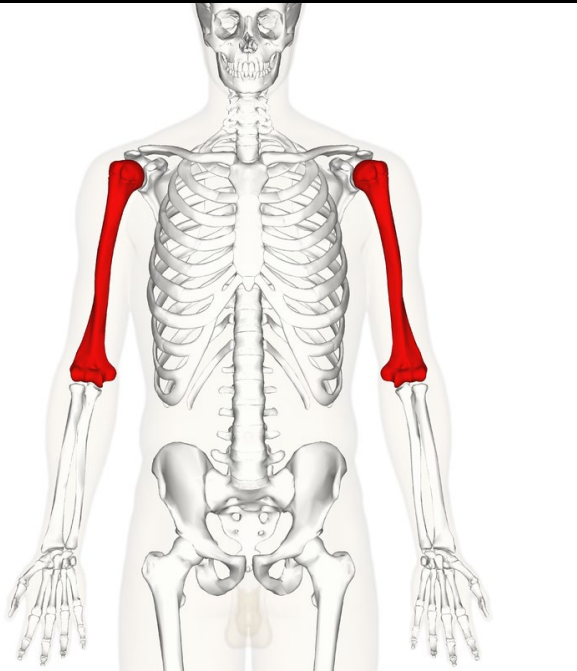
Continuation of Crest
of Greater Tubercle

Anteromedial surface
of the Humerus

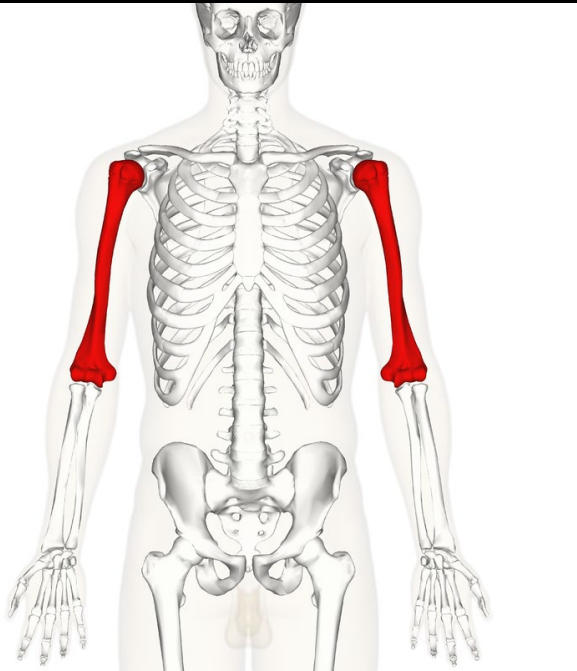
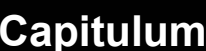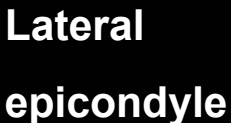
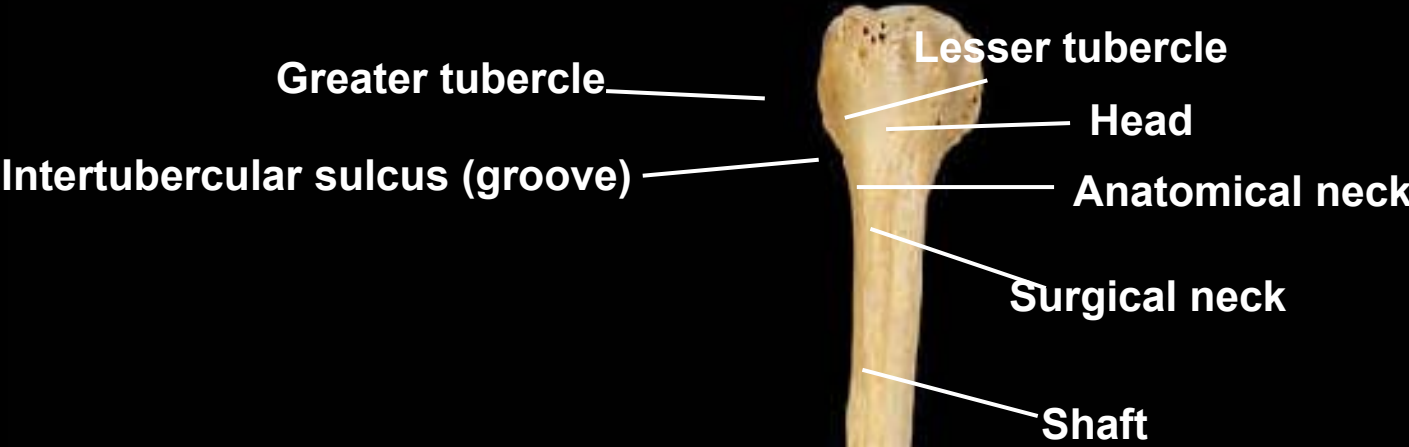
Humerus, anterior view, right side



Radial fossa

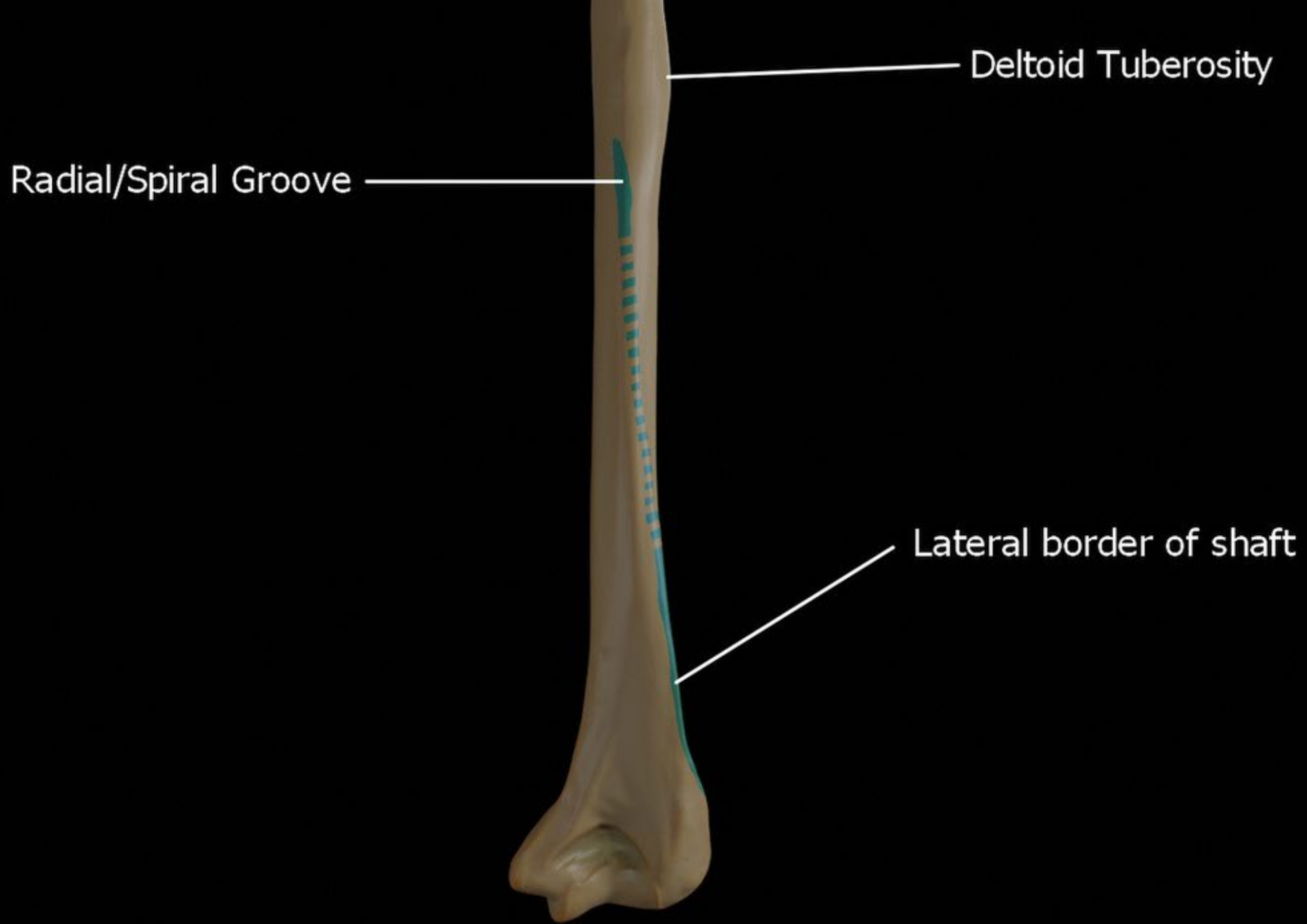


Humerus, anterior view, right side



Deltoid tuberosity

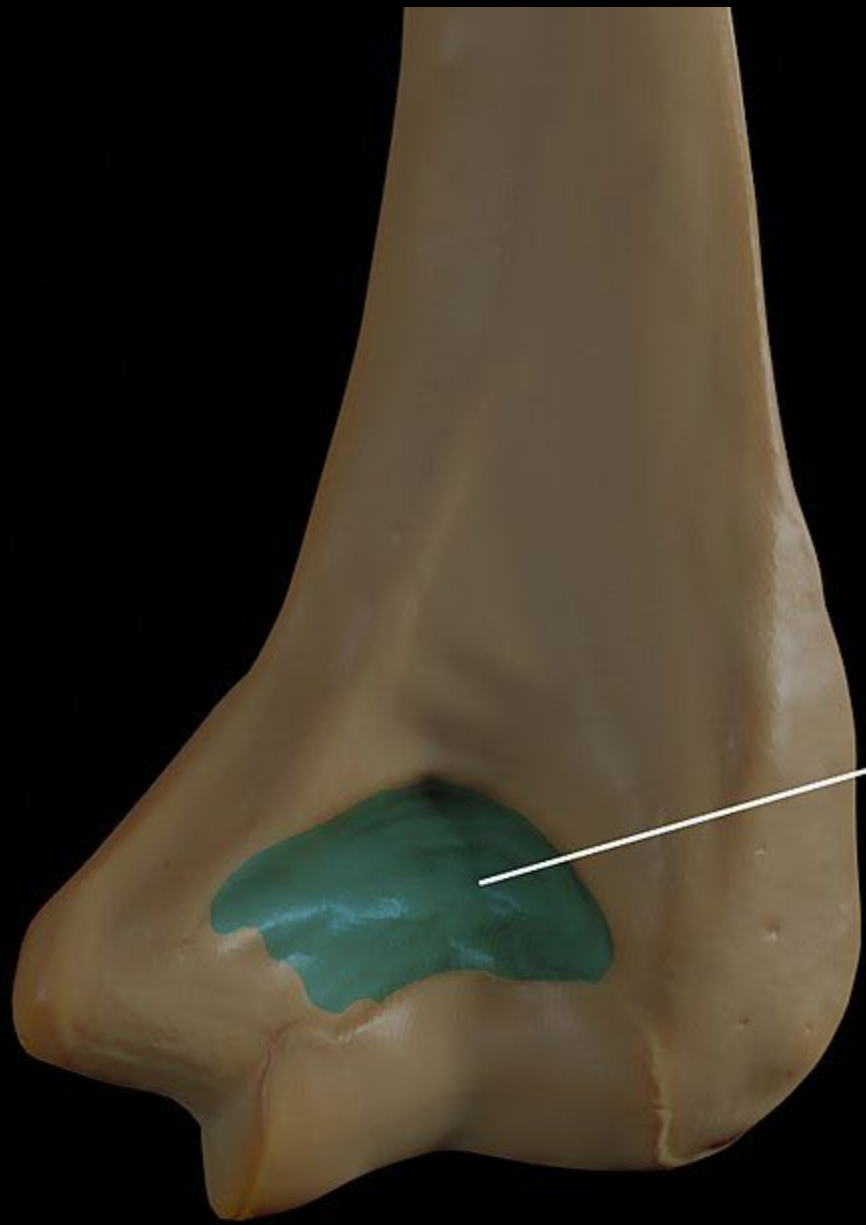



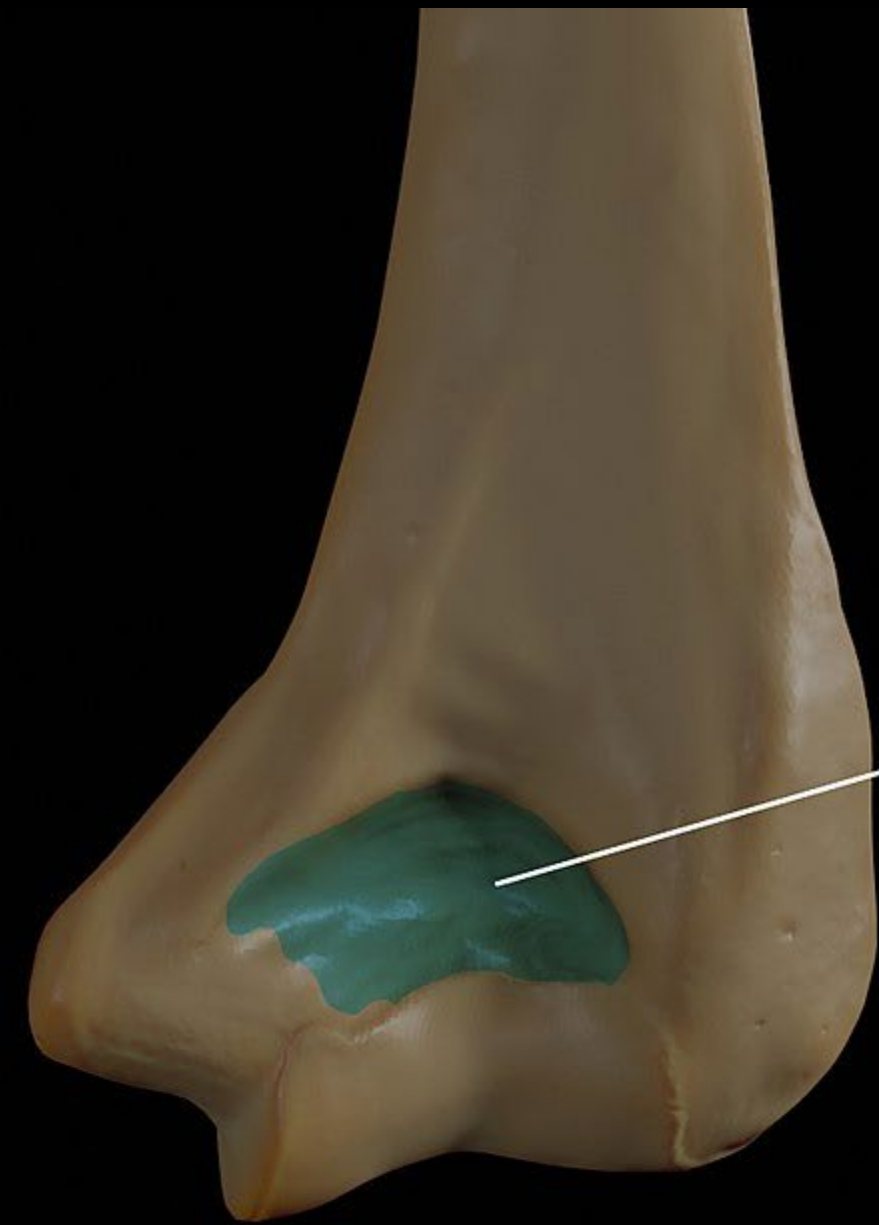Deltoid Tuberosity

Radial/Spiral Groove

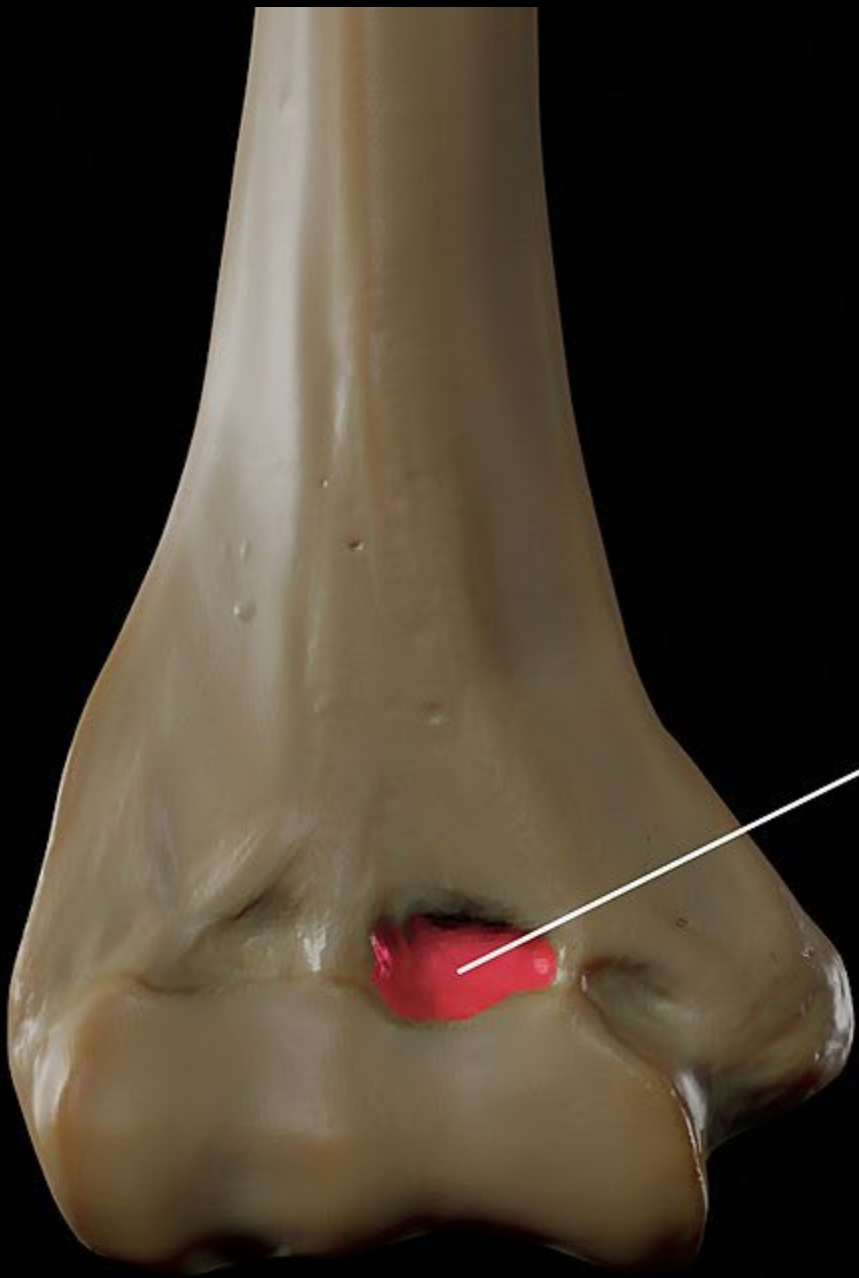
Lateral border of shaft



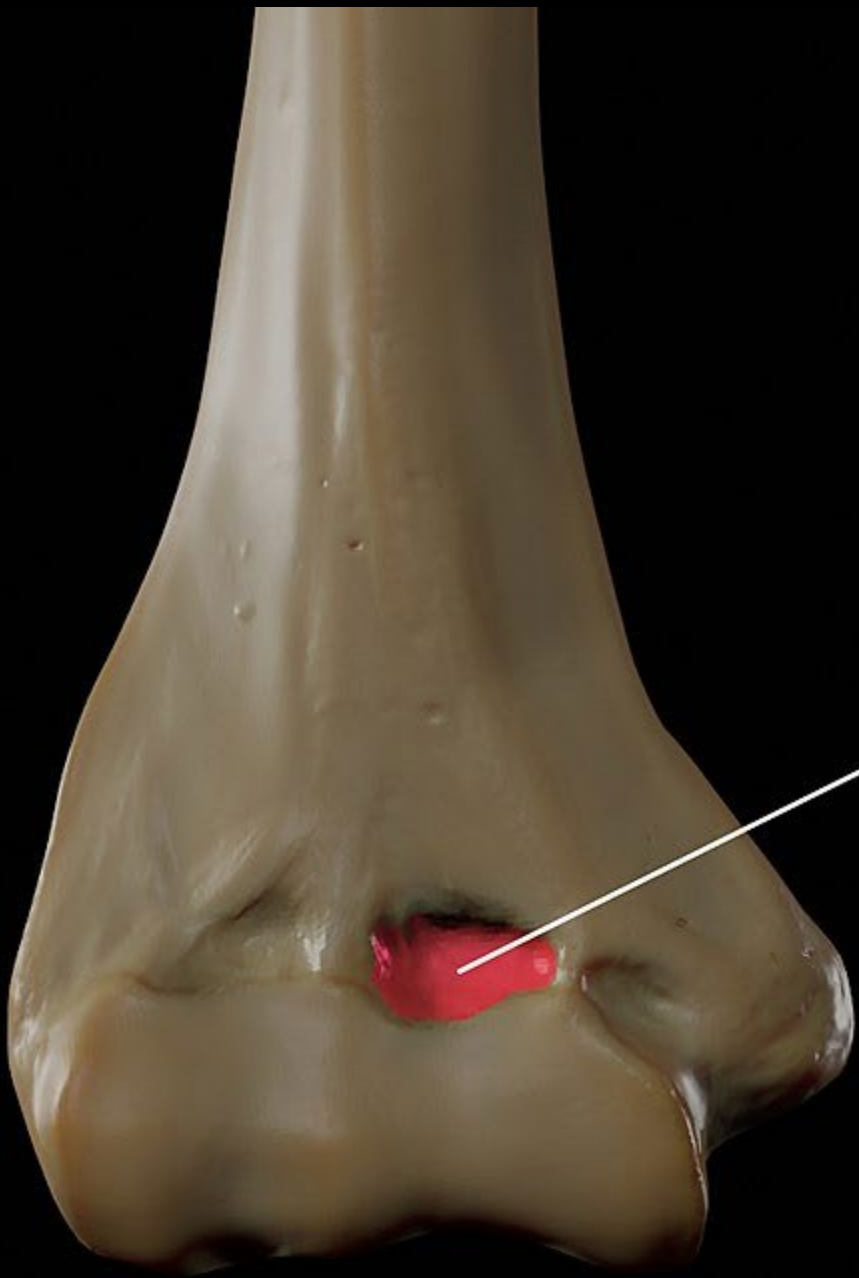
?



Olecranon Fossa

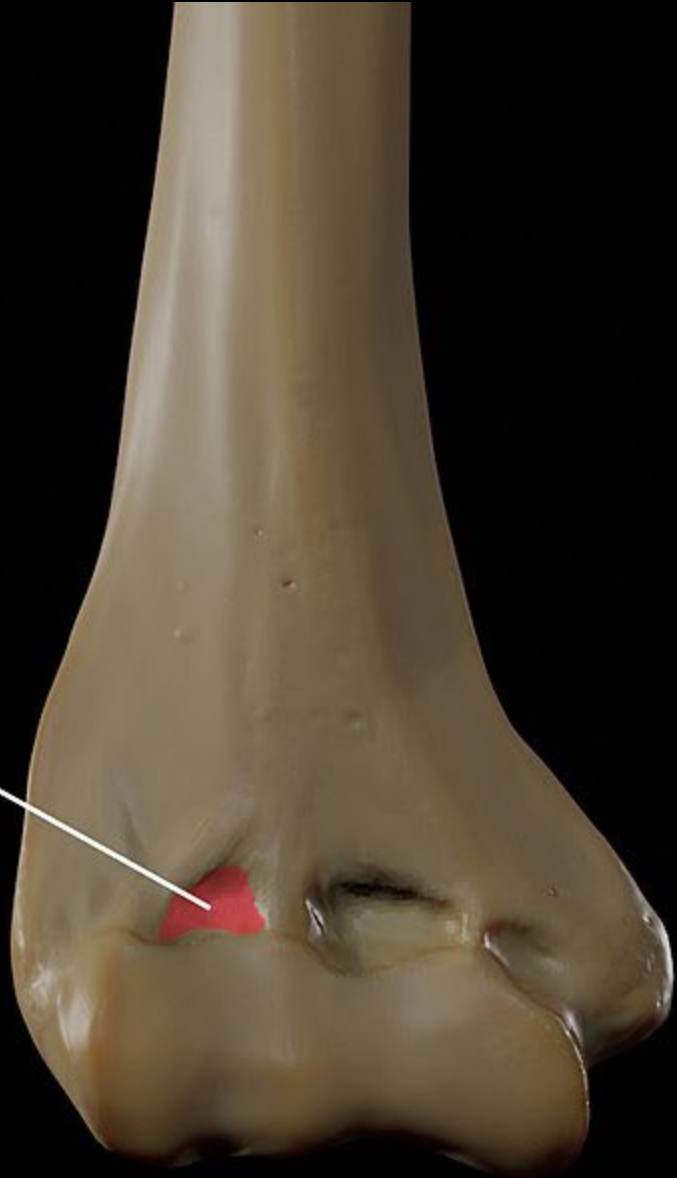


?

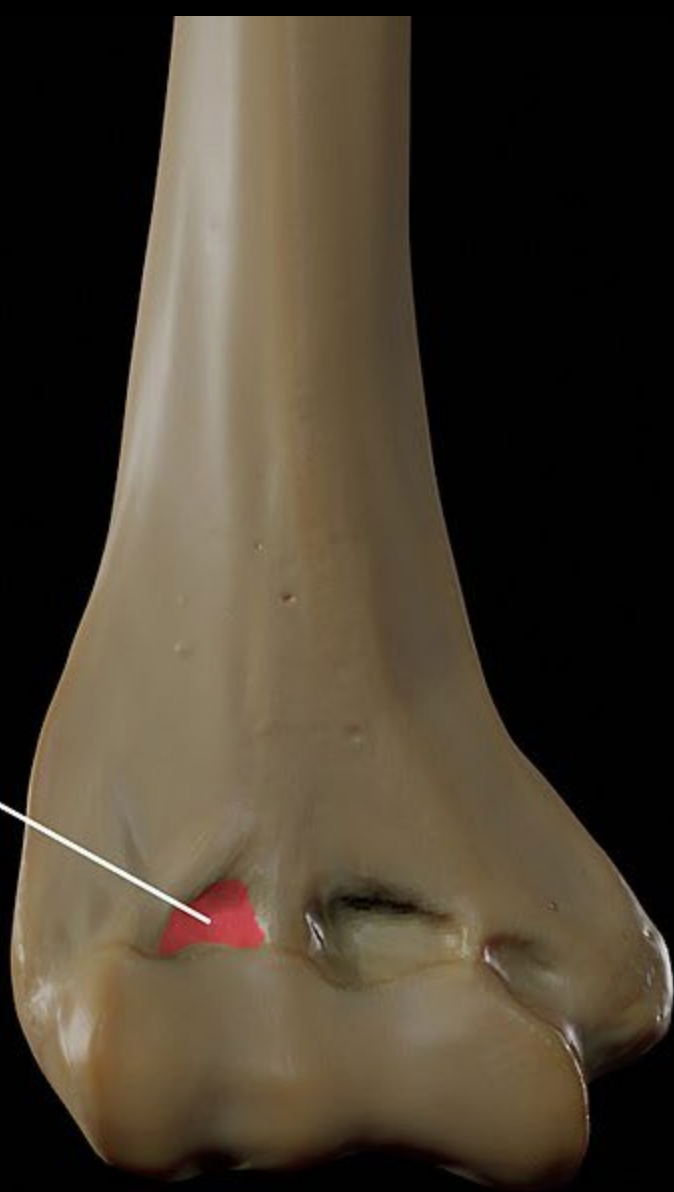


Coronoid Fossa

?



Radial Fossa



?

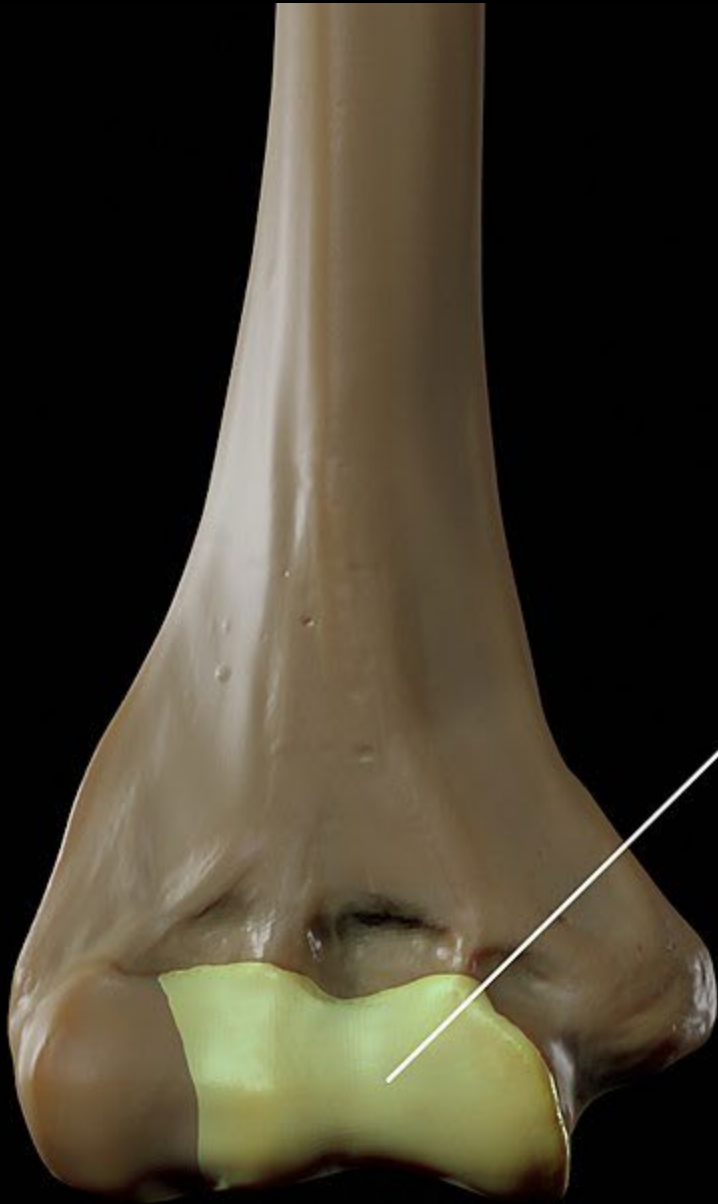

?

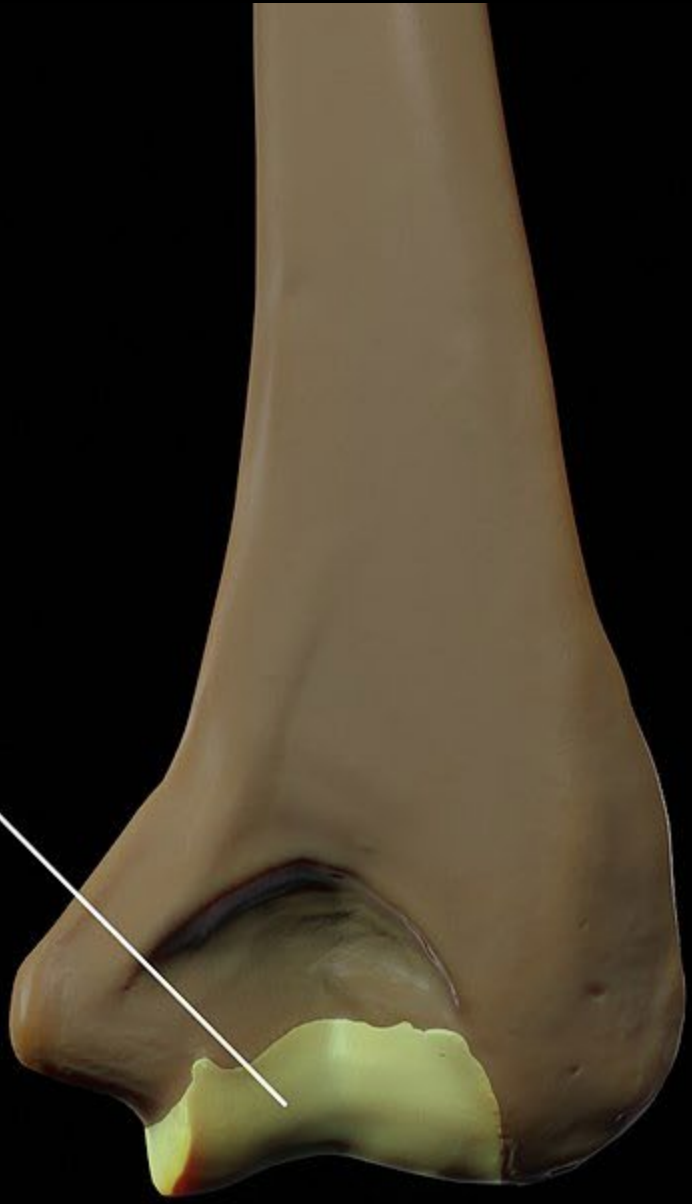Capitulum

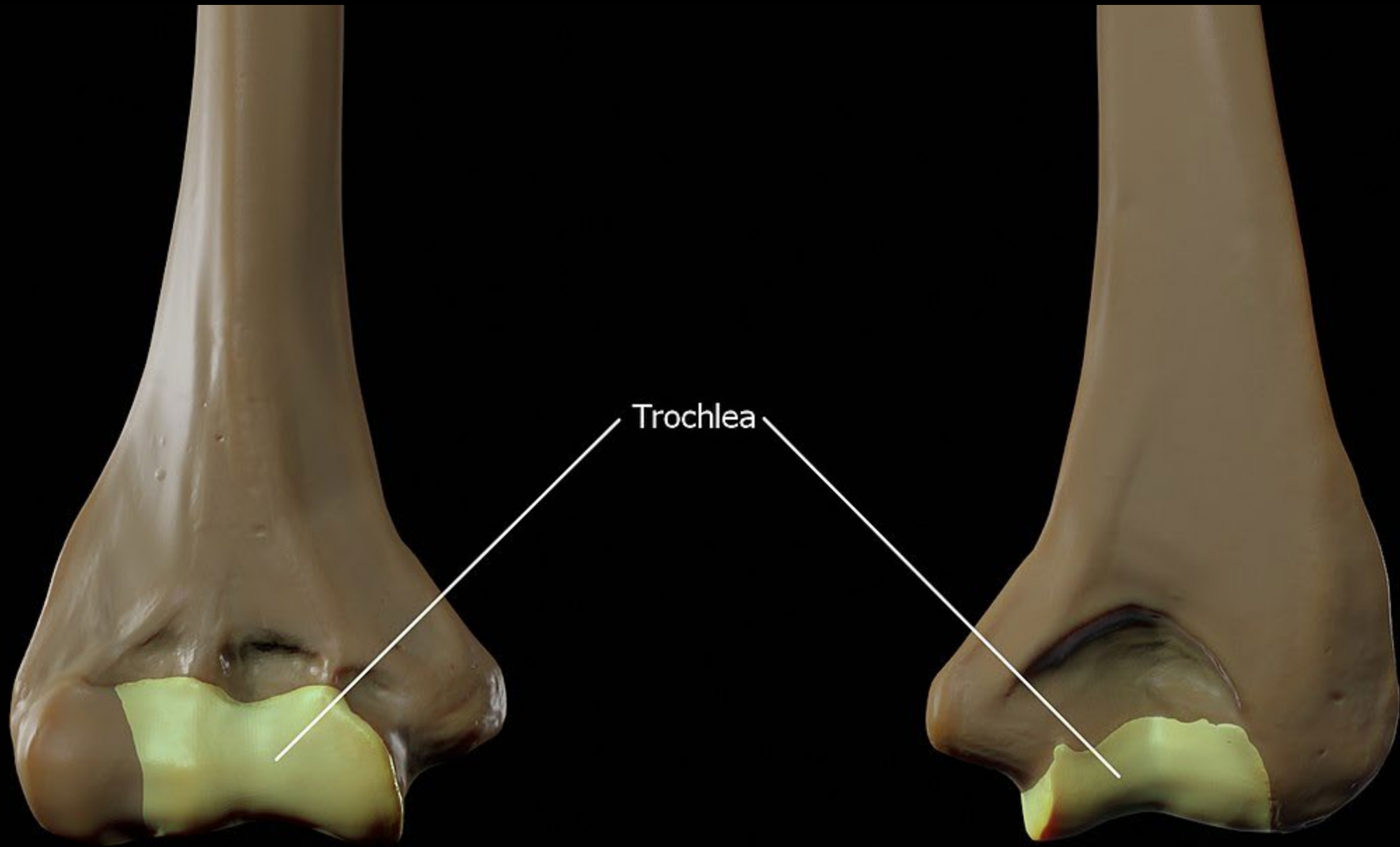
Trochlea





?





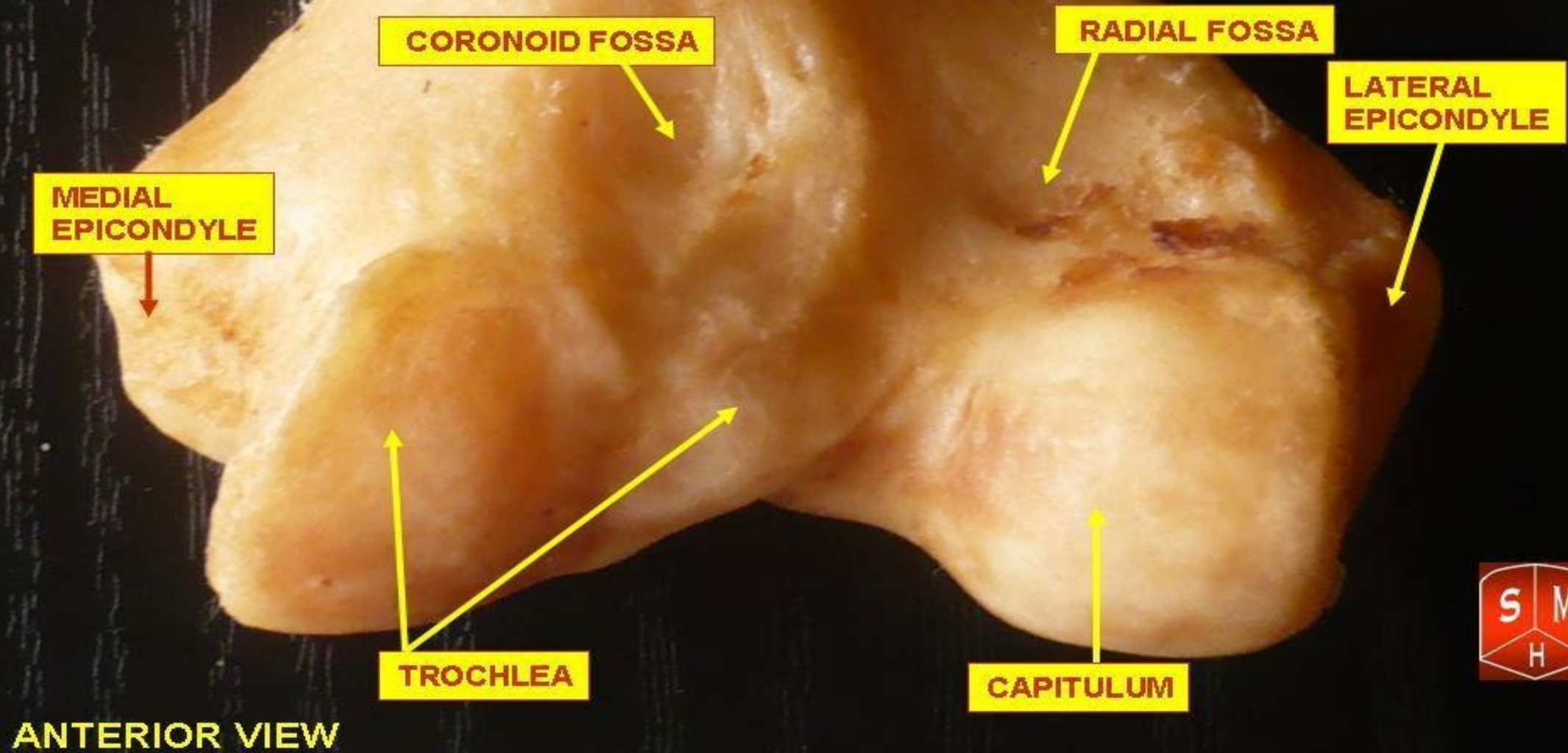


Lateral Epicondyle

Medial Epicondyle



HUMERUS



HUMERUS

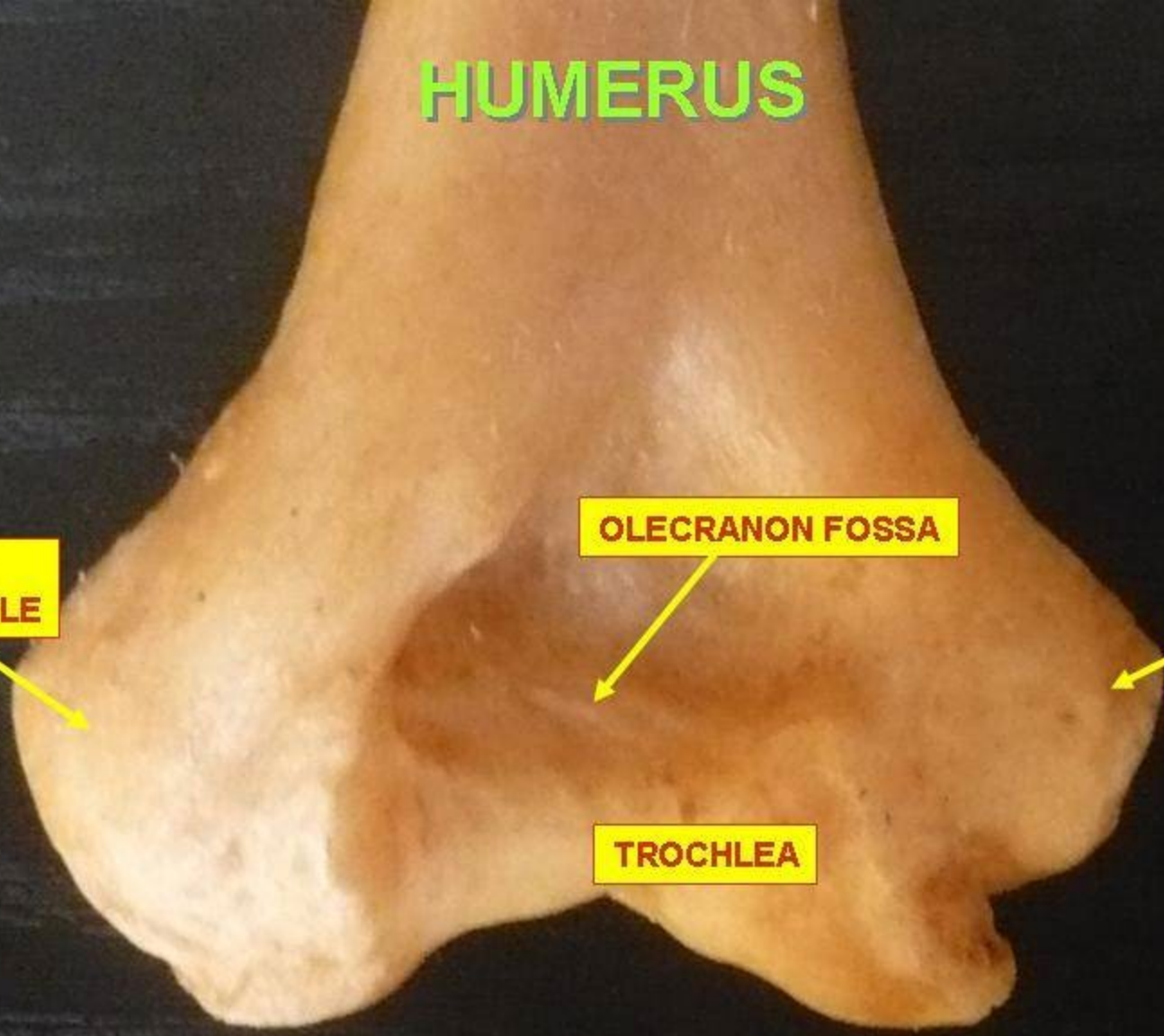
LATERAL
EPICONDYLE

OLECRANON FOSSA

MEDIAL
EPICONDYLE

TROCHLEA

POSTERIOR VIEW



GREATER TUBERCLE

HEAD OF HUMERUS

ANATOMICAL NECK

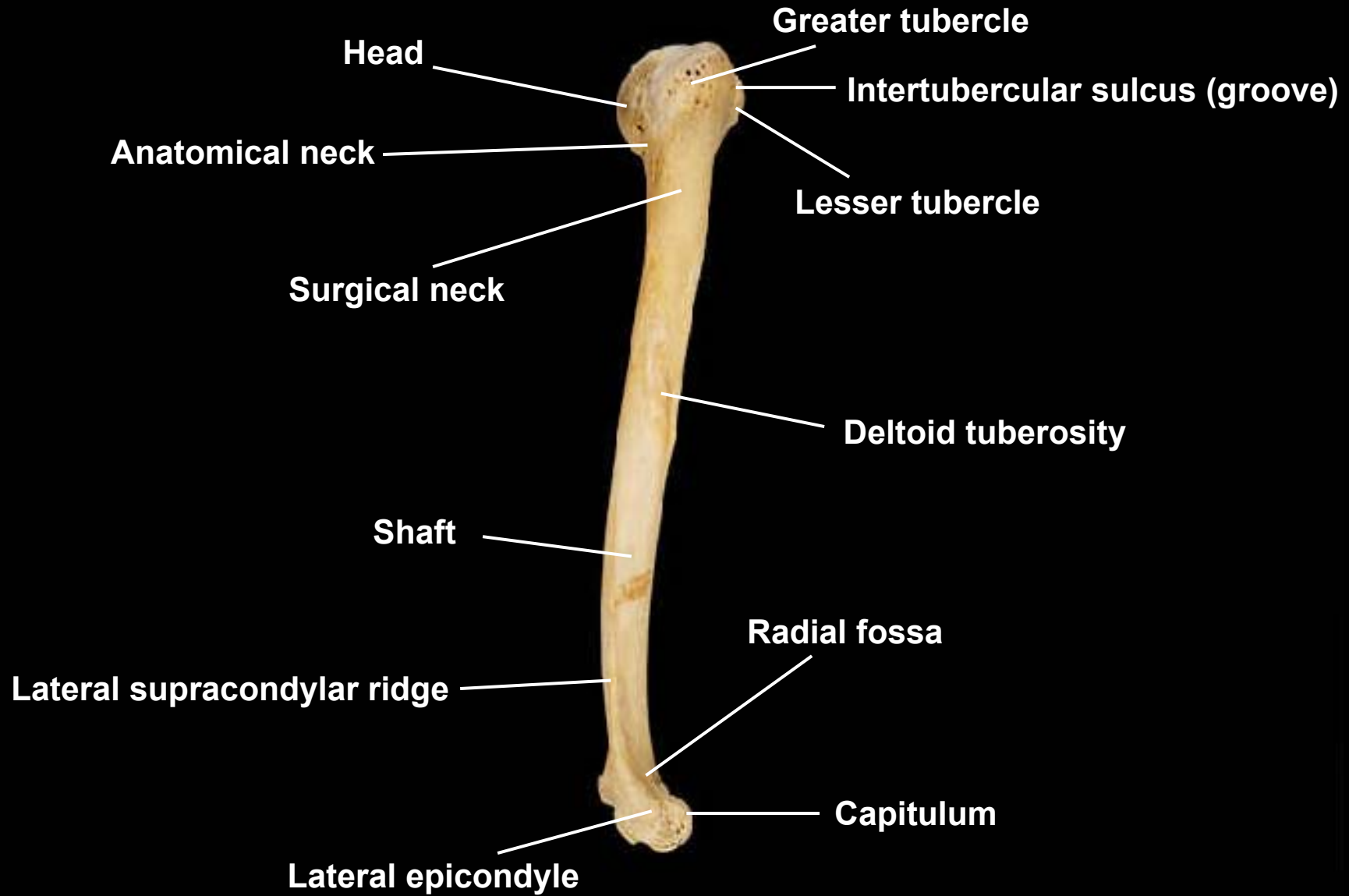
SURGICAL NECK

HUMERUS

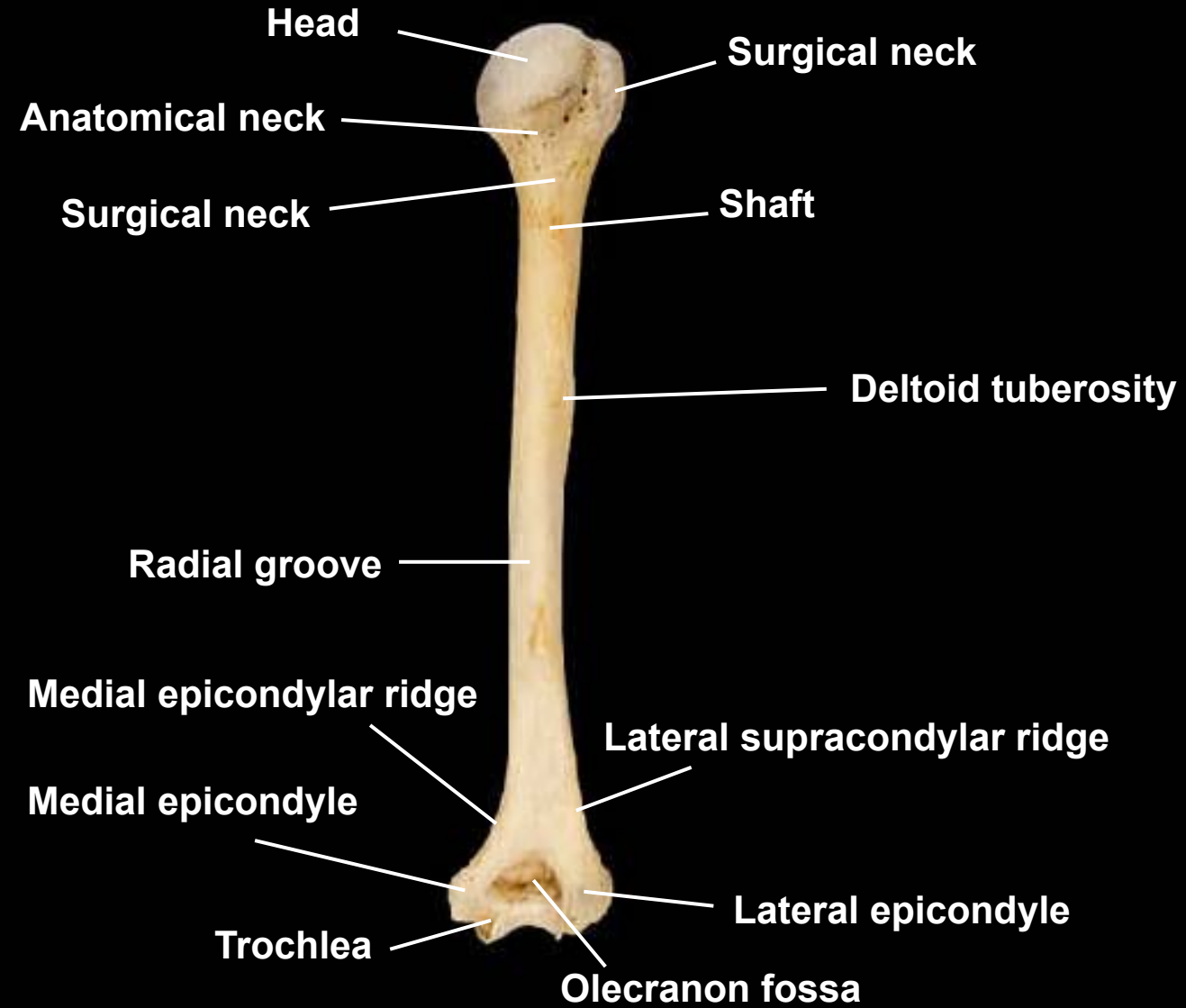
POSTERIOR VIEW



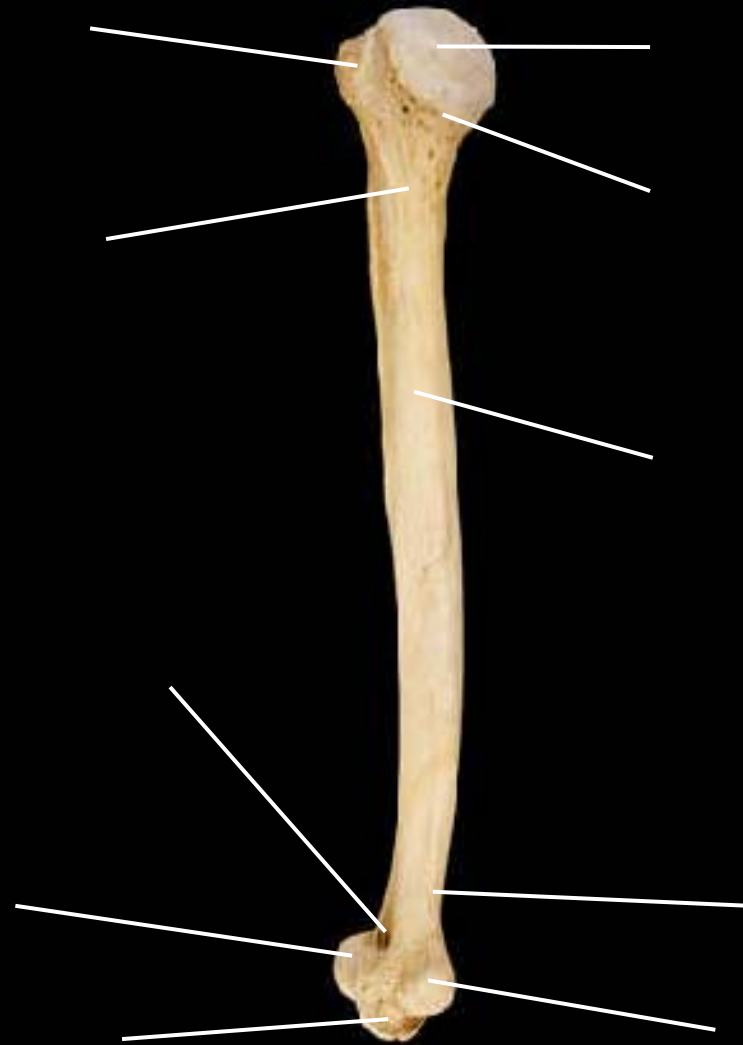Humerus, lateral view, right side



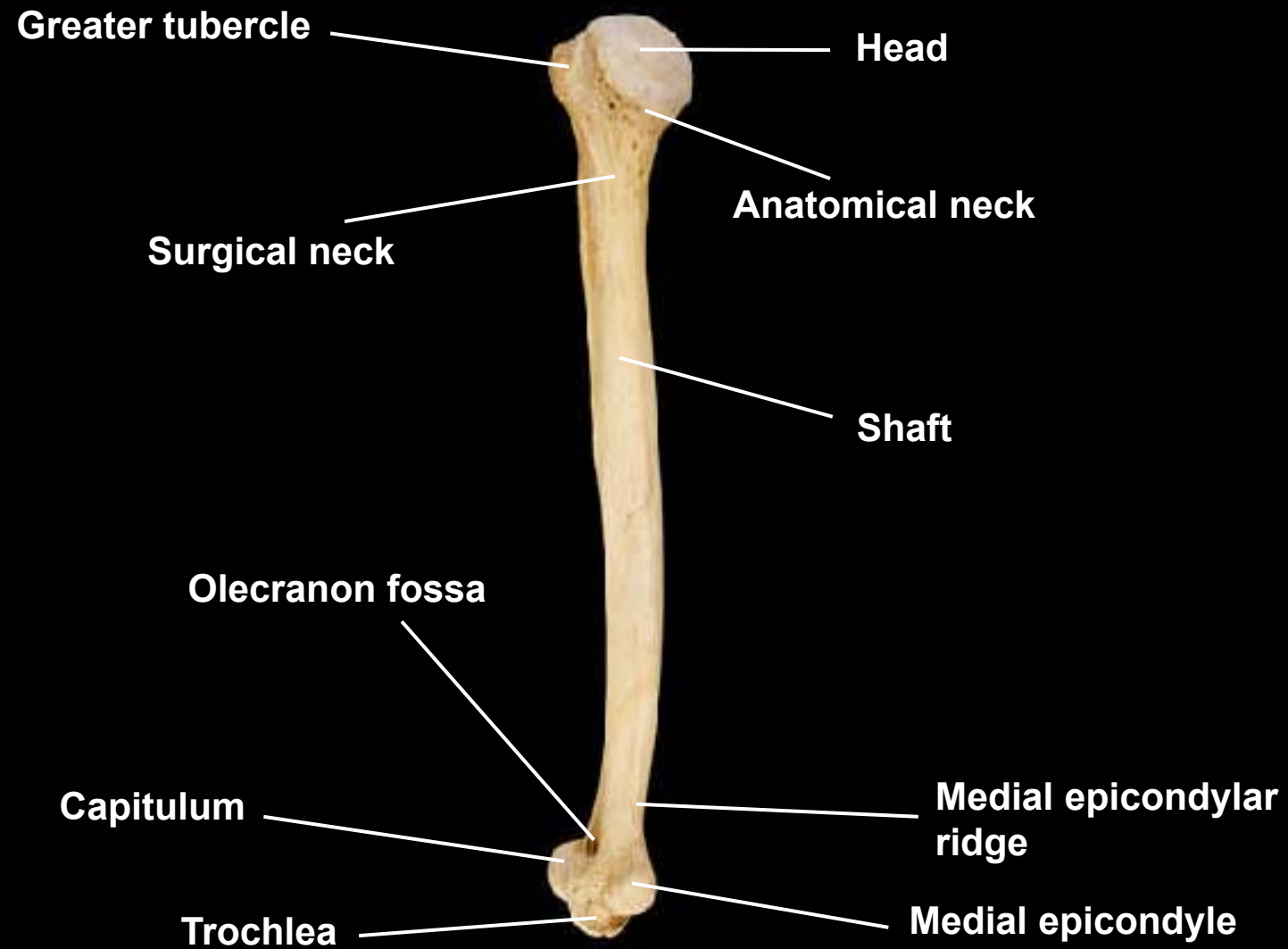
Humerus, posterior view, right side

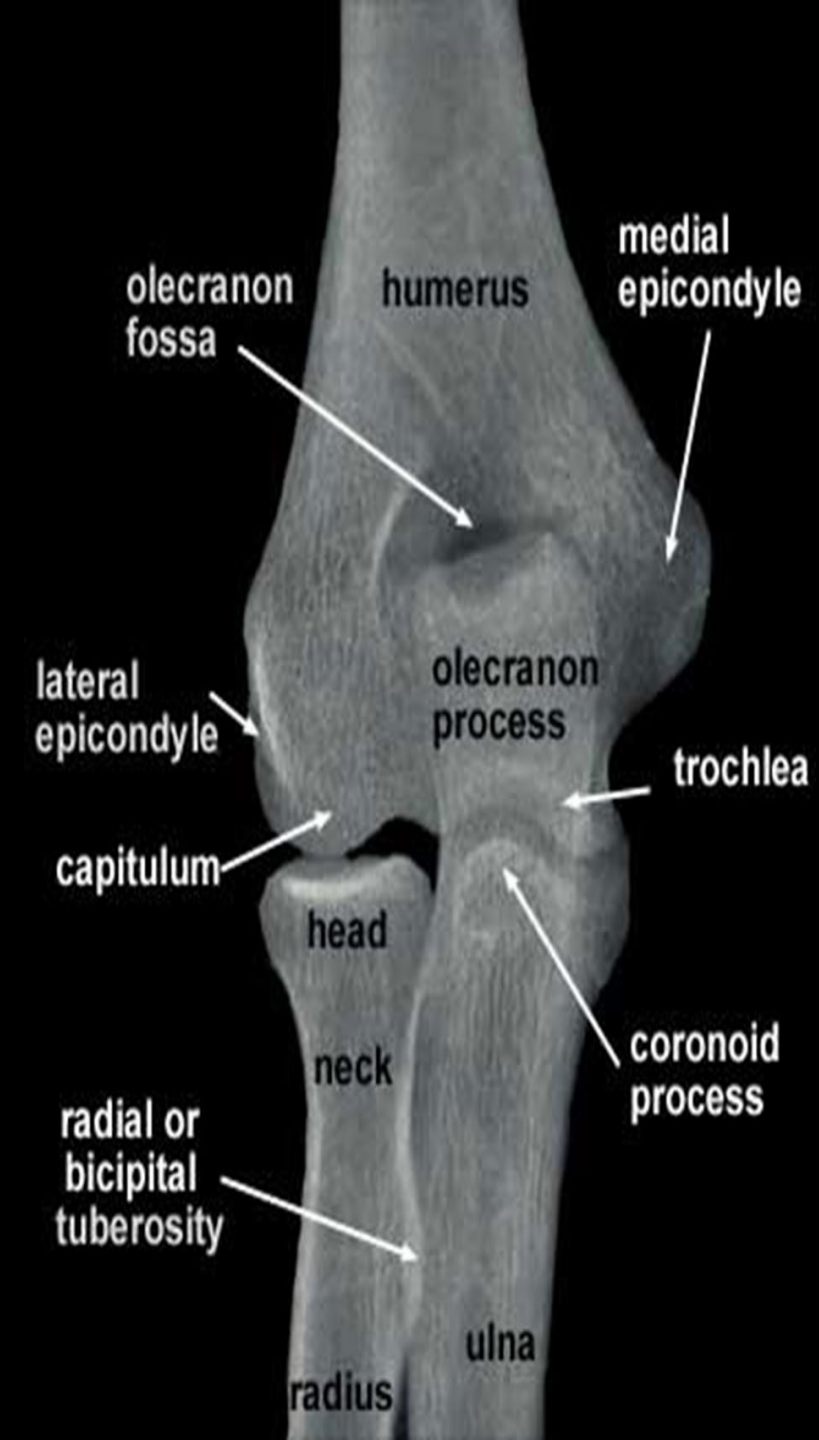

Humerus, medial view, right side



Humerus, medial view, right side



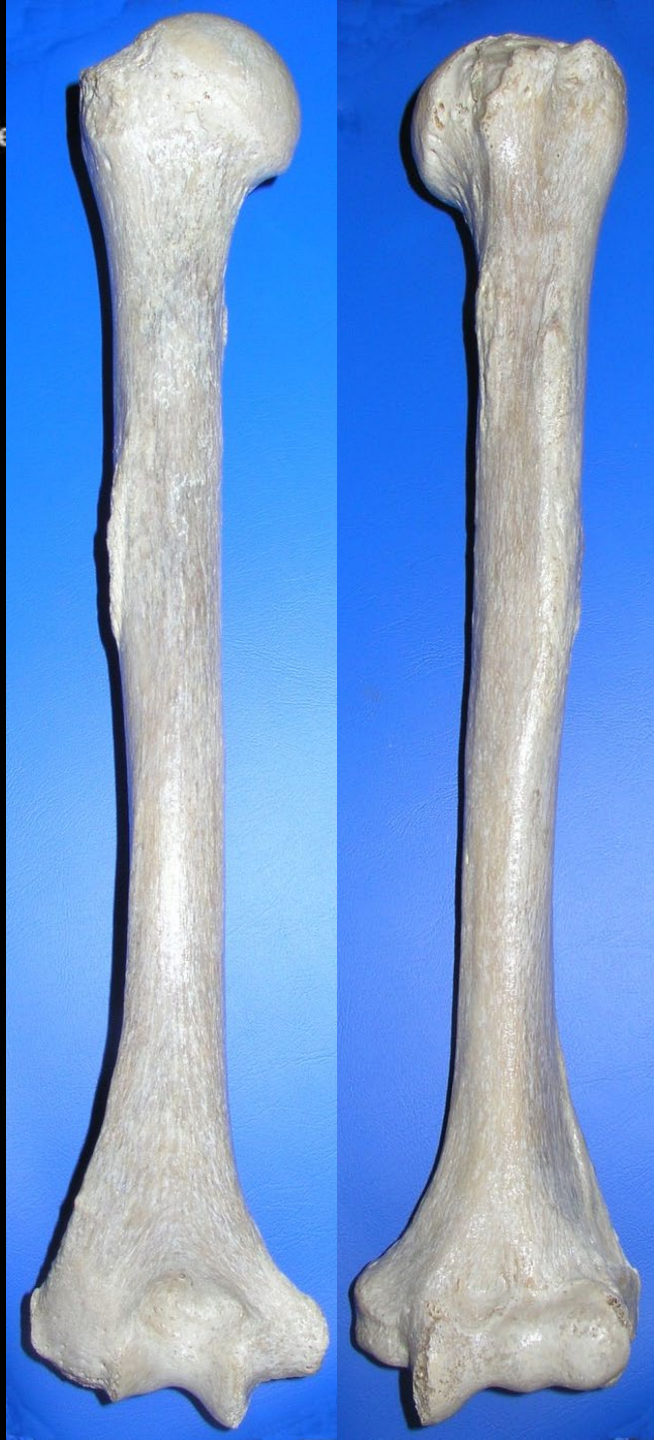

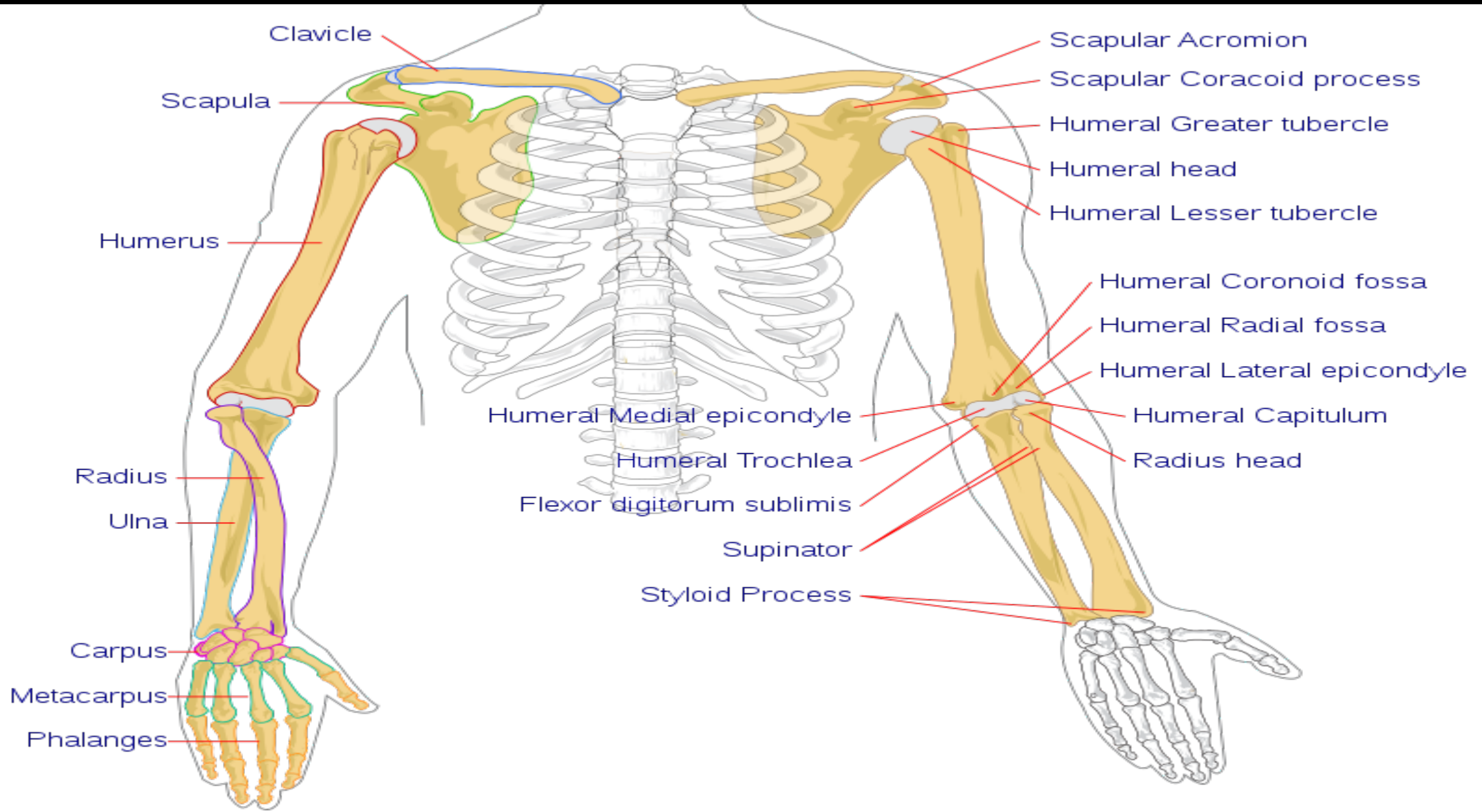
Humerus, anterior view



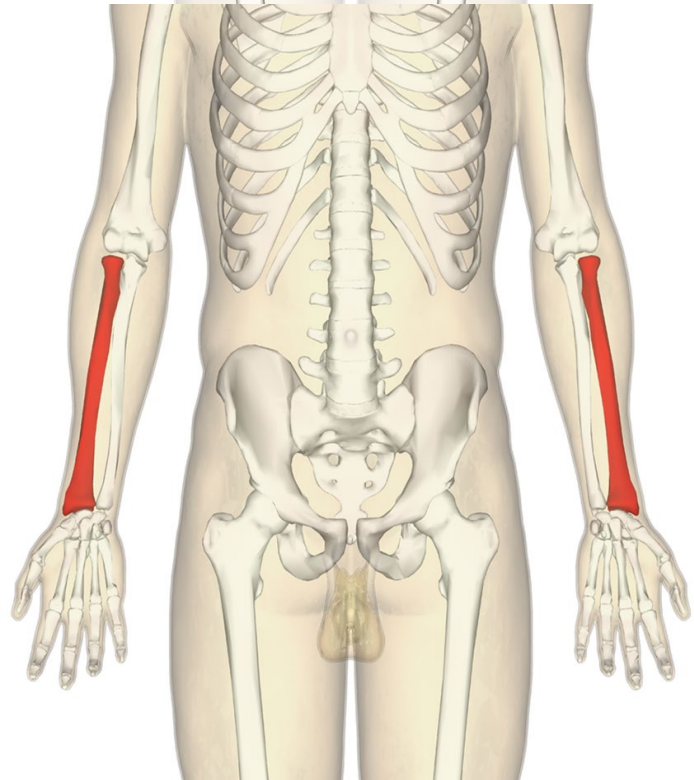
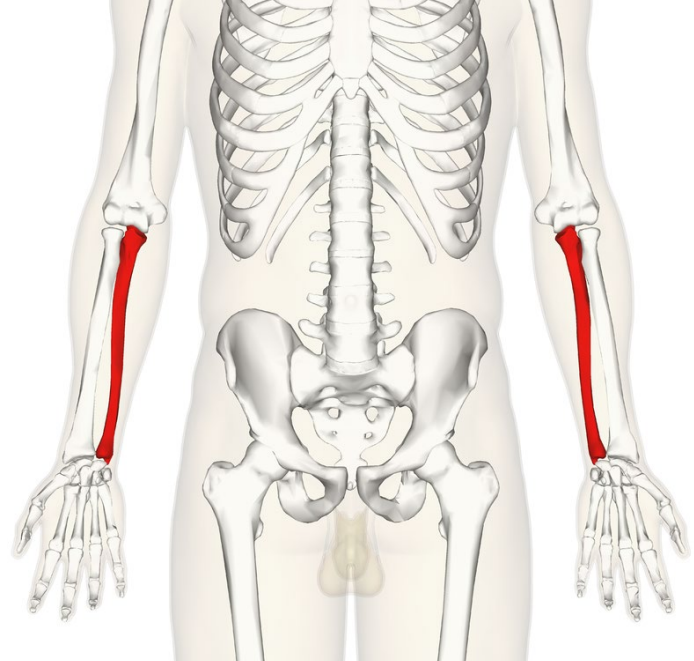
Capitulum
Medial epicondyle

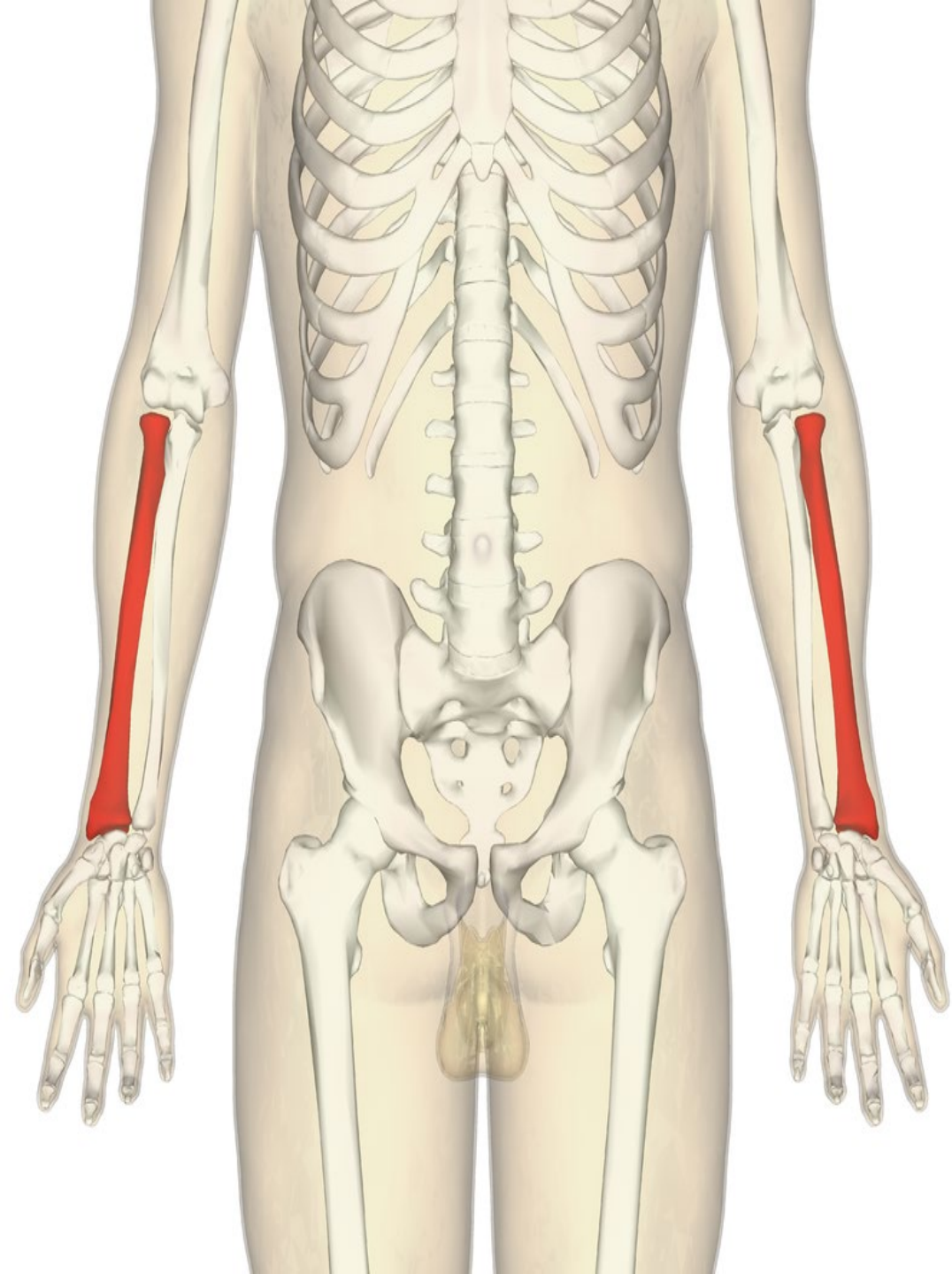
This block contains two labels with arrows pointing to the distal end of the humerus in the photograph. The label 'Capitulum' points to the small, rounded articular surface on the lateral side. The label 'Medial epicondyle' points to the larger, more prominent bony projection on the medial side.





What these two bones named?


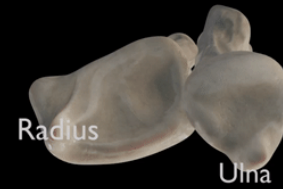



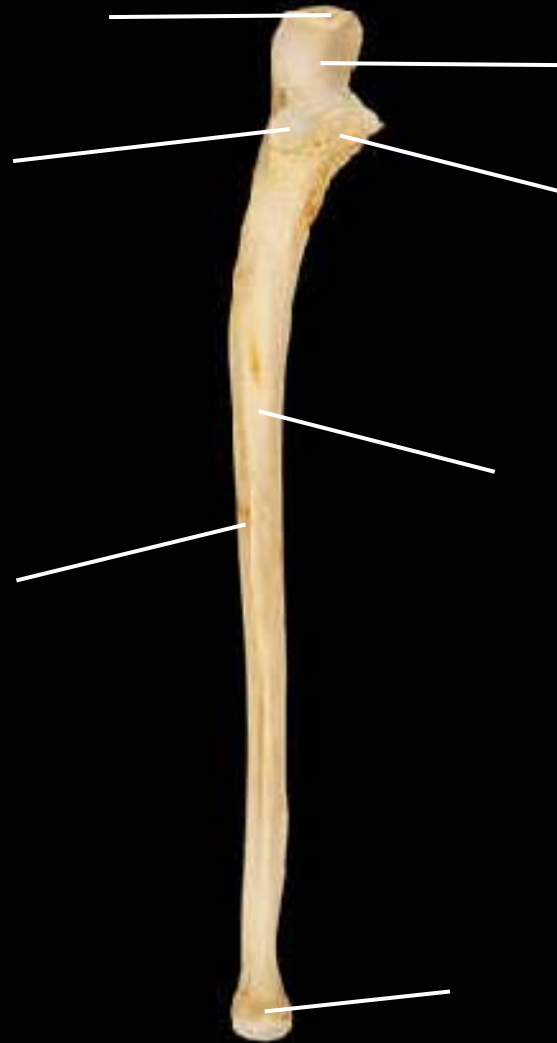
Ulna & radius, anterior view, right side



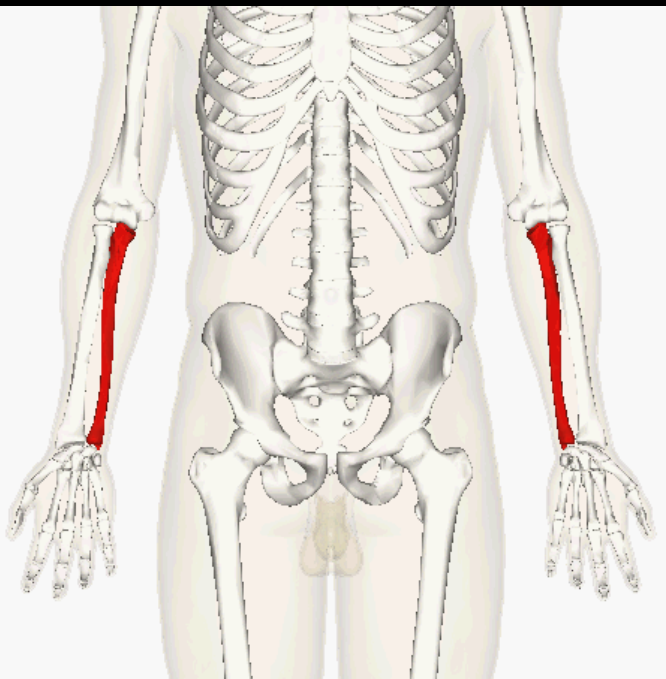
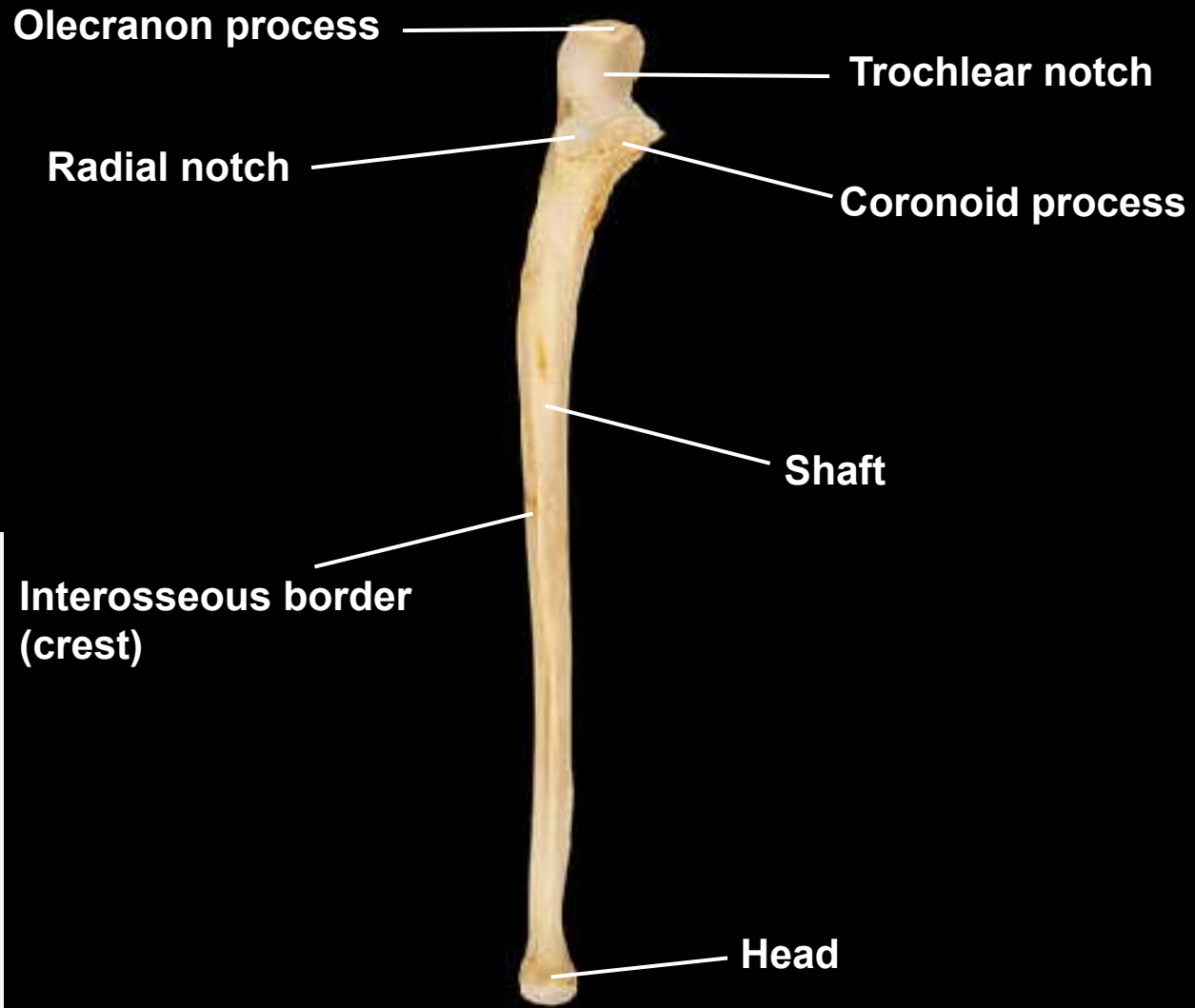
Radial tuberosity



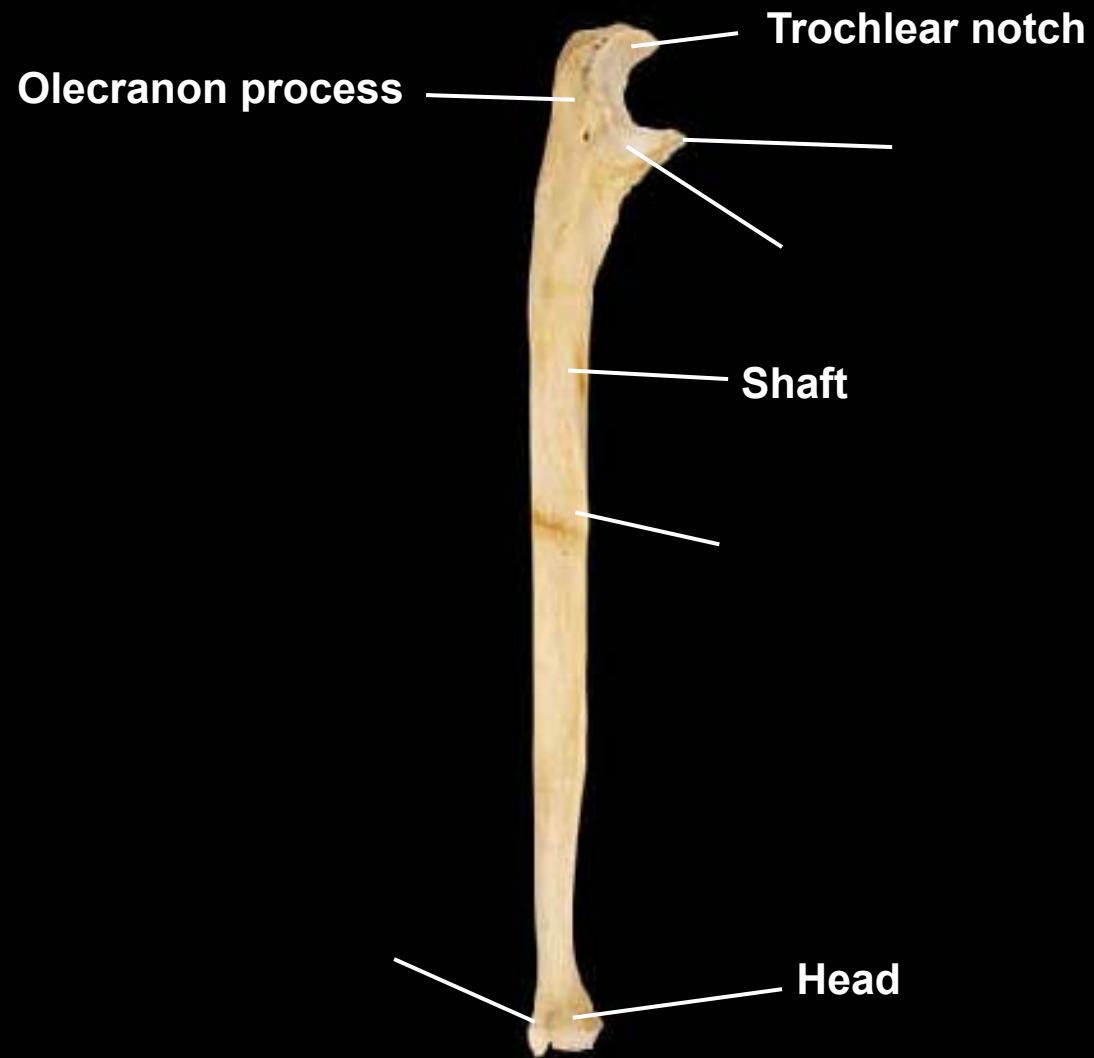
Ulna, anterior view, right side



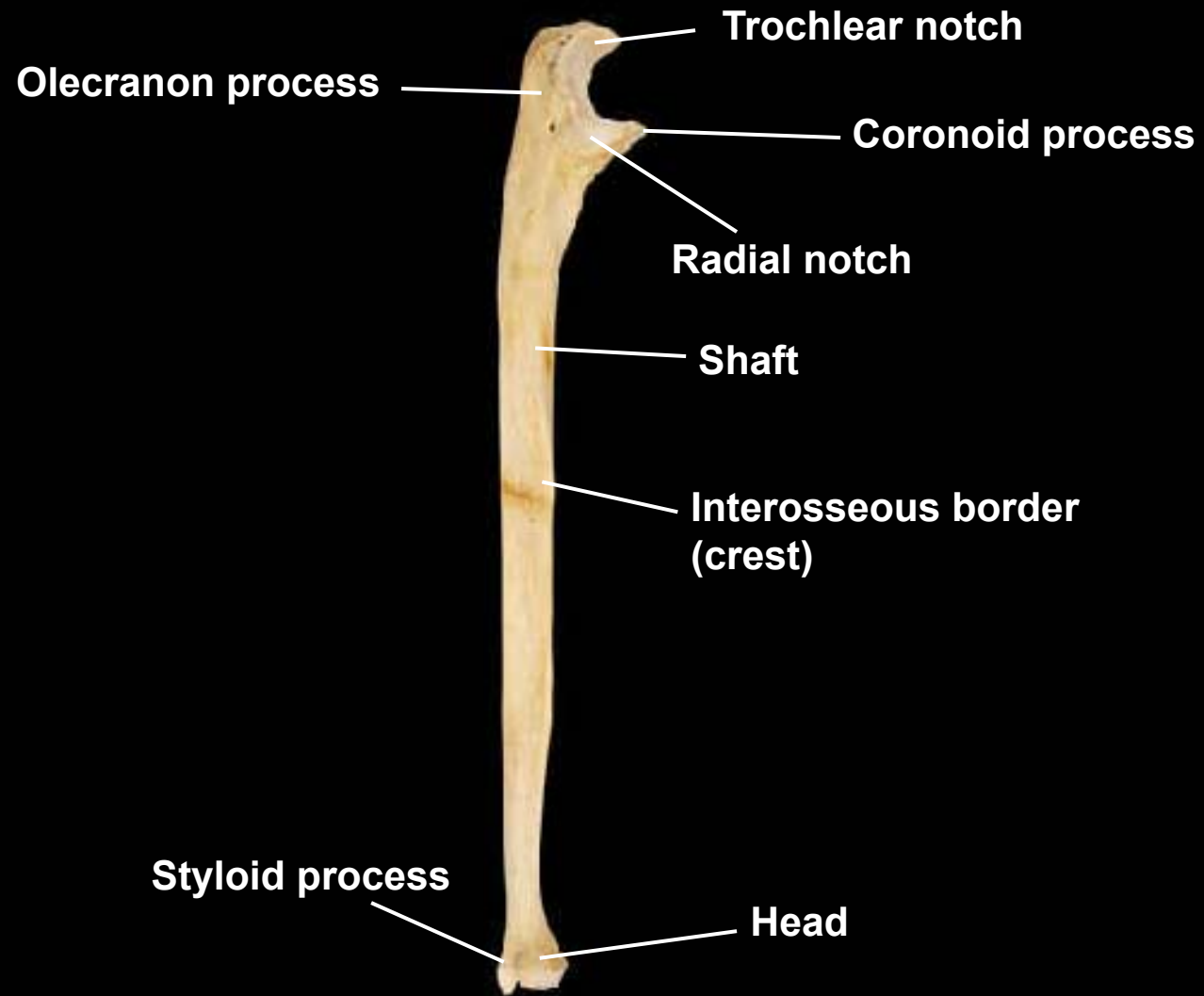
Ulna, anterior view, right side



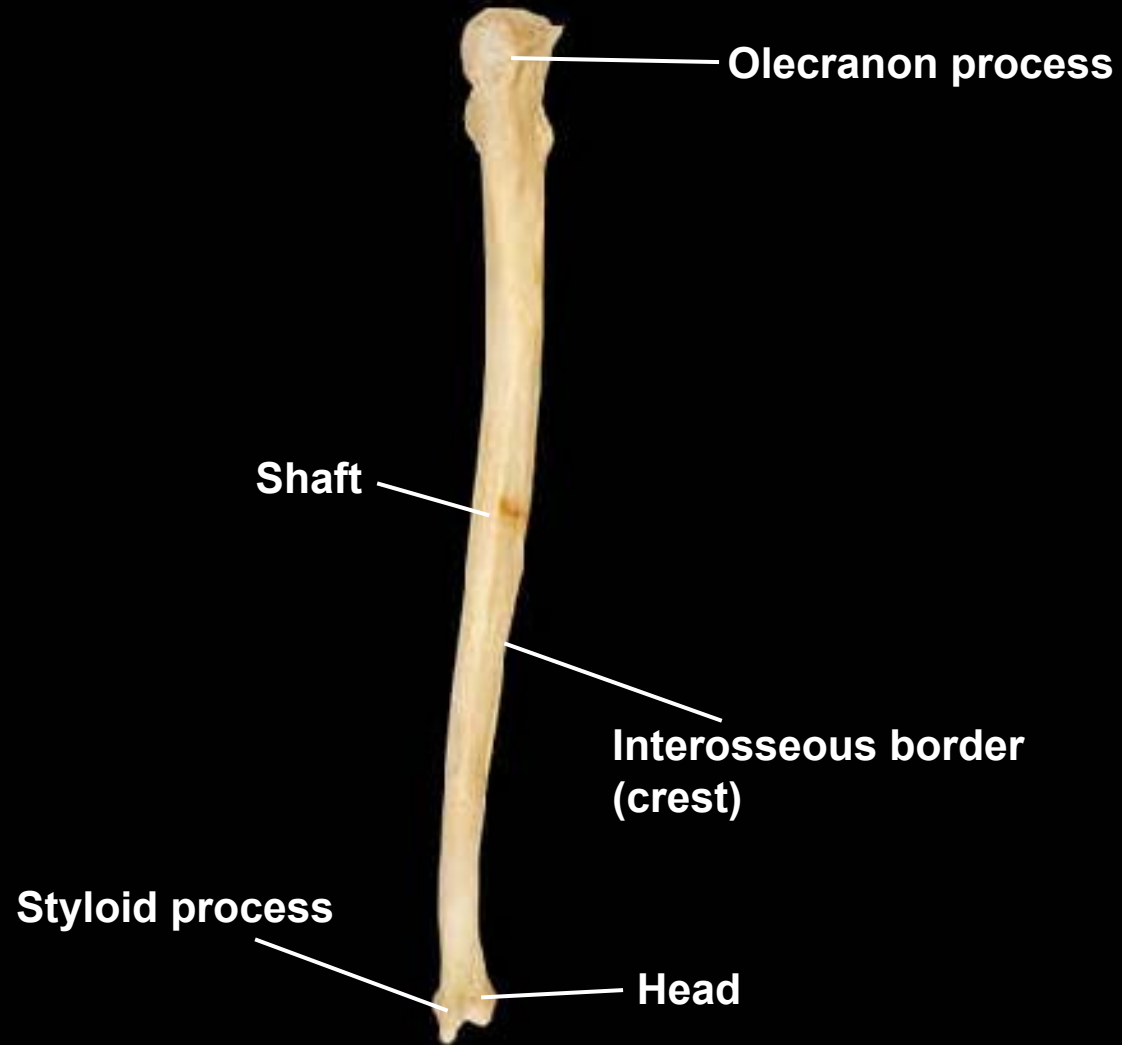
Ulna, lateral view, right side



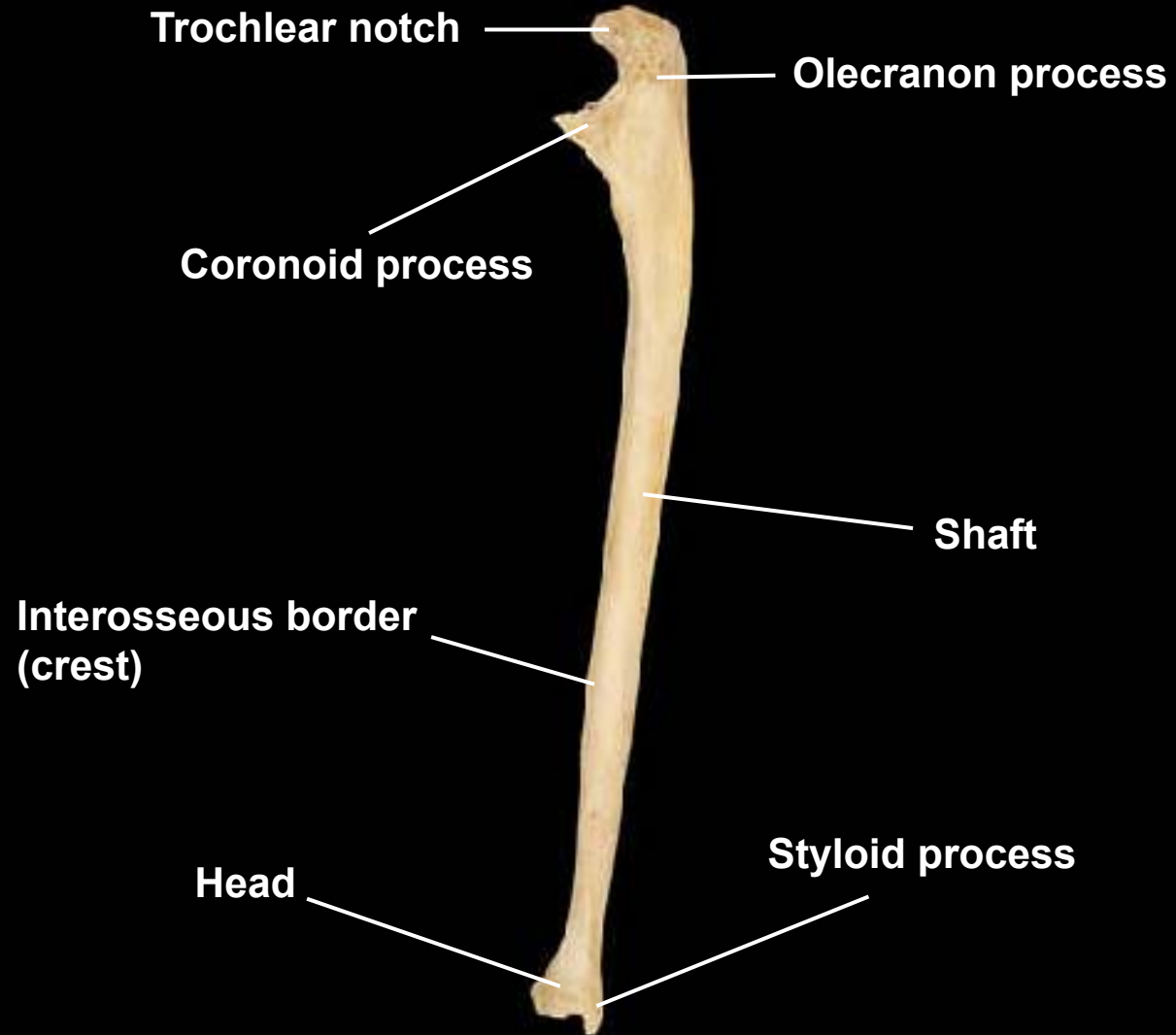
Ulna, lateral view, right side



Ulna, posterior view, right side

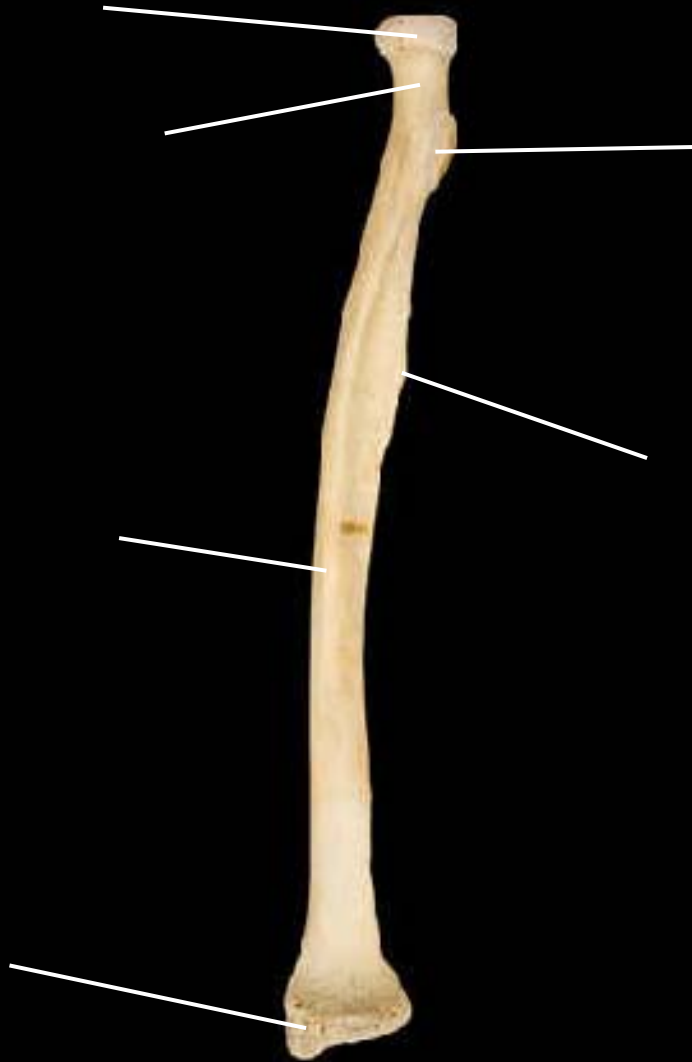

Ulna, medial view, right side



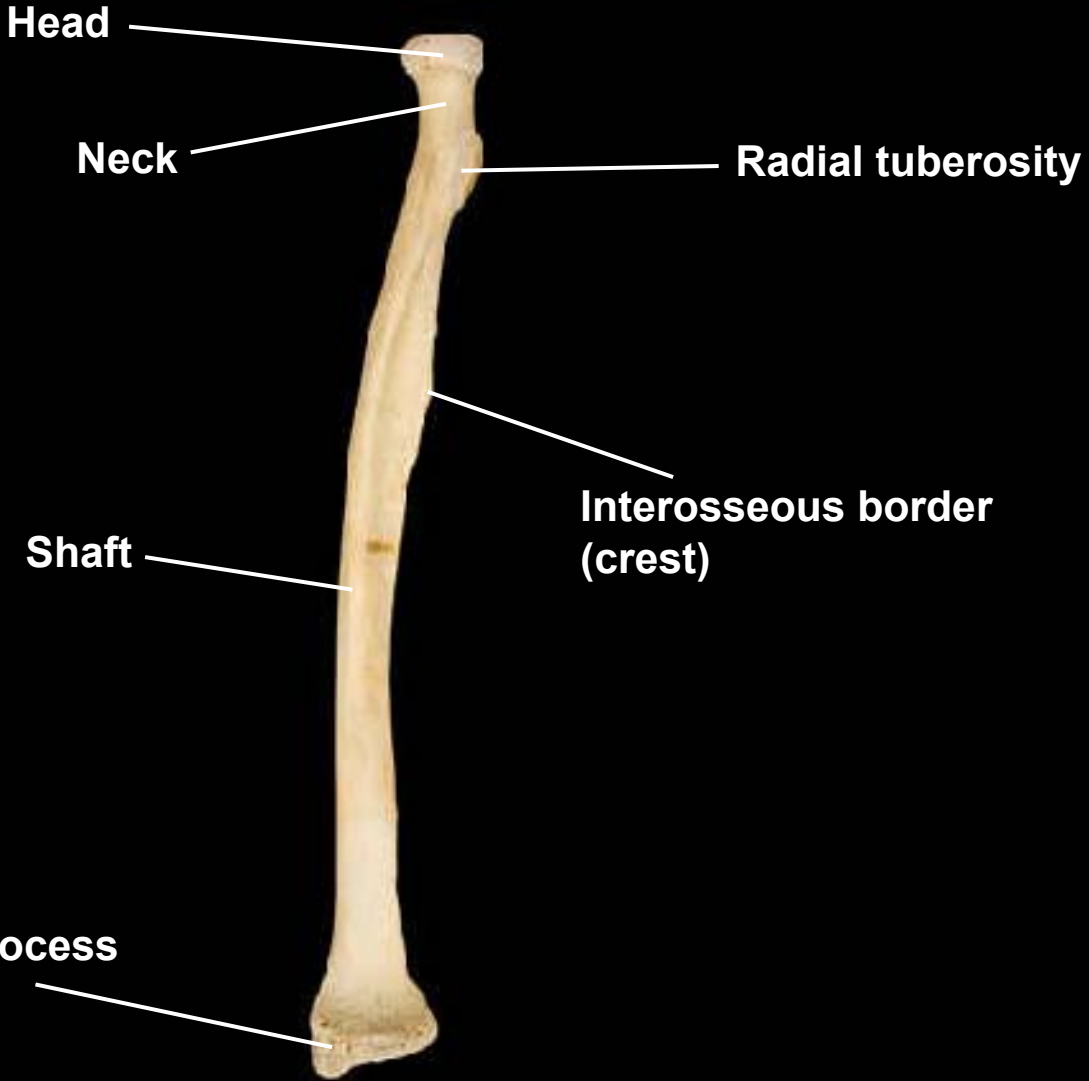

Radius, anterior view, right side



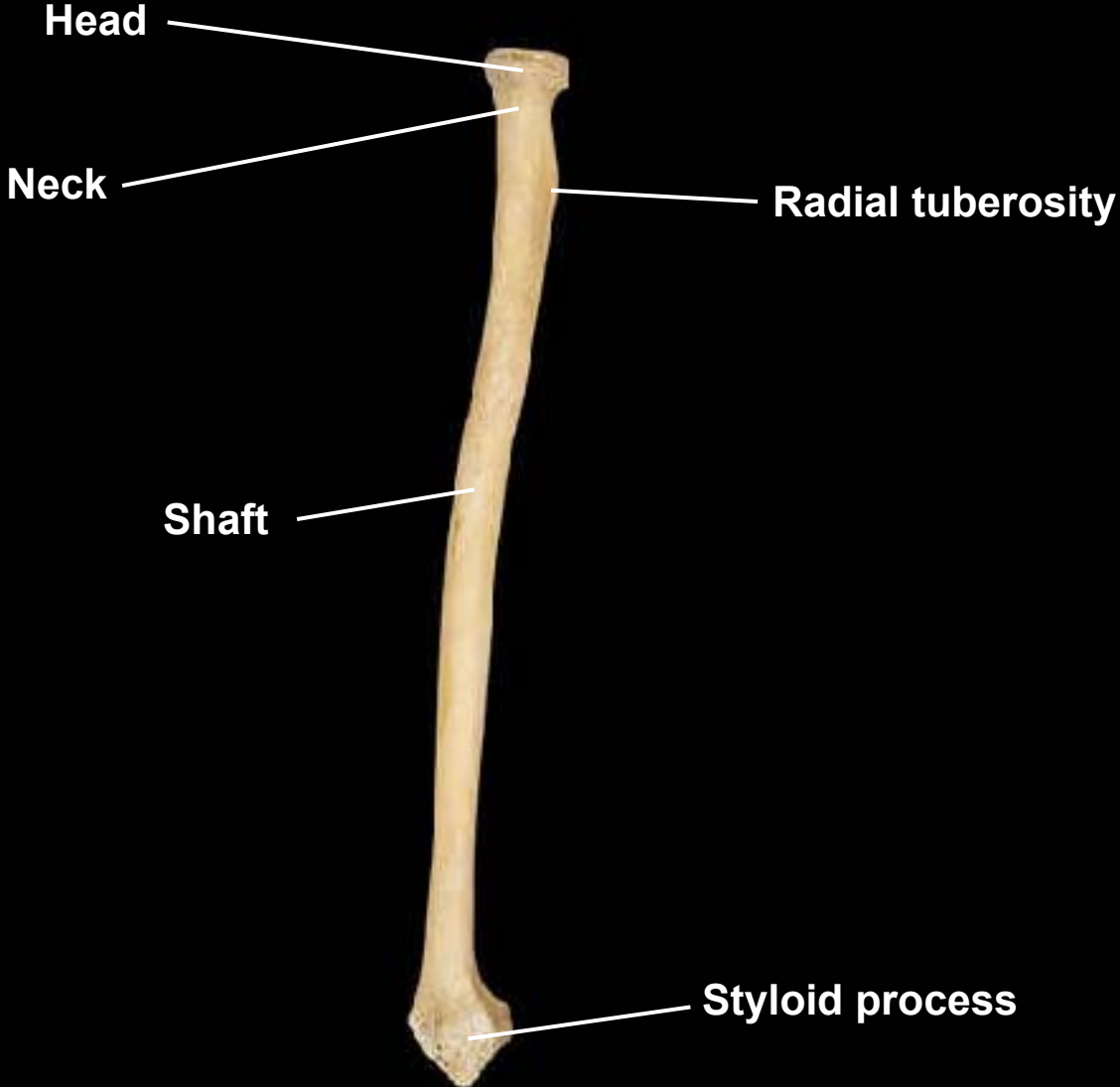


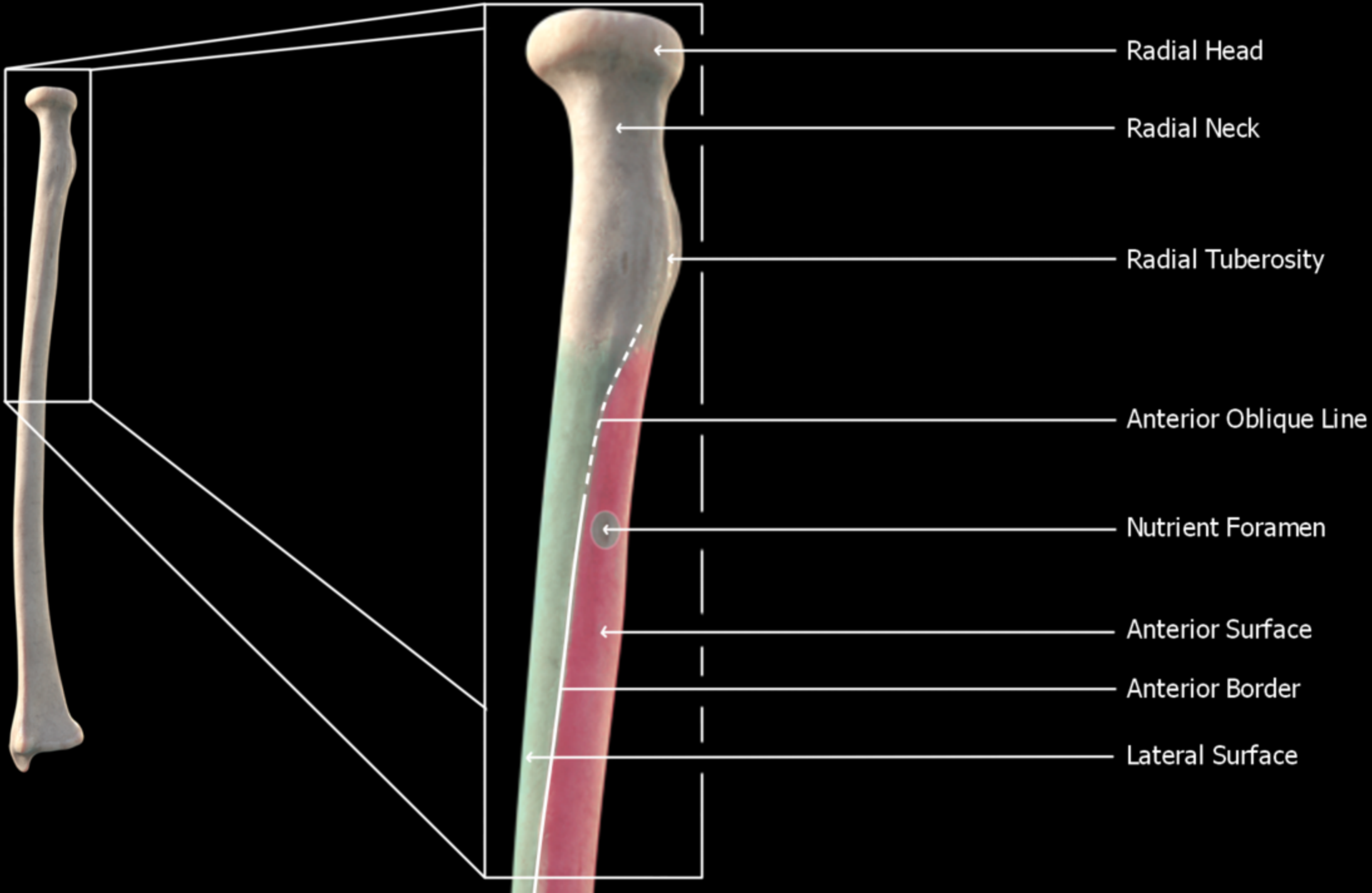
Radius, anterior view, right side

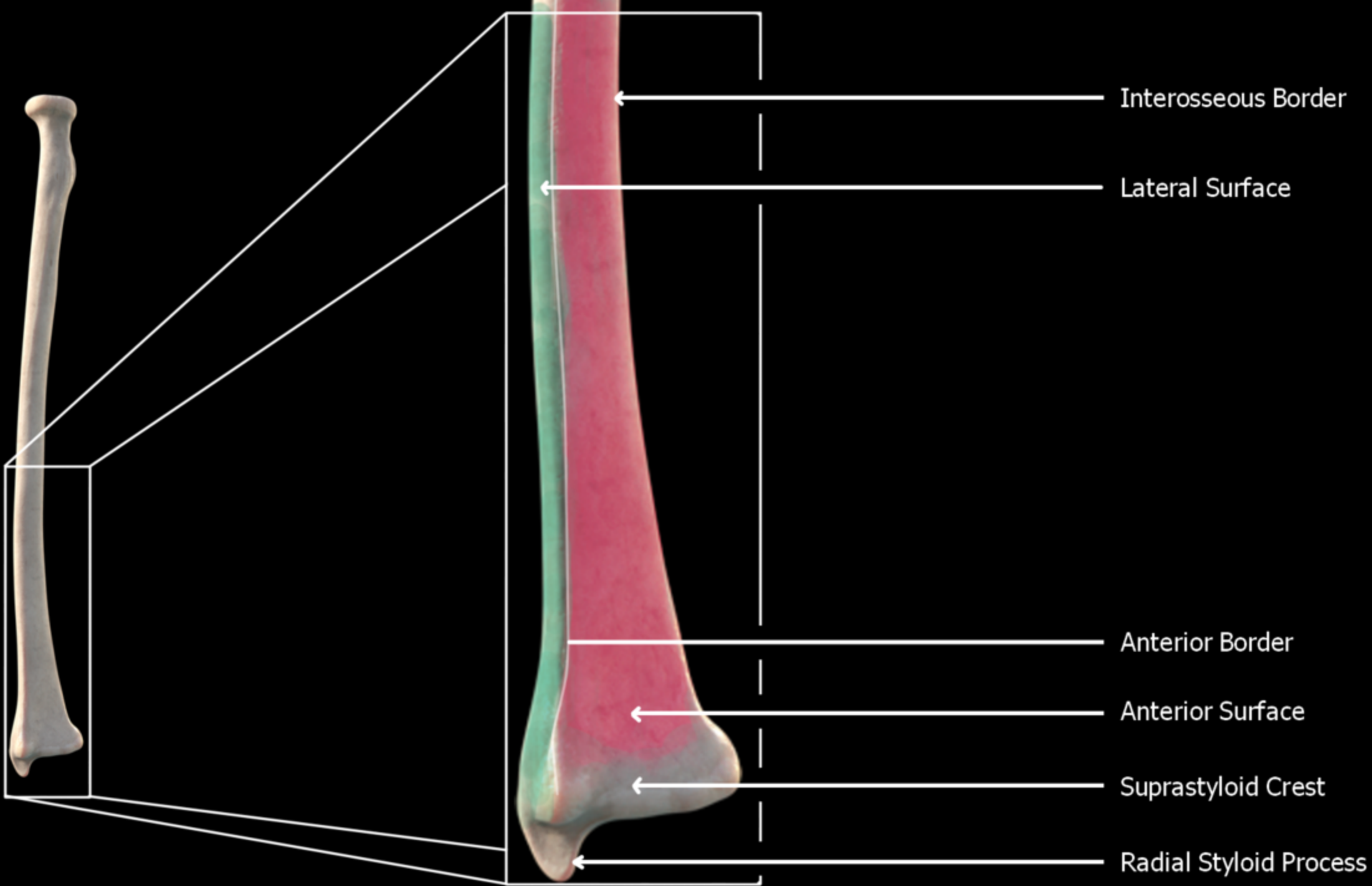


Styloid process

Radius, lateral view, right side

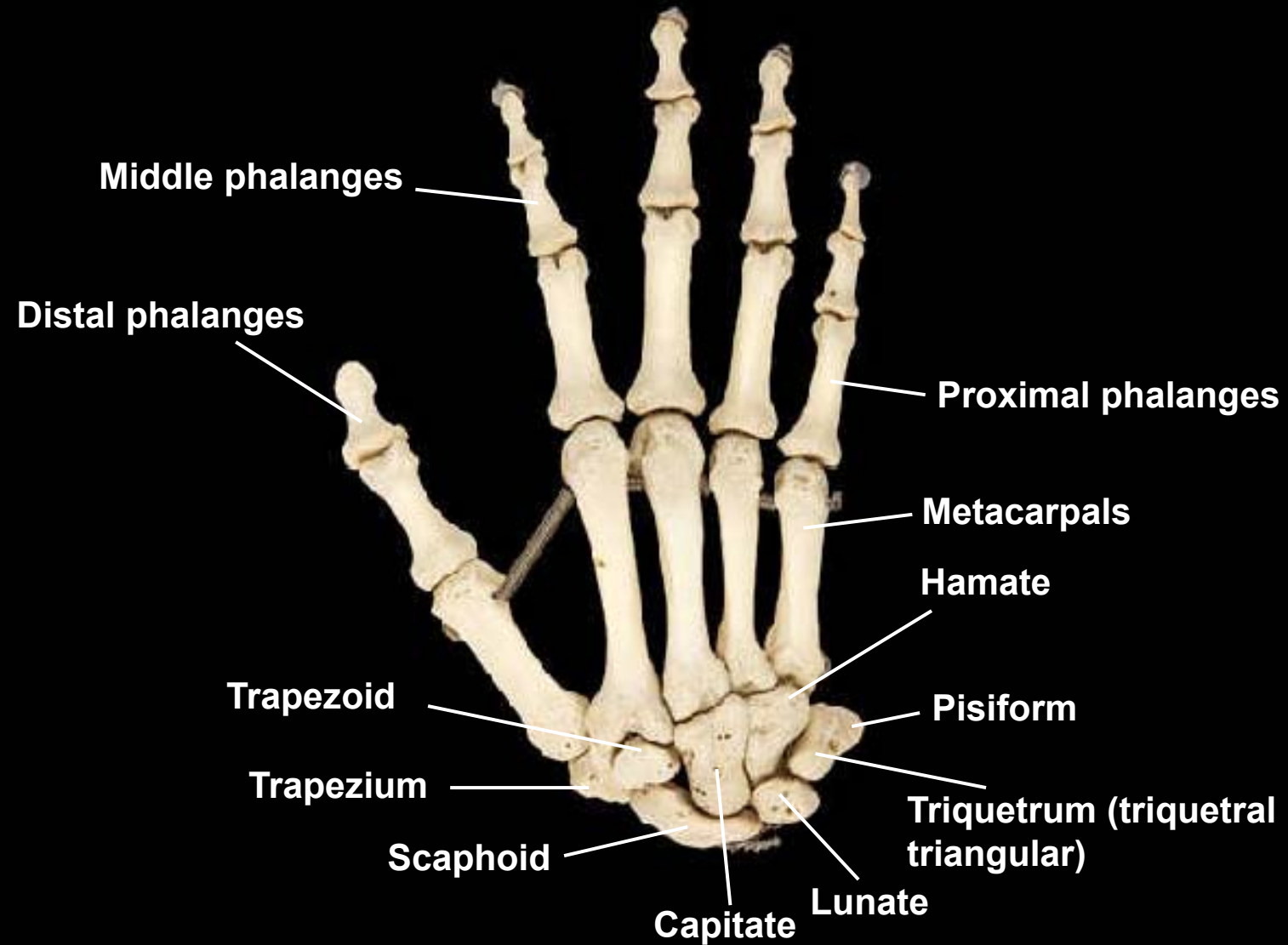




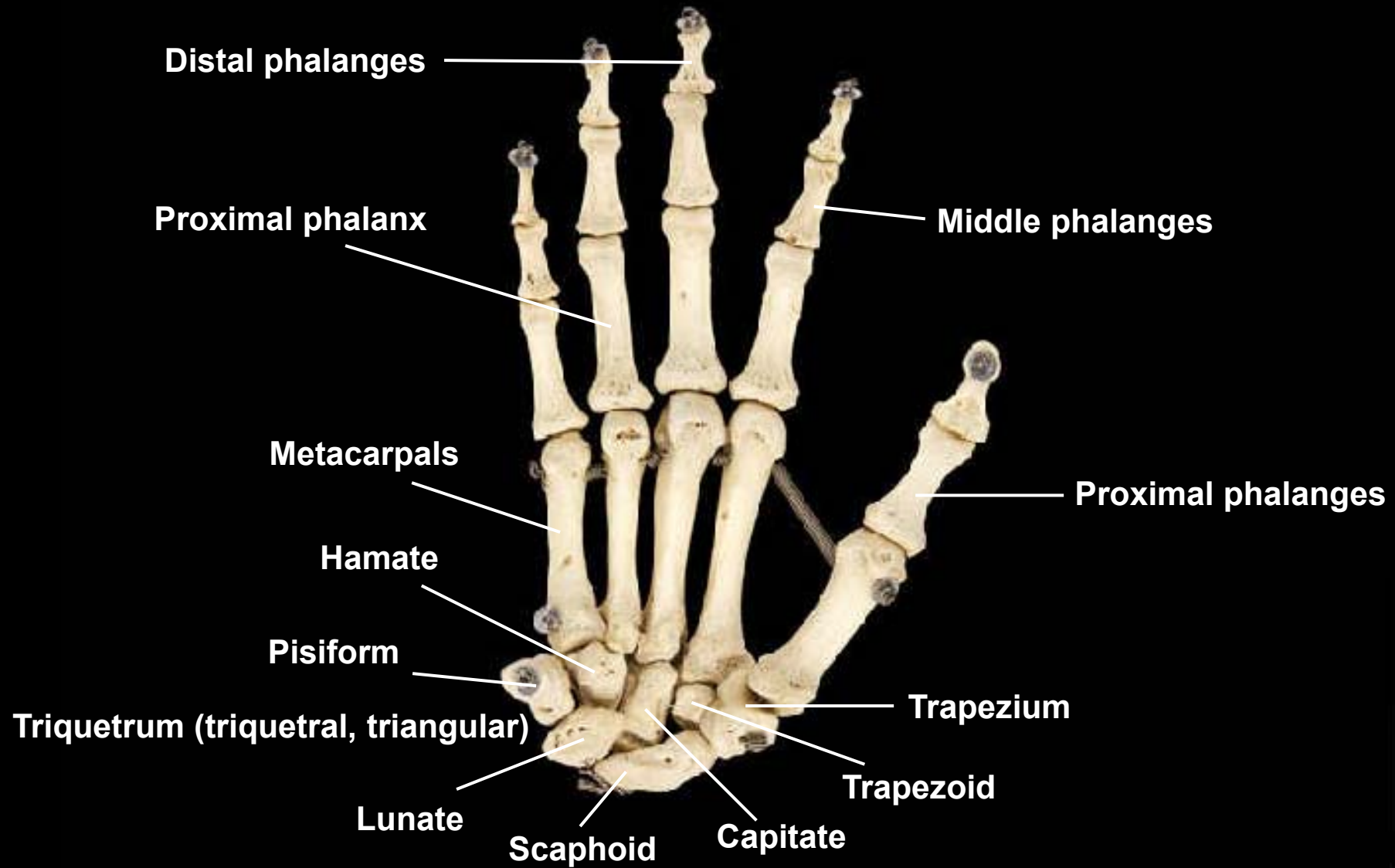


The Hand

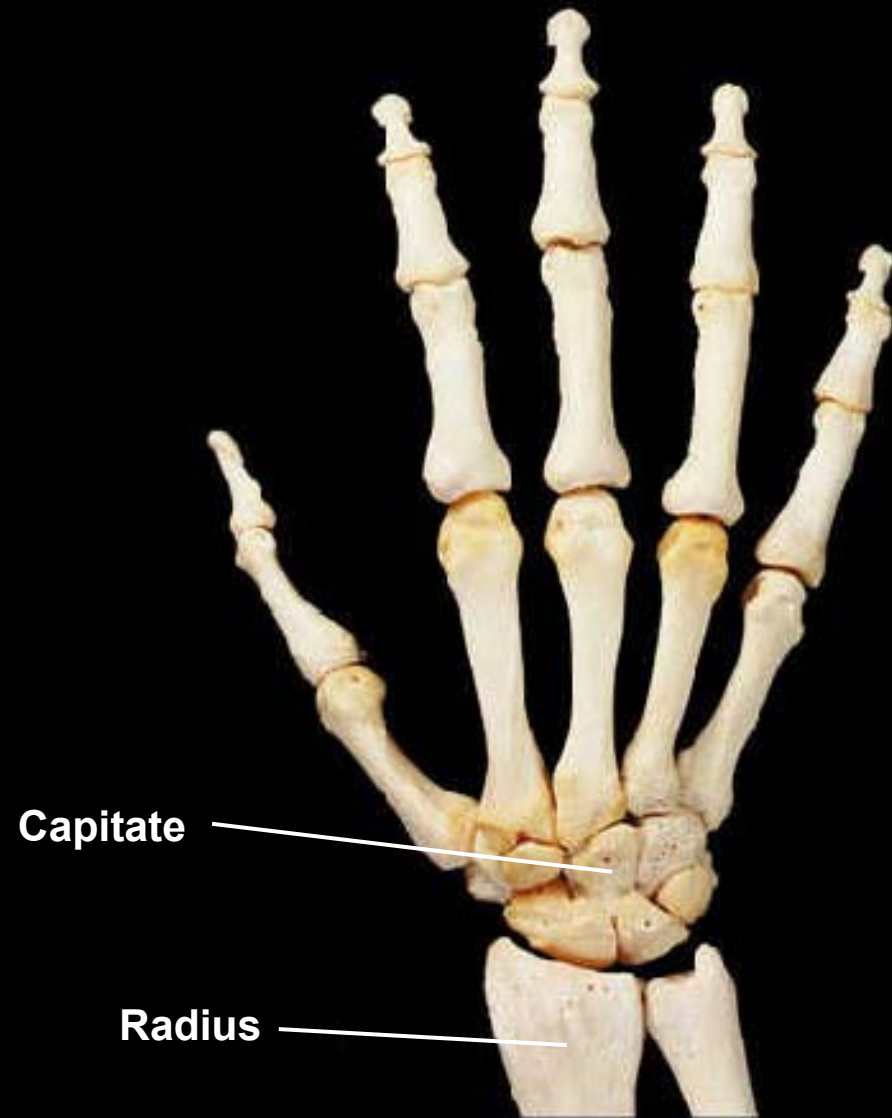
Bones of the hand, posterior view, right side



Bones of the hand, anterior view, right side



Hand, posterior view, right side



Capitate

Radius

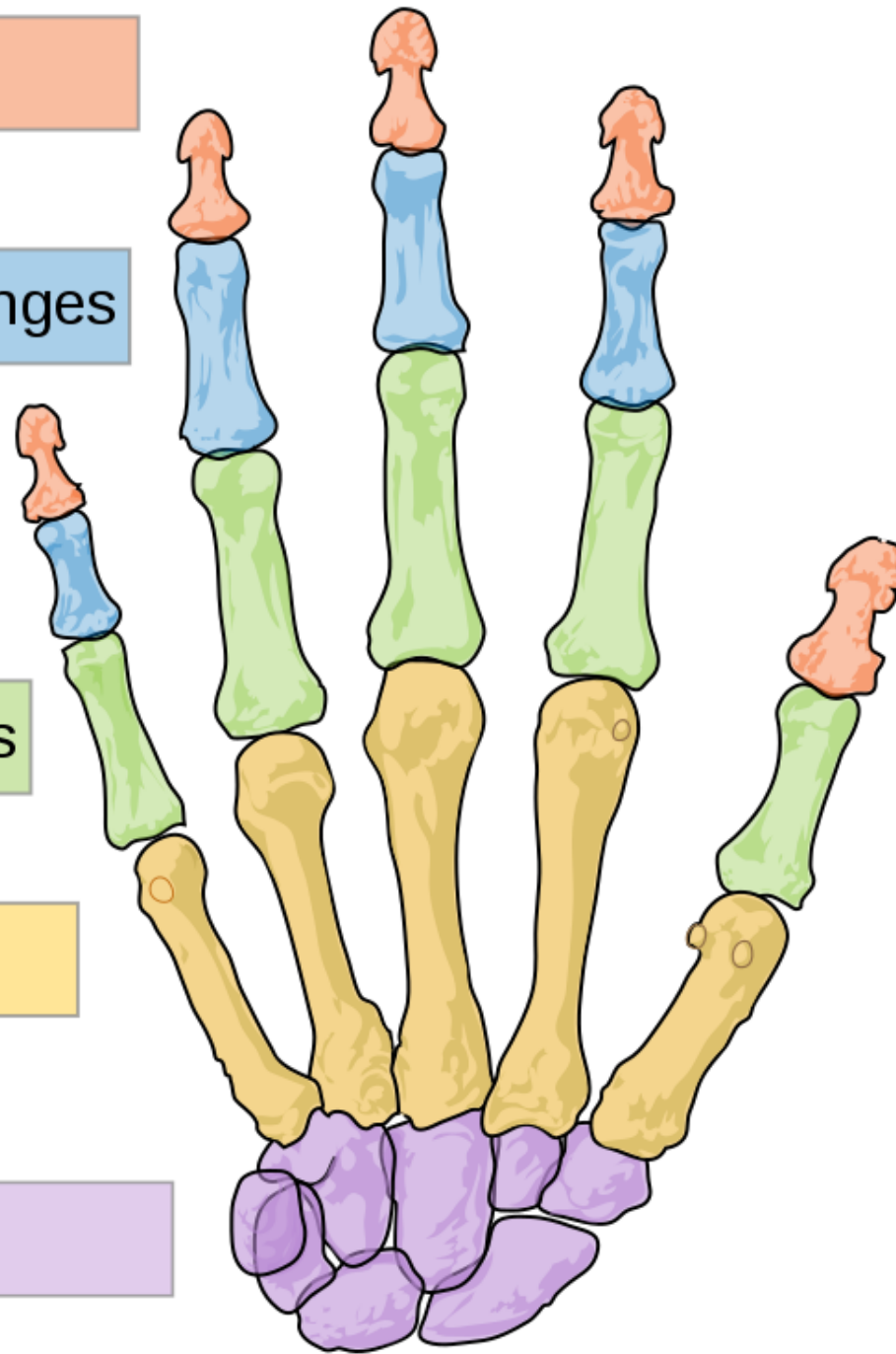
Distal phalanges

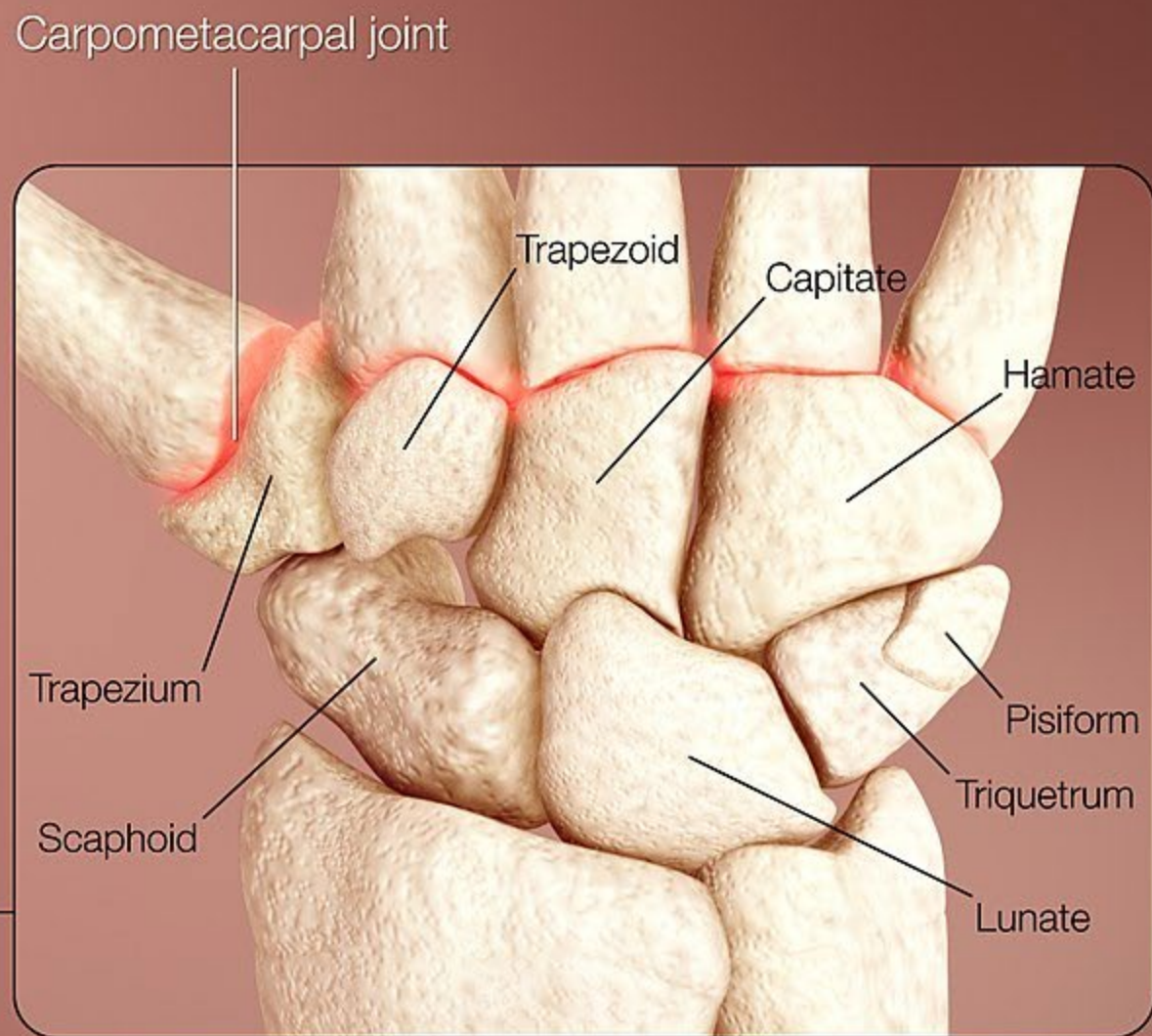
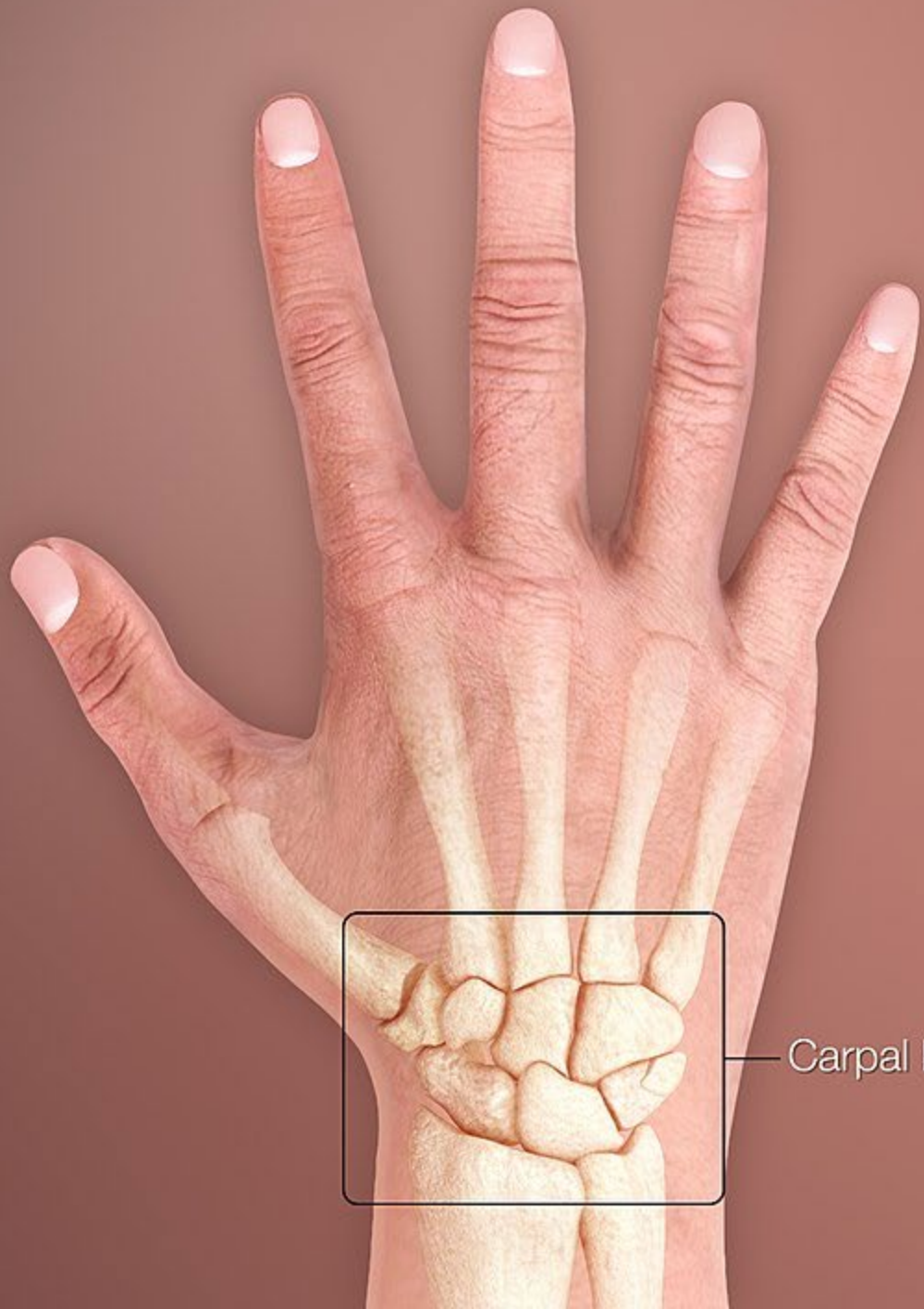Intermediate phalanges

Proximal phalanges

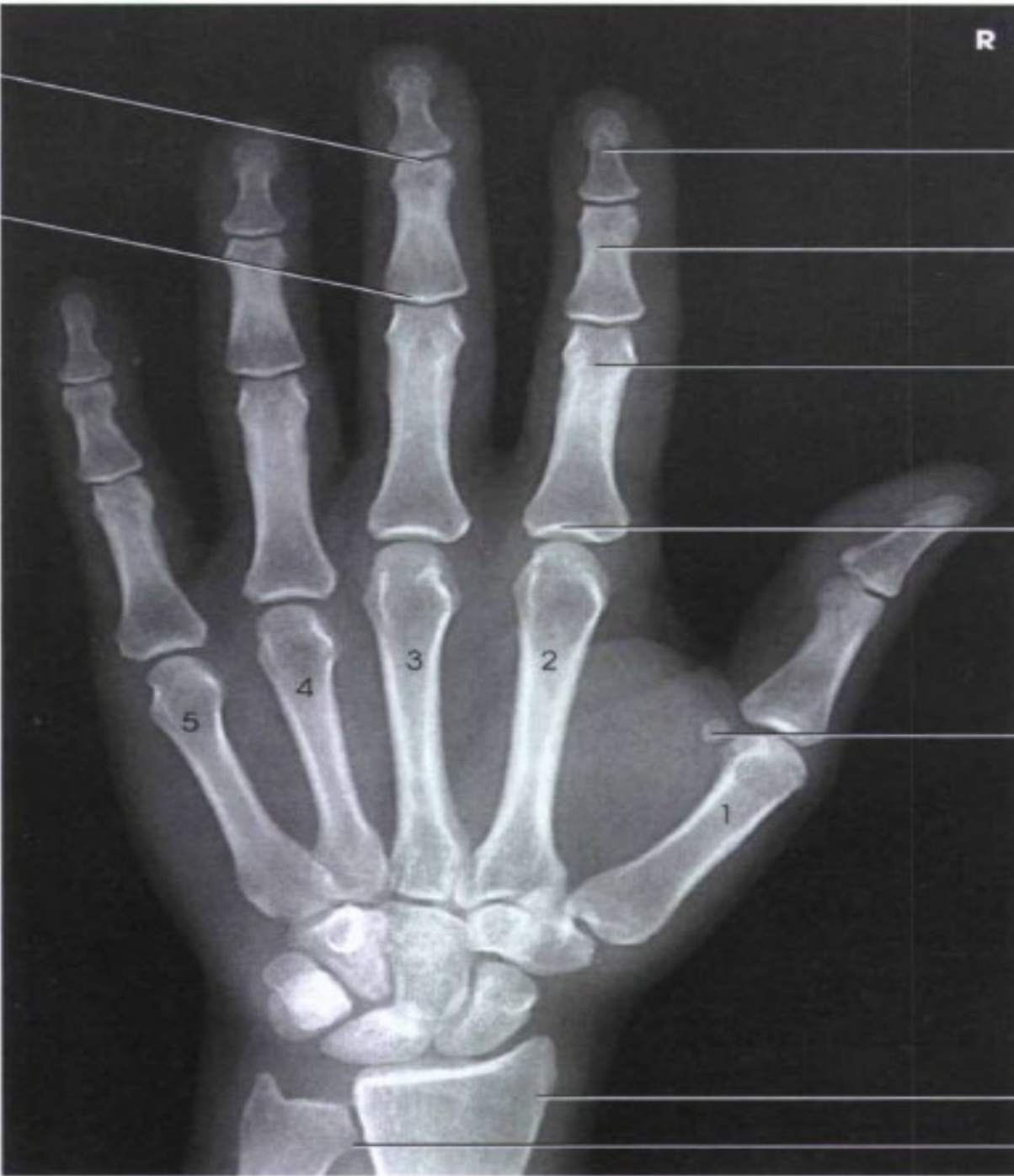Metacarpals

Carpals





R



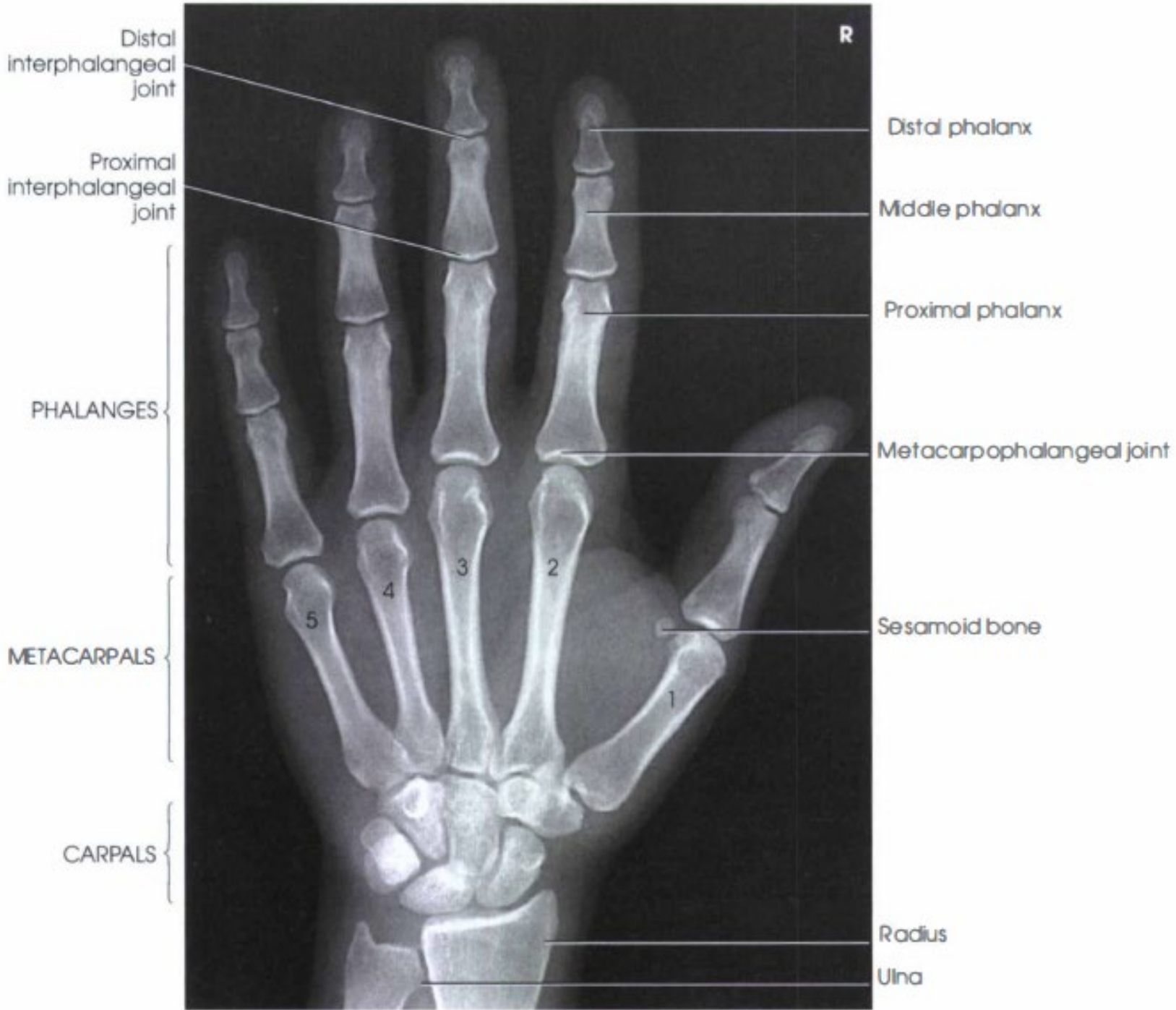5

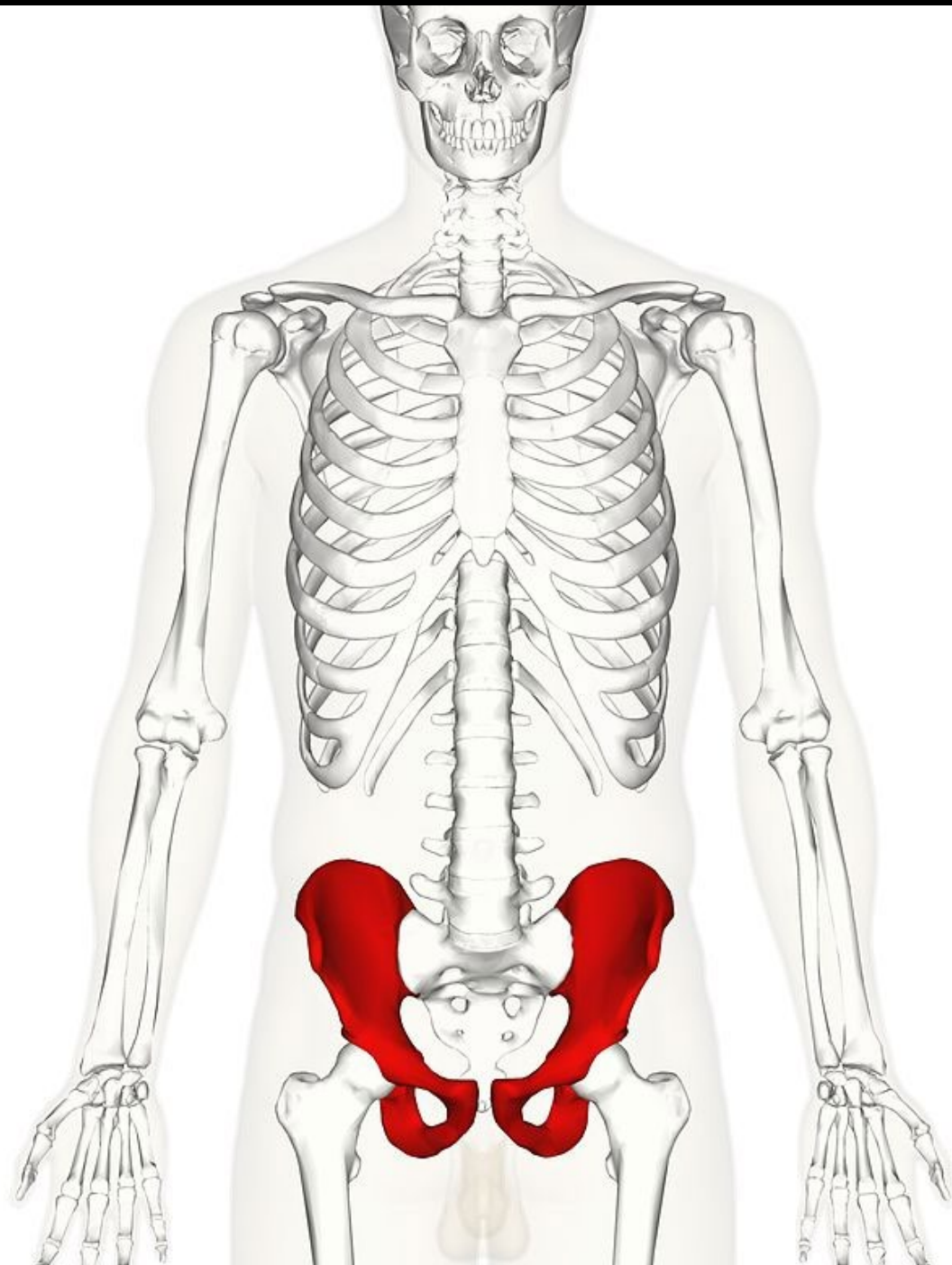
4

3

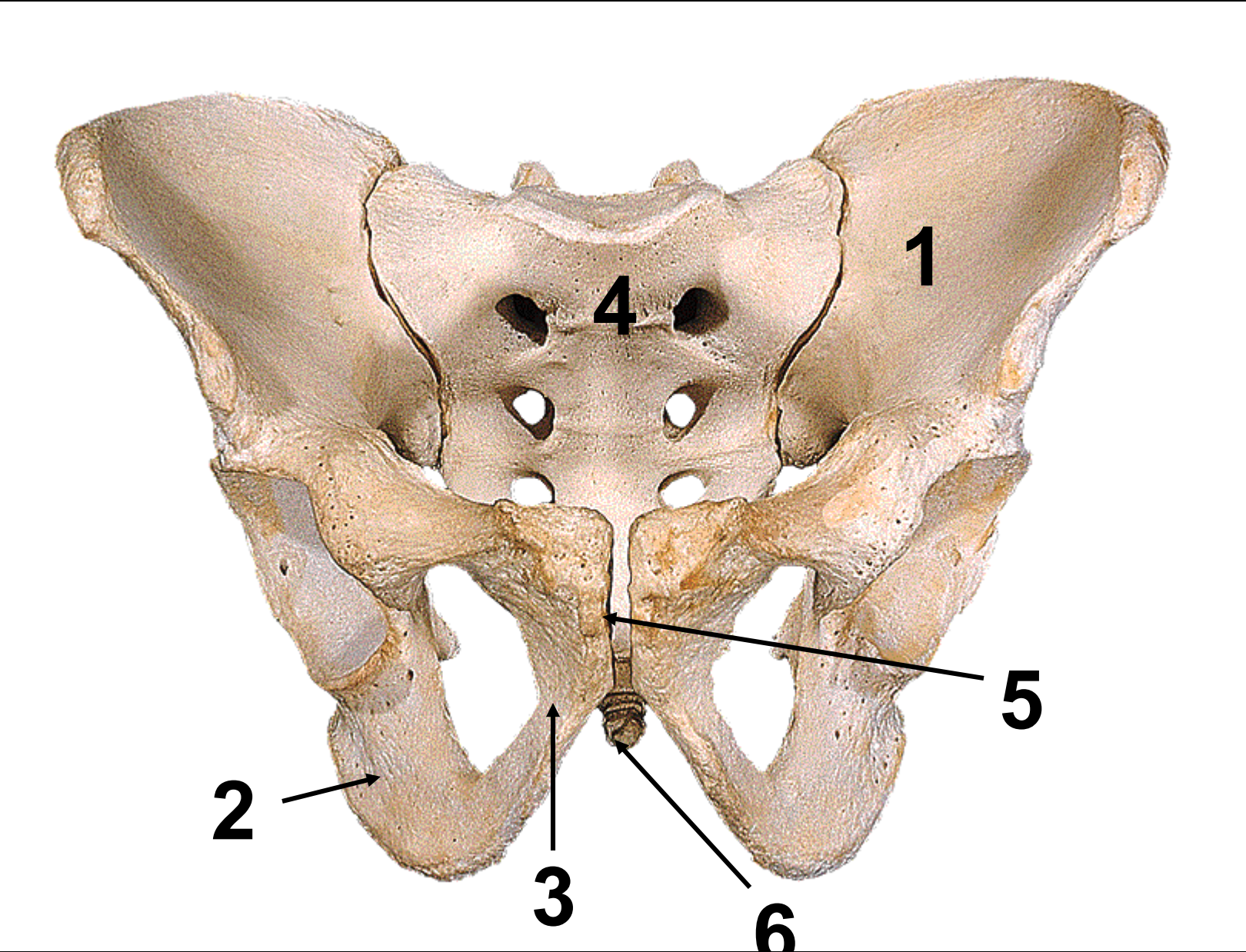
2

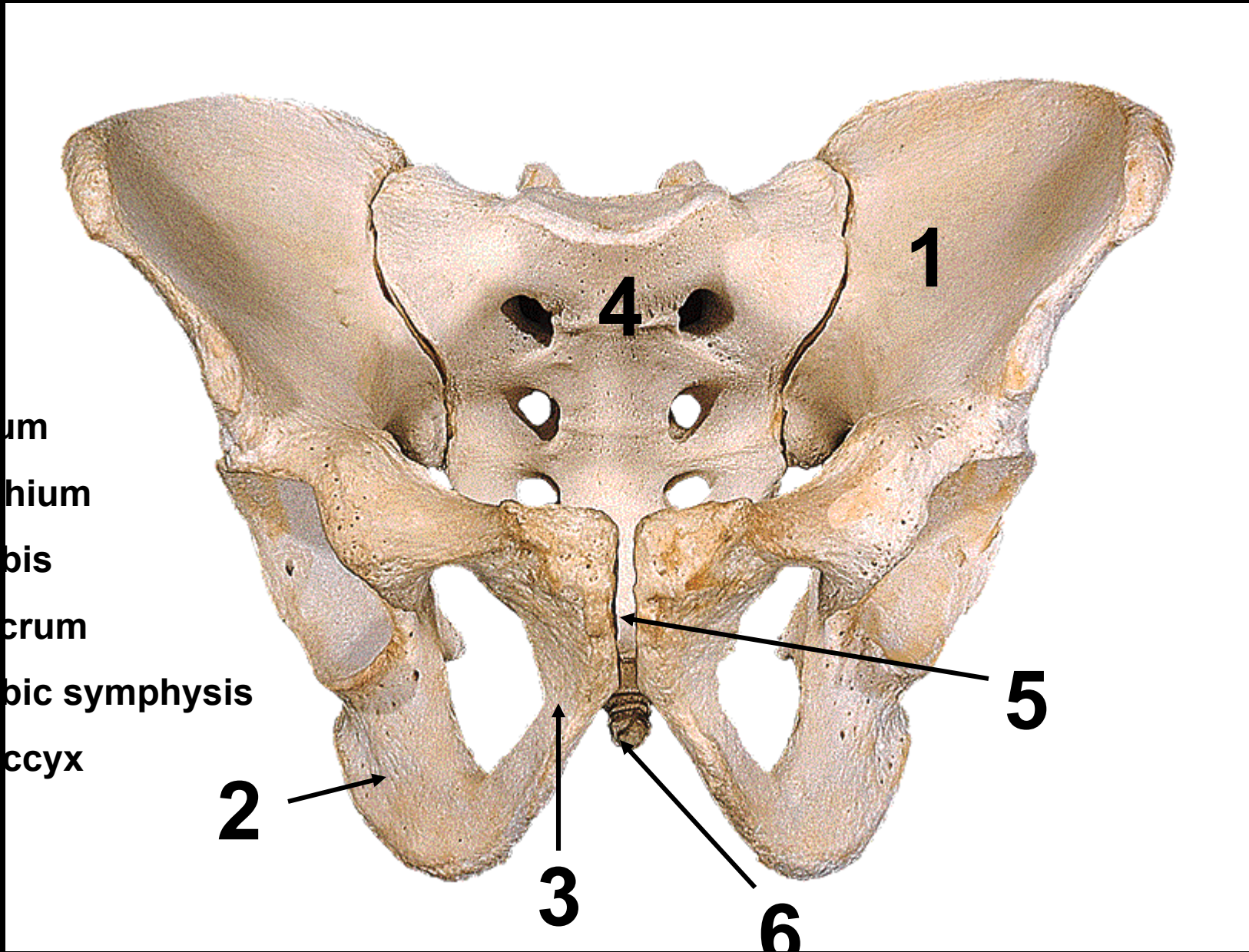
1





The Hips bones





um

hium

ois

crum

bic symphysis

ccyx

2

3

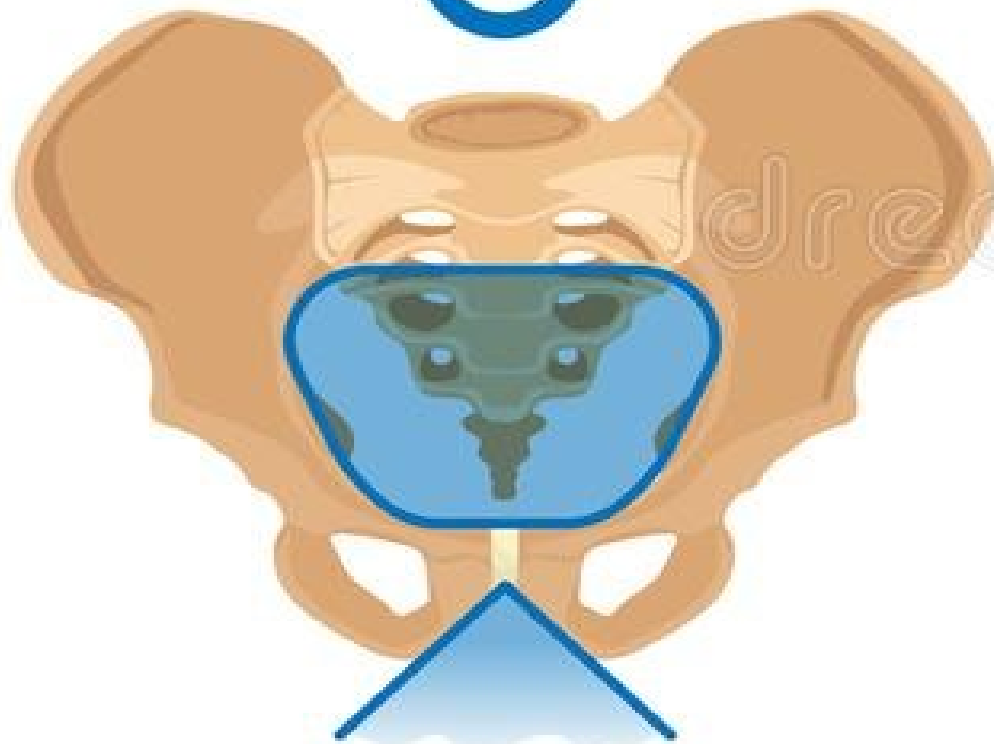4

1

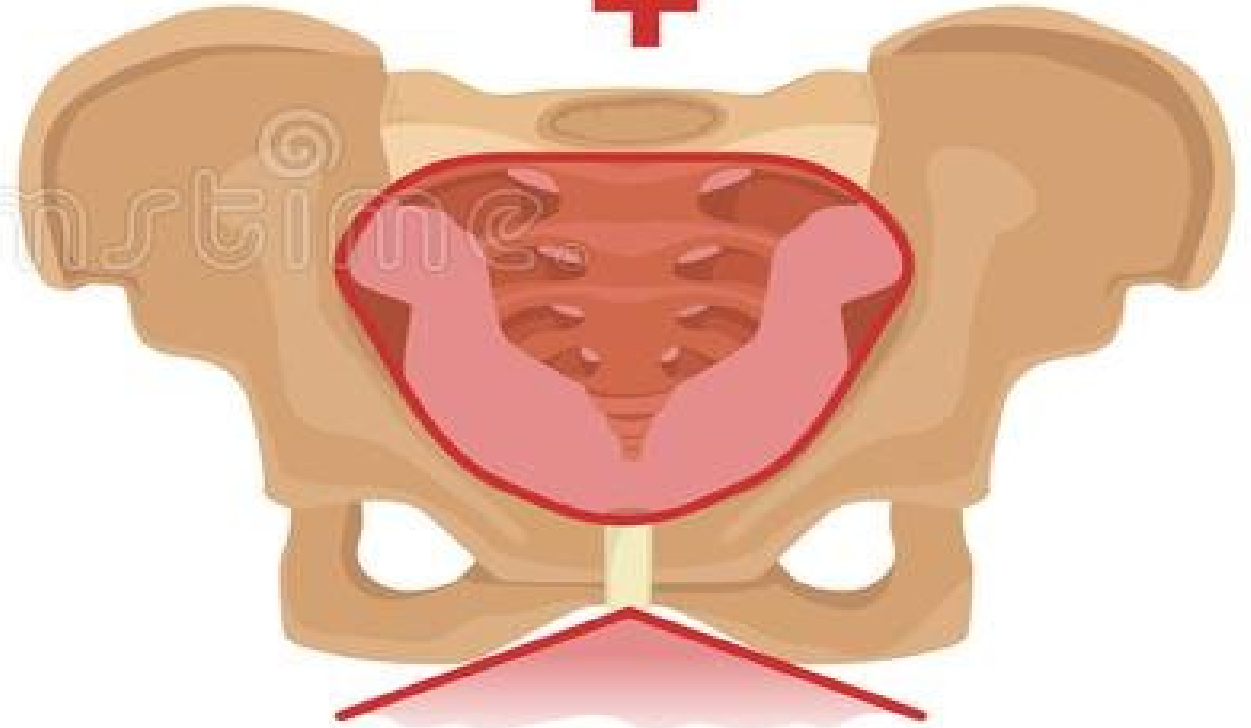
5

6

Male Vs Female Pelvis



NARROW PUBIC ARCH



WIDE PUBIC ARCH

Hip bone, lateral view, right side

Posterior superior iliac spine

Posterior inferior iliac spine

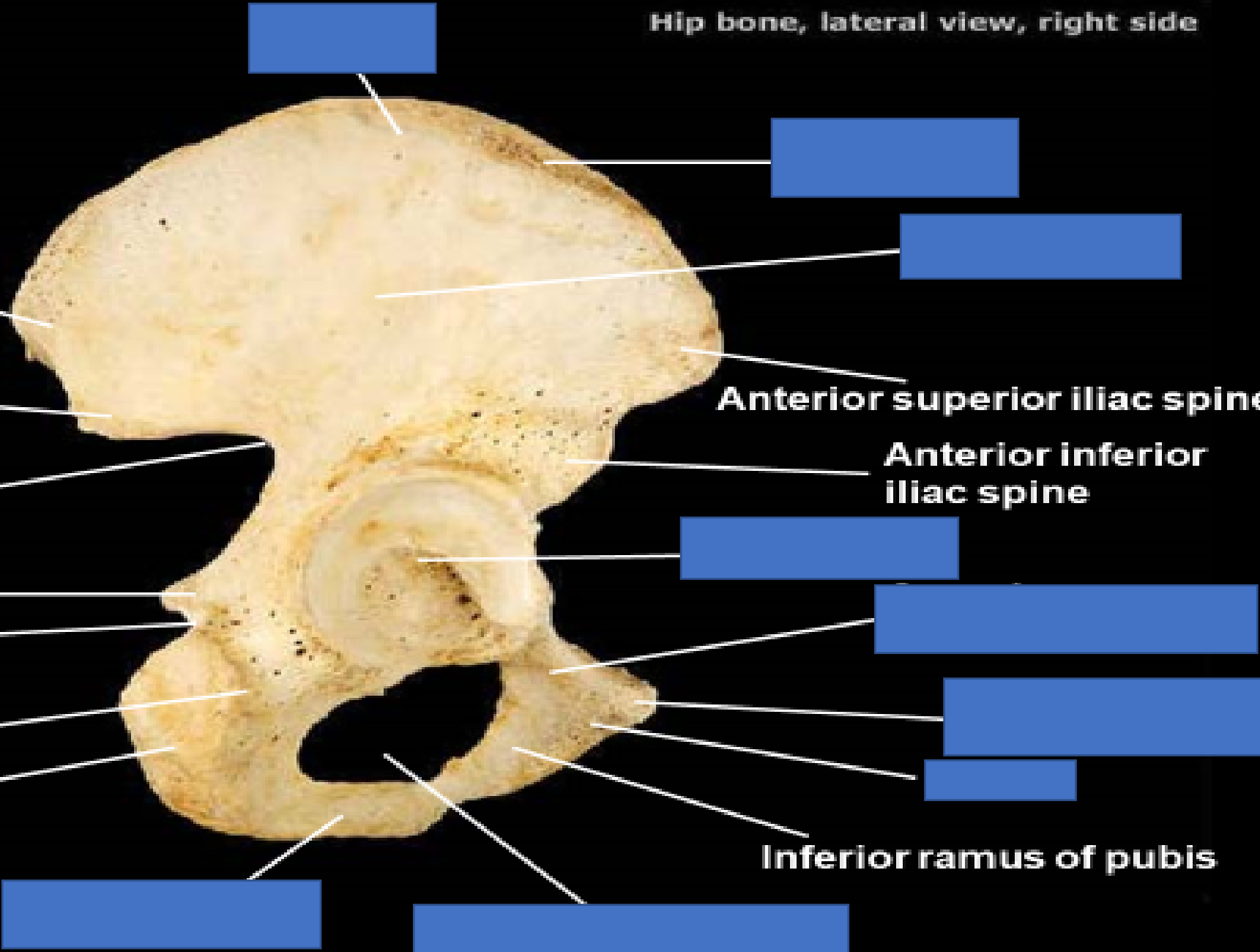
Ischial spine
Lesser sciatic notch

Ischial tuberosity

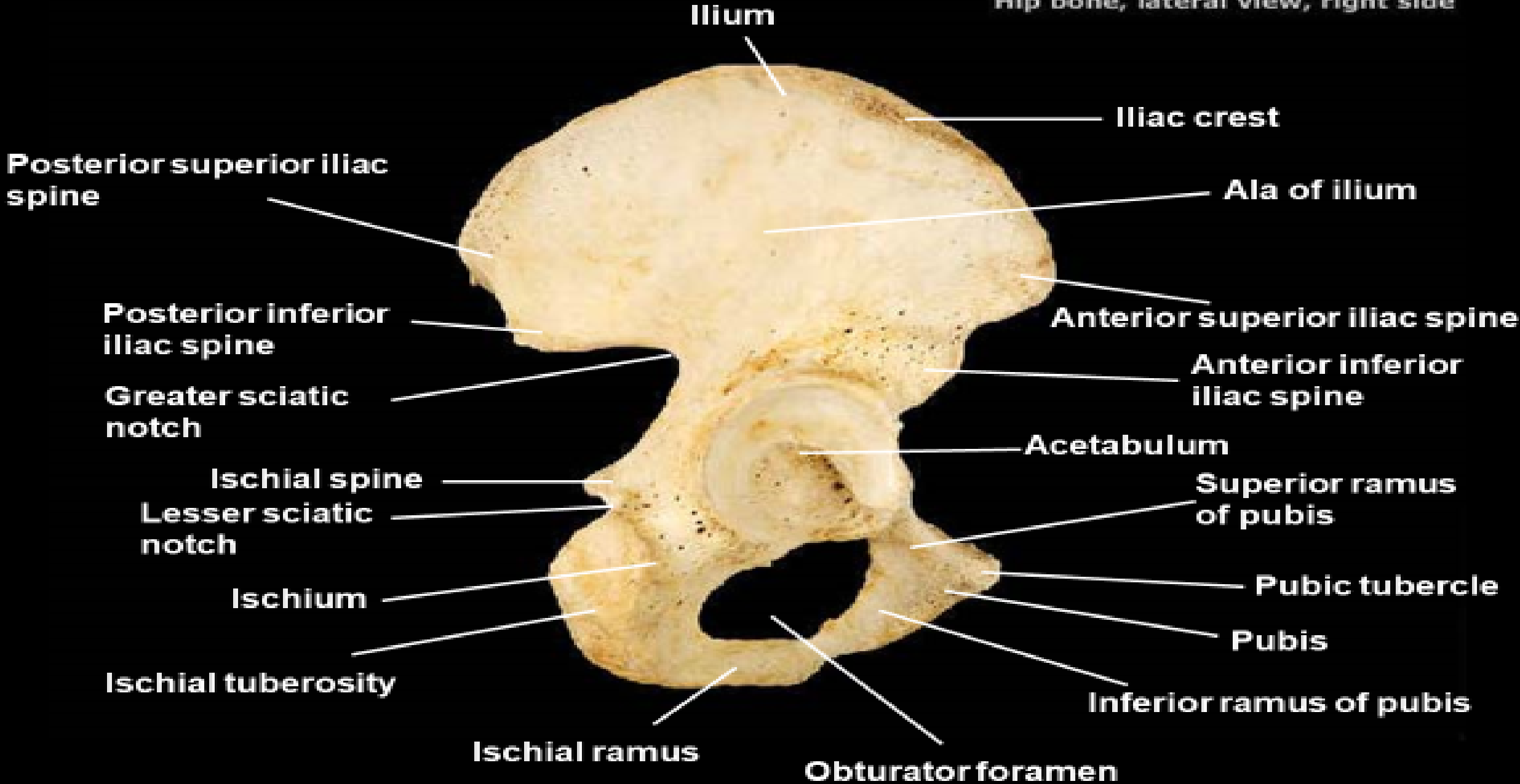
Anterior superior iliac spine

Anterior inferior iliac spine

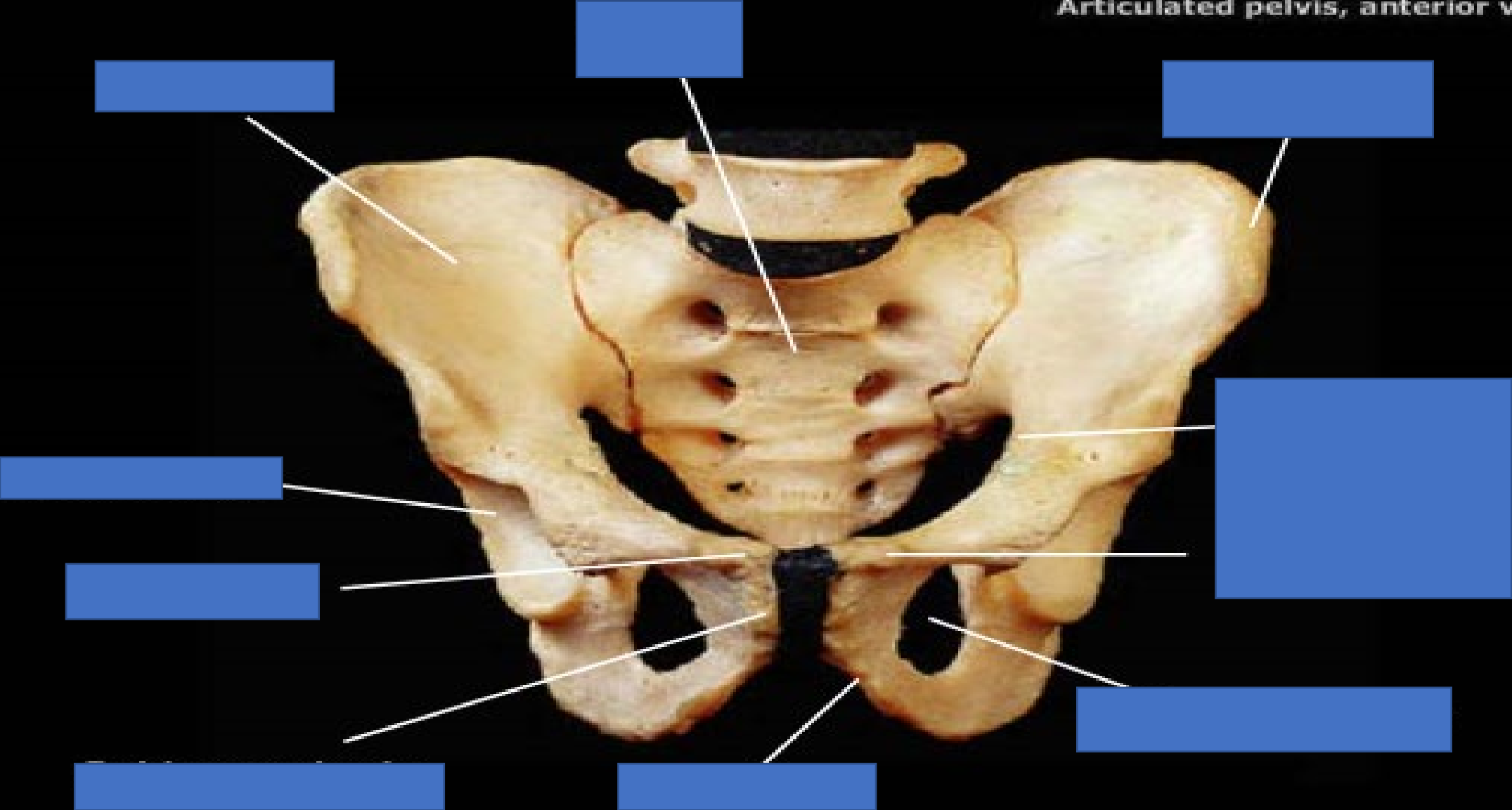
Inferior ramus of pubis



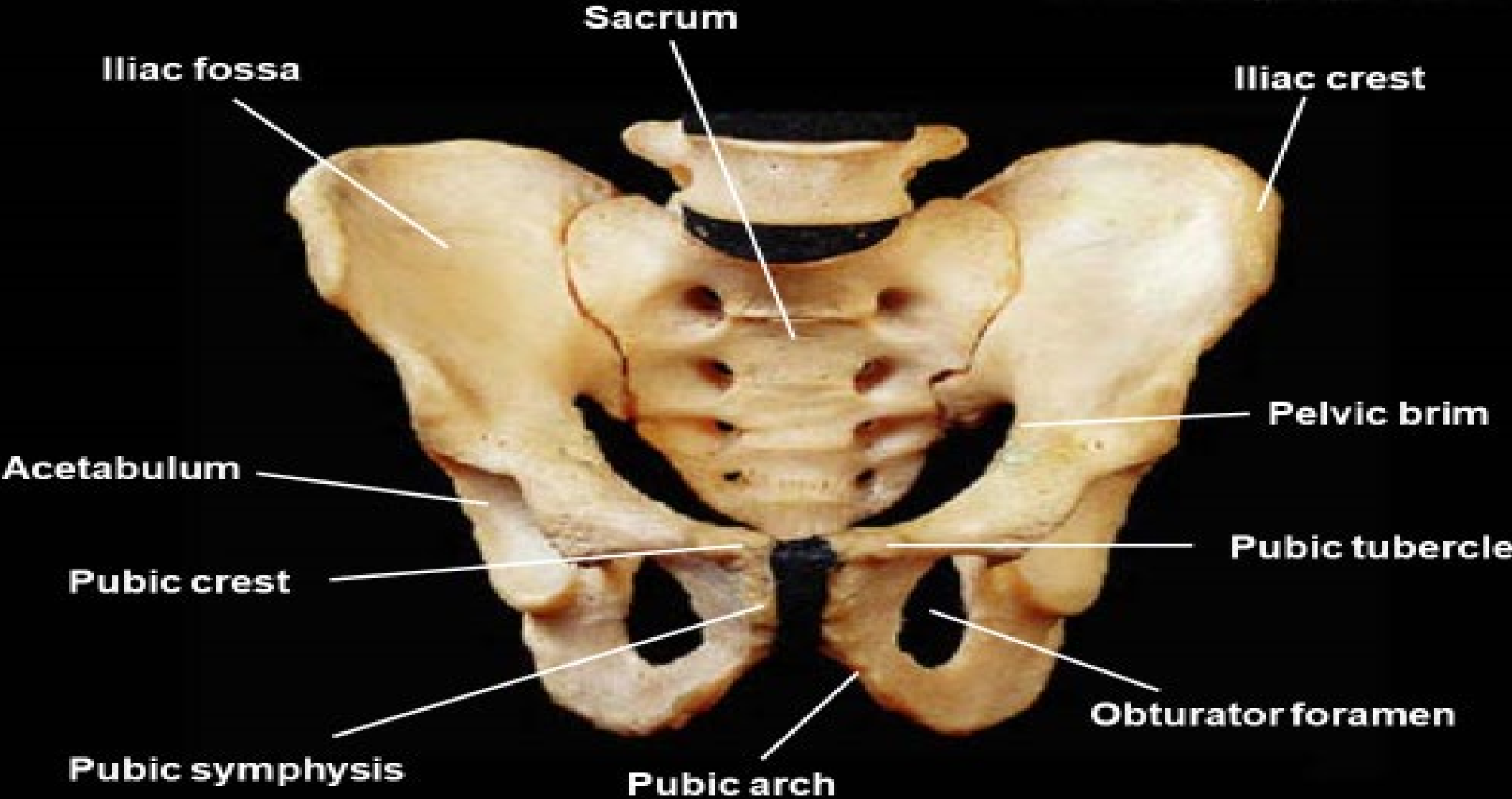
Hip bone, lateral view, right side

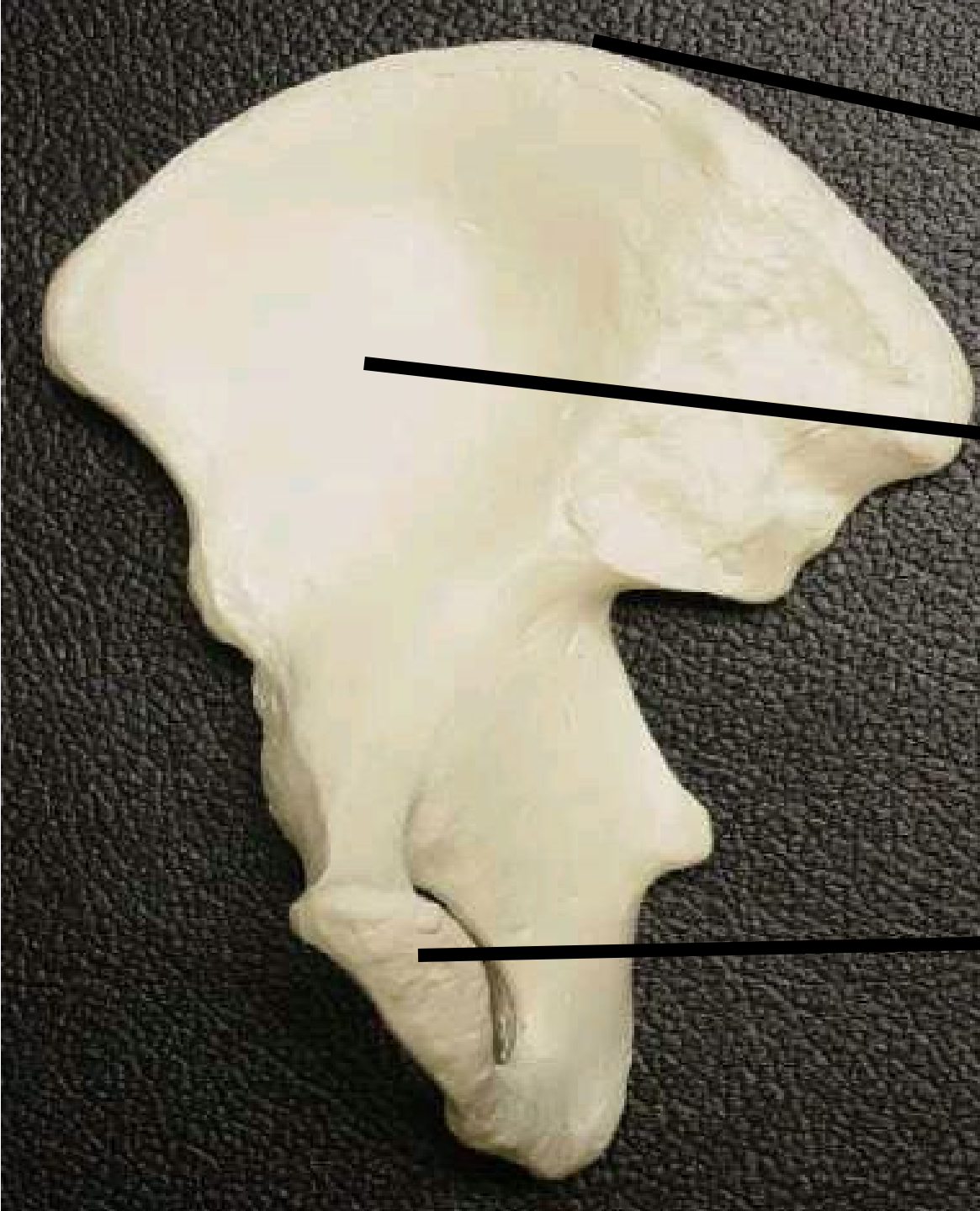


Articulated pelvis, anterior view



Articulated pelvis, anterior view





1

Identify structure

#1

2

#2

#3

3

Identify structure

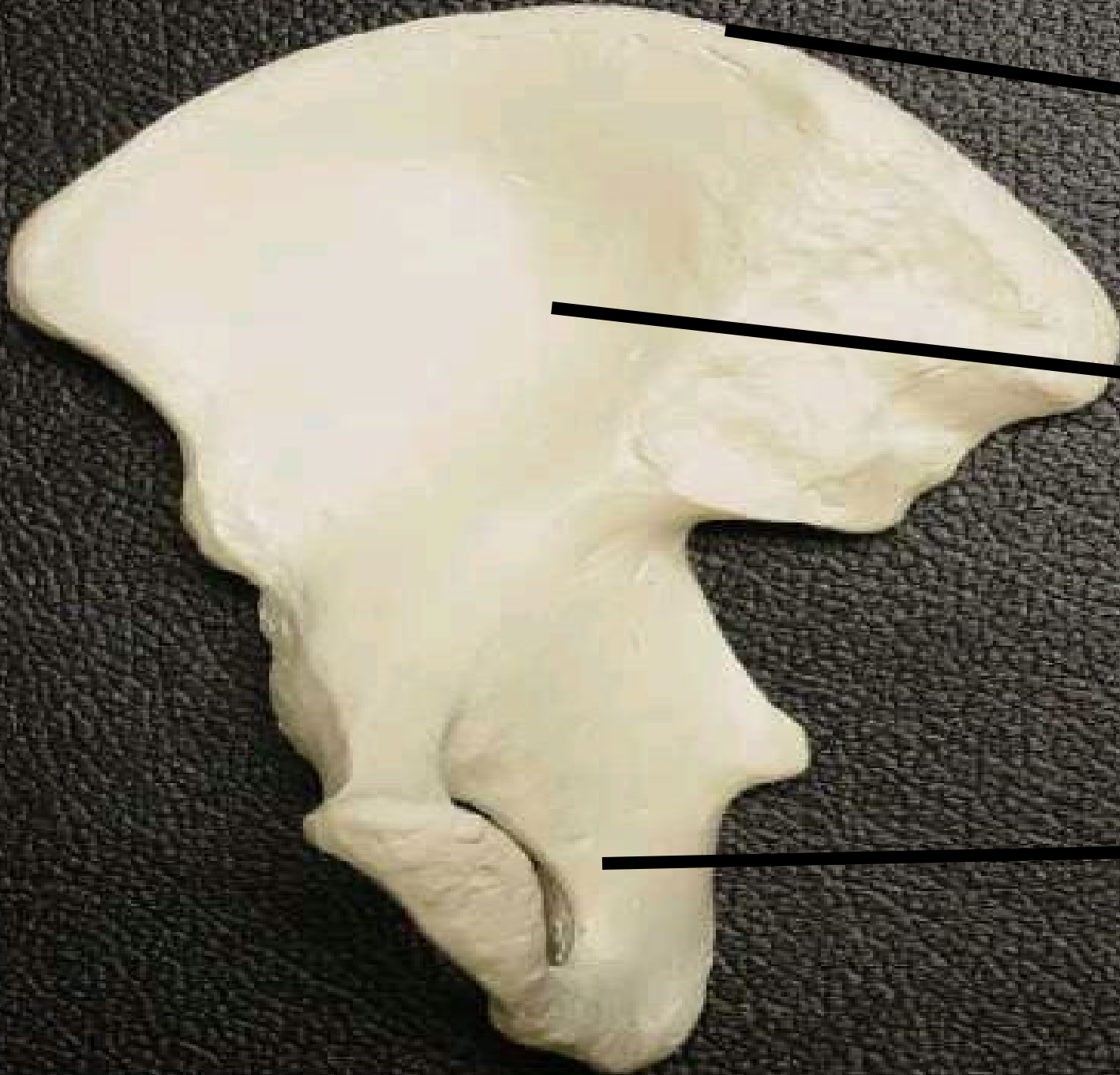
1 #1

anterior superior iliac
spine -Iliac Crest

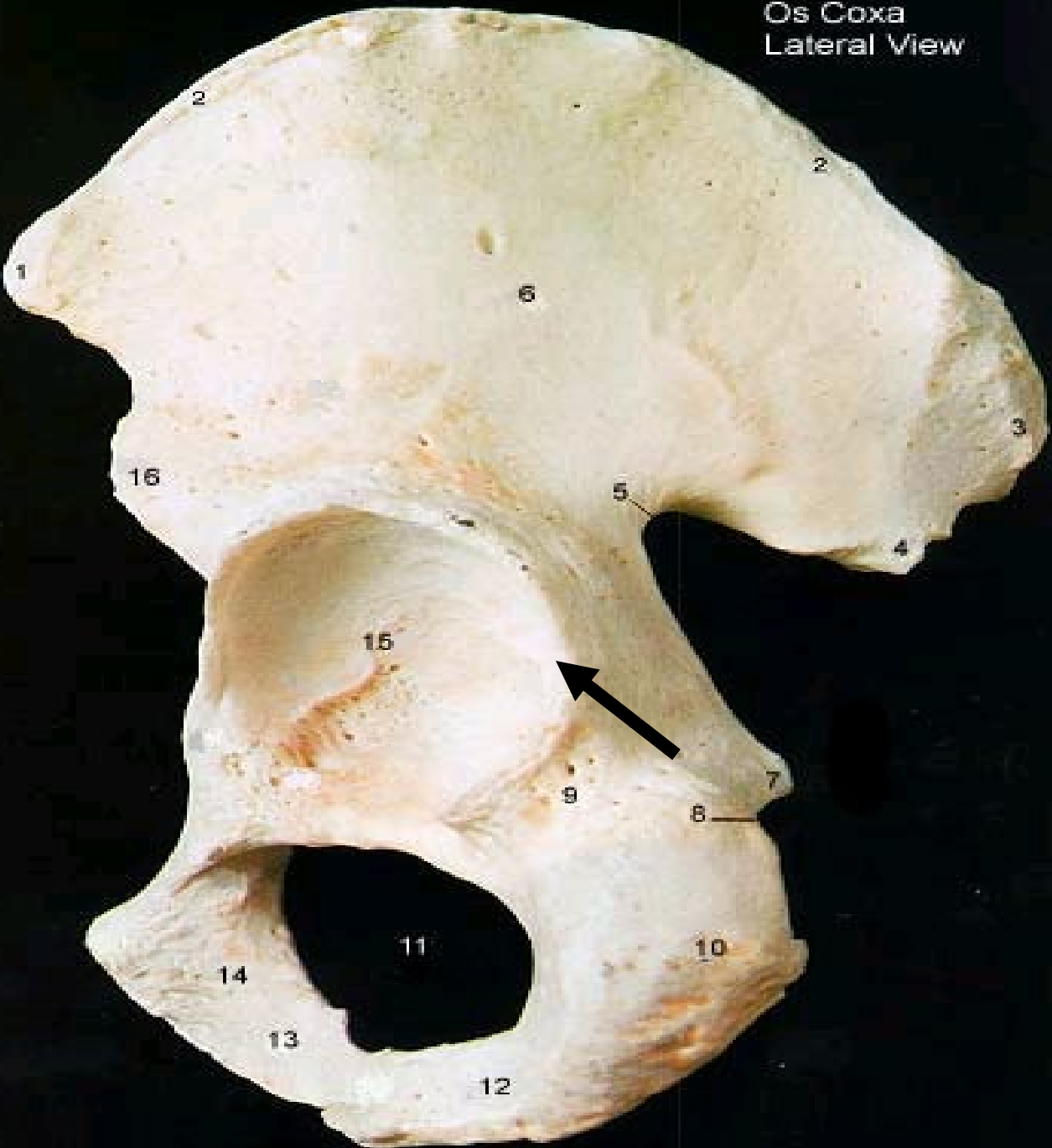2 #2 iliac fossa

#3 inferior pubic
ramus , Symphysis
Pubis
Articulating Surface

3



Os Coxa
Lateral View



**What bone
association of this
os coxa form the
structure # 15**

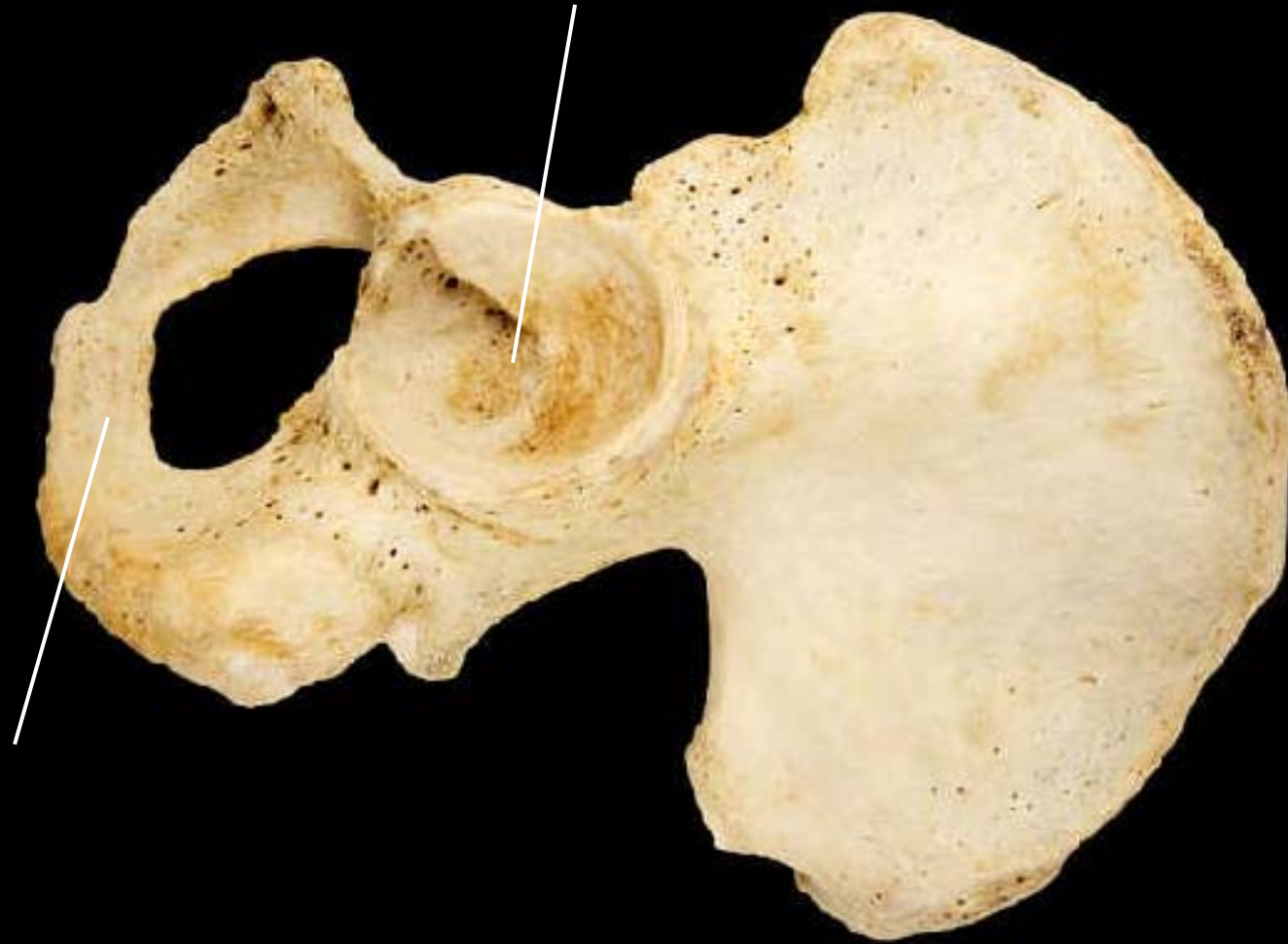Os Coxa
Lateral View



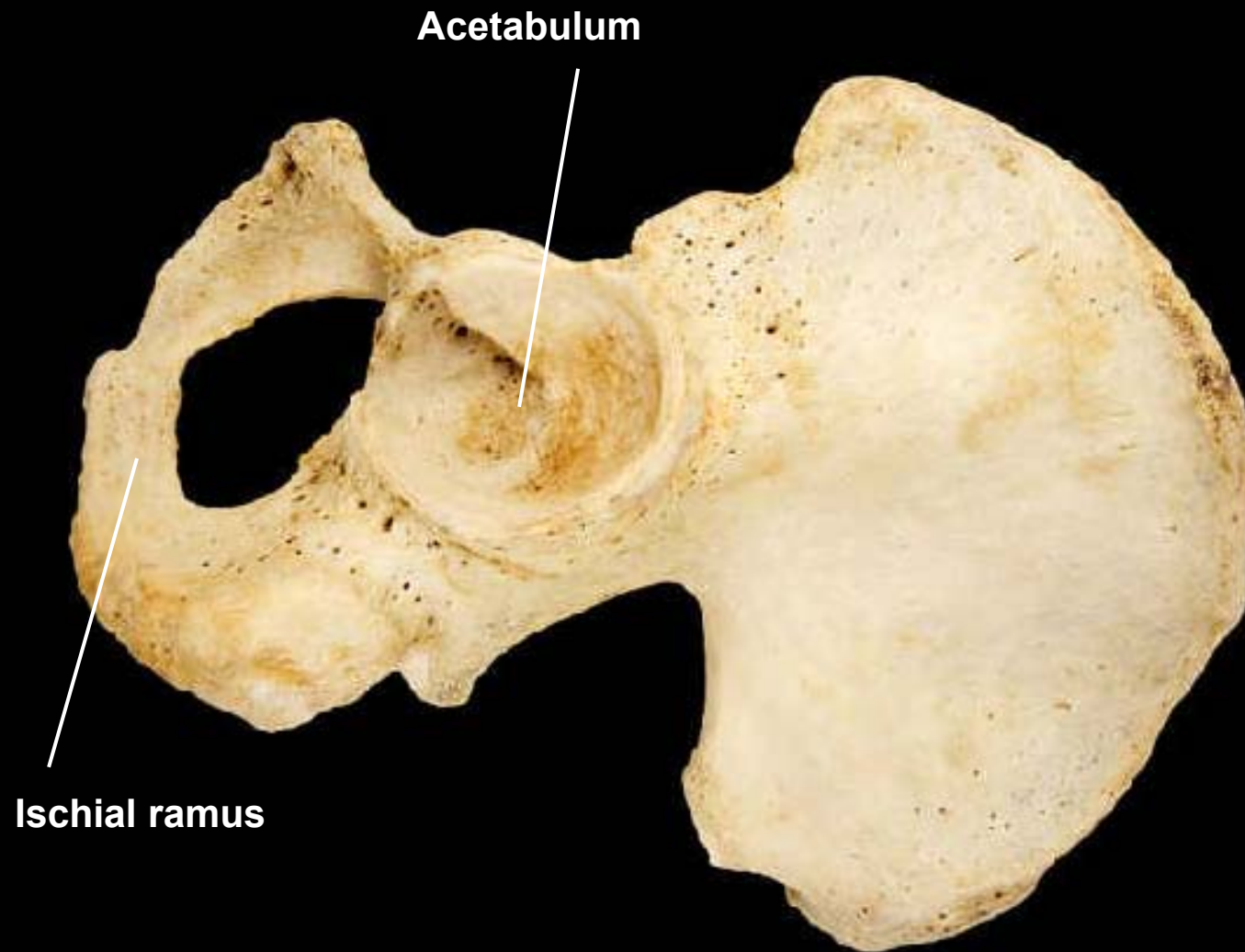
**What bone association
of this os coxa form the
structure # 15**

Ilium, ischium, pubis

Hipe bone, lateral view, left side



Hipe bone, lateral view, left side



Hip bone, lateral view, right side

Posterior superior iliac spine

Posterior inferior iliac spine

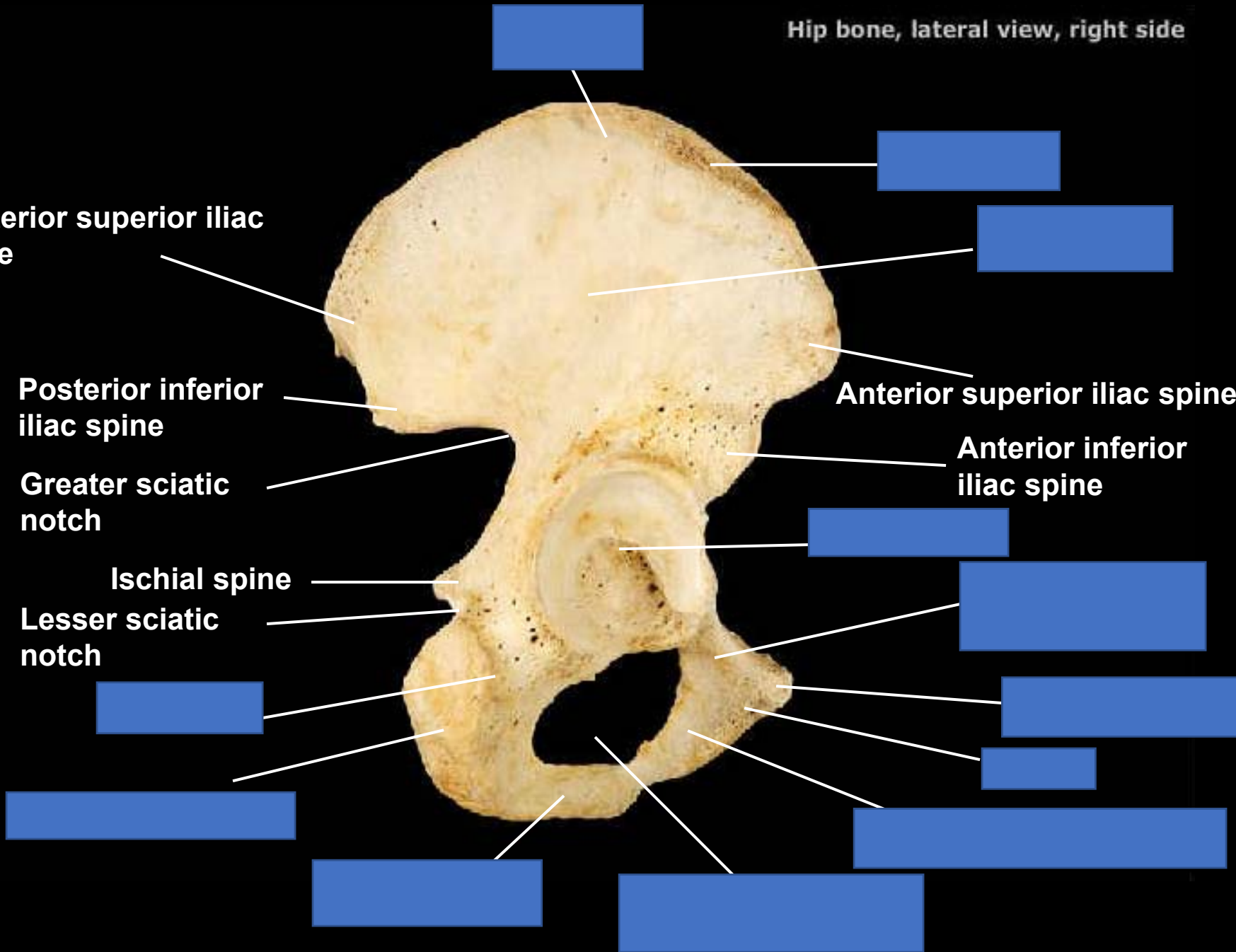
Greater sciatic notch

Ischial spine

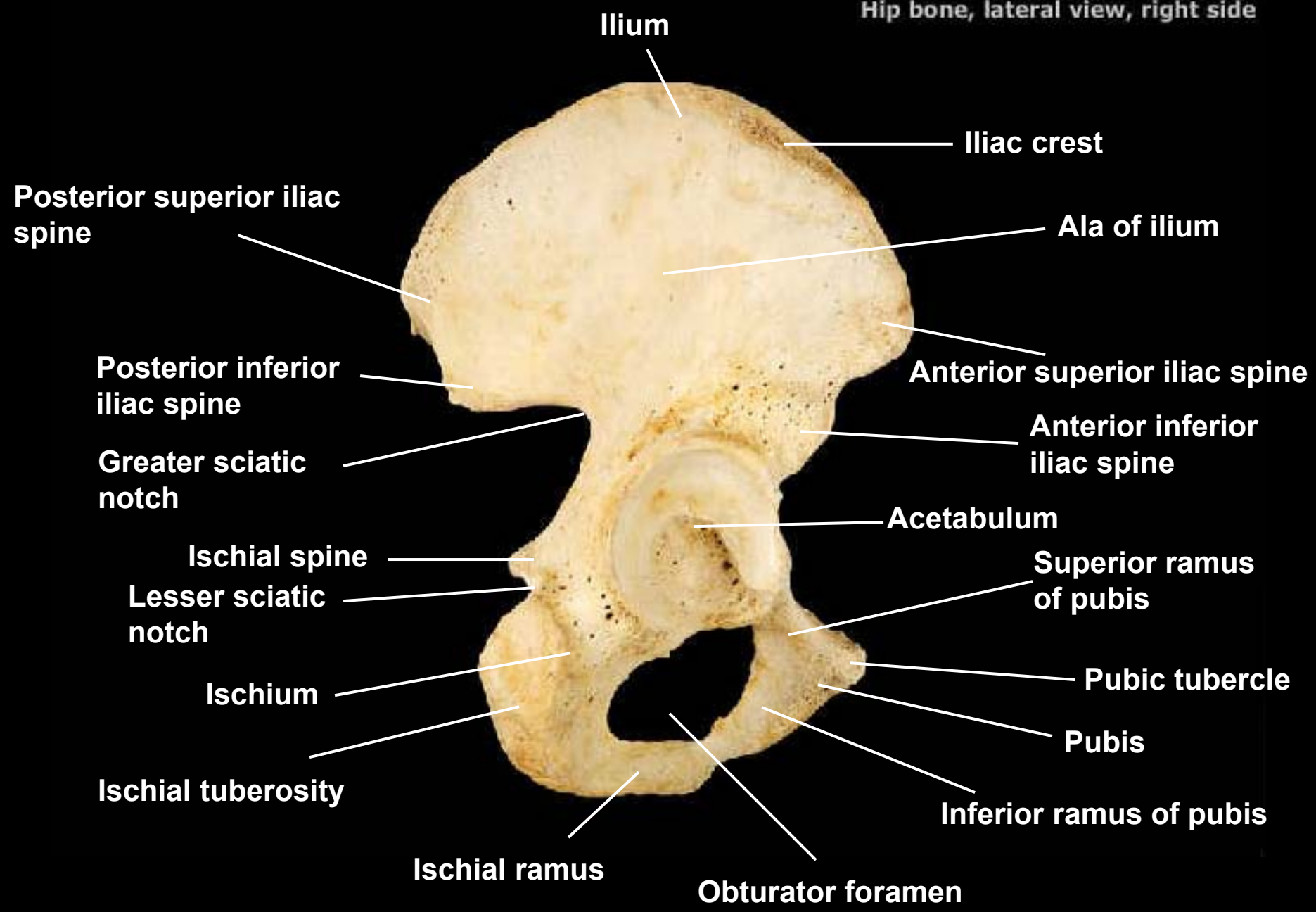
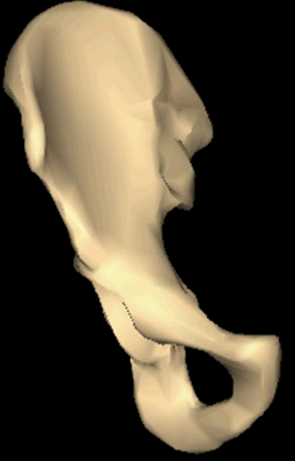Lesser sciatic notch

Anterior superior iliac spine

Anterior inferior iliac spine



Hip bone, lateral view, right side



Ilium

Iliac crest

Ala of ilium

Posterior superior iliac spine

Anterior superior iliac spine

Posterior inferior iliac spine

Anterior inferior iliac spine

Greater sciatic notch

Acetabulum

Ischial spine

Superior ramus of pubis

Lesser sciatic notch

Pubic tubercle

Ischium

Pubis

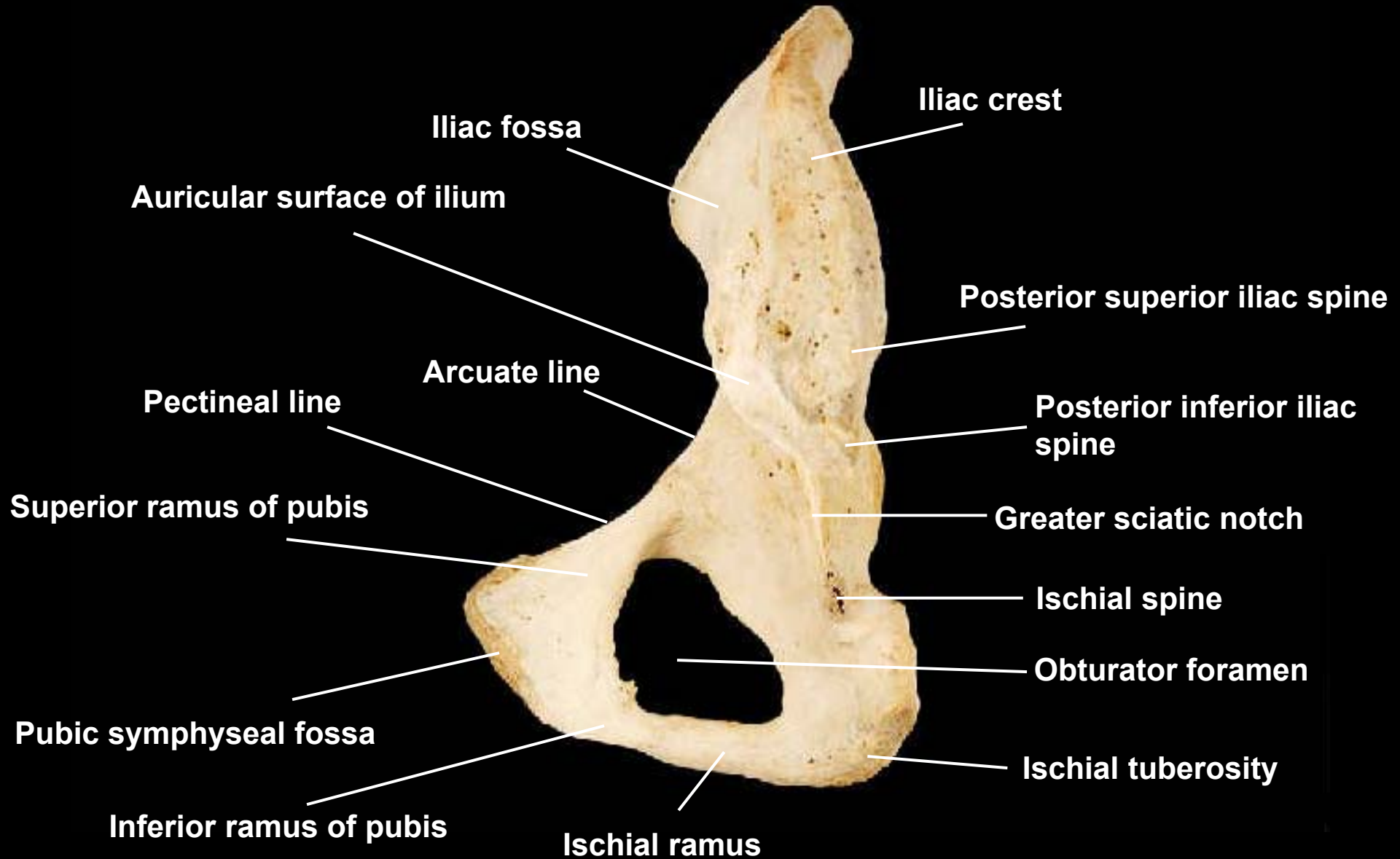
Ischial tuberosity

Inferior ramus of pubis

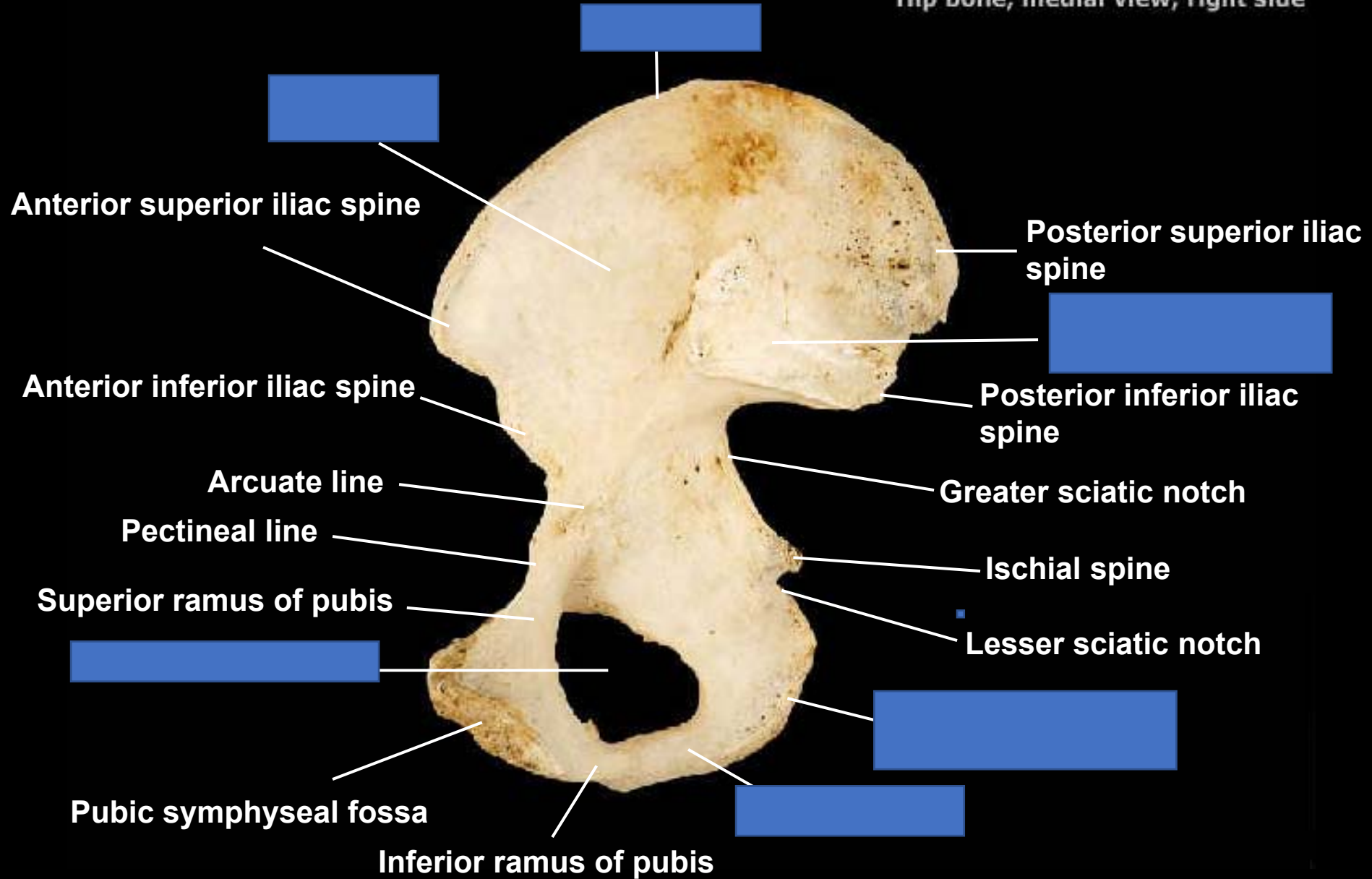
Ischial ramus

Obturator foramen

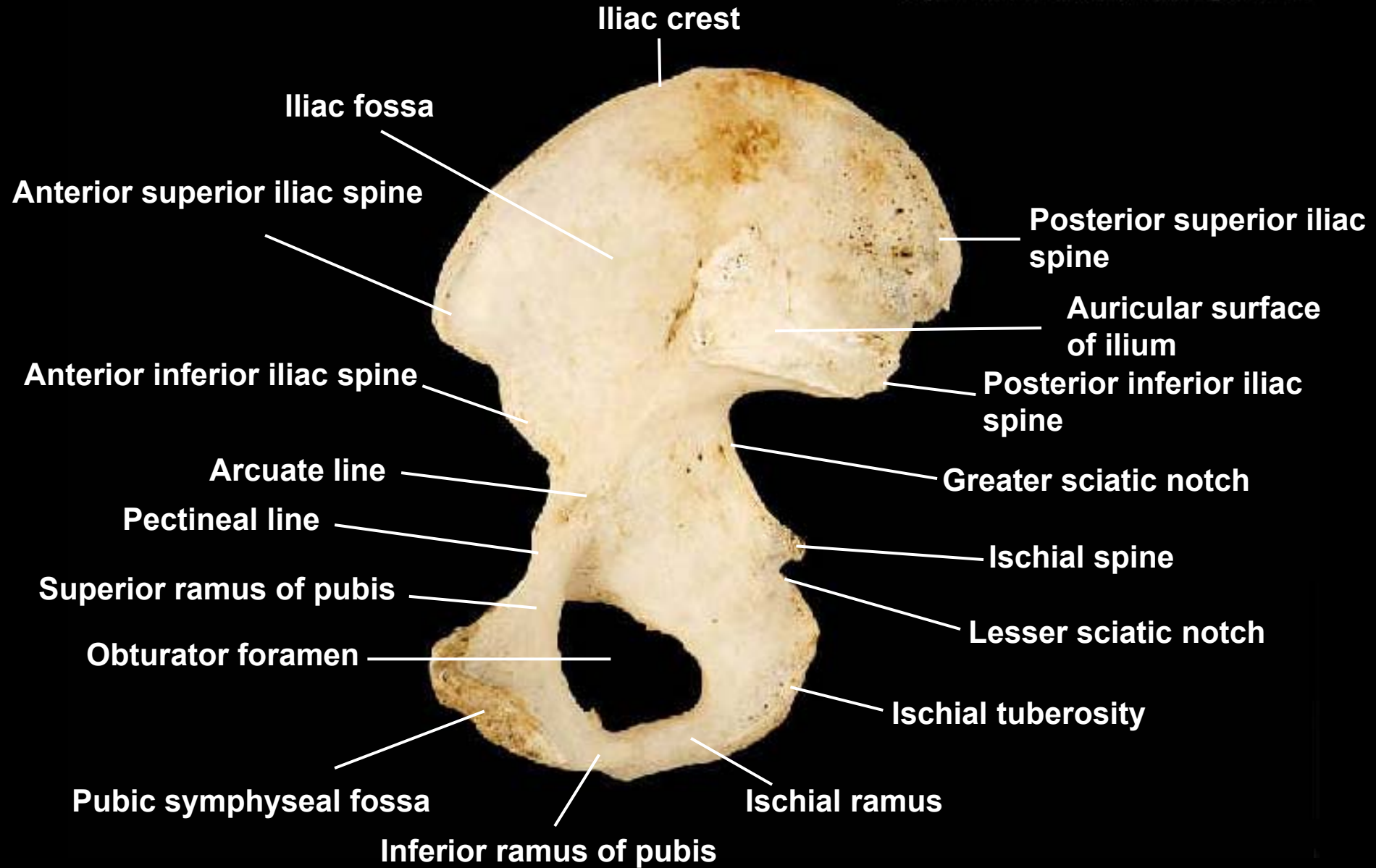
Hip bone, posteromedial view, right side



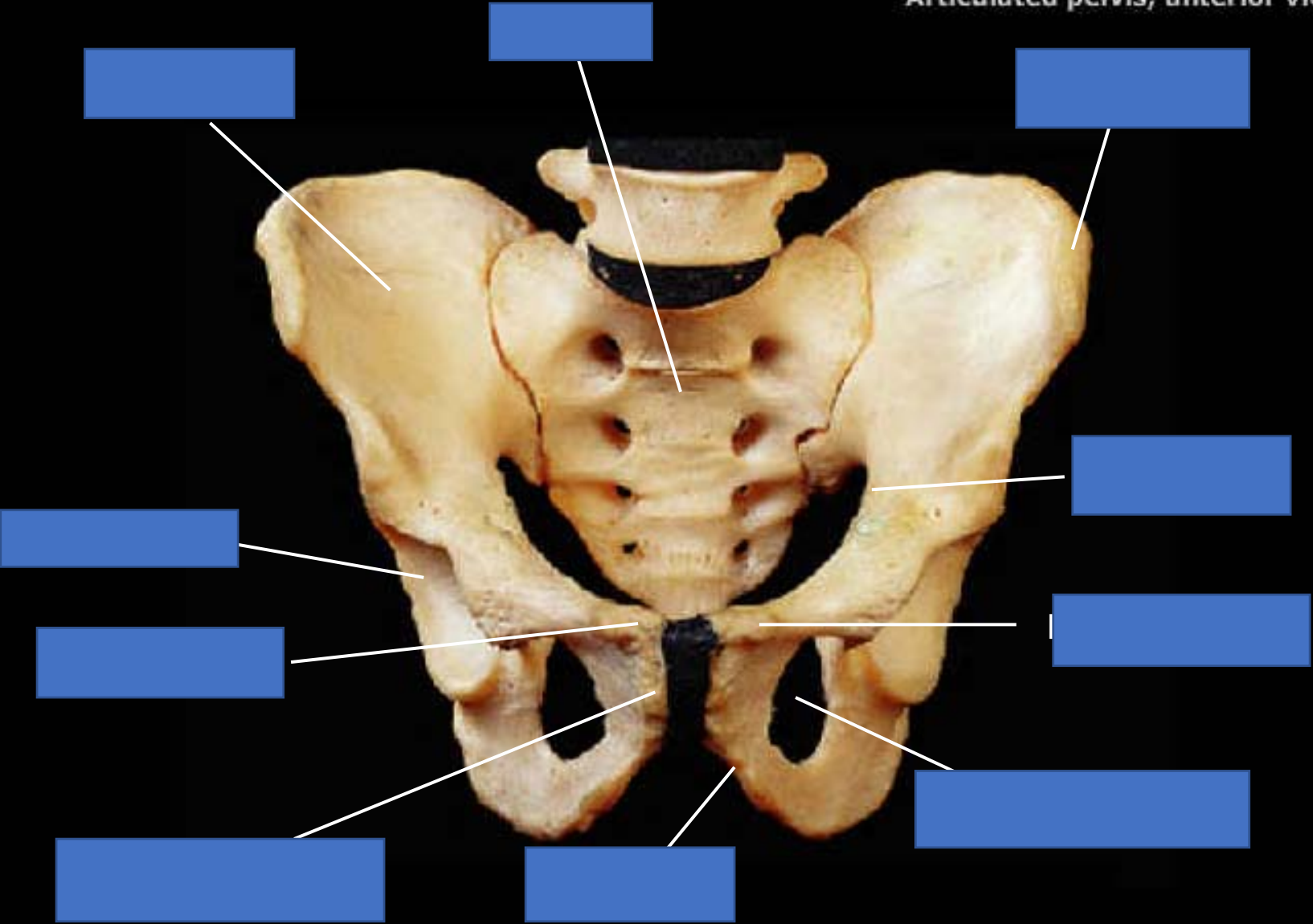
Hip bone, medial view, right side



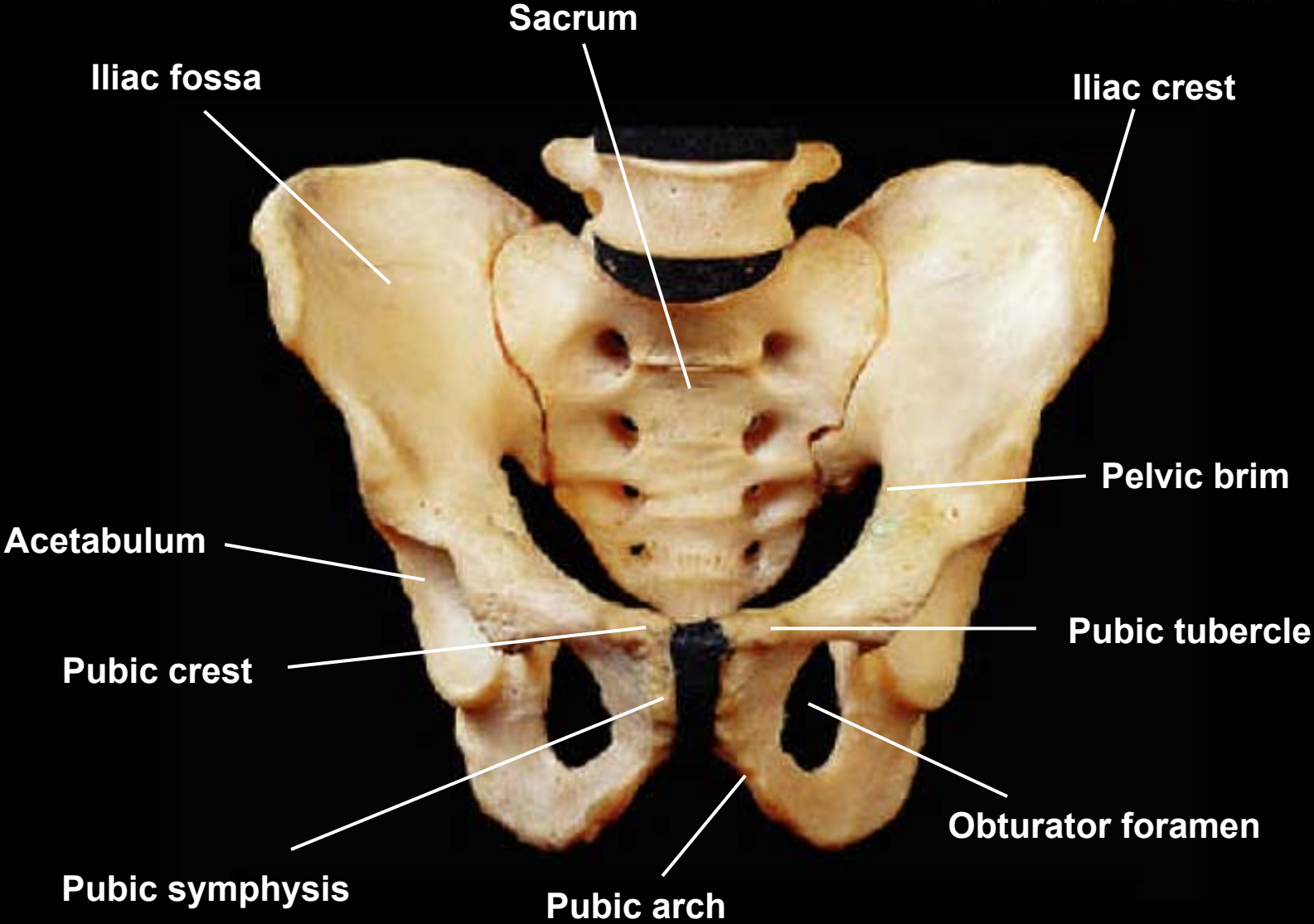
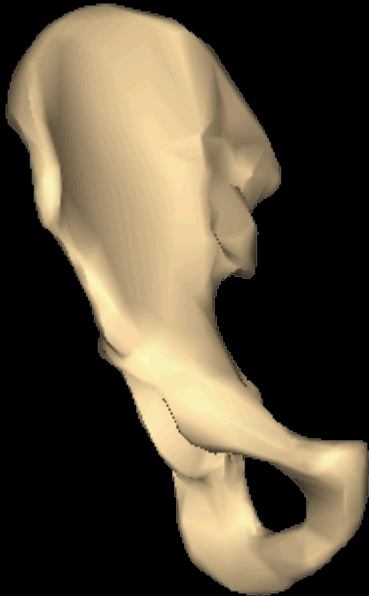Hip bone, medial view, right side



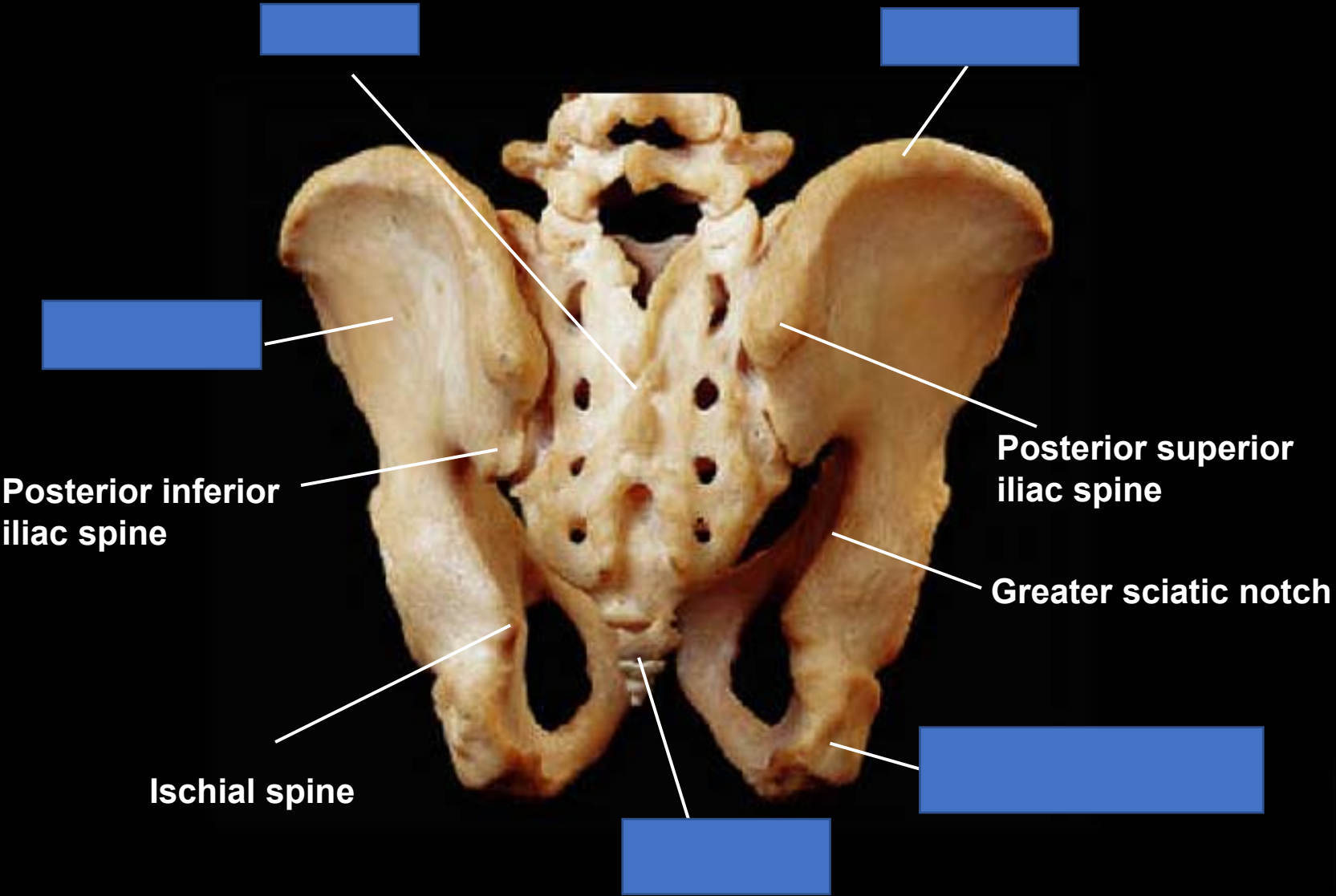
Articulated pelvis, anterior view



Articulated pelvis, anterior view



Articulated pelvis, posterior view



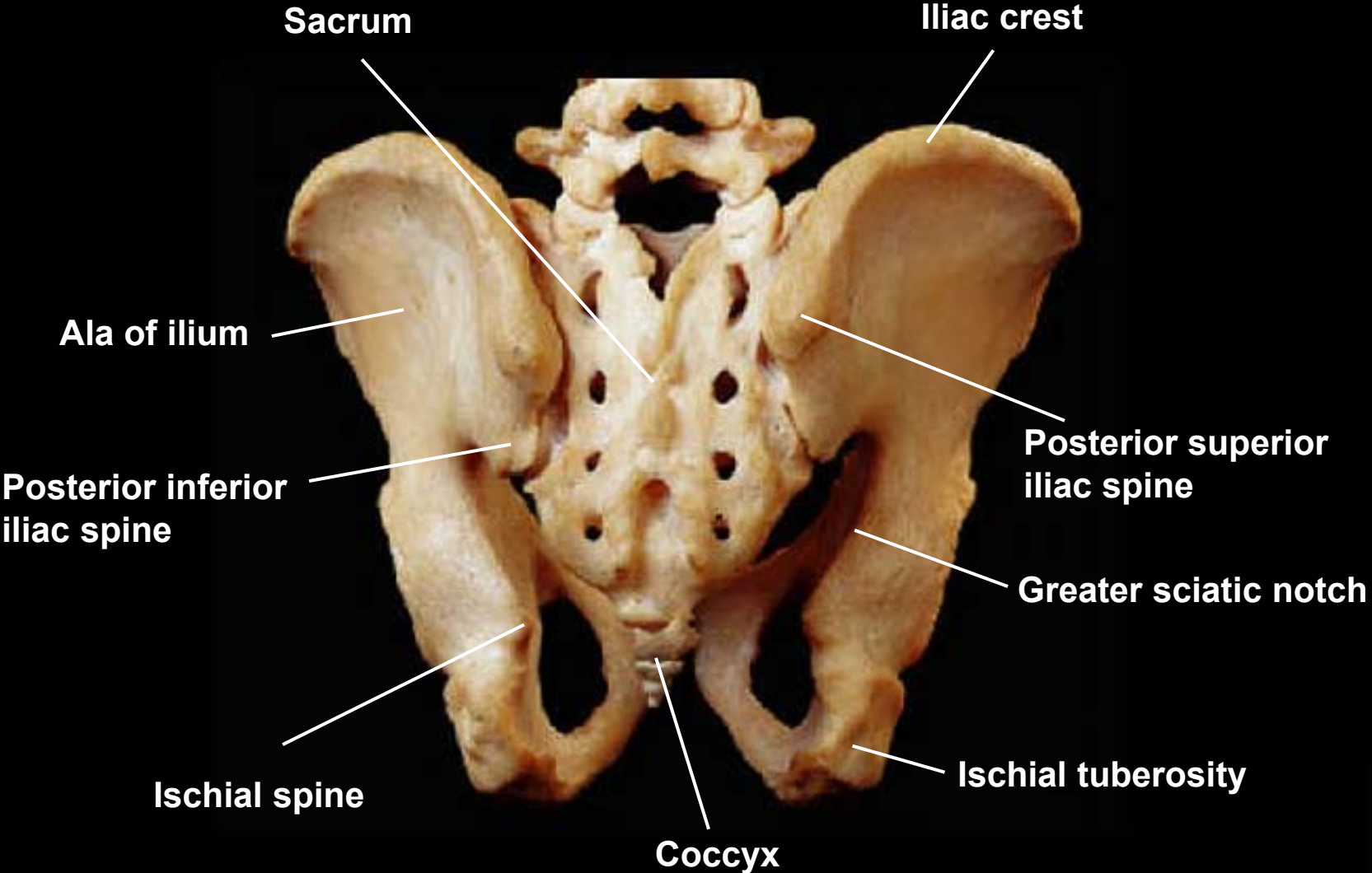
Posterior inferior iliac spine

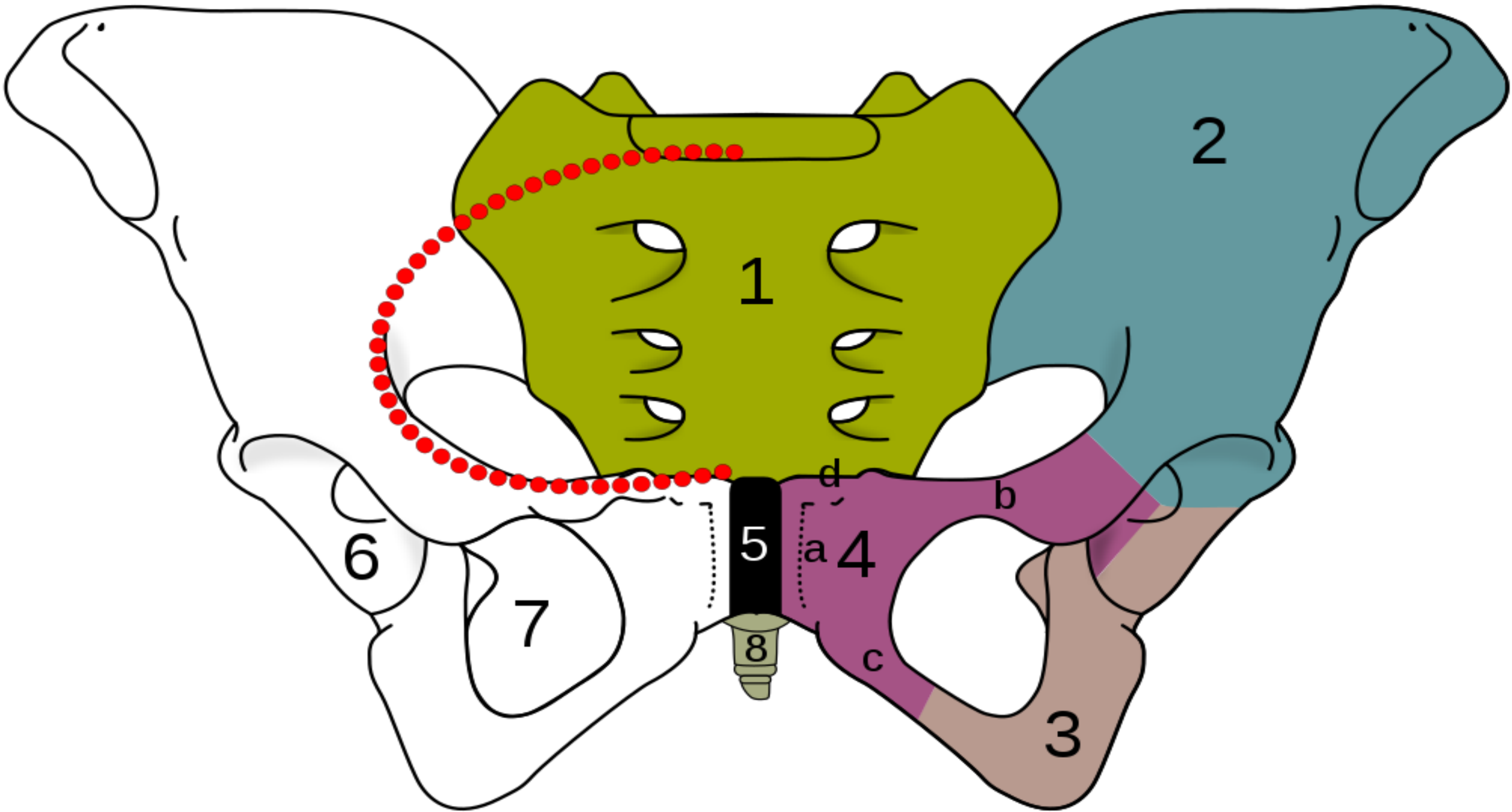
Ischial spine

Posterior superior iliac spine

Greater sciatic notch

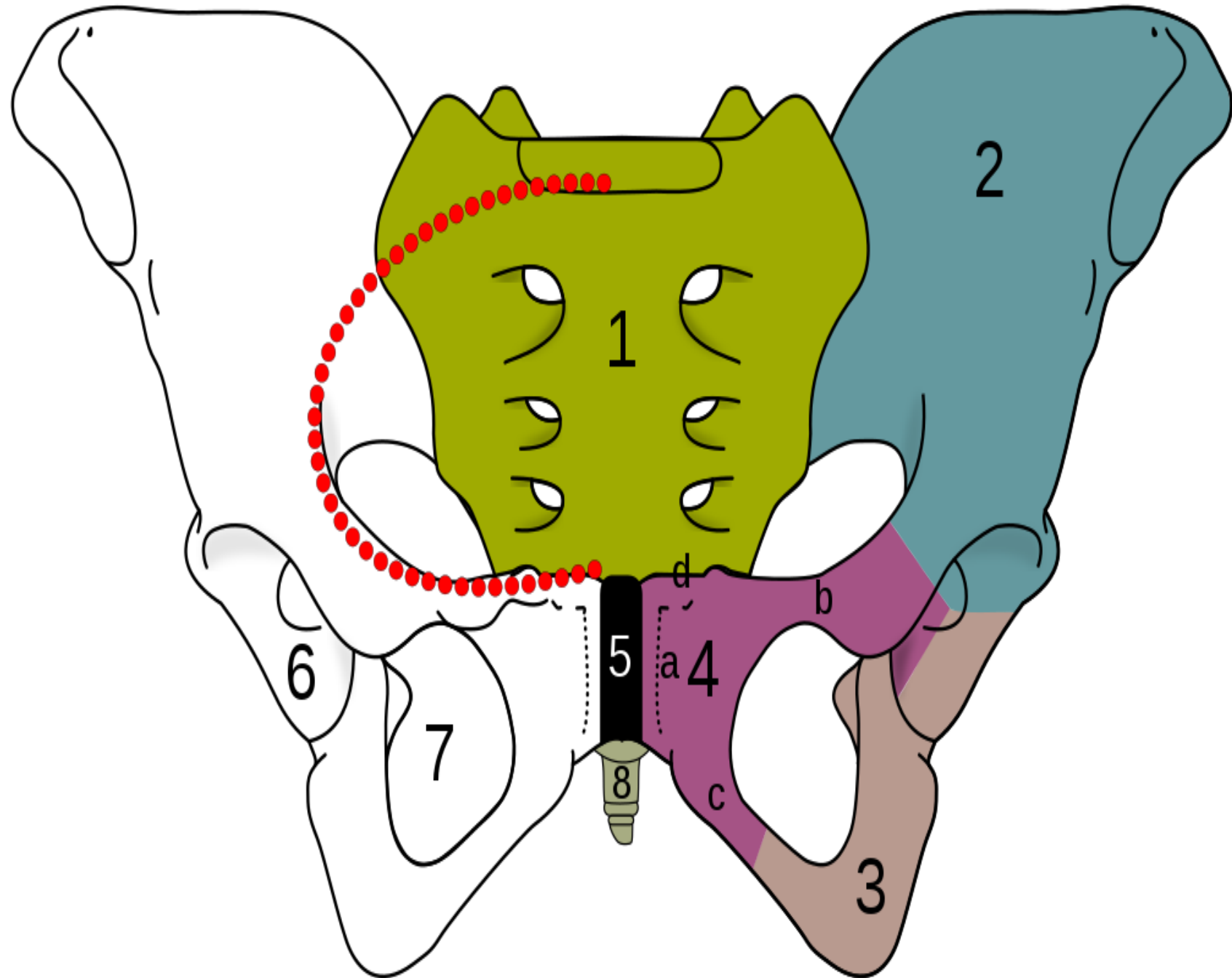
Articulated pelvis, posterior view

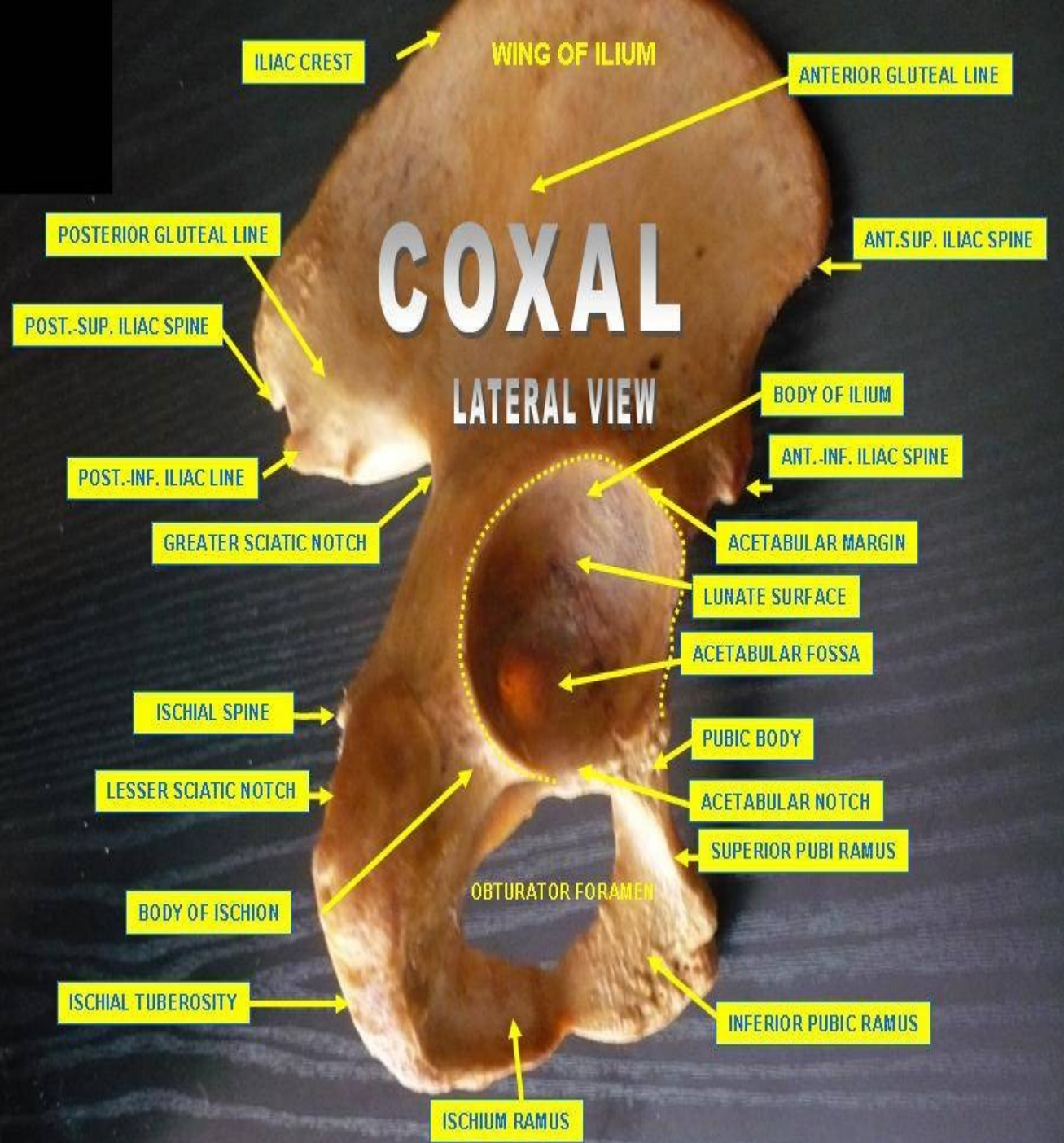
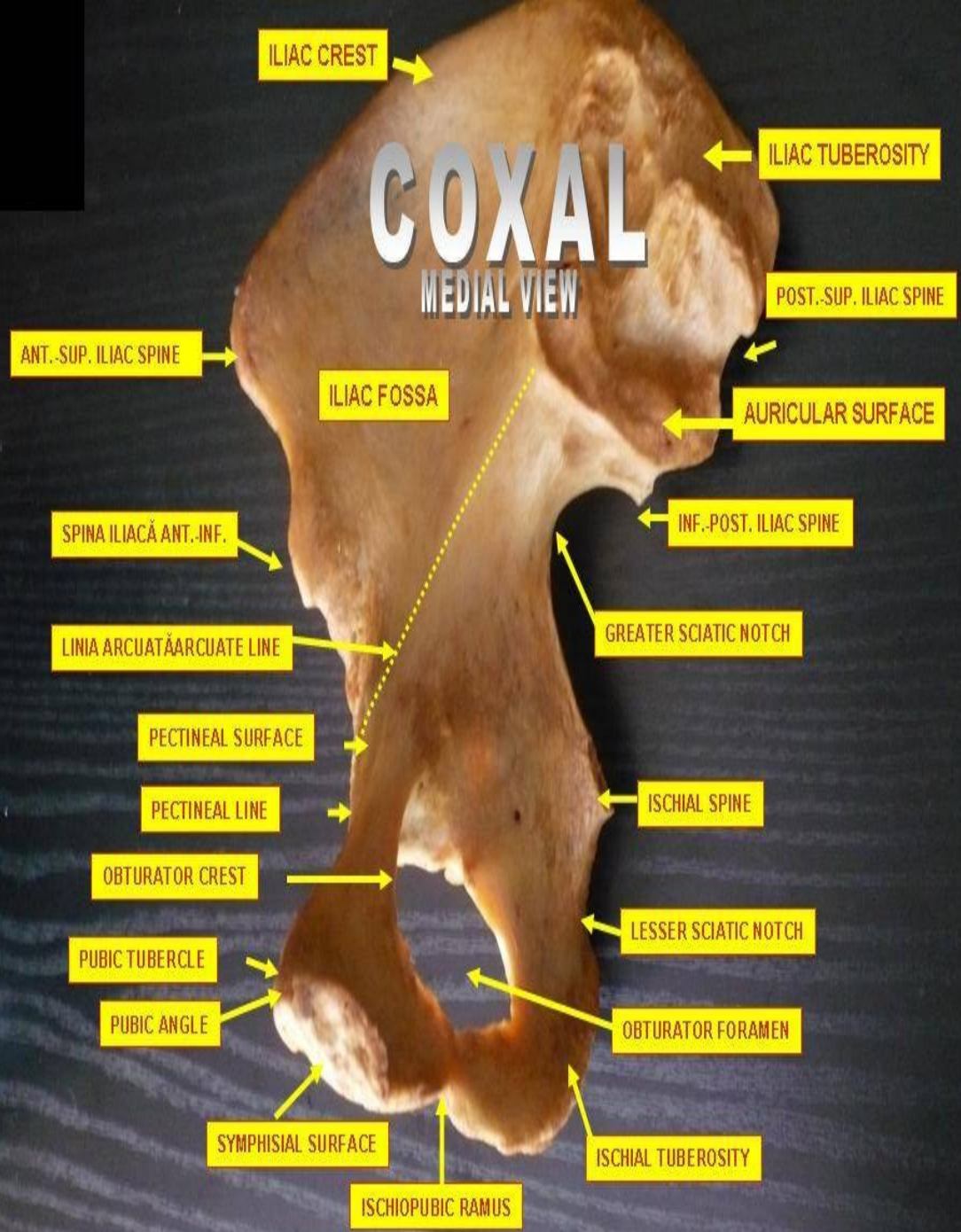



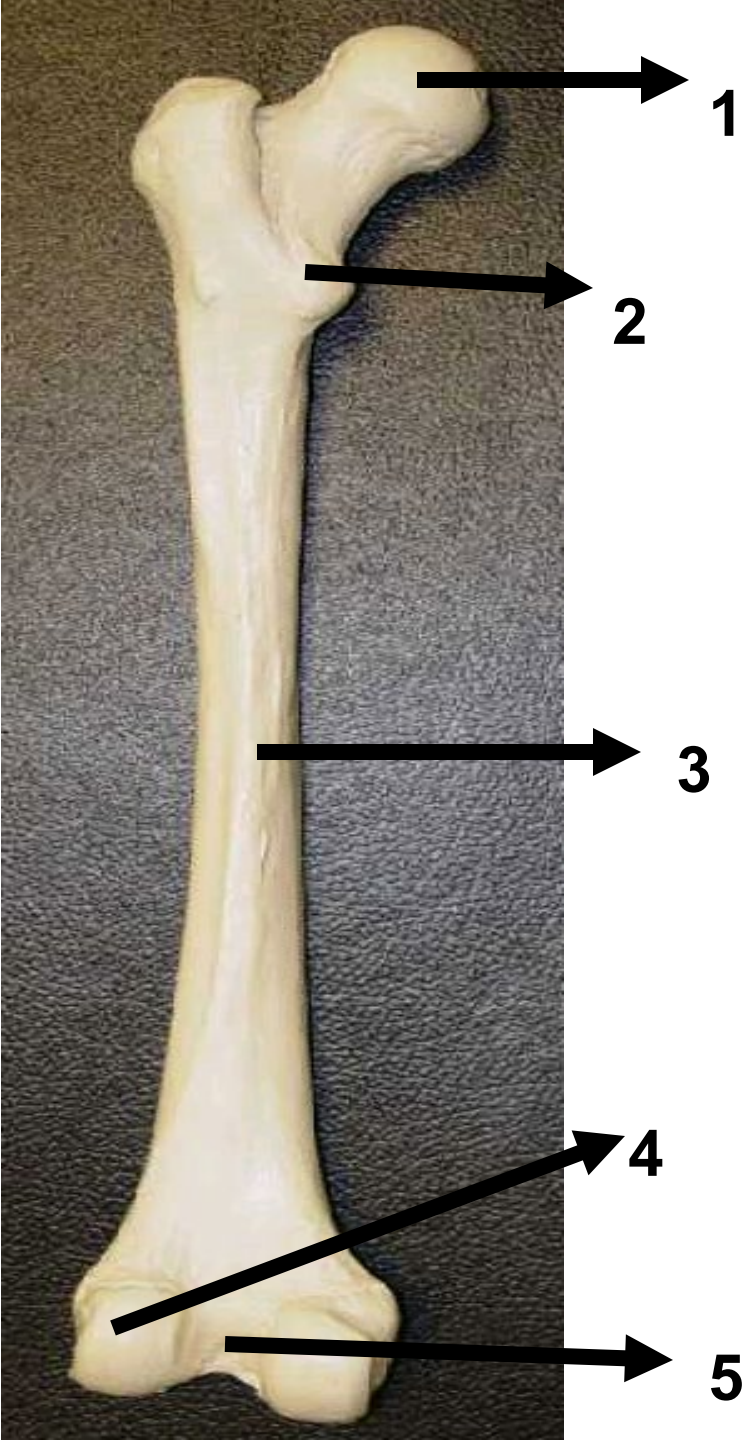
The skeleton of the human pelvis:

- 2-4. Hip bone (**os coxae**)
1. Sacrum (**os sacrum**),
 2. Ilium (os ilium),
 3. Ischium (os ischii)
 4. Pubic bone (**os pubis**) (4a. corpus, 4b. ramus superior, 4c. ramus inferior, 4d. tuberculum pubicum)
 5. Pubic symphysis,
 6. Acetabulum (of the hip joint),
 7. Foramen obturatum,
 8. Coccyx/tailbone (os coccygis)
- Dotted. Linea terminalis of the pelvic brim





Inferior appendages



What bone is this bone?

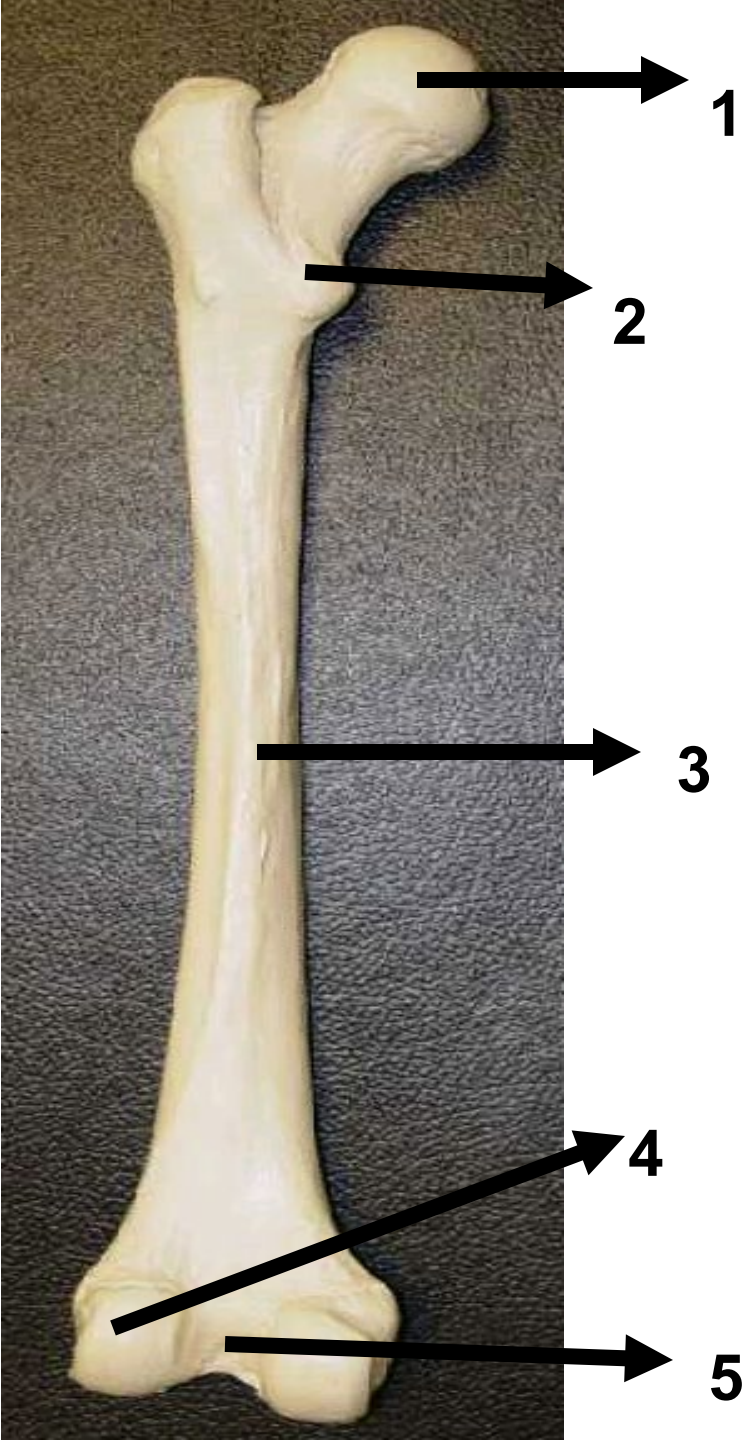
What side is this bone from?

Identify the area #1

Identify the area #2

Identify area #4

Identify area #5



What bone is this bone? femur

What side is this bone from? left

Identify the area #1 head

Identify the area #2 Lesser Trochanter

Identify area #3 lateral condyle

Identify area # 5 intercondylar notch ,medial condyle fossa



Name this bone?

What articulation this bone has in its proximal surface?



Name this bone? fibula

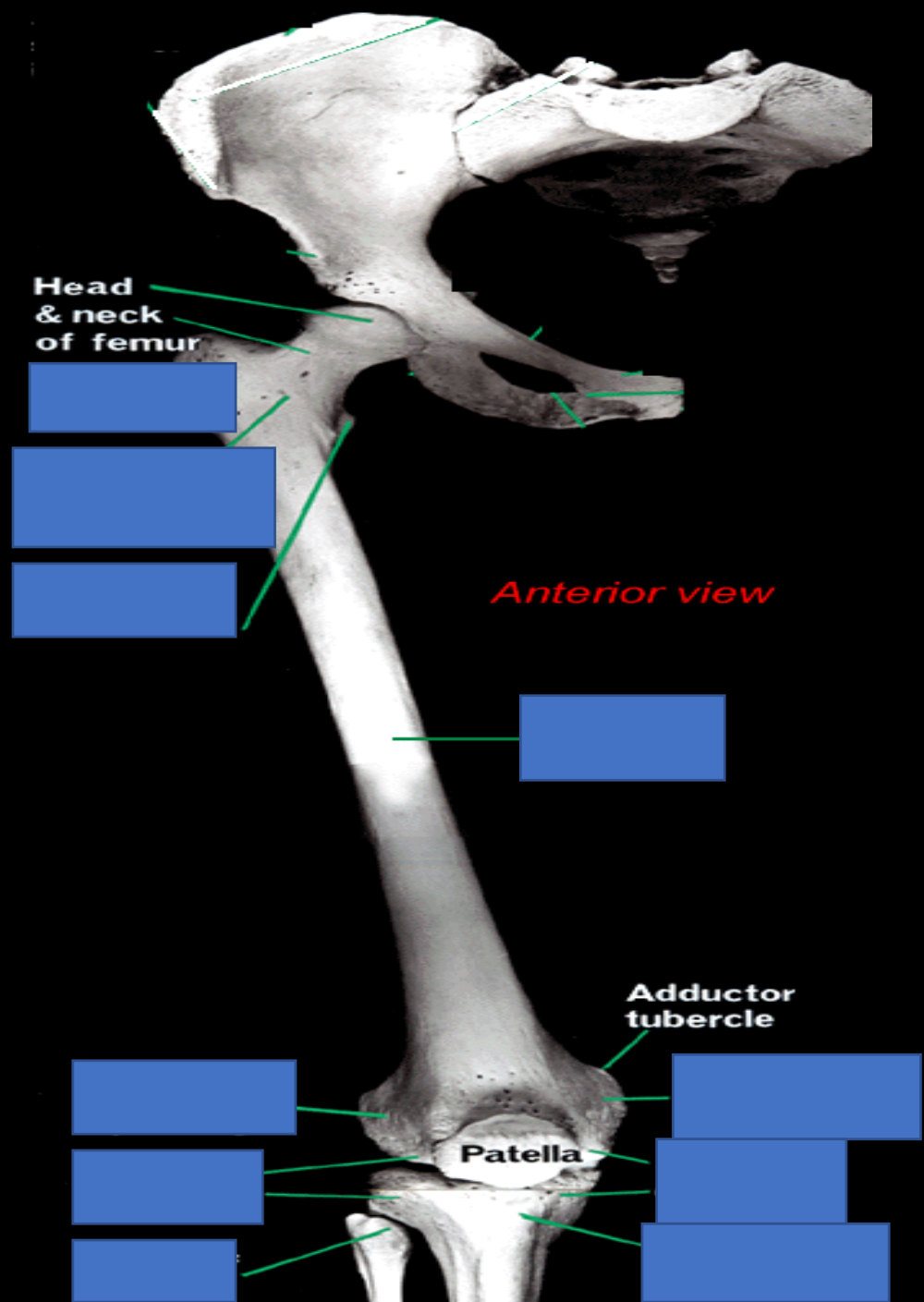
What articulation this bone has in its proximal surface? tibia

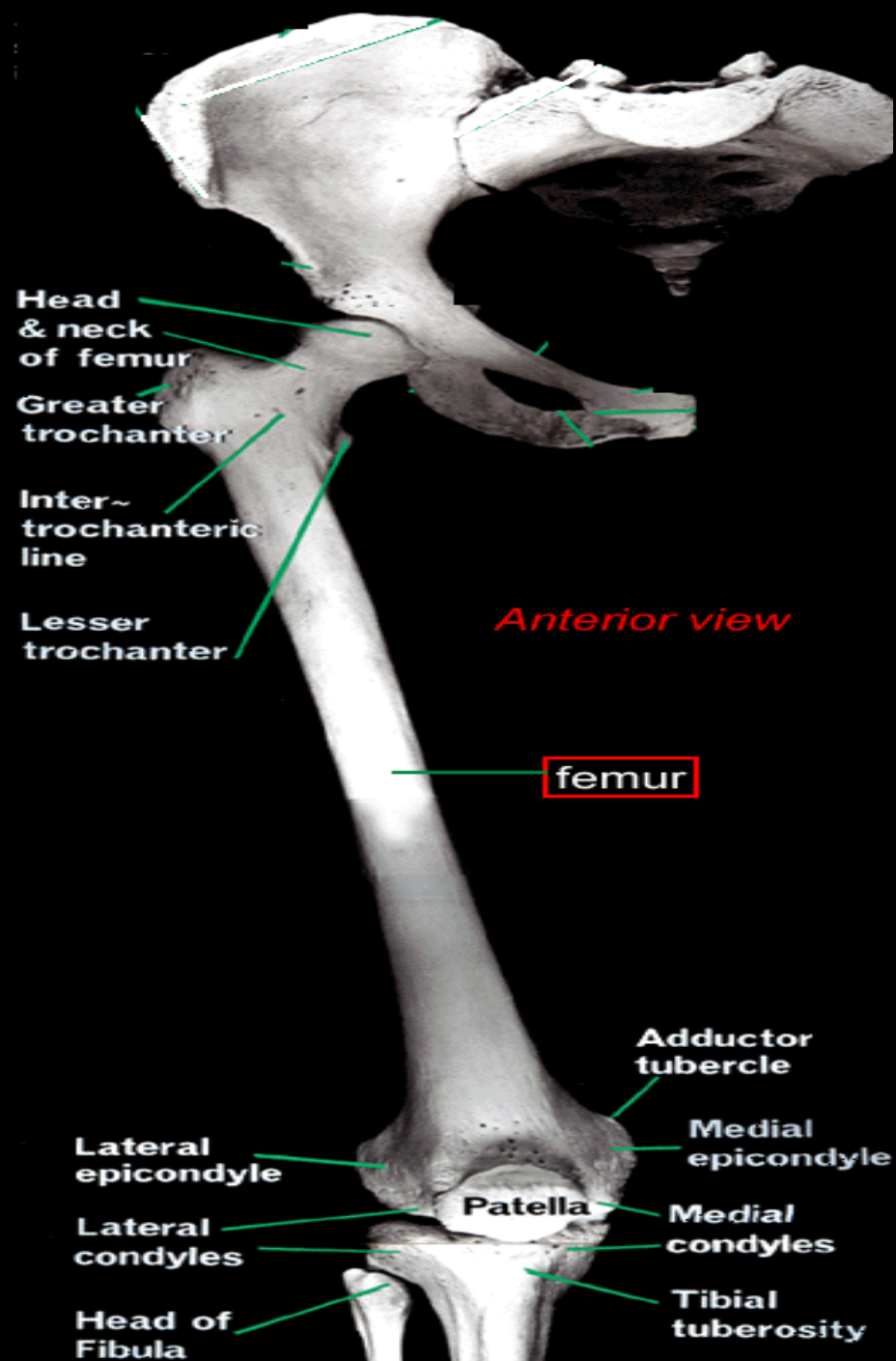


IDENTIFY THIS
BONE?



IDENTIFY THIS
BONE? TIBIA





Head & neck of femur

Greater trochanter

Inter-trochanteric line

Lesser trochanter

Anterior view

femur

Lateral epicondyle

Lateral condyles

Head of Fibula

Adductor tubercle

Medial epicondyle

Medial condyles

Tibial tuberosity

Patella

Trochanteric fossa



Quadrato tubercle



Inter-trochanteric crest

Pectineal line
Spiral line



Posterior view

femur



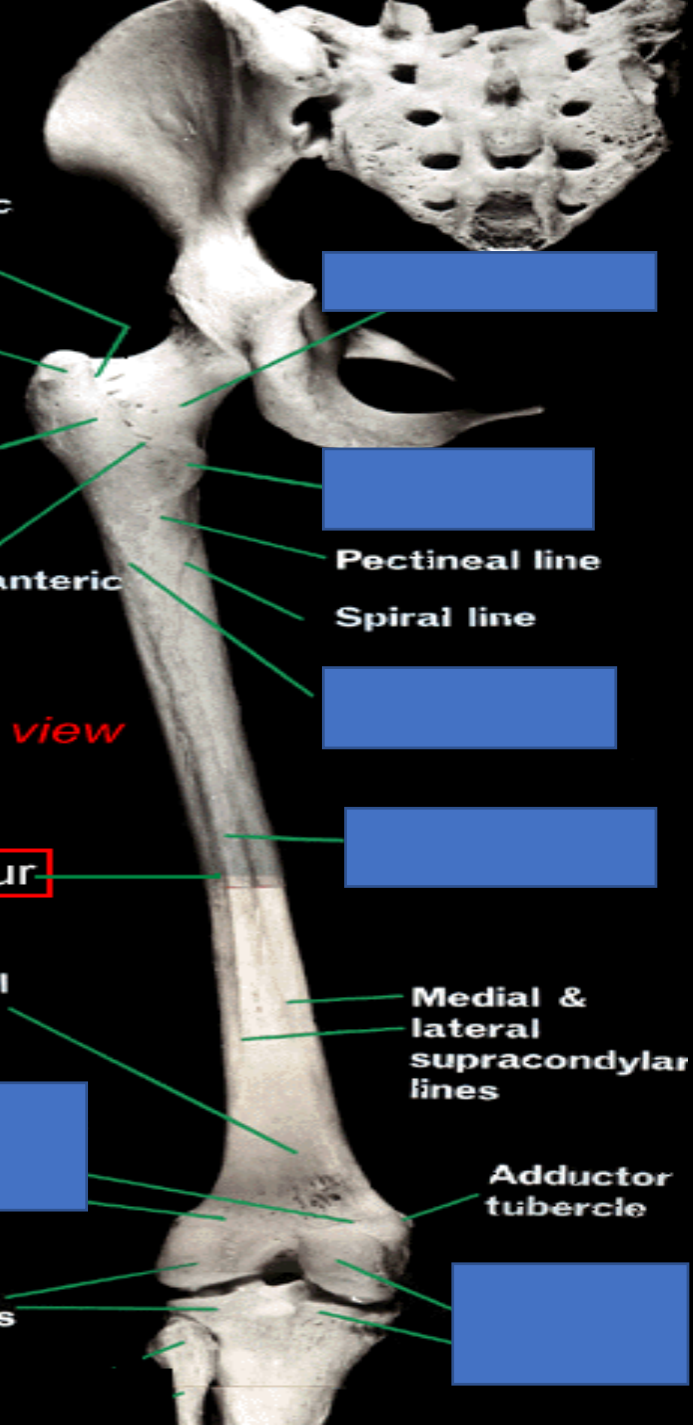
Popliteal surface

Medial & lateral supracondylar lines



Adductor tubercle

Lateral condyles



Trochanteric fossa

Greater trochanter

Quadratus tubercle

Inter-trochanteric crest

Neck of femur

Lesser trochanter

Pectineal line

Spiral line

Gluteal tuberosity

Posterior view

Linea aspera

femur

Popliteal surface

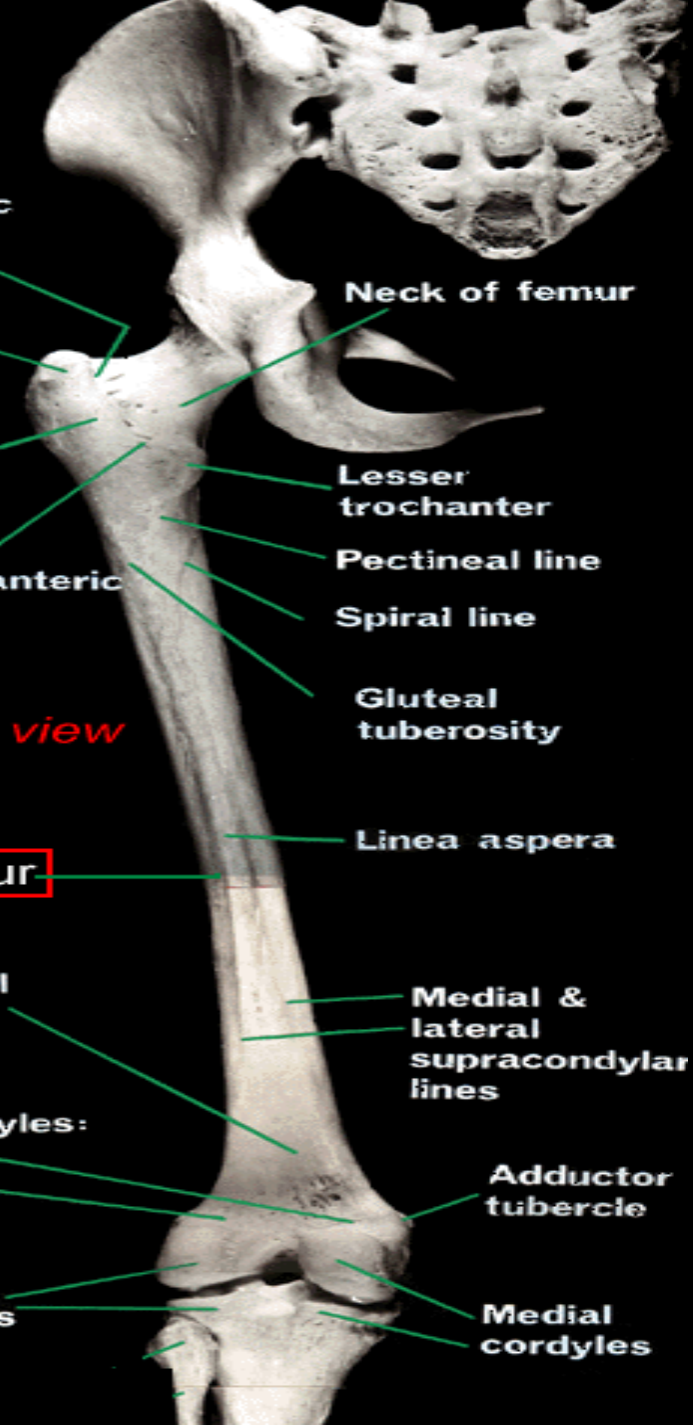
Medial & lateral supracondylar lines

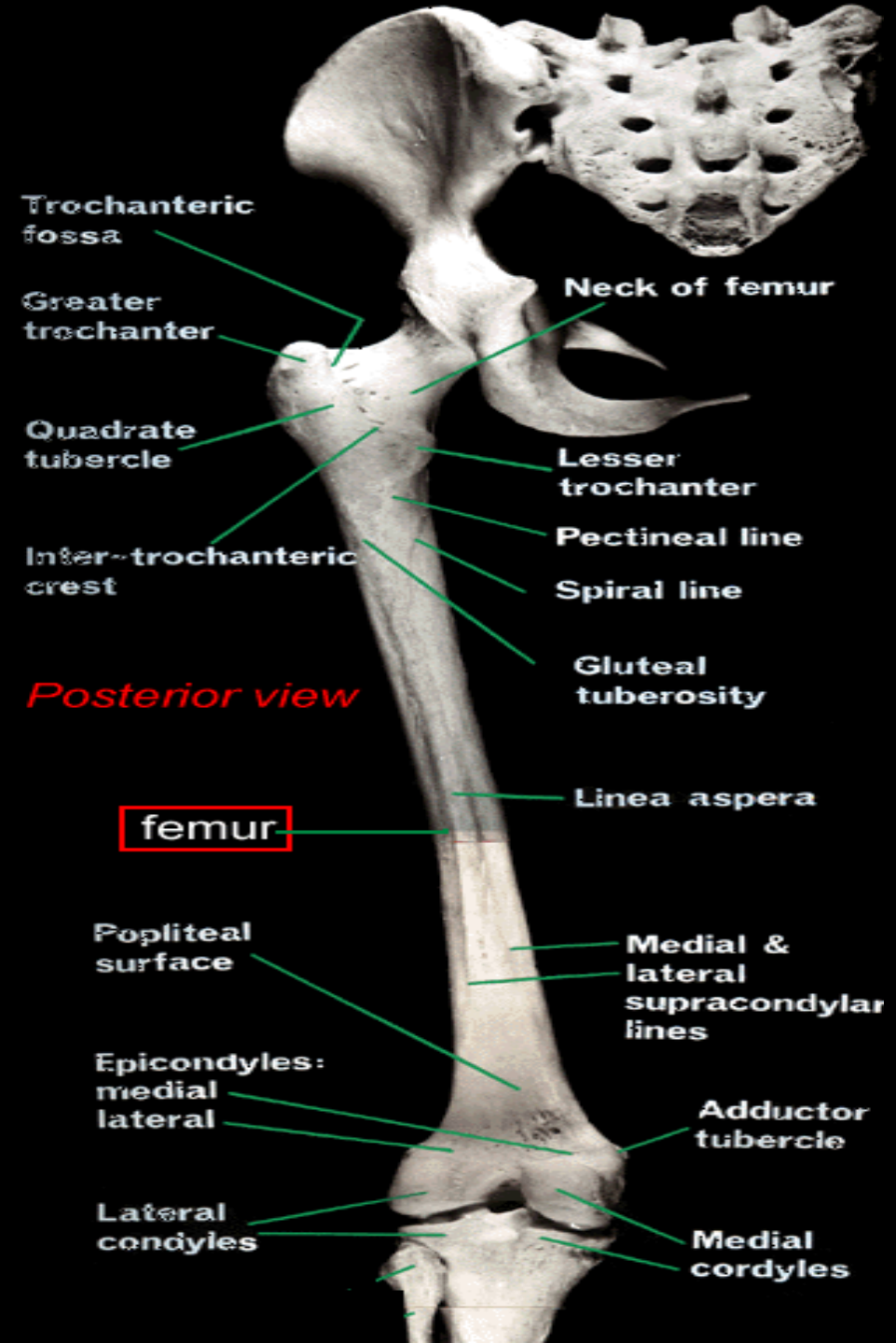
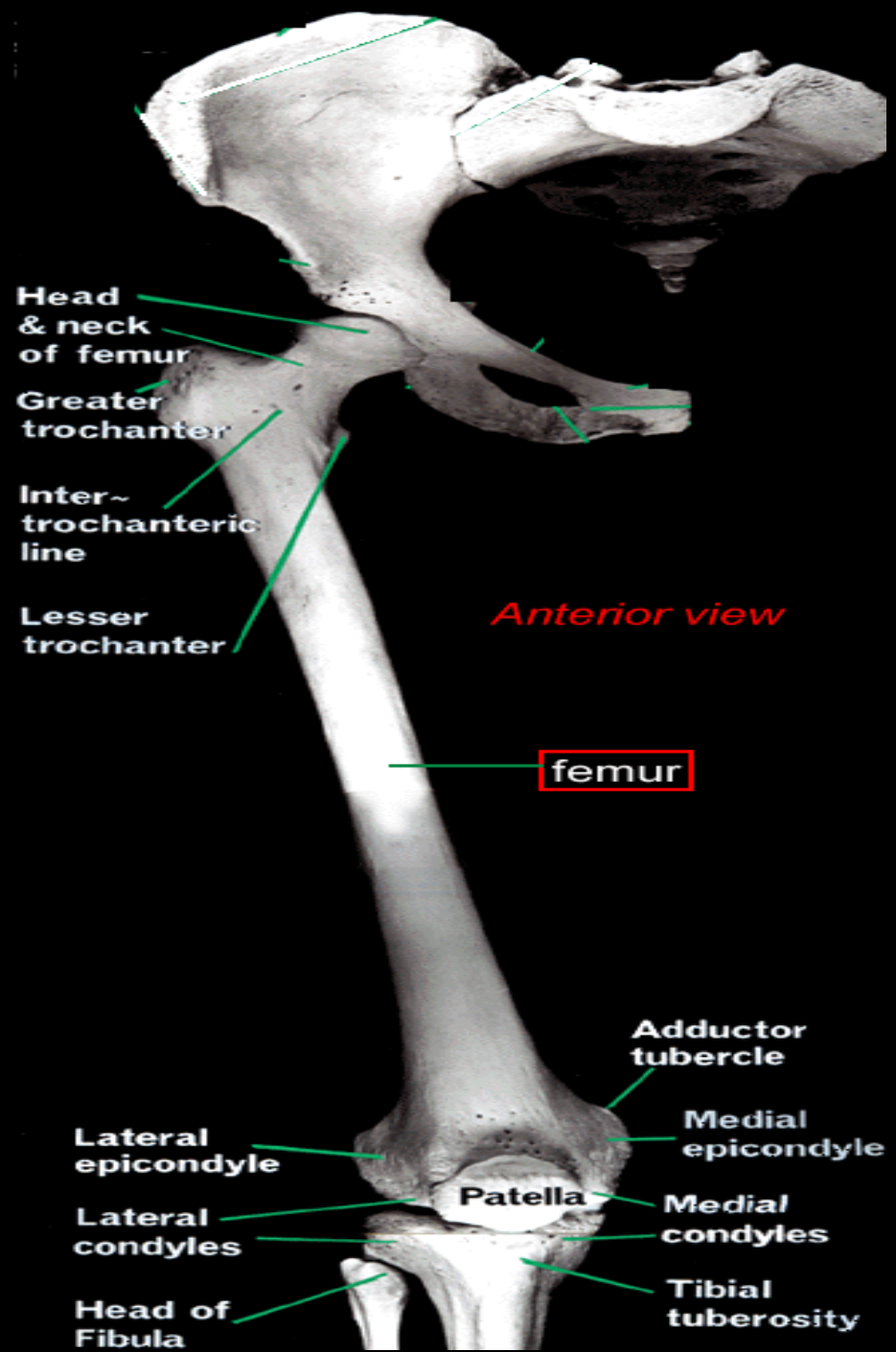
Epicondyles: medial lateral

Adductor tubercle

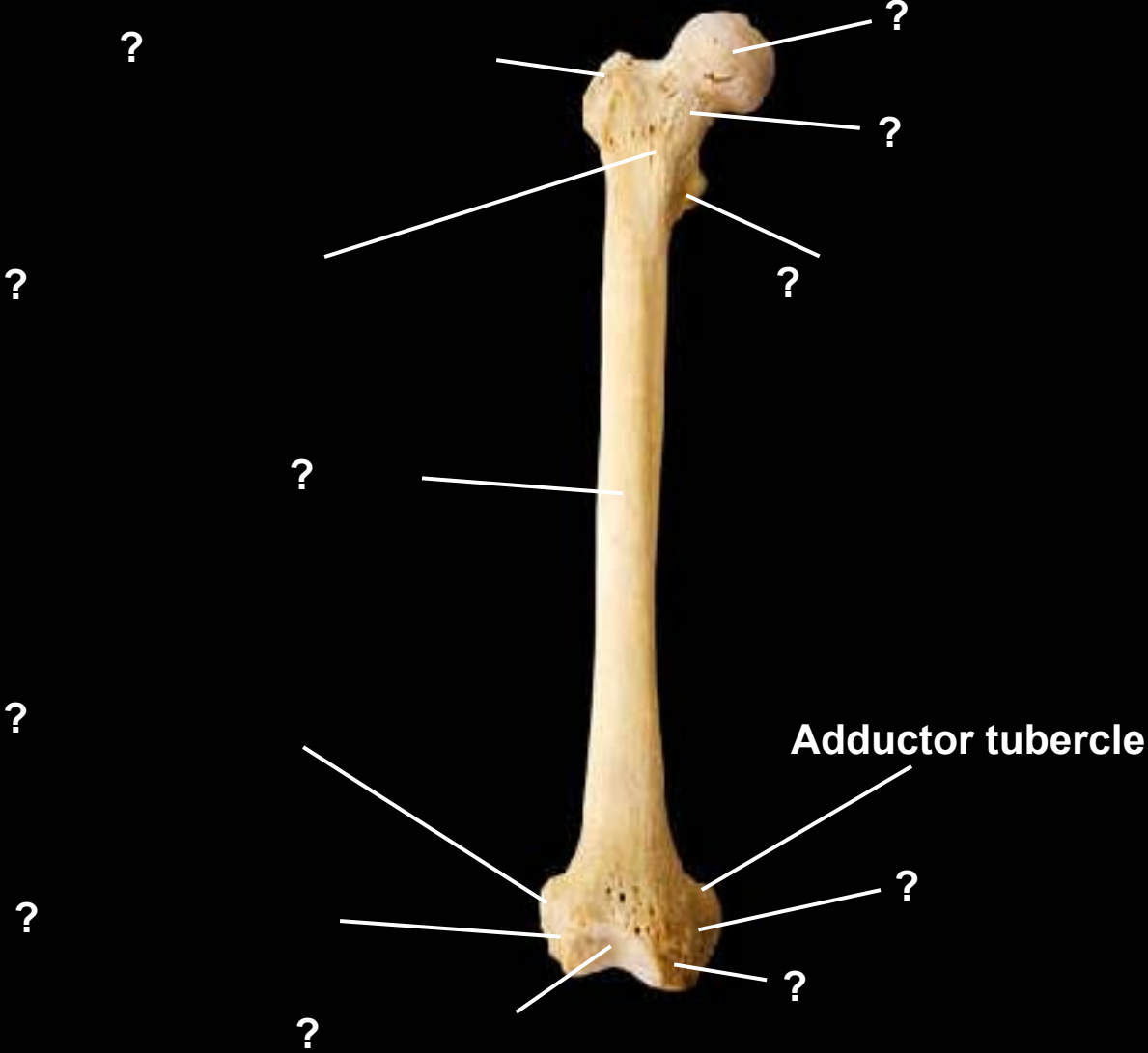
Lateral condyles

Medial condyles

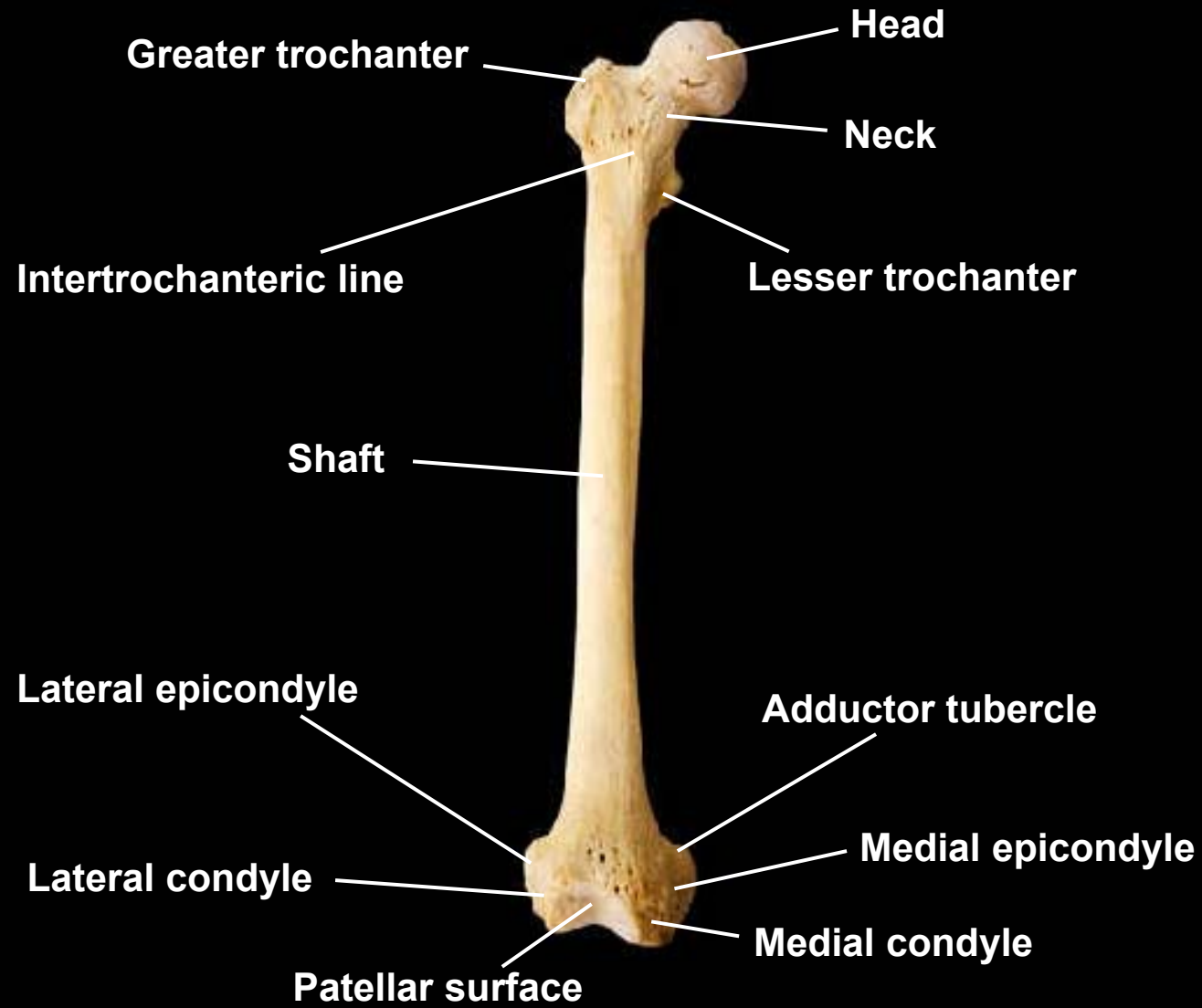


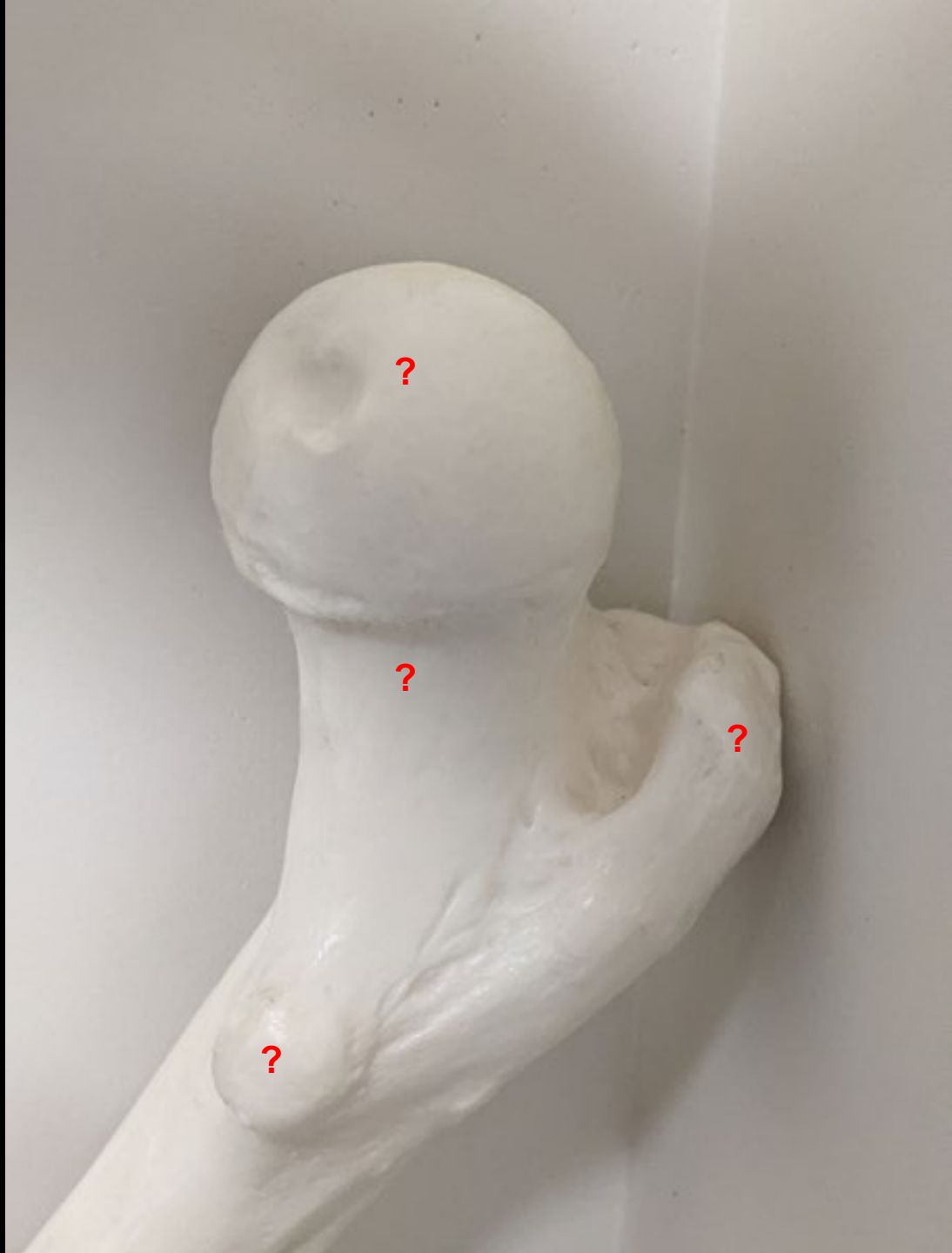

Femur, anterior view, right side



Femur, anterior view, right side





?

?

?

?




Head

Neck

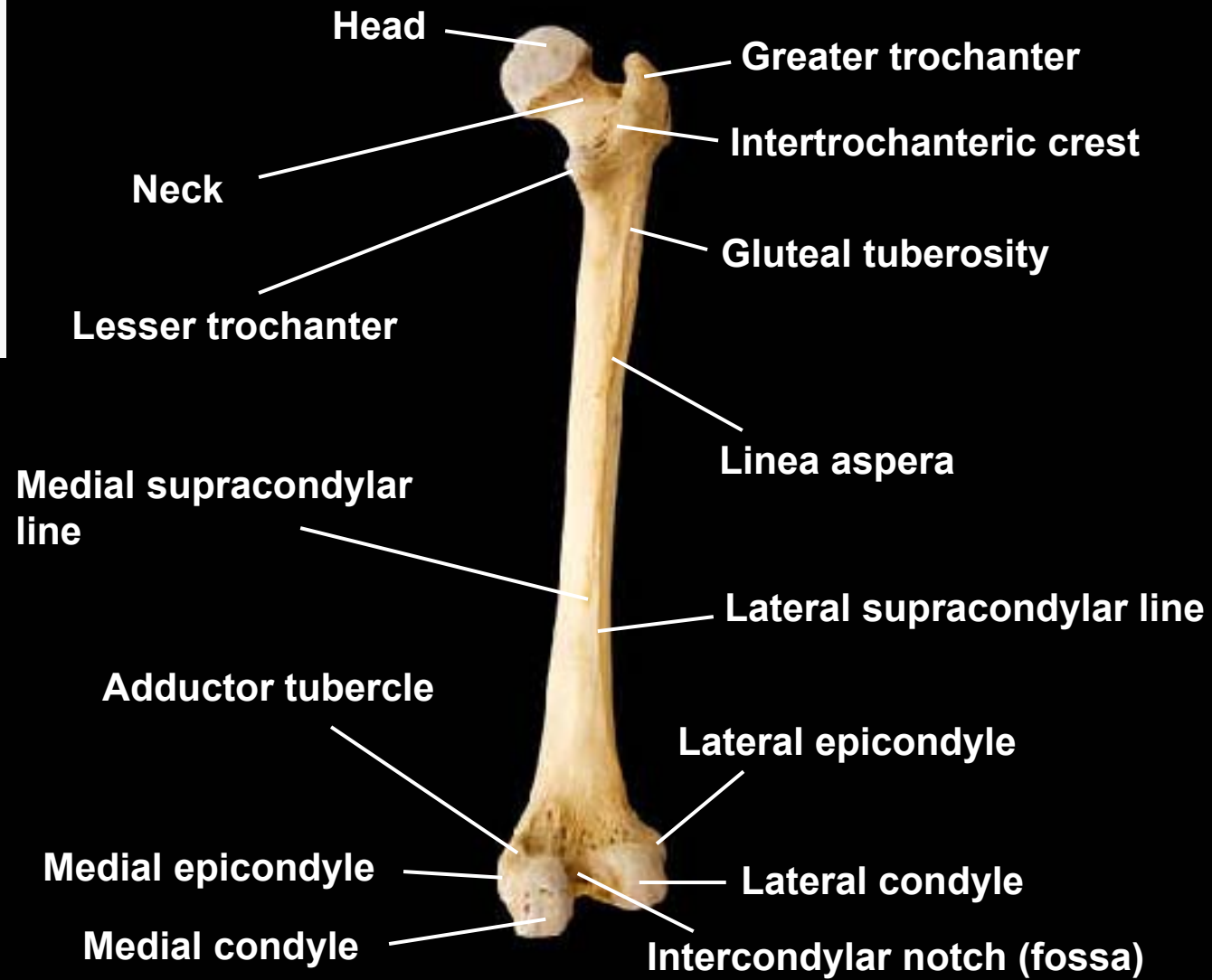

Greater trochanter

Lesser trochanter

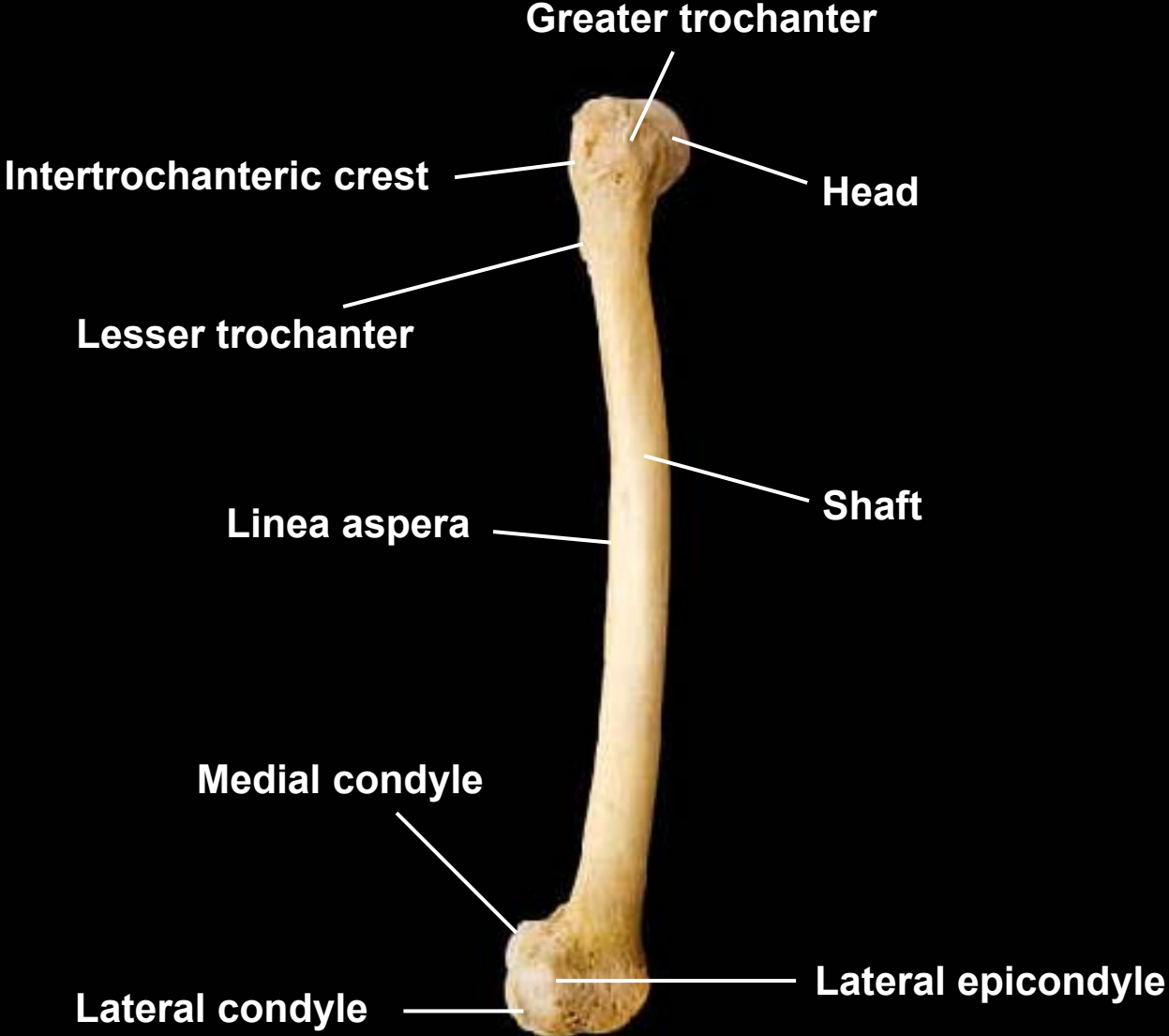
Femur, posterior view, right side



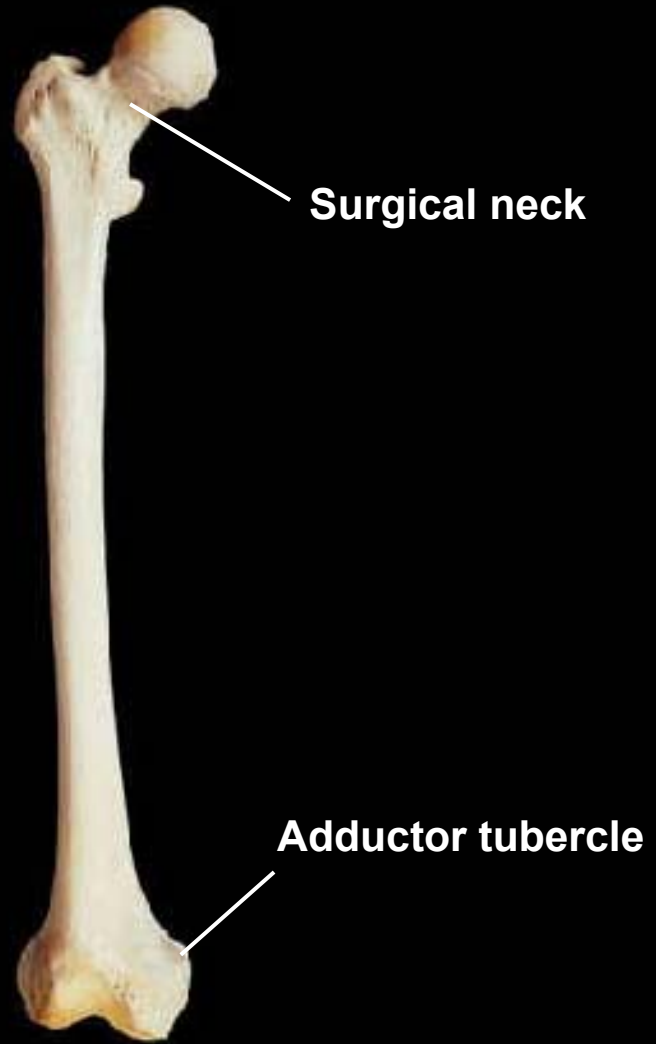
Femur, posterior view, right side



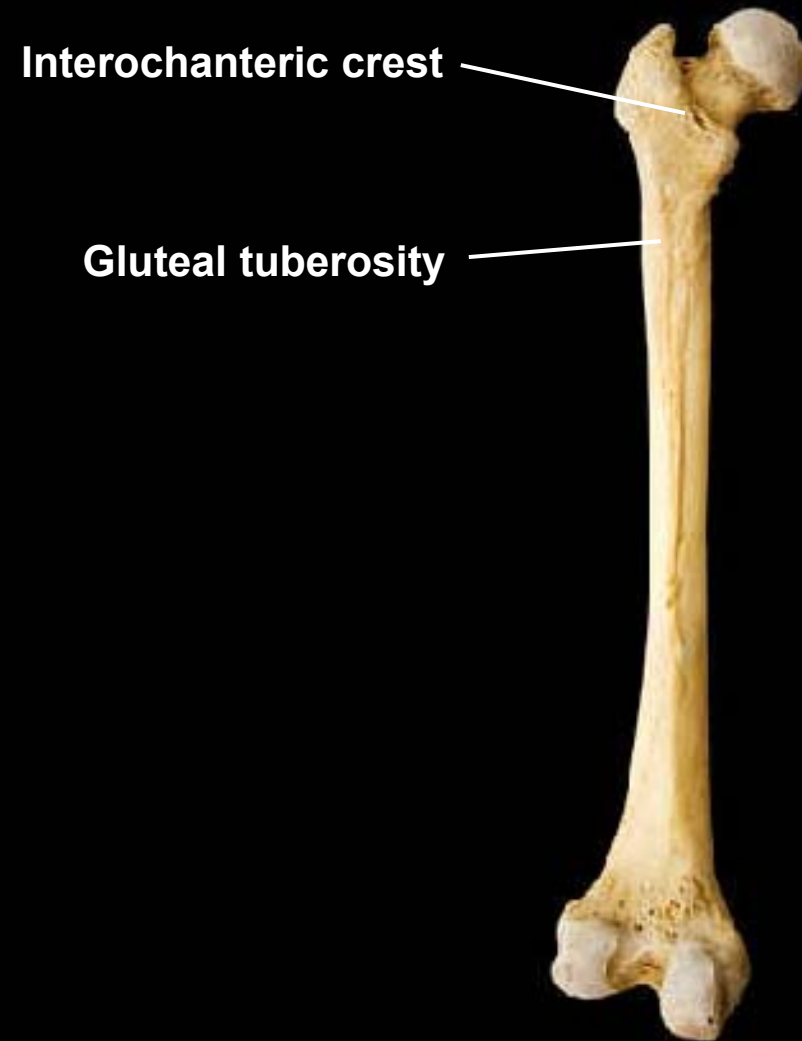
Femur, lateral view, right side



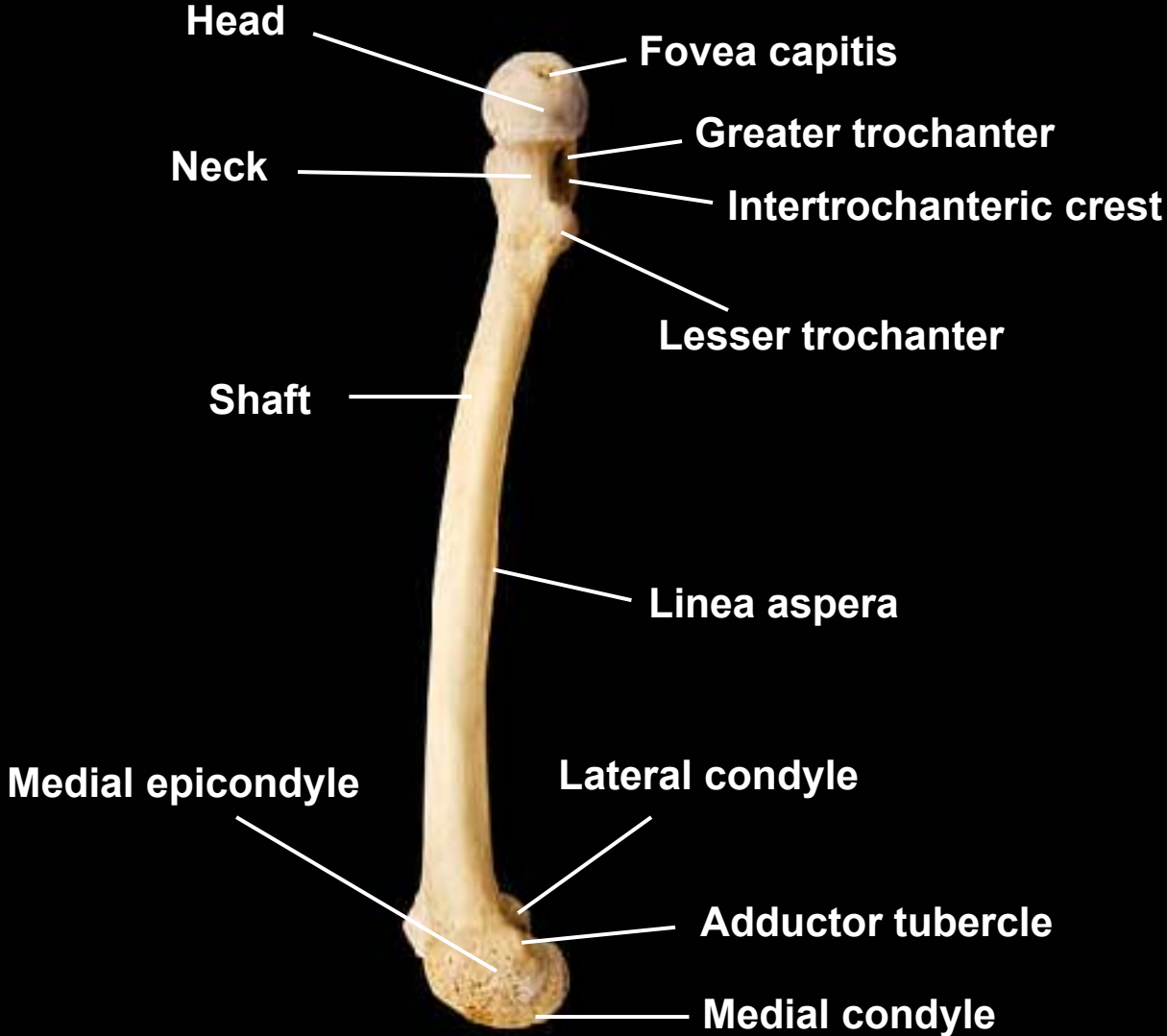
Femur, anterior view, right side



Femur, posterior view, left side



Femur, medial view, right side

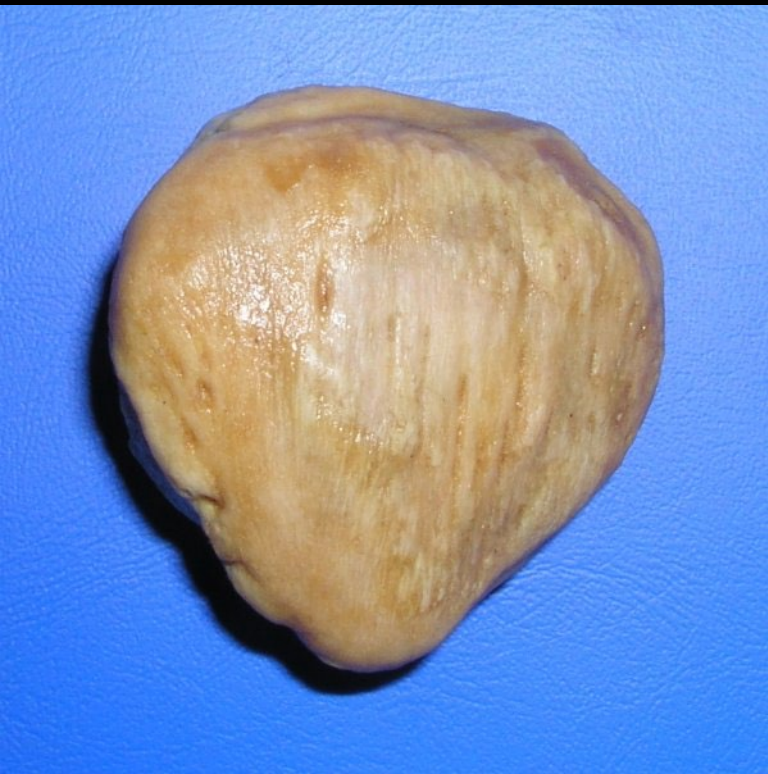

What bone this represents?

Base

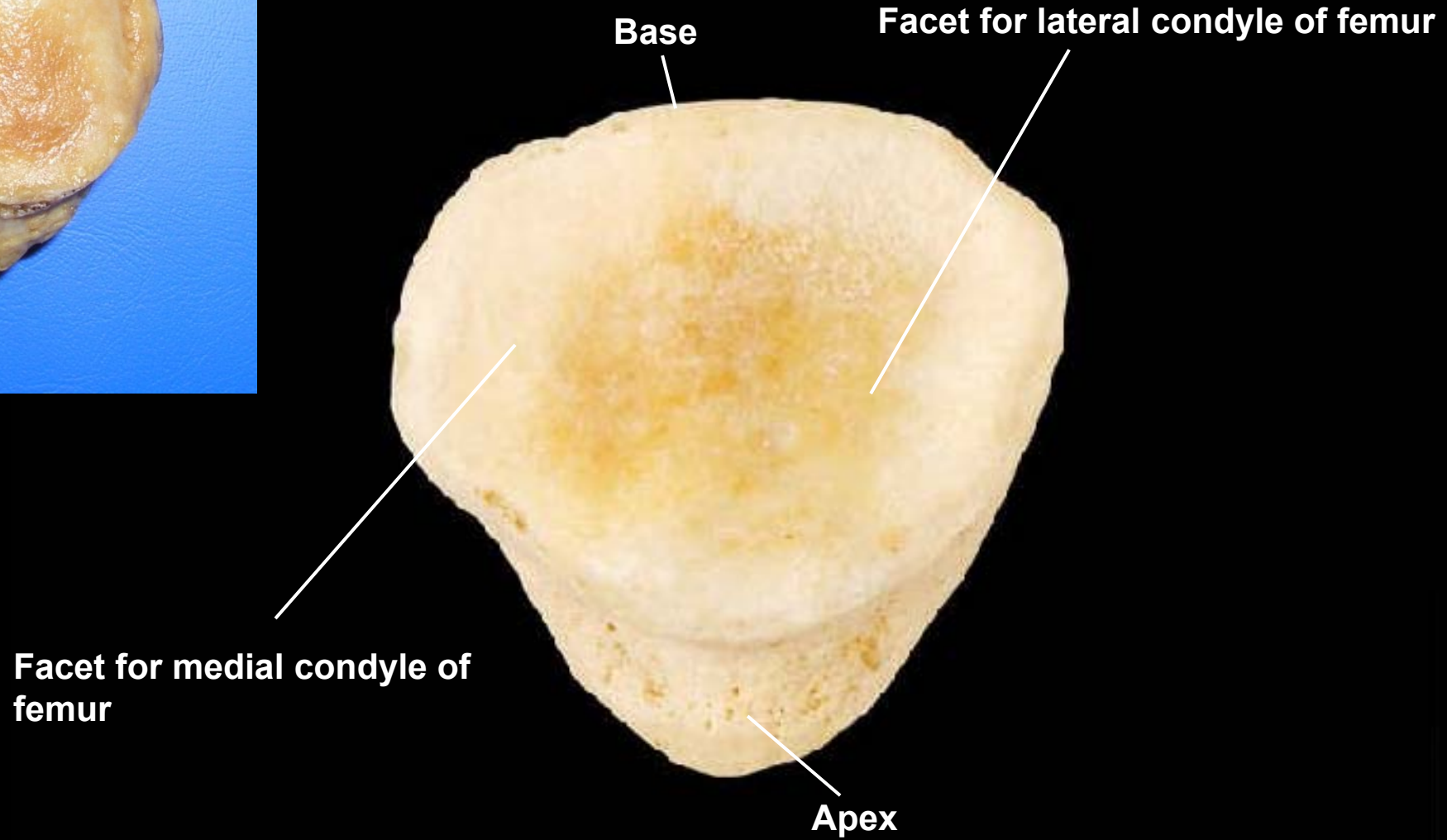


Apex





Patella, posterior view, right side



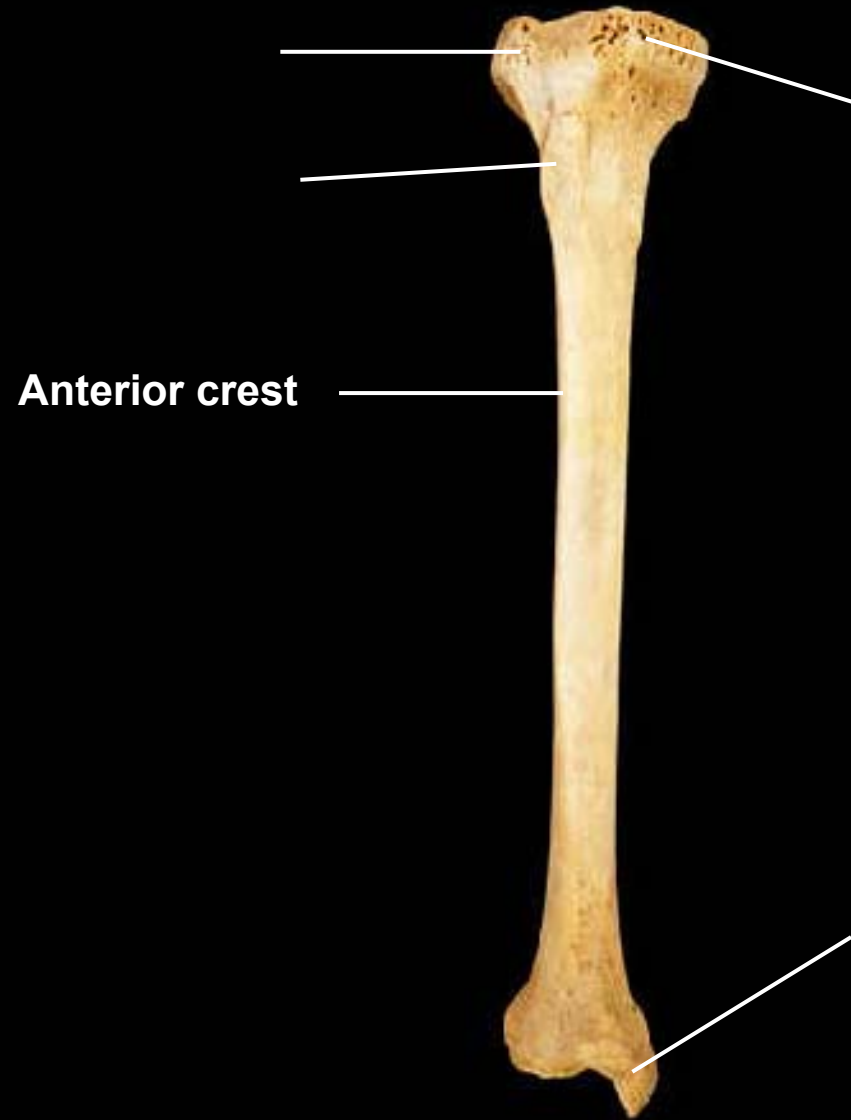
Base

Facet for lateral condyle of femur

Facet for medial condyle of femur

Apex

What bone this represents?



Tibia, anterior view, right side

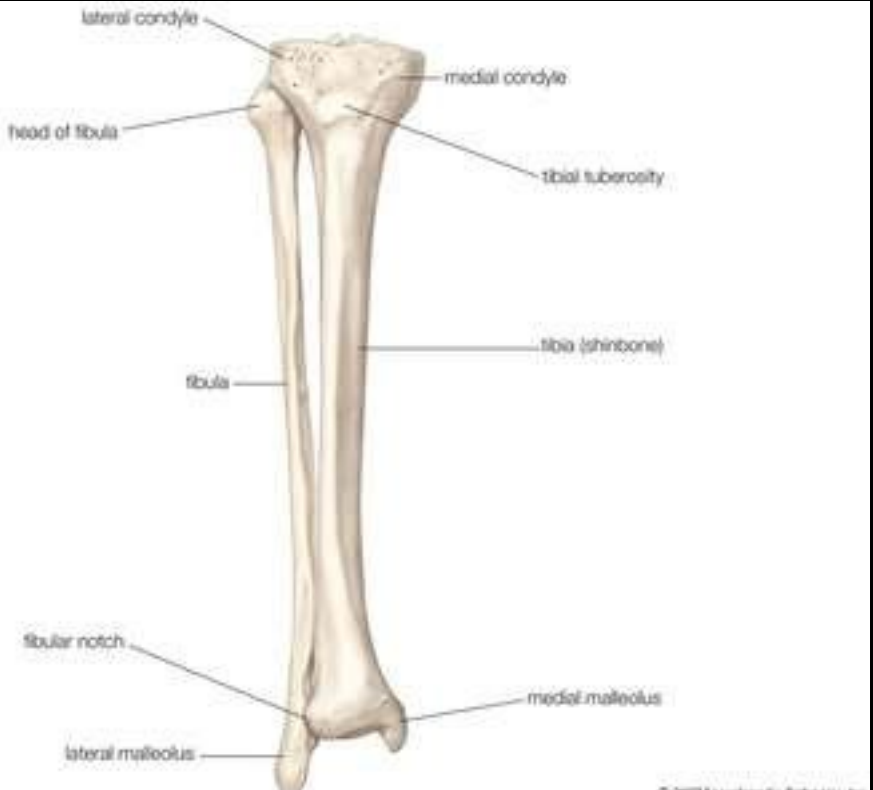Lateral condyle

Medial condyle

Tibial tuberosity

Anterior crest

Medial malleolus



Tibia, lateral view, right side

Lateral condyle

Articular facet for head of fibula

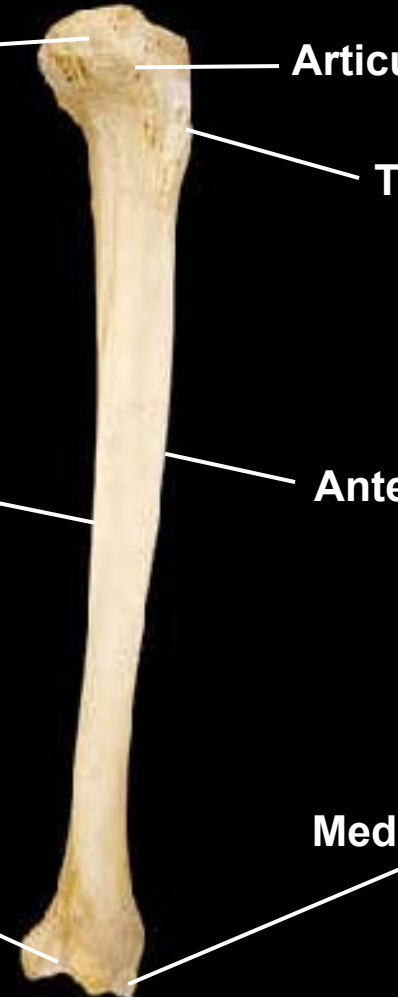
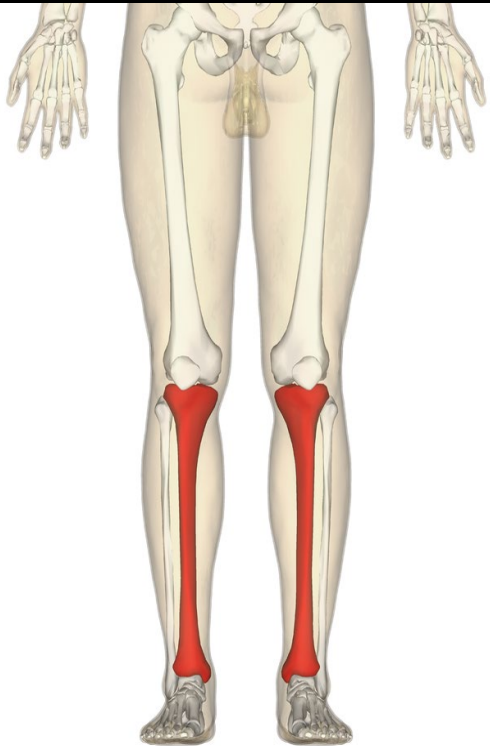
Tibial tuberosity

Interosseous crest

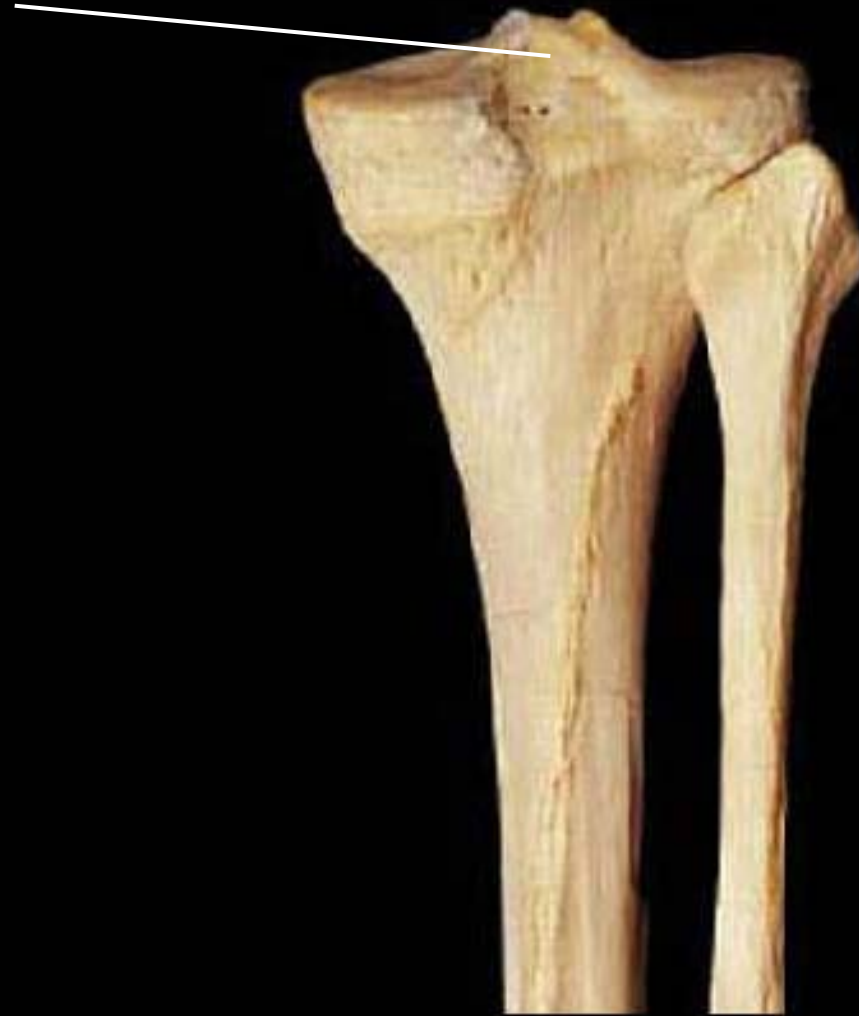Anterior crest

Fibular notch

Medial malleolus

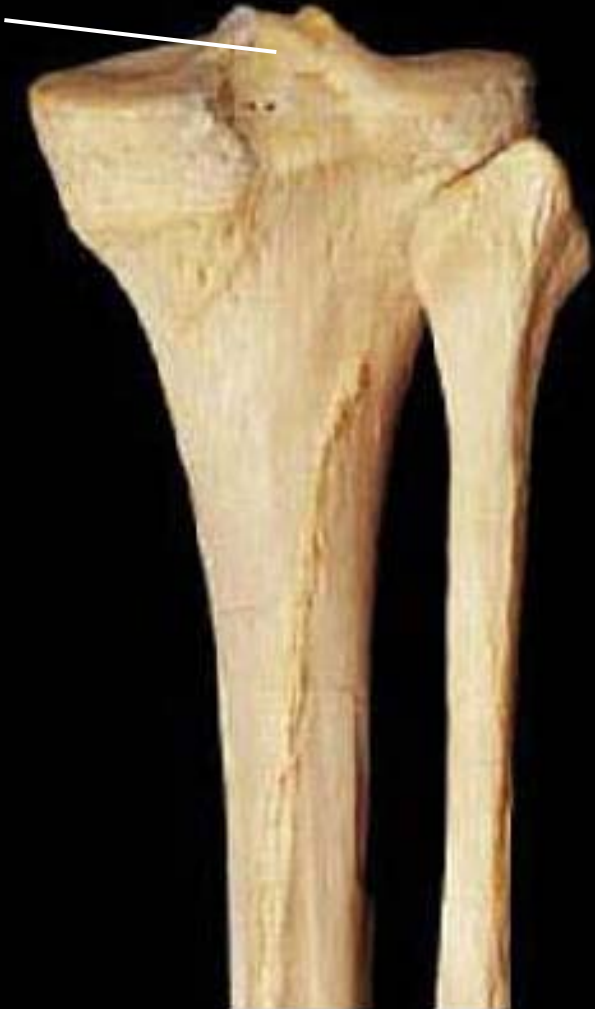

Tibia & fibula, posterior view, right side



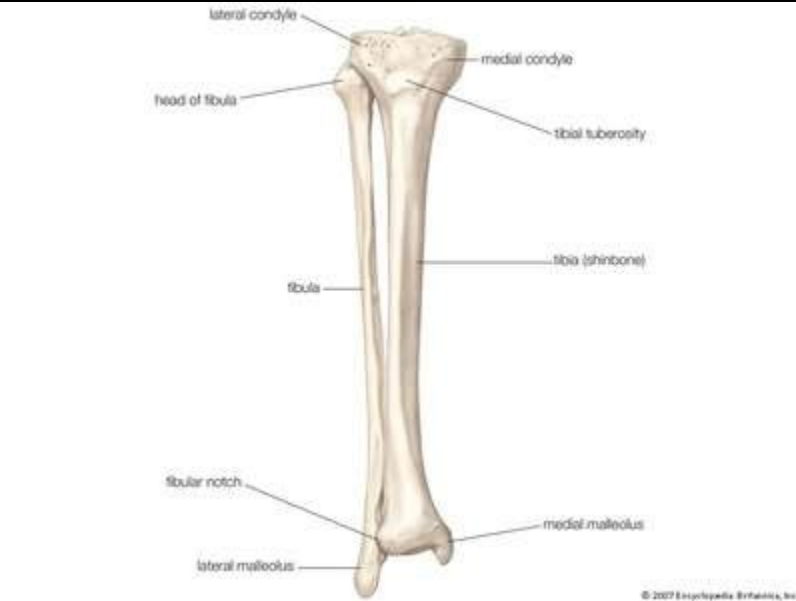Tibia & fibula, posterior view, right side

Intercondylar eminence



Tibia, posterior view, right side

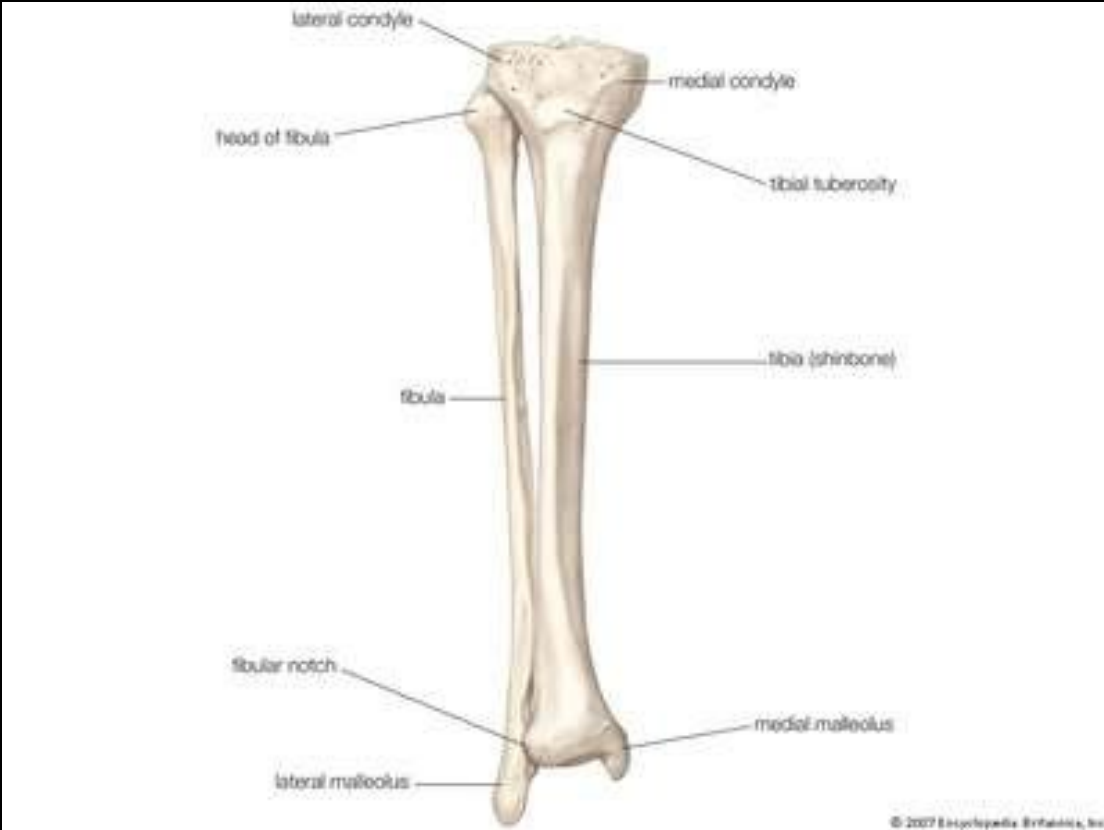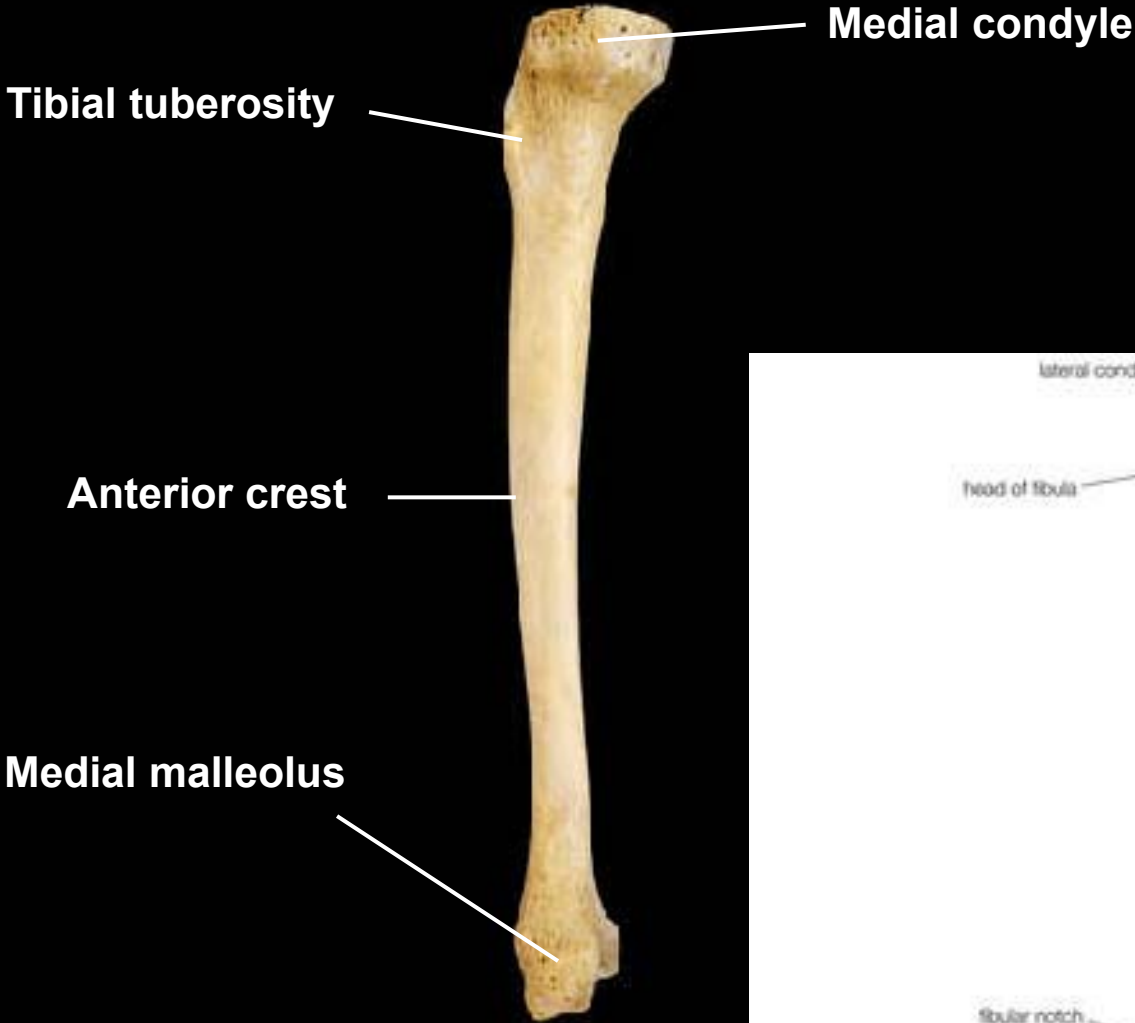
Intercondylar eminence
Medial condyle **Lateral condyle**



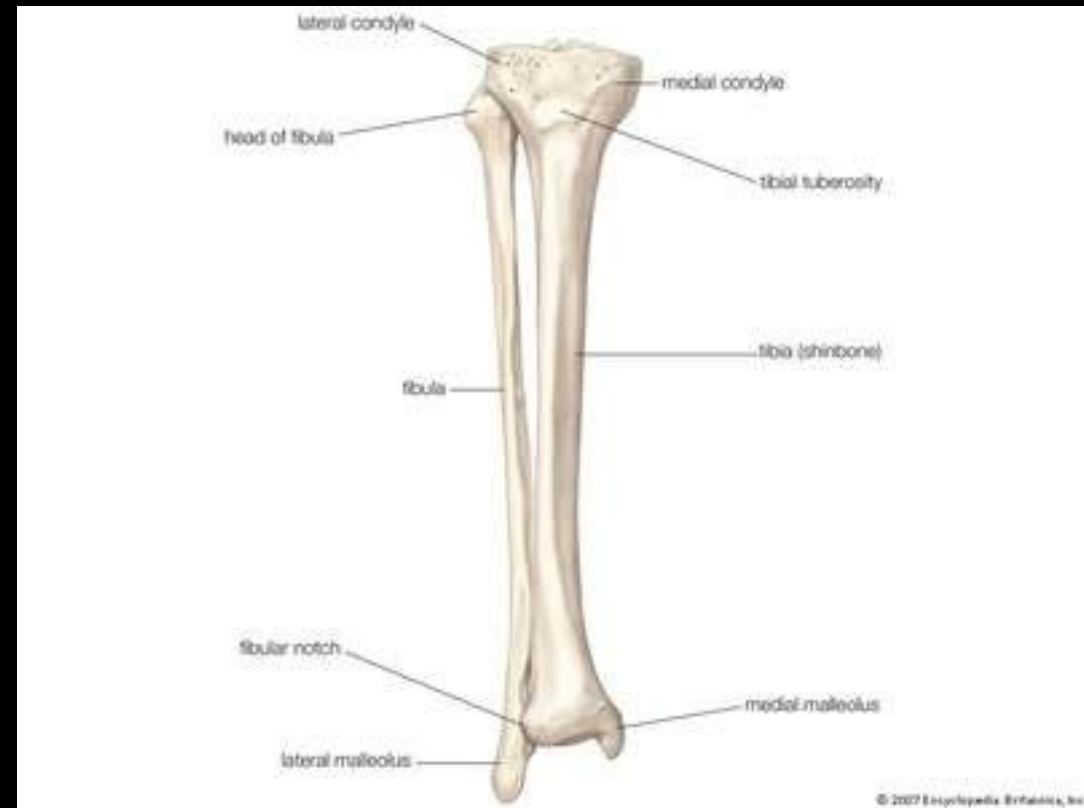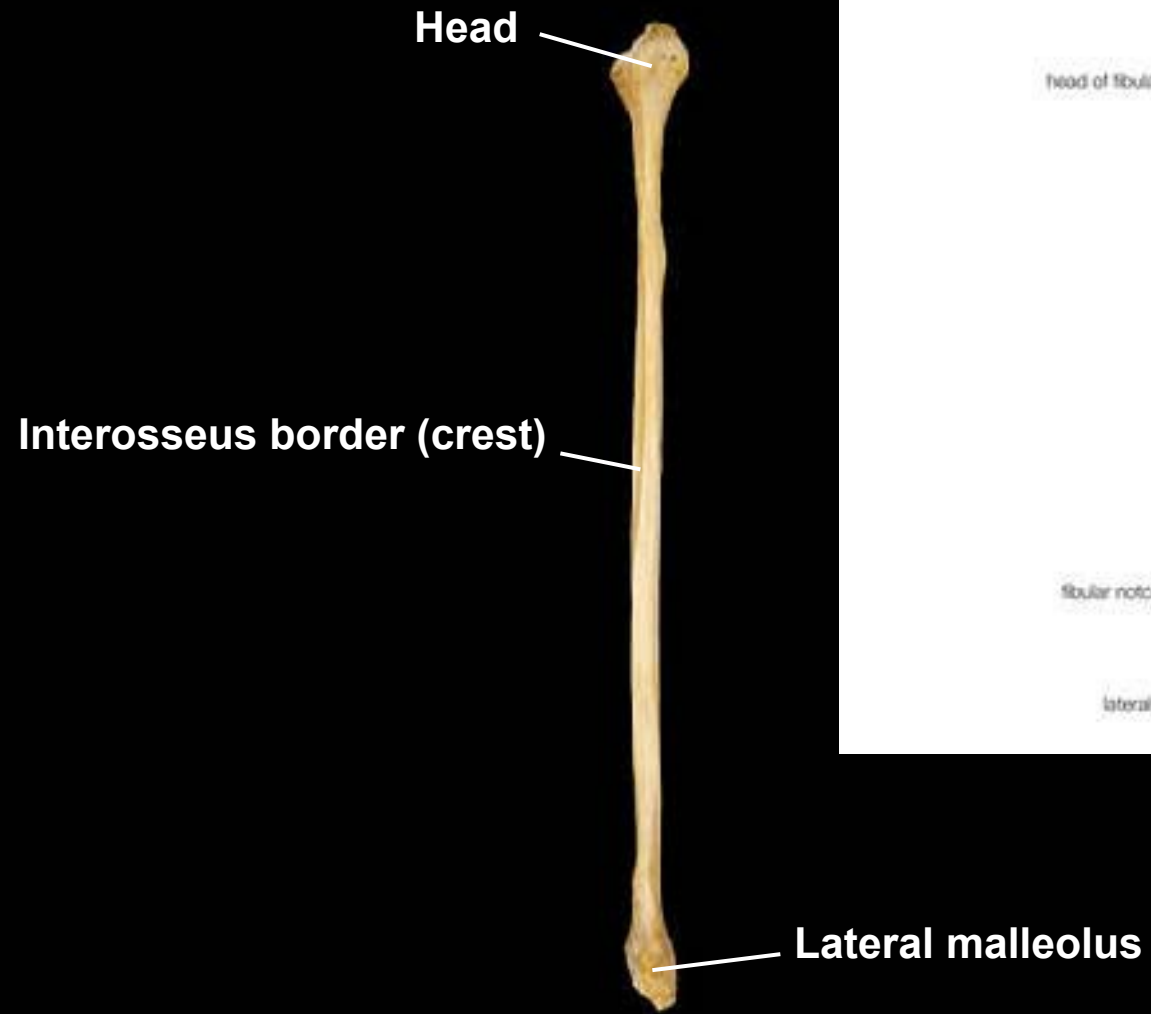
Medial malleolus **Fibular notch**



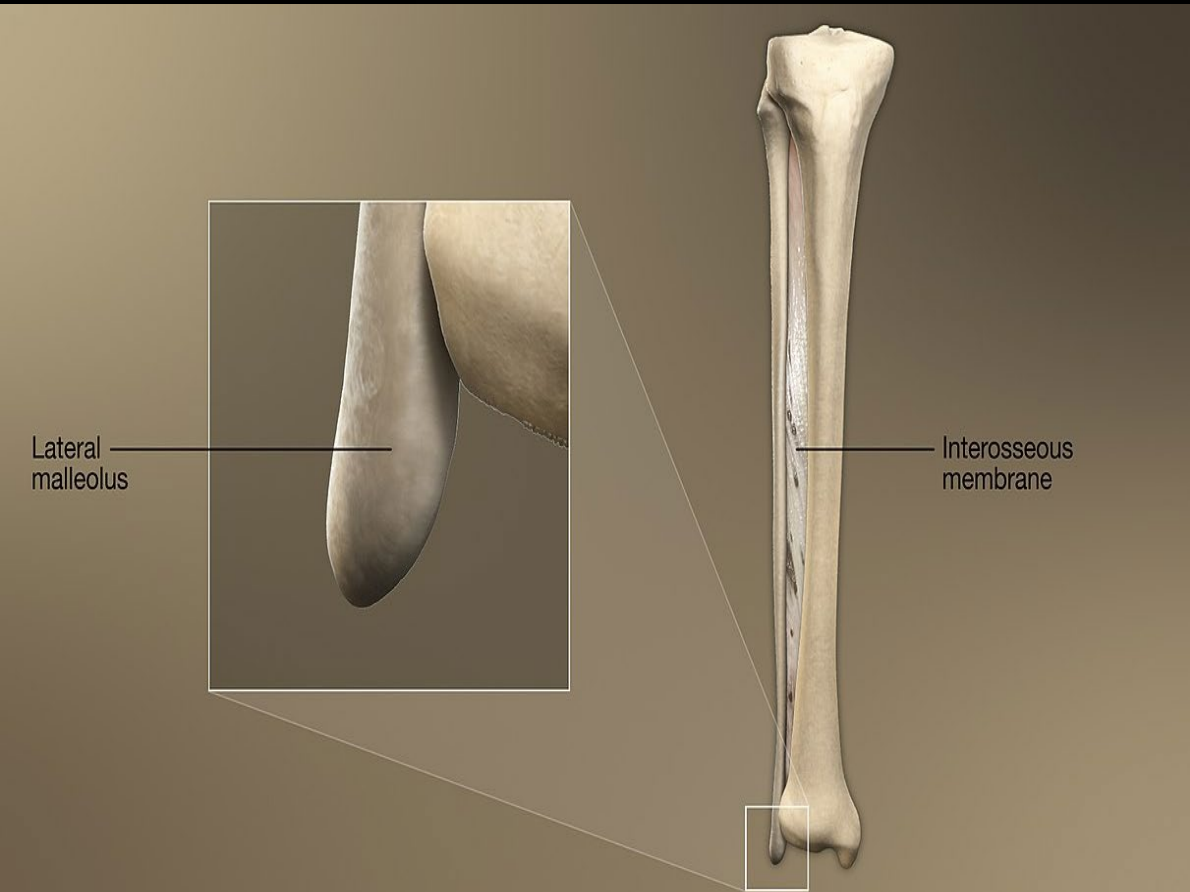
Tibia, medial view, right side

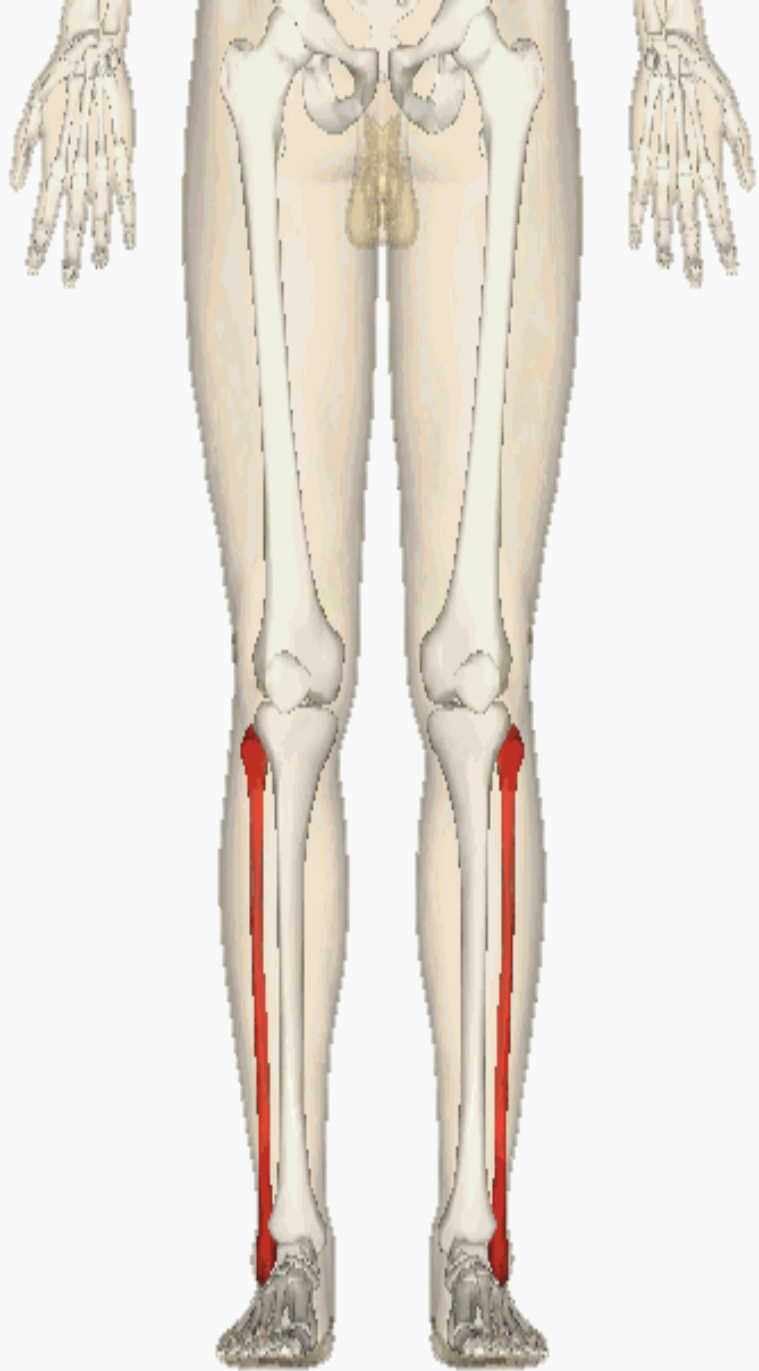

Fibula, anterior view, right side




Fibula, lateral view, right side

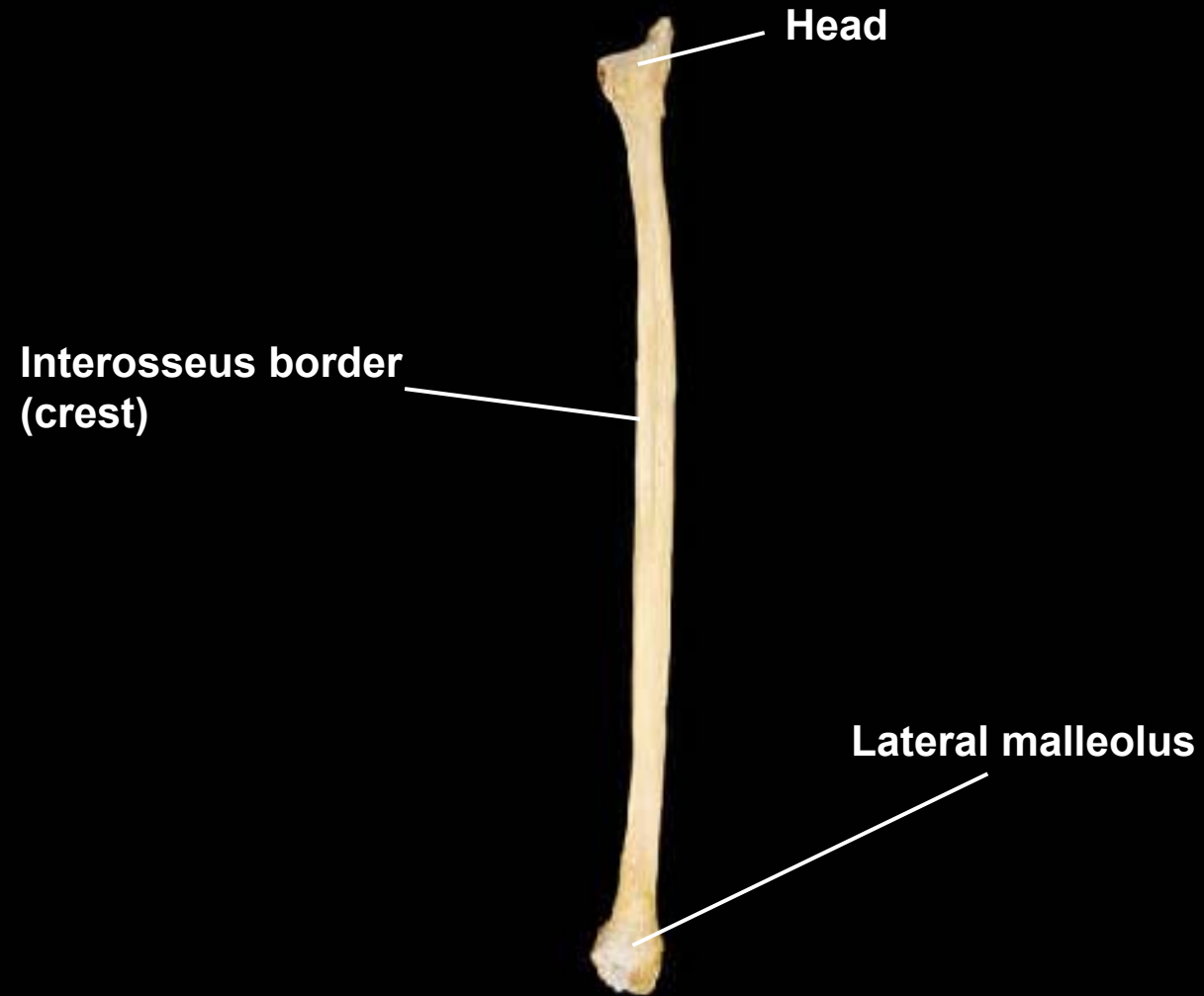


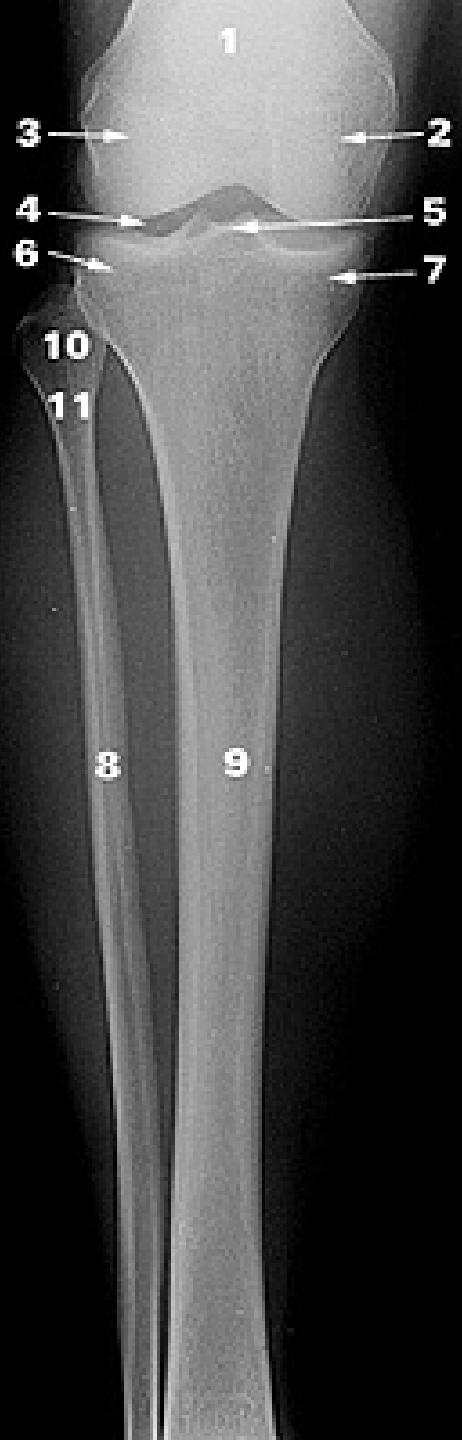


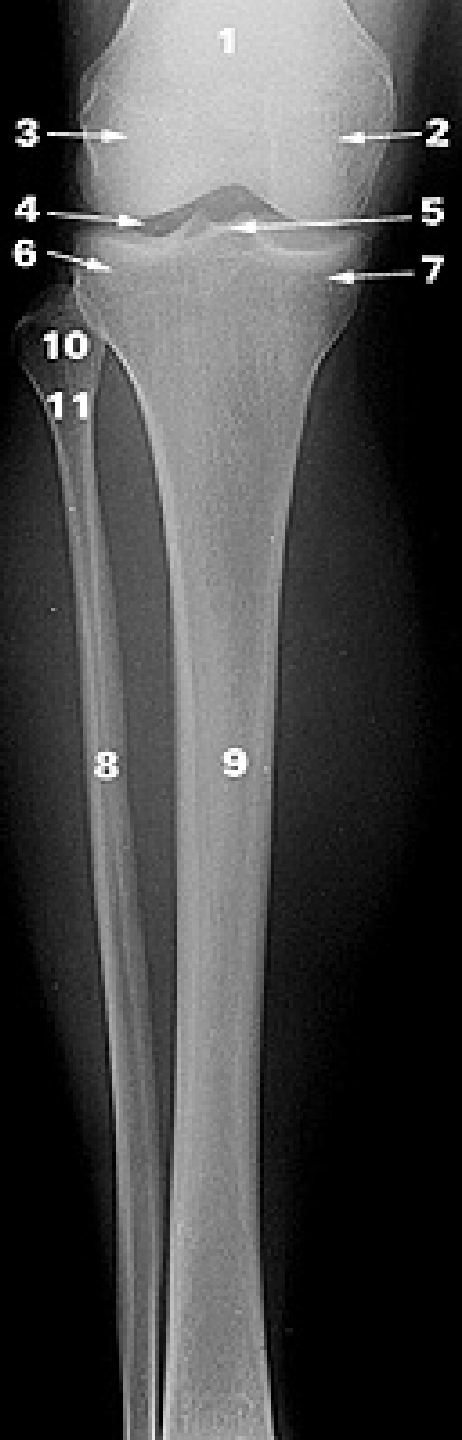
Fibula, posterior view, right side



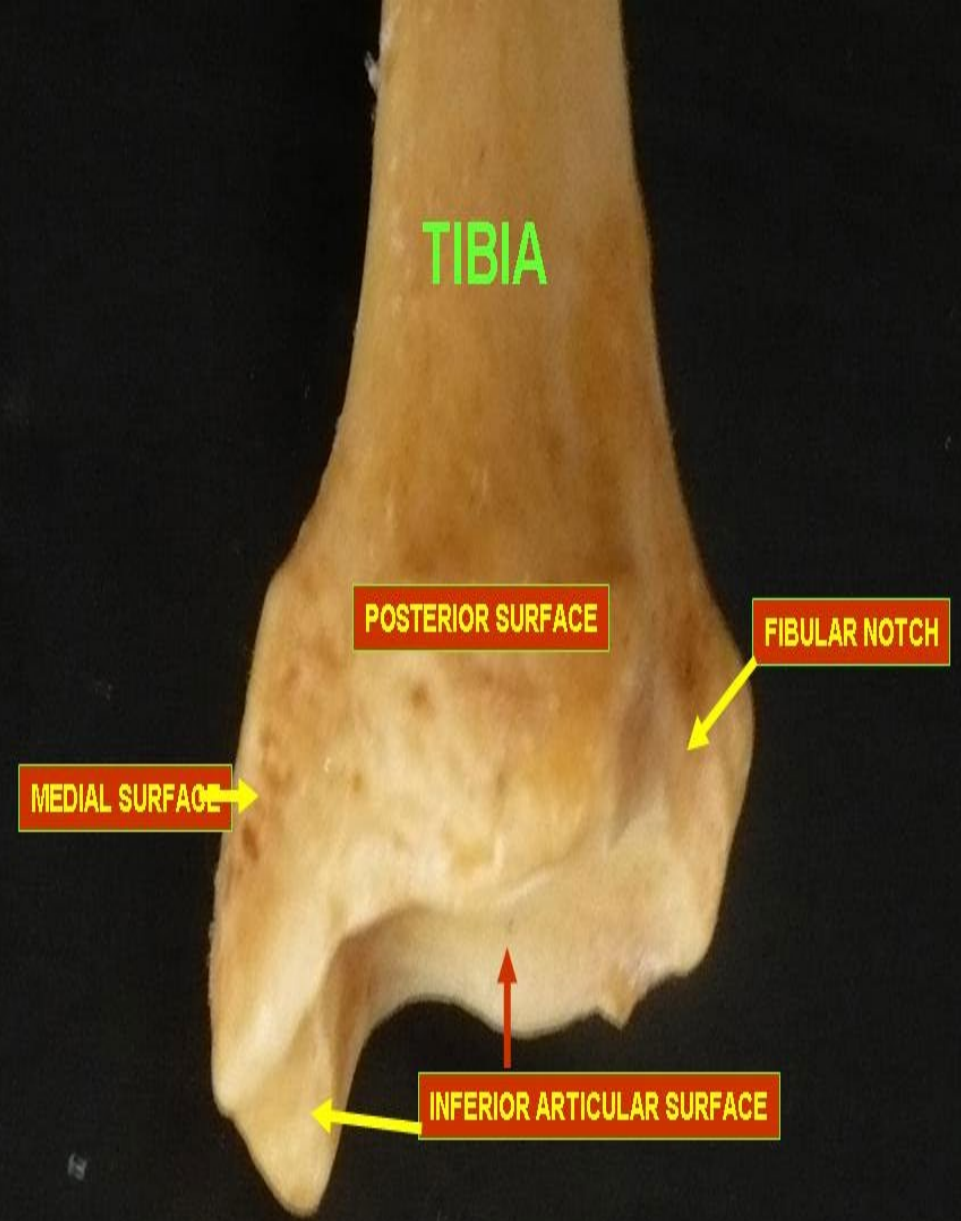
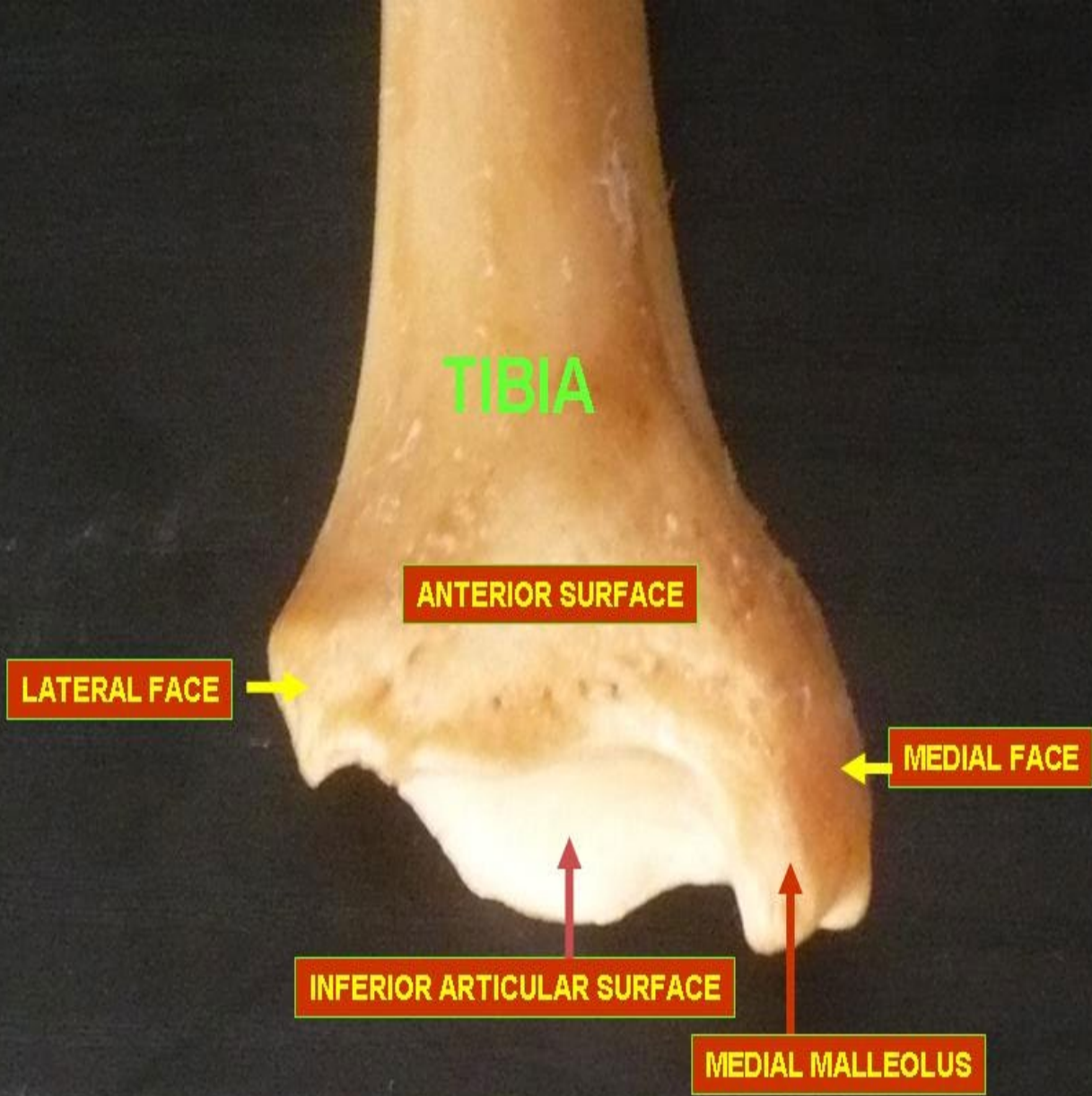
Fibula, medial view, right side



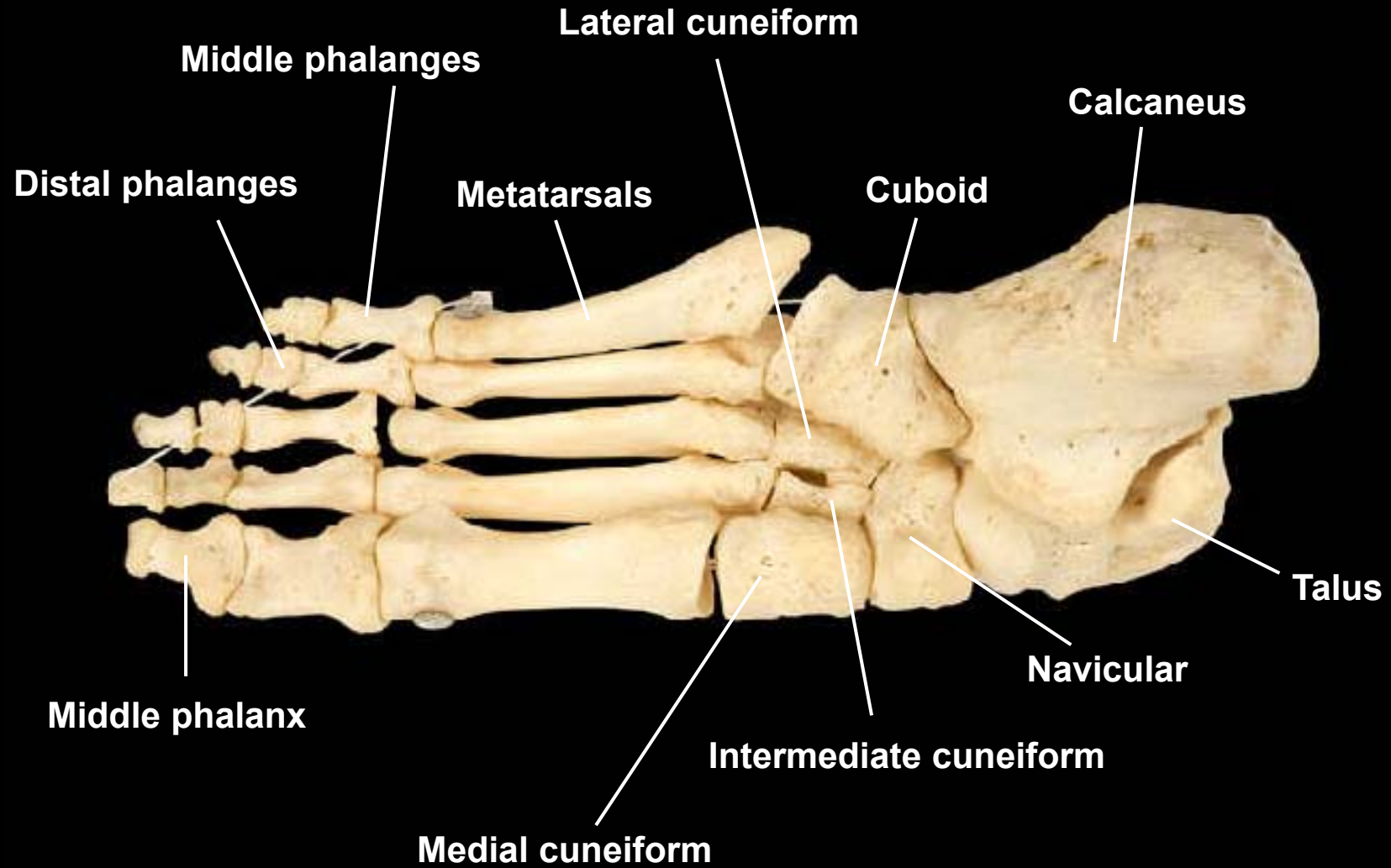




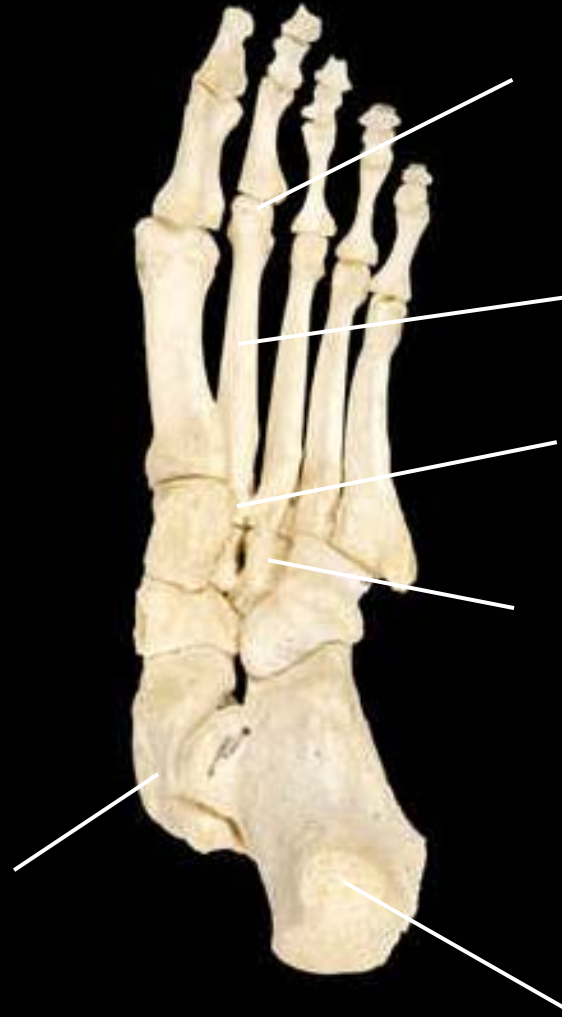1. Femur
2. Medial condyle of femur
3. Lateral condyle of femur
4. Knee joint
5. Intercondylar eminence
6. Lateral condyle of tibia
7. Medial condyle of tibia
8. Fibula
9. Tibia
10. Head of fibula
11. Neck of fibula



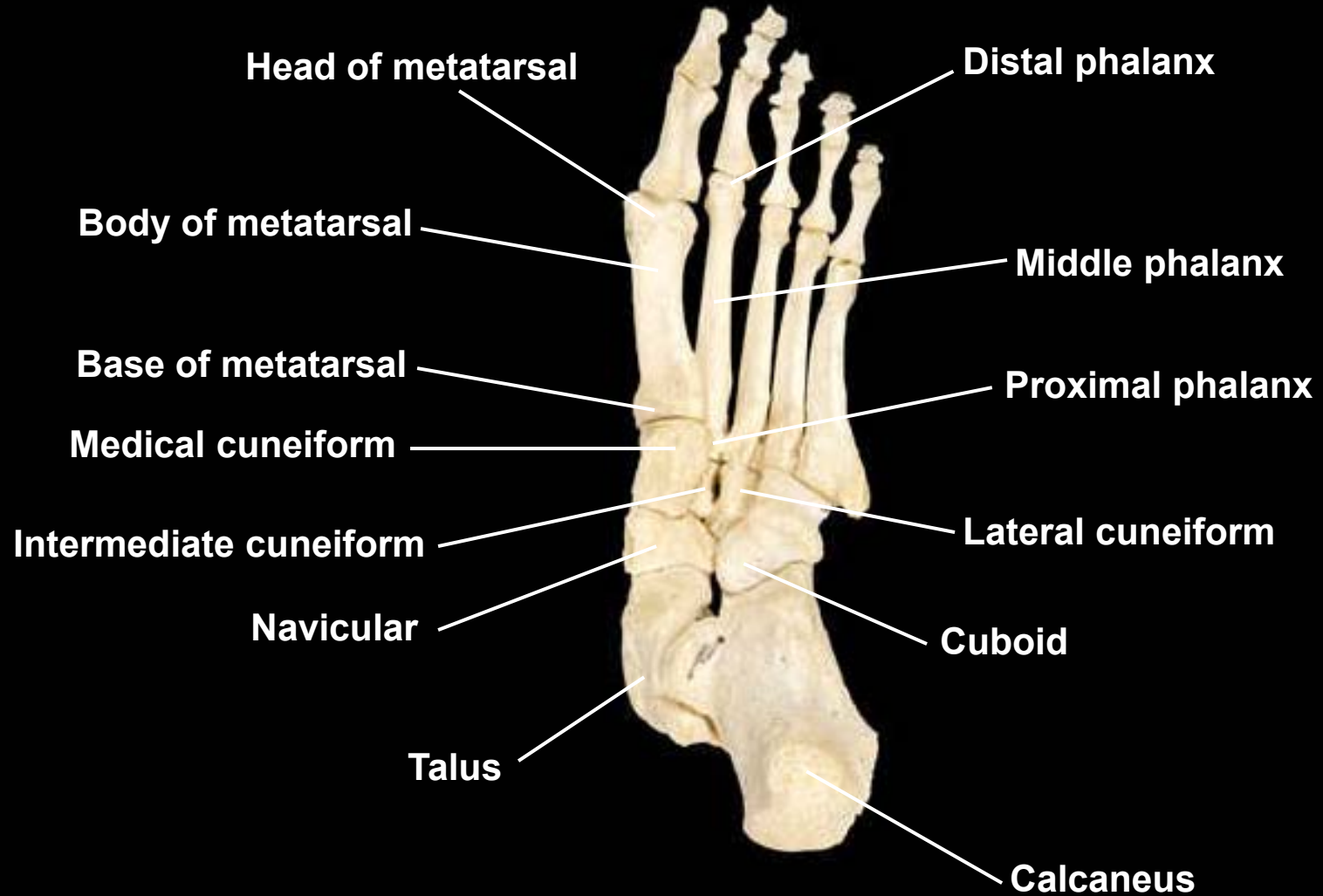Bones of the foot, inferior view, right side



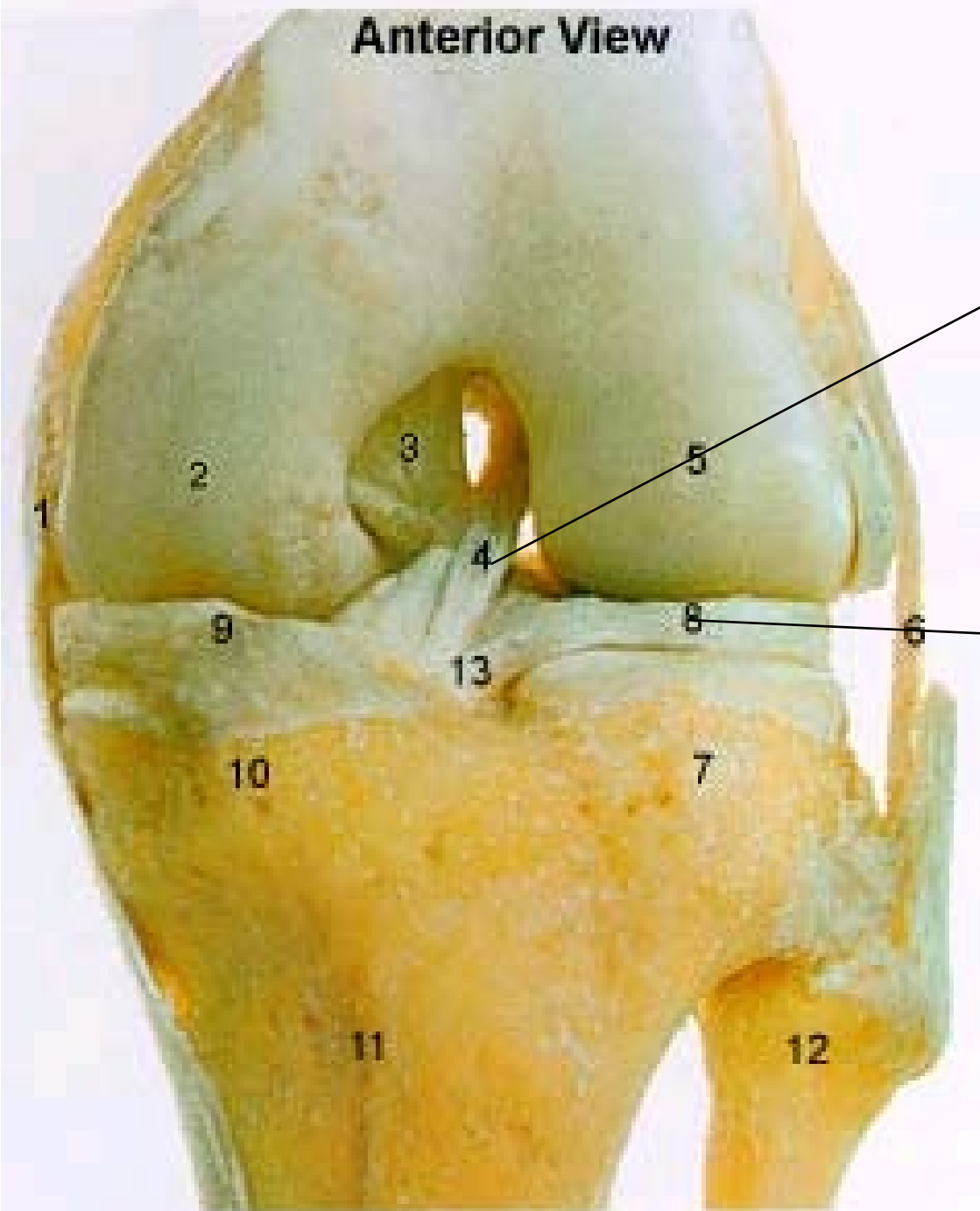
Bones of the foot, inferior view, left side



Bones of the foot, inferior view, left side



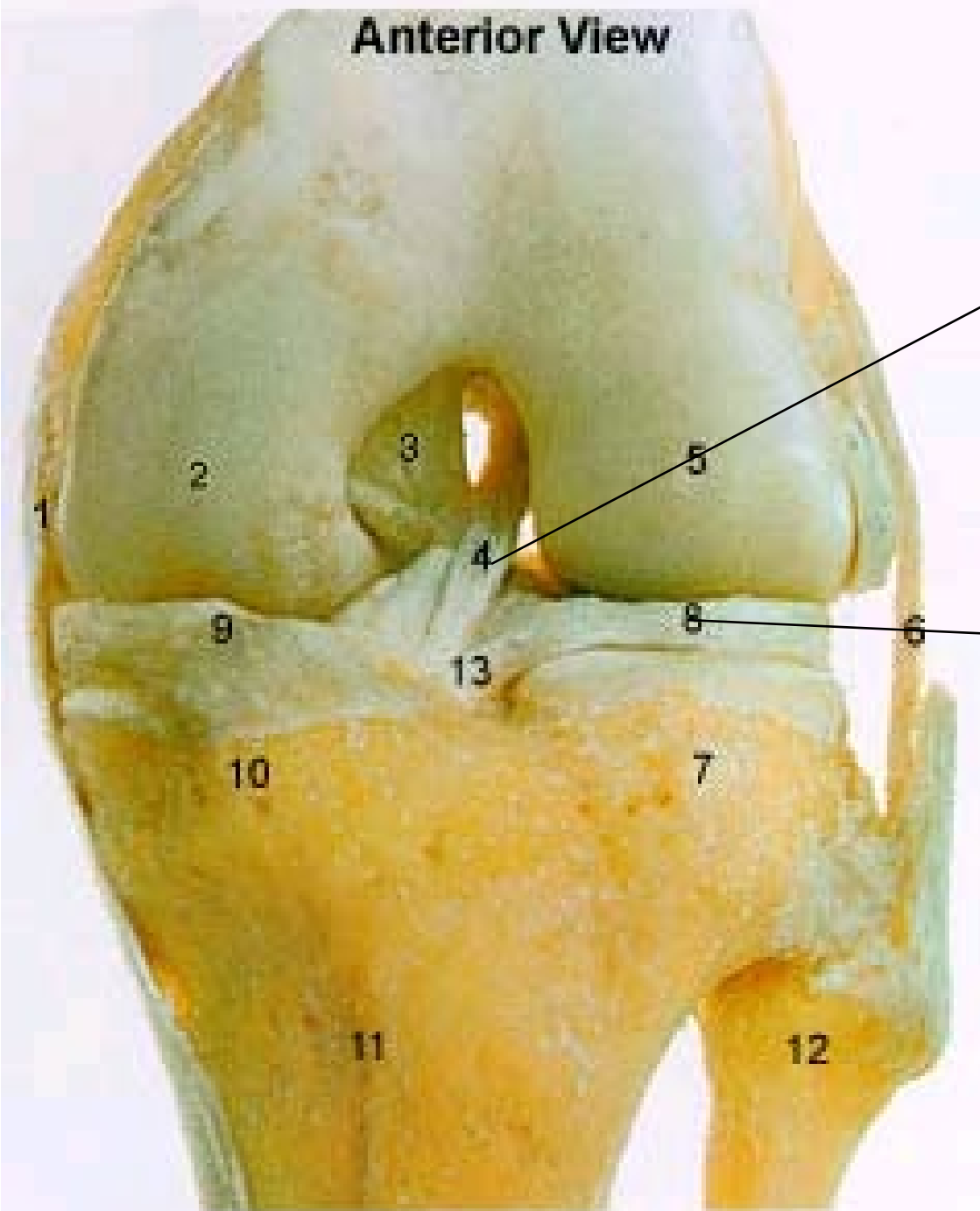
KNEE



Knee:

**Identify
structure #4**

**Identify
structure # 8**



Knee:

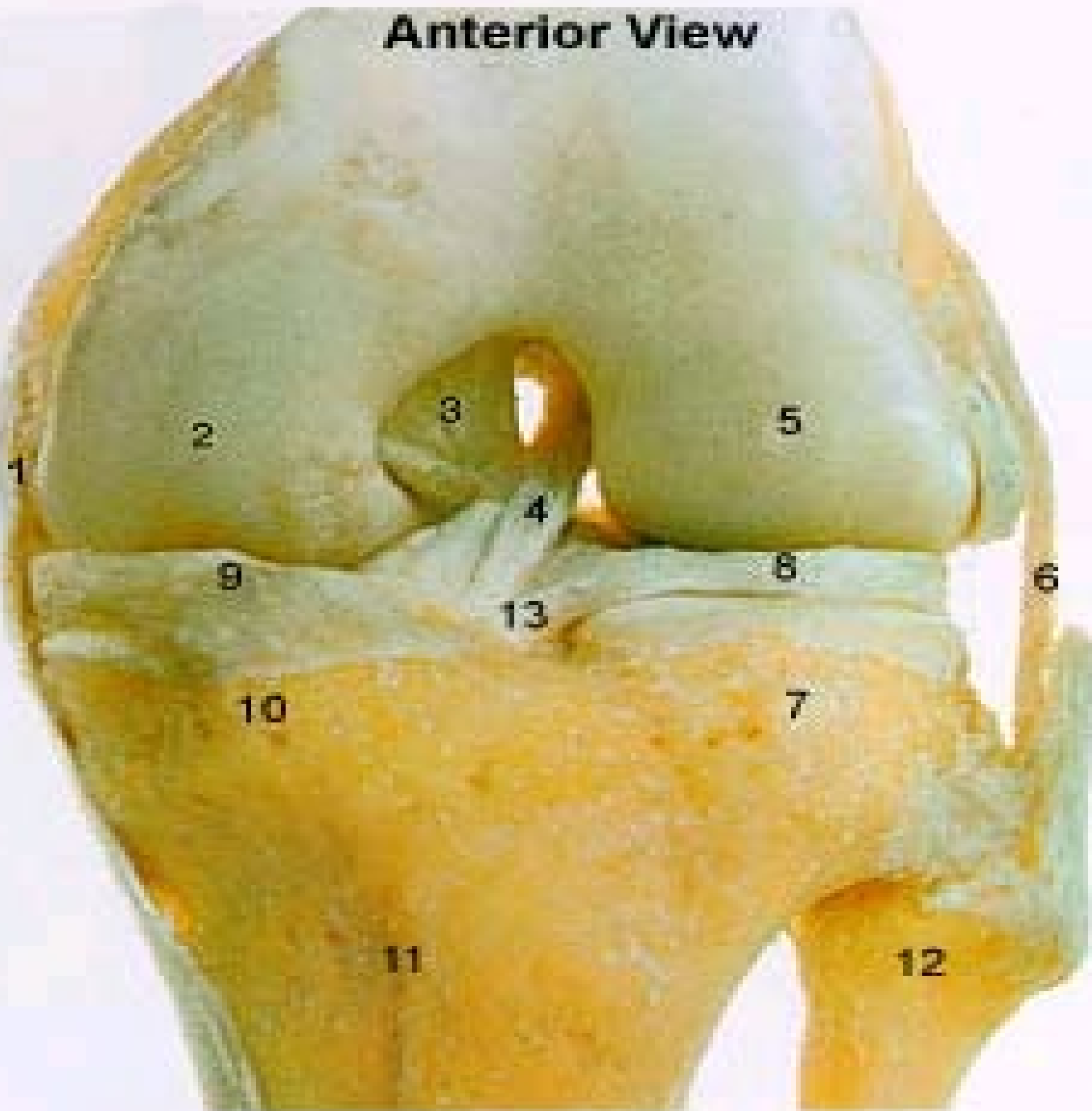
Identify structure

#4 Anterior Cruciate Ligament

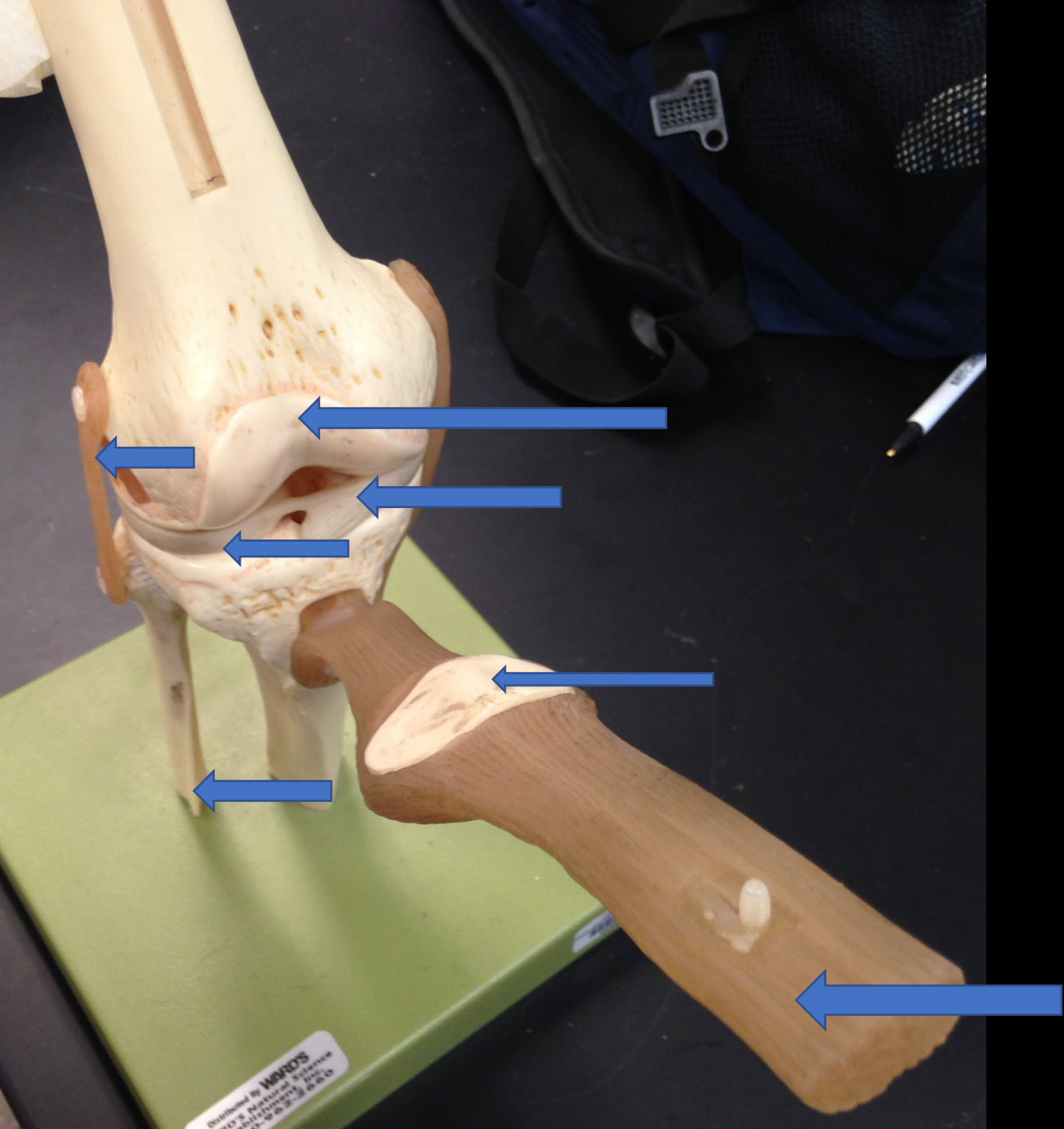
Identify structure

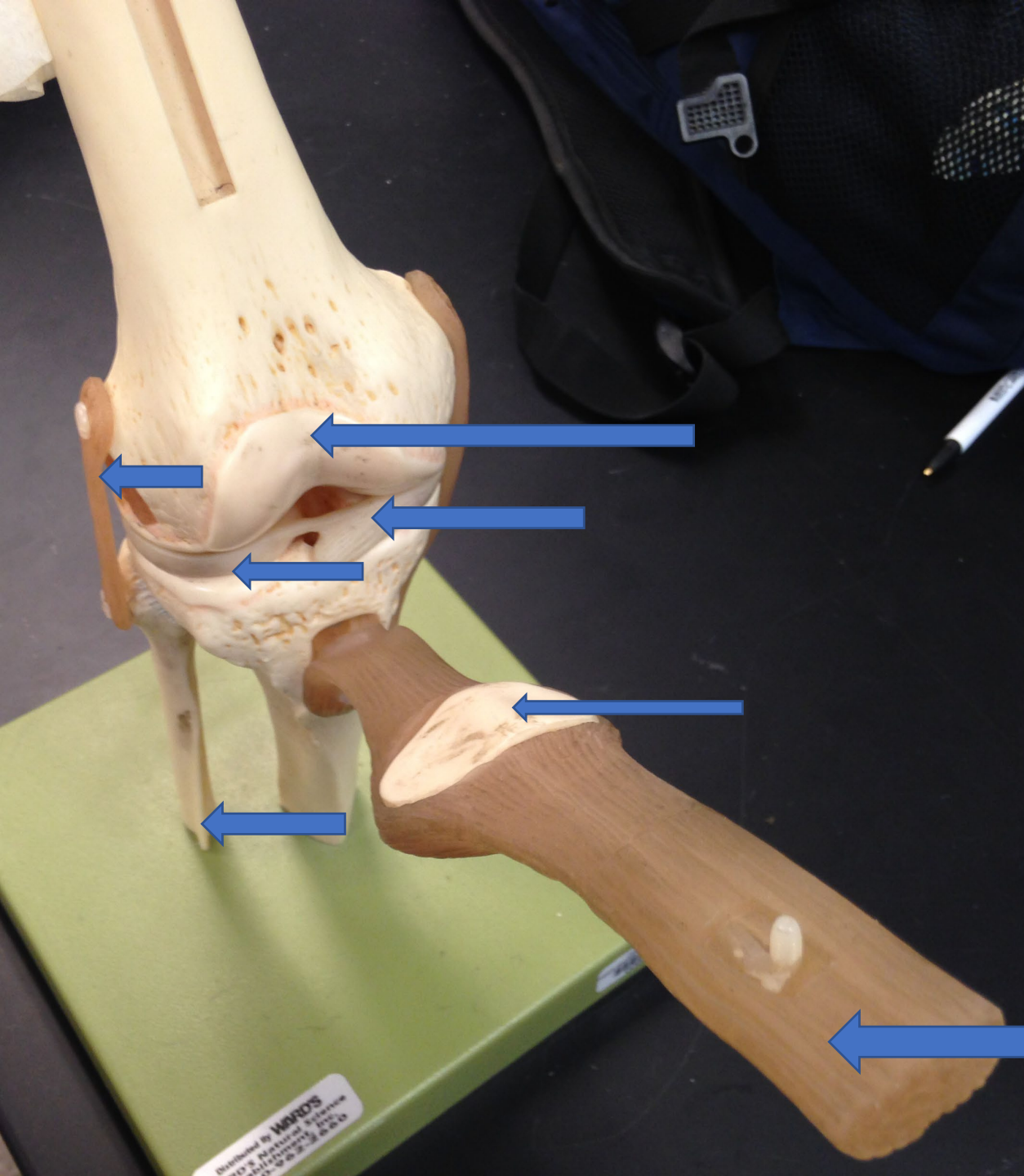
8 Lateral Meniscus

Anterior View

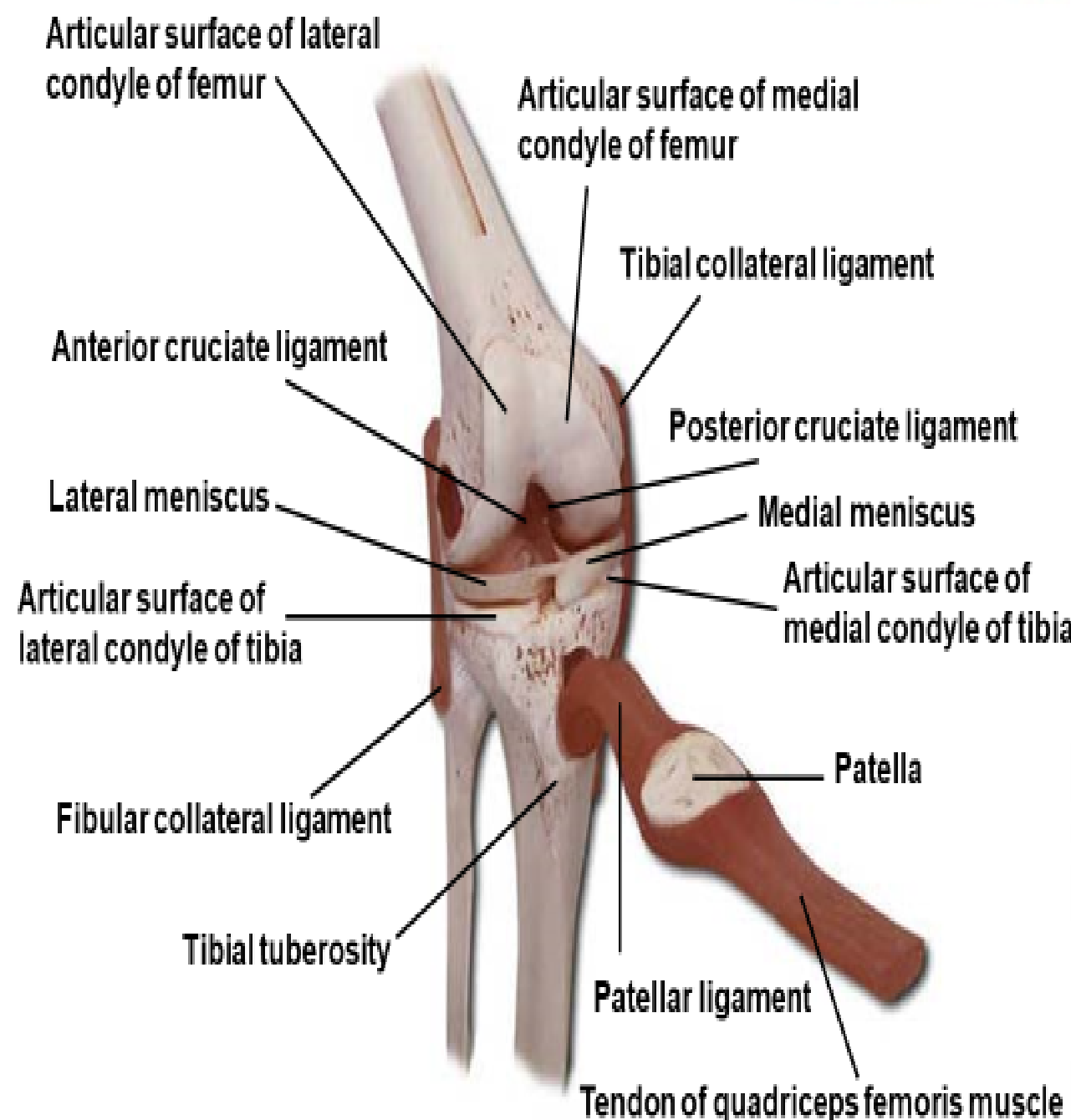


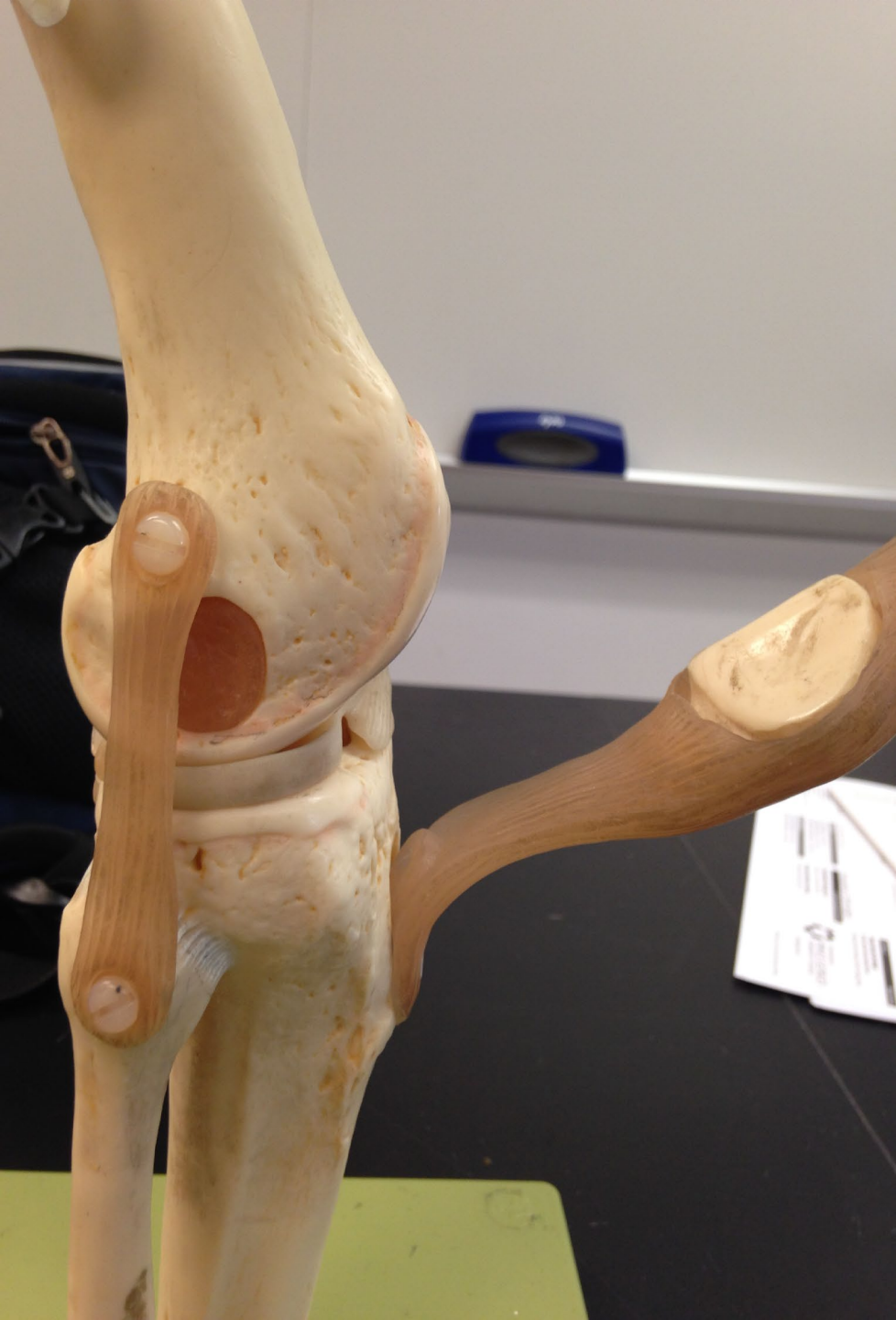1. Tibial Collateral Ligament
2. Medial Condyle of Femur
3. Posterior Cruciate Ligament
4. Anterior Cruciate Ligament
5. Lateral Condyle of Femur
6. Fibular Collateral Ligament
7. Lateral Condyle of Tibia
8. Lateral Meniscus
9. Medial Meniscus
10. Medial Condyle of Tibia
11. Tibia
12. Fibula
13. Transverse Ligament





Knee joint, anterior view





Quadriceps muscles

Quadriceps tendon

Femur

Quadriceps tendon

Patella

Articular cartilage

Lateral condyle

Posterior cruciate ligament

Anterior cruciate ligament

Lateral collateral ligament

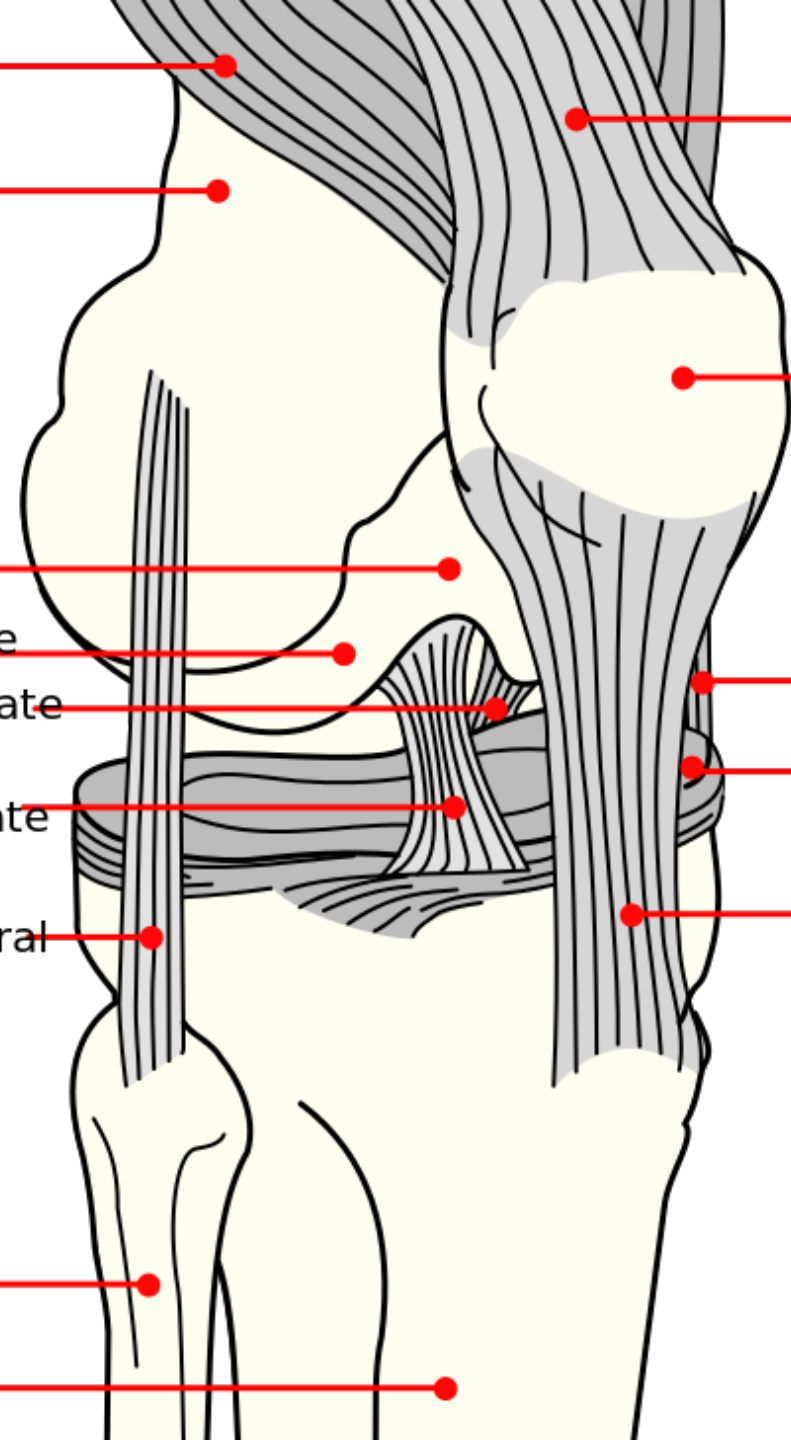
Medial collateral ligament

Meniscus

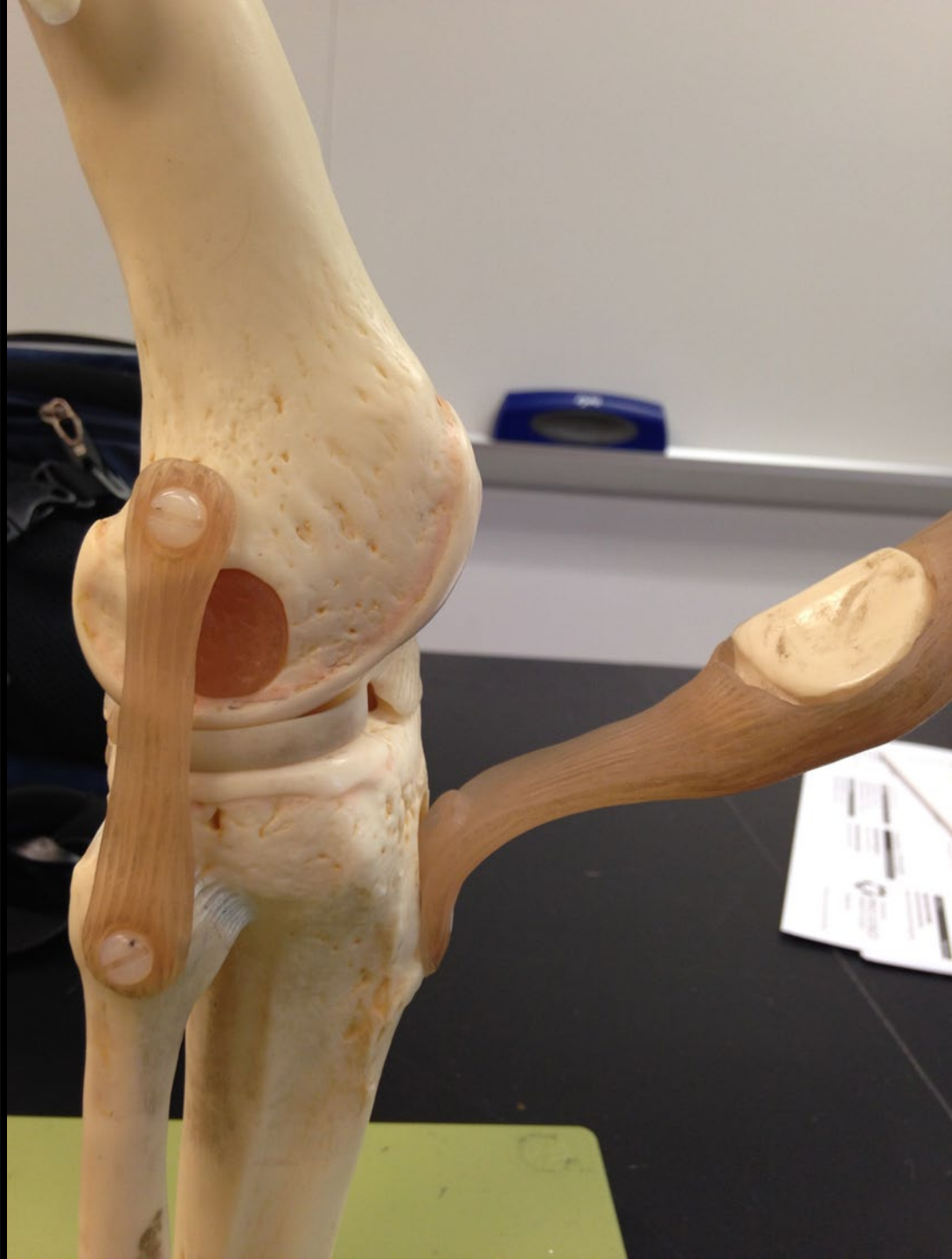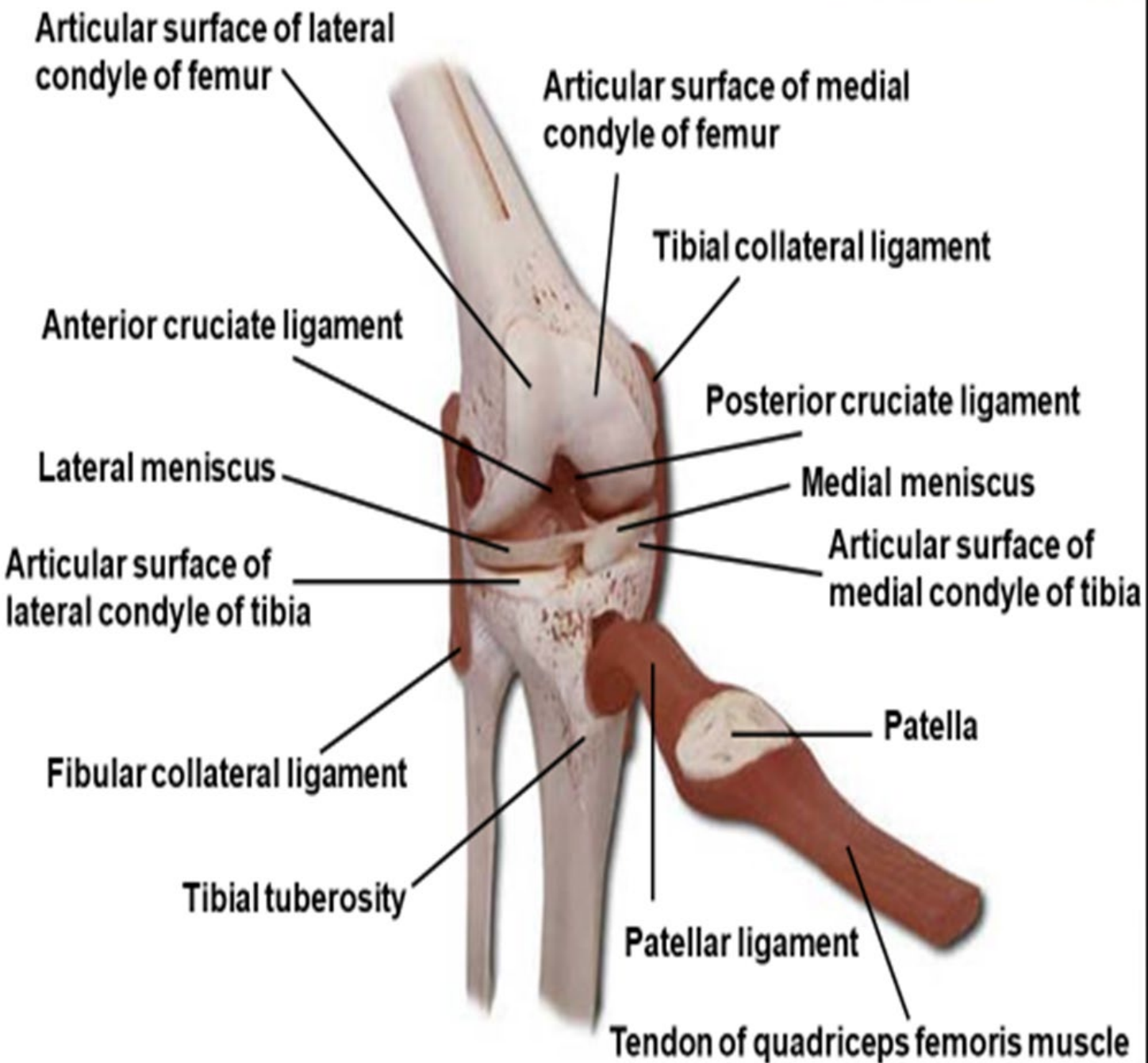
Patellar tendon (Ligament)

Fibula

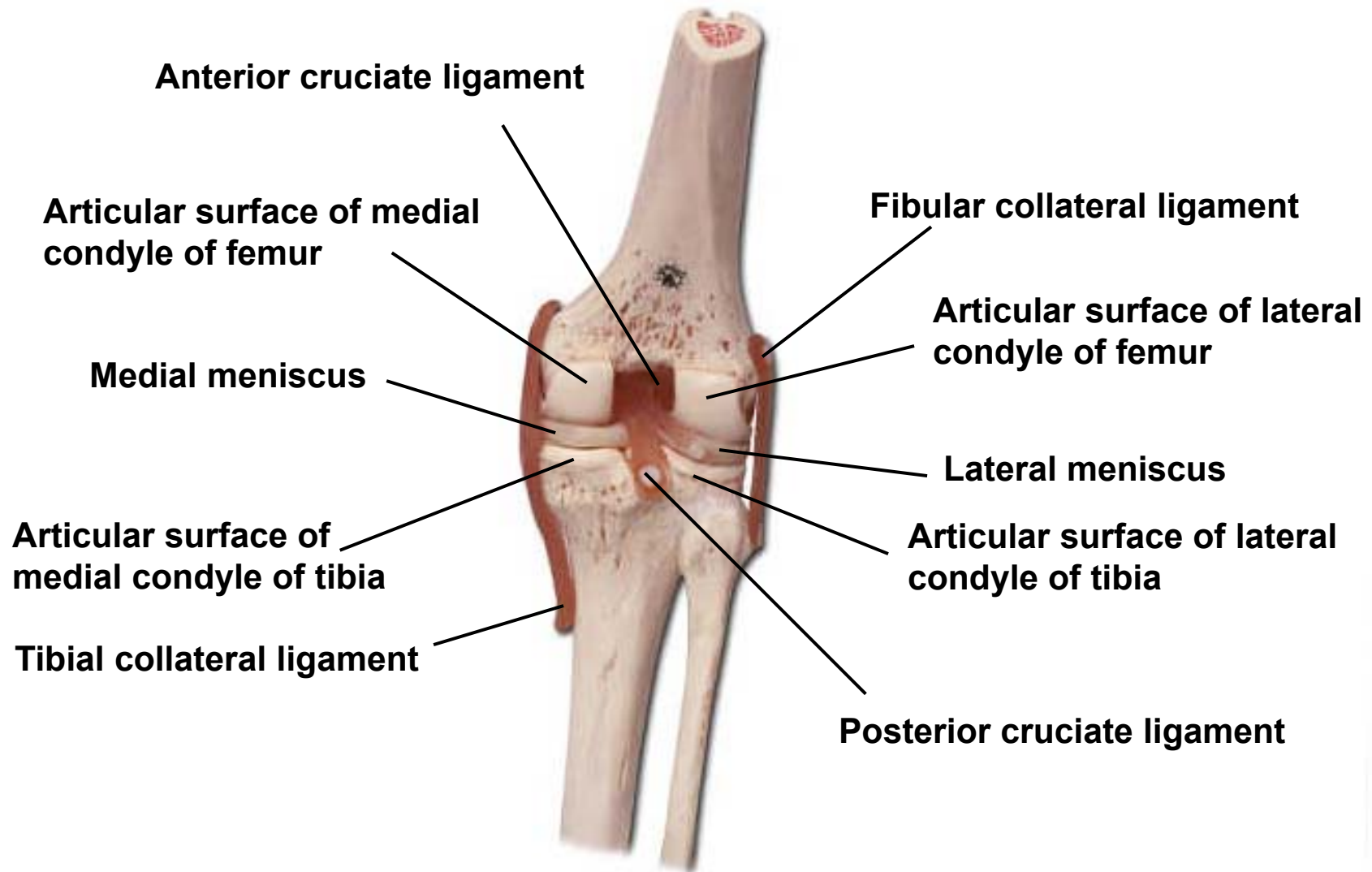
Tibia



Knee joint, anterior view



Knee joint, posterior view



Knee joint, anterior view

